



Videos on Osteology with Soft Parts and FAQs

BD Chaurasia's

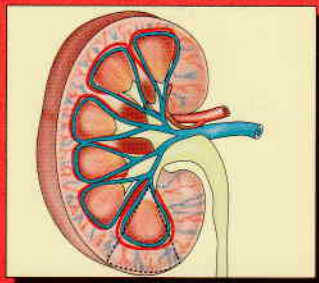
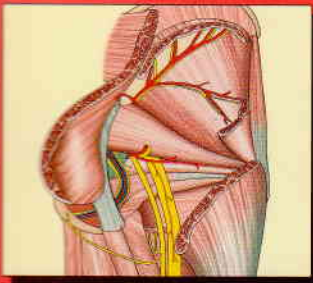
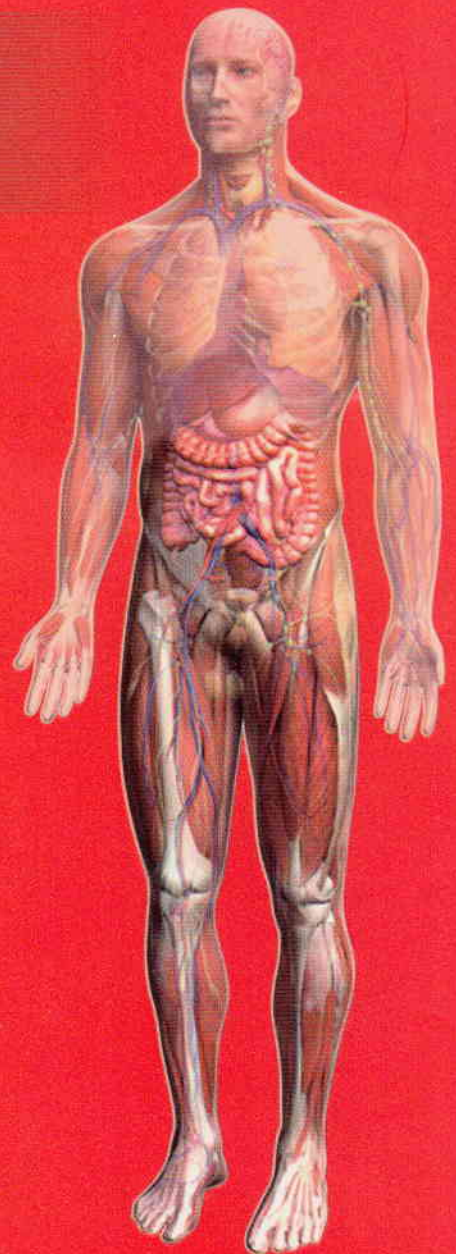
Human Anatomy

**Sixth
Edition**

Volume 2

**Regional and Applied
Dissection and Clinical**

**Lower Limb
Abdomen and Pelvis**



CBS

CBS Publishers & Distributors Pvt Ltd

mebooksfree.com

Contents

Preface to the Sixth Edition
Preface to the First Edition (excerpts)

vii

viii

Section 1 LOWER LIMB

1. Introduction 3

- Parts of the Lower Limb 4
- Related Terms 4

2. Bones of Lower Limb 6

- Hip Bone 6
- Ilium 6
- Pubis 10
- Ischium 11
- Acetabulum 12
- Obturator Foramen 12
- Clinical Anatomy 13
- Femur 13
- Clinical Anatomy 19
- Patella 19
- Clinical Anatomy 21
- Tibia 22
- Clinical Anatomy 25
- Fibula 25
- Clinical Anatomy 29
- Bones of the Foot 29
- Tarsus/Tarsals 29
- Talus 30
- Clinical Anatomy 31
- Calcaneus or Calcaneum 32
- Clinical Anatomy 33
- Navicular Bone 33
- Cuneiform Bones 34
- Medial Cuneiform 35
- Intermediate Cuneiform 35
- Lateral Cuneiform 35
- Cuboid 35

- Metatarsus 36
- Phalanges 37
- Clinical Anatomy 37
- Sesamoid Bones 38
- Mnemonics 38
- Facts to Remember 38
- Clinicoanatomical Problem 38
- Multiple Choice Questions 38

3. Front of Thigh 40

- Surface Landmarks 40
- Skin and Superficial Fascia 41
- Dissection 41
- Cutaneous Nerves 42
- Cutaneous Arteries 43
- Great or Long Saphenous Vein 43
- Superficial Inguinal Lymph Nodes 43
- Subcutaneous Bursae 43
- Clinical Anatomy 44
- Deep Fascia and Femoral Triangle 44
- Dissection 44
- Clinical Anatomy 45
- Femoral Triangle 45
- Boundaries 45
- Contents 45
- Femoral Sheath 47
- Femoral Canal 47
- Clinical Anatomy 48
- Femoral Artery 48
- Clinical Anatomy 51
- Femoral Vein 51
- Femoral Nerve 52
- Branches and Distribution 52



- Muscles of the Front of the Thigh 52
 Iliacus and Psoas Major 53
Clinical Anatomy 55
 Adductor/Hunter's/Subsartorial Canal 55
Dissection 55
Facts to Remember 57
Clinicoanatomical Problem 57
Multiple Choice Questions 57
- 4. Medial Side of Thigh** 59
- Adductor Compartment 59
Dissection 59
 Boundaries 59
 Muscles of Adductor Compartment of Thigh 59
 Relations of Adductor Longus 60
 Obturator Nerve 61
Clinical Anatomy 62
 Accessory Obturator Nerve 62
 Obturator Artery 63
 Medial Circumflex Femoral Artery 63
Clinical Anatomy 63
Facts to Remember 63
Clinicoanatomical Problem 64
Multiple Choice Questions 64
- 5. Gluteal Region** 65
- Introduction 65
 Surface Landmarks 65
Dissection 66
 Superficial Fascia 66
 Cutaneous Nerves 66
 Cutaneous Vessels and Lymphatics 66
 Deep Fascia 66
 Muscles of Gluteal Region 66
Dissection 66
 Structures under Cover of Gluteus
 Maximus 67
 Structures Deep to the Gluteus Medius 70
 Structures Deep to the Gluteus Minimus 70
Clinical Anatomy 70
 Sacrotuberous and Sacrospinous
 Ligaments 71
 Nerves of the Gluteal Region 72
 Superior Gluteal Nerve 72
 Inferior Gluteal Nerve 72
 Sciatic Nerve 72
Clinical Anatomy 72
 Posterior Cutaneous Nerve of the Thigh 72
 Nerve to Quadratus Femoris 73
 Pudendal Nerve 73
 Nerve to the Obturator Internus 73
 Perforating Cutaneous Nerve 73
 Arteries of Gluteal Region 73
 Superior Gluteal Artery 73
 Inferior Gluteal Artery 73
 Internal Pudendal Artery 73
 Trochanteric Anastomoses 73
 Cruciate Anastomoses 73
 Structures Passing through the Greater
 Sciatic Foramen (Gateway of Gluteal
 Region) 73
 Structures Passing through the Lesser
 Sciatic Foramen 74
Facts to Remember 74
Clinicoanatomical Problem 75
Multiple Choice Questions 75
- 6. Popliteal Fossa** 76
- Introduction 76
 Surface Landmarks 76
 Popliteal Fossa 76
Dissection 76
 Popliteal Artery 78
Clinical Anatomy 79
 Popliteal Vein 79
 Tibial Nerve 79
Clinical Anatomy 80
 Common Peroneal Nerve 80
 Posterior Cutaneous Nerve of Thigh 80
 Genicular Branch of Obturator Nerve 80
 Popliteal Lymph Nodes 80
Clinical Anatomy 80
 Anastomoses around the Knee Joint 80
Mnemonics 81
Facts to Remember 82
Clinicoanatomical Problem 82
Multiple Choice Questions 82
- 7. Back of Thigh** 83
- Introduction 83
 Muscles and Nerves 83
Dissection 83
 Muscles of Back of the Thigh 83
Clinical Anatomy 83
 Sciatic Nerve 84
 Arteries of the Back of Thigh 87
 Anastomoses on the Back of Thigh 88
Facts to Remember 89
Clinicoanatomical Problem 89
Multiple Choice Questions 89



8. Front, Lateral and Medial Sides of Leg and Dorsum of Foot 90

- Introduction 90
- Surface Landmarks 90
- Superficial Fascia 91
- Contents 91
- Dissection** 91
 - Superficial Veins 91
 - Cutaneous Nerves 91
- Clinical Anatomy** 92
- Deep Fascia 92
- Dissection** 92
 - Superior Extensor Retinaculum 93
 - Inferior Extensor Retinaculum 93
- Clinical Anatomy** 93
- Muscles of Front of Leg 93
- Dissection** 93
- Muscles of Anterior Compartment of the Leg 94
- Anterior Tibial Artery 94
- Deep Peroneal Nerve 95
- Dorsum of Foot 97
- Dissection** 97
- Dorsalis Pedis Artery (Dorsal Artery of the Foot) 97
- Clinical Anatomy** 98
- Fascia and Muscles of Lateral Side of the Leg 98
- Dissection** 98
- Peroneal Retinacula 98
- Clinical Anatomy** 98
- Peroneal Muscles 98
- Clinical Anatomy** 98
- Superficial Peroneal Nerve 99
- Dissection** 99
- Clinical Anatomy** 100
- Medial Side of the Leg 100
- Dissection** 100
- Clinical Anatomy** 101
- Mnemonics 101
- Facts to Remember 101
- Clinicoanatomical Problem** 101
- Multiple Choice Questions** 102

9. Back of Leg 103

- Introduction 103
- Superficial Fascia 103
- Dissection** 103
 - Small or Short Saphenous Vein 103
 - Great or Long Saphenous Vein 103
 - Cutaneous Nerves 103

- Clinical Anatomy** 104
- Deep Fascia 104
- Dissection** 104
- Boundaries and Subdivisions 104
 - Flexor Retinaculum 105
- Clinical Anatomy** 105
- Superficial Muscles 105
- Dissection** 107
- Deep Muscles 108
- Clinical Anatomy** 108
- Posterior Tibial Artery 109
- Peroneal Artery 110
- Tibial Nerve 110
- Clinical Anatomy** 111
- Mnemonics 111
- Facts to Remember 112
- Clinicoanatomical Problem** 112
- Multiple Choice Questions** 112

10. Sole of Foot 113

- Introduction 113
- Skin 113
- Dissection** 113
- Fasciae 113
- Dissection** 113
 - Superficial Fascia 114
 - Deep Fascia 114
 - Plantar Aponeurosis 114
 - Deep Transverse Metatarsal Ligaments 115
 - Fibrous Flexor Sheaths 115
- Clinical Anatomy** 115
- Muscles and Tendons of the First and Second Layers 115
- Dissection** 115
- Muscles and Tendons of Third and Fourth Layers 115
- Dissection** 115
- Plantar Vessels and Nerves 116
- Dissection** 116
- Medial Plantar Nerve 116
- Lateral Plantar Nerve 119
- Clinical Anatomy** 119
- Medial Plantar Artery 119
- Lateral Plantar Artery 120
- Plantar Arch 121
- Clinical Anatomy** 122
- Facts to Remember 123
- Clinicoanatomical Problem** 123
- Multiple Choice Questions** 123



11. Venous and Lymphatic Drainage, Segmental Innervation, and Comparison of Lower and Upper Limbs 124

- Venous Drainage 124
 - Factors Helping Venous Return 124
- Veins of Lower Limb 124
- Long Saphenous Veins 125
- Small or Short Saphenous Vein 126
- Perforating Veins 126
- Clinical Anatomy** 127
- Lymphatic Drainage 127
 - Classification 128
- Superficial Lymphatics 128
- Deep Lymphatics 129
- Clinical Anatomy** 129
- Segmental Innervation 130
 - Dermatomes 130
 - Myotomes 131
- Clinical Anatomy** 131
- Sympathetic Innervation 131
- Mnemonics** 131
- Facts to Remember** 135
- Clinicoanatomical Problem** 135
- Multiple Choice Questions** 135

12. Joints of Lower Limb 136

- Hip Joint 136
- Dissection** 136
 - Type 136
 - Ligaments 137
 - Relations of the Hip Joint 138
 - Blood Supply 138
 - Nerve Supply 139
 - Movements 139
- Clinical Anatomy** 139
- Knee Joint 140
- Dissection** 140
 - Type 141
 - Ligaments 141
- Synovial Membrane 144
- Dissection** 144
 - Bursae around the Knee 144
- Relations of Knee Joint 144
 - Blood Supply 144
 - Nerve Supply 145
- Movements at the Knee Joint 145
- Dissection** 145
 - Locking and Unlocking of the Knee Joint 146

- Clinical Anatomy** 146
- Ankle Joint 147
- Dissection** 147
 - Ligaments 148
 - Relations of the Ankle Joint 149
 - Movements 149
 - Blood Supply 150
 - Nerve Supply 150
- Clinical Anatomy** 150
- Tibiofibular Joints 150
- Dissection** 150
 - Superior Tibiofibular Joint 150
 - Middle Tibiofibular Joint 150
 - Inferior Tibiofibular Joint 151
- Joints of the Foot 151
- Dissection** 151
 - Talocalcanean Joint 152
 - Movements 152
 - Talocalcaneonavicular Joint 152
 - Movements 152
 - Calcaneocuboid Joint 153
 - Transverse Tarsal or Midtarsal Joint 153
 - Inversion and Eversion of the Foot 153
 - Joints Taking Part 153
 - Muscles Producing Movements 154
- Dissection** 154
 - Joint Cavities of Foot 154
 - Metatarsophalangeal and Interphalangeal Joints 155
- Clinical Anatomy** 155
- Mnemonics** of Locking and Unlocking 156
- Facts to Remember** 157
- Clinicoanatomical Problems** 157
- Multiple Choice Questions** 157

13. Arches of Foot 159

- Introduction 159
- Formation or Structure of Arches 159
 - Medial Longitudinal Arch 159
 - Lateral Longitudinal Arch 160
 - Anterior Transverse Arch 160
 - Posterior Transverse Arch 160
- Factors Responsible for Maintenance of Arches 160
- Functions of Arches 161
- Summary 162
- Clinical Anatomy** 163
- Facts to Remember** 164
- Clinicoanatomical Problem** 164
- Multiple Choice Questions** 164



11. Venous and Lymphatic Drainage, Segmental Innervation, and Comparison of Lower and Upper Limbs 124

- Venous Drainage 124
 - Factors Helping Venous Return 124
- Veins of Lower Limb 124
- Long Saphenous Veins 125
- Small or Short Saphenous Vein 126
- Perforating Veins 126
- Clinical Anatomy** 127
- Lymphatic Drainage 127
 - Classification 128
- Superficial Lymphatics 128
- Deep Lymphatics 129
- Clinical Anatomy** 129
- Segmental Innervation 130
 - Dermatomes 130
 - Myotomes 131
- Clinical Anatomy** 131
- Sympathetic Innervation 131
- Mnemonics** 131
- Facts to Remember** 135
- Clinicoanatomical Problem** 135
- Multiple Choice Questions** 135

12. Joints of Lower Limb 136

- Hip Joint 136
- Dissection** 136
 - Type 136
 - Ligaments 137
 - Relations of the Hip Joint 138
 - Blood Supply 138
 - Nerve Supply 139
 - Movements 139
- Clinical Anatomy** 139
- Knee Joint 140
- Dissection** 140
 - Type 141
 - Ligaments 141
- Synovial Membrane 144
- Dissection** 144
 - Bursae around the Knee 144
- Relations of Knee Joint 144
 - Blood Supply 144
 - Nerve Supply 145
- Movements at the Knee Joint 145
- Dissection** 145
 - Locking and Unlocking of the Knee Joint 146

- Clinical Anatomy** 146
- Ankle Joint 147
- Dissection** 147
 - Ligaments 148
 - Relations of the Ankle Joint 149
 - Movements 149
 - Blood Supply 150
 - Nerve Supply 150

- Clinical Anatomy** 150
- Tibiofibular Joints 150
- Dissection** 150
 - Superior Tibiofibular Joint 150
 - Middle Tibiofibular Joint 150
 - Inferior Tibiofibular Joint 151
- Joints of the Foot 151
- Dissection** 151
 - Talocalcanean Joint 152
 - Movements 152
 - Talocalcaneonavicular Joint 152
 - Movements 152
 - Calcaneocuboid Joint 153
 - Transverse Tarsal or Midtarsal Joint 153
 - Inversion and Eversion of the Foot 153
 - Joints Taking Part 153
 - Muscles Producing Movements 154
- Dissection** 154
 - Joint Cavities of Foot 154
 - Metatarsophalangeal and Interphalangeal Joints 155
- Clinical Anatomy** 155
- Mnemonics** of Locking and Unlocking 156
- Facts to Remember** 157
- Clinicoanatomical Problems** 157
- Multiple Choice Questions** 157

13. Arches of Foot 159

- Introduction 159
- Formation or Structure of Arches 159
 - Medial Longitudinal Arch 159
 - Lateral Longitudinal Arch 160
 - Anterior Transverse Arch 160
 - Posterior Transverse Arch 160
- Factors Responsible for Maintenance of Arches 160
- Functions of Arches 161
- Summary 162
- Clinical Anatomy** 163
- Facts to Remember** 164
- Clinicoanatomical Problem** 164
- Multiple Choice Questions** 164

**14. Surface and Radiological Anatomy**

165

Surface Marking of Arteries	165
Femoral Artery	165
Profunda Femoris Artery	165
Popliteal Artery	165
Superior Gluteal Artery	165
Inferior Gluteal Artery	165
Anterior Tibial Artery	166
Posterior Tibial Artery	166
Dorsalis Pedis Artery	166
Medial Plantar Artery	166
Lateral Plantar Artery	167
Plantar Arch	167
Veins	167
Femoral Vein	167
Great Saphenous Vein	167
Small Saphenous Vein	167
Nerves	168
Femoral Nerve	168
Sciatic Nerve	168
Tibial Nerve	168
Common Peroneal Nerve	168
Deep Peroneal Nerve	168
Superficial Peroneal Nerve	168

Medial Plantar Nerve	169
Lateral Plantar Nerve	168
Miscellaneous Structures	169
Saphenous Opening	169
Femoral Ring	169
Superior Extensor Retinaculum	169
Inferior Extensor Retinaculum	169
Flexor Retinaculum	169
Radiological Anatomy	170
Hip	170
Knee	170
Foot	171

Appendix I

172

Nerves of Lower Limb	172
Femoral Nerve	172
Obturator Nerve	172
Accessory Obturator Nerve	172
Superior Gluteal Nerve	173
Sciatic Nerve	173
Tibial Nerve	173
Clinical Anatomy	175
<i>Clinical Terms</i>	177
Arteries of Lower Limb	178
Multiple Choice Questions	179
Further Reading	180

Section 2 ABDOMEN AND PELVIS**15. Introduction and Osteology**

183

Introduction to Abdomen	183
Osteology	183
Lumbar Vertebrae	183
Clinical Anatomy	186
The Sacrum/Vertebra Magnum	187
Sacral Canal	189
Attachments on the Sacrum	189
Relations of the Sacrum	190
Sex Differences	190
Coccyx	190
Bony Pelvis	191
Sex Differences in the Pelvis	192
Anatomical Position of the Pelvis	193
Intervertebral Joints	193
Intervertebral Disc	193
Mnemonics	194
Facts to Remember	194

Clinicoanatomical Problem	194
Multiple Choice Questions	195

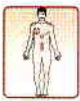16. Anterior Abdominal Wall

196

Surface Landmarks	196
Skin and Superficial Fascia	197
Dissection	197
The Umbilicus	198
Clinical Anatomy	199
Superficial Fascia	199
Clinical Anatomy	200
Cutaneous Nerves	200
Cutaneous Arteries	201
Cutaneous Veins	201
Clinical Anatomy	201
Muscles of the Anterolateral Abdominal Wall	202
Dissection	202



- External Oblique Muscle 202
 Internal Oblique Muscle 203
 Transversus Abdominis Muscle 204
Dissection 204
 Rectus Abdominis Muscle 204
 Actions of the Main Muscles of the Anterior Abdominal Wall 205
 Inguinal Ligament 205
Dissection 206
 Conjoint Tendon or Falx Inguinalis 206
 The Cremaster Muscle 206
Clinical Anatomy 206
 Deep Nerves of the Anterior Abdominal Wall 207
 Deep Arteries of Anterior Abdominal Wall 207
 Rectus Sheath 209
Dissection 209
 The Fascia Transversalis 211
 Inguinal Canal 211
Dissection 211
 Structures Passing through the Canal 212
 Constituents of the Spermatic Cord 212
 Mechanism of Inguinal Canal 213
Clinical Anatomy 214
Mnemonics 217
Facts to Remember 217
Clinicoanatomical Problem 217
Multiple Choice Questions 217
- 17. Male External Genital Organs** 219
- Introduction 219
Dissection 219
 Organs Included 219
 Penis 219
 Root of Penis 219
 Body of Penis 220
 Scrotum 221
Clinical Anatomy 222
 Testis 223
 External Features 223
 Arterial Supply 224
 Histology of Seminiferous Tubule 225
Clinical Anatomy 225
 Epididymis 226
Clinical Anatomy 226
 Testis 226
 Descent of the Testis 226
 Ducts 227
 External Genitalia 227
Facts to Remember 228
Clinicoanatomical Problem 228
Multiple Choice Questions 228
- 18. Abdominal Cavity and Peritoneum** 229
- Nine Regions of Abdomen 229
 Peritoneum 229
 Functions of Peritoneum 231
Clinical Anatomy 232
 Peritoneal Folds 232
Dissection 232
 Greater Omentum 234
Dissection 234
 Lesser Omentum 234
 Mesentery 235
 Mesoappendix 236
 Transverse Mesocolon 236
Dissection 236
 Sigmoid Mesocolon 237
Dissection 237
 Reflection of Peritoneum on the Liver 237
 Vertical Tracing /Sagittal Tracing 238
 Horizontal Tracing above Transverse Colon 238
 Horizontal Tracing below the Level of the Transverse Colon 239
 Horizontal Tracing of Peritoneum in the Lesser Pelvis (Male) 240
 Horizontal Tracing of Peritoneum in the Lesser Pelvis (Female) 240
 Epiploic Foramen/Omental Foramen/Foramen of Winslow 240
 Lesser Sac or Omental Bursa 240
Clinical Anatomy 241
 Special Regions of the Peritoneal Cavity 242
 Supracolic Compartment/Subphrenic Spaces 243
 Hepatorenal Pouch (Morison's Pouch) 243
 Infracolic Compartments 243
 Paracolic Gutters 244
 Rectouterine Pouch (Pouch of Douglas) 244
Clinical Anatomy 244
 Peritoneal Fossae (Recesses) 244
Clinical Anatomy 245
 Development 245
Facts to Remember 246
Clinicoanatomical Problem 246
Multiple Choice Questions 247
- 19. Abdominal Part of Oesophagus and Stomach** 248
- Oesophagces and Stomach 248
Dissection 248
 Abdominal Part of Oesophagus 248



- Histology 249
- Clinical Anatomy** 249
- Stomach 250
 - Location 250
- External Features 250
 - Relations of Stomach 251
 - Blood Supply 252
- Lymphatic Drainage 252
 - Nerve Supply 253
- Interior of Stomach
 - Dissection** 253
 - Clinical Anatomy** 254
 - Histology of Stomach 253
 - Development 255
 - Mnemonics** 255
 - Facts to Remember** 256
 - Clinicoanatomical Problem** 256
 - Multiple Choice Questions** 256
- 20. Small and Large Intestines** 257
 - Small Intestine 257
 - Relevant Features 257
 - Large Surface Area 257
 - Duodenum 259
 - Dissection** 259
 - Peritoneal Relations 259
 - Suspensory Muscle of Duodenum or Ligament of Treitz 262
 - Histology 263
 - Clinical Anatomy** 263
 - Jejunum and Ileum 263
 - Dissection** 263
 - Histology 264
 - Meckel's Diverticulum (Diverticulum Ileii) 265
 - Clinical Anatomy** 265
 - Large Intestine 265
 - Dissection** 265
 - Clinical Anatomy** 267
 - Caecum 267
 - Clinical Anatomy** 269
 - Vermiform Appendix 269
 - Histology 271
 - Clinical Anatomy** 271
 - Ascending Colon 271
 - Right Colic Flexure (Hepatic Flexure) 272
 - Transverse Colon 272
 - Left Colic Flexure (Splenic Flexure) 272
 - Descending Colon 272
 - Sigmoid Colon (Pelvic Colon) 272
 - Histology of Colon 273
- Development 273
- Mnemonics** 273
- Facts to Remember** 273
- Clinicoanatomical Problem** 274
- Multiple Choice Questions** 274
- 21. Large Blood Vessels of the Gut** 275
 - Blood Vessels 275
 - Dissection** 275
 - Coeliac Trunk 275
 - Origin and Length 275
 - Branches 275
 - Superior Mesenteric Artery 277
 - Origin, Course and Termination 277
 - Branches 278
 - Superior Mesenteric Vein 279
 - Clinical Anatomy** 280
 - Inferior Mesenteric Artery 280
 - Branches 280
 - Inferior Mesenteric Vein 281
 - Clinical Anatomy** 281
 - Marginal Artery of Drummond 281
 - Portal Vein 282
 - Branches of Portal Vein 283
 - Tributaries 283
 - Portosystemic Communications (Portocaval Anastomoses) 283
 - Clinical Anatomy** 283
 - Development 284
 - Facts to Remember** 284
 - Clinicoanatomical Problem** 286
 - Multiple Choice Questions** 286
- 22. Extrahepatic Biliary Apparatus** 287
 - Hepatic Ducts 287
 - Dissection** 287
 - Common Hepatic Duct 287
 - Gallbladder 288
 - Cystic Duct 288
 - Bile Duct 289
 - Sphincters Related to the Bile and Pancreatic Ducts 290
 - Nerve Supply 290
 - Clinical Anatomy** 291
 - Histology 292
 - Development 292
 - Facts to Remember** 292
 - Clinicoanatomical Problems** 292
 - Multiple Choice Questions** 293



23. Spleen, Pancreas and Liver

294

- Spleen 294
- Dissection** 204
 - External Features 294
 - Relations 295
 - Arterial Supply 296
 - Venous Drainage 296
 - Lymphatic Drainage 297
- Histology 297
- Development 298
- Clinical Anatomy** 298
- Pancreas 298
- Dissection** 298
 - Head of the Pancreas 299
 - Body of the Pancreas 300
 - Tail of the Pancreas 301
 - Ducts of the Pancreas
 - Arterial Supply 301
 - Venous Drainage 302
 - Lymphatic Drainage 302
 - Histology 302
 - Development 303
 - Clinical Anatomy** 304
- Liver 304
- Dissection** 304
 - External Features 304
 - Five Surfaces 304
 - One Prominent Border 305
 - Visceral Relations 306
 - Blood Supply 307
 - Venous Drainage 307
 - Lymphatic Drainage 307
 - Nerve Supply 307
 - Hepatic Segments 307
 - Histology 308
 - Development 308
 - Clinical Anatomy** 309
 - Mnemonics** 310
 - Facts to Remember** 310
 - Clinicoanatomical Problem** 311
 - Multiple Choice Questions** 311

- Histology 317
- Clinical Anatomy** 317
- Ureters 318
- Dimensions 319
 - Normal Constrictions 320
 - Relations 320
 - Abdominal Part of Ureter 320
 - Pelvic Part of Ureter 321
 - Intravesical Part 321
 - Blood Supply 322
 - Nerve Supply 323
- Histology 323
- Development of Kidney and Ureter 323
 - Anomalies of the Kidney and Ureter 323
- Clinical Anatomy** 328
- Mnemonics** 323
- Facts to Remember** 325
- Clinicoanatomical Problem** 325
- Multiple Choice Questions** 325

25. Suprarenal Gland and Chromaffin System

326

- Suprarenal Glands 326
- Dissection** 326
 - Right Suprarenal Gland 326
 - Left Suprarenal Gland 327
 - Structure and Function 327
 - Arterial Supply 328
 - Venous Drainage 328
 - Lymphatic Drainage 328
 - Nerve Supply 328
- Histology 328
- Development of Suprarenal Gland 329
- Chromaffin System 329
- Clinical Anatomy** 329
- Facts to Remember** 330
- Clinicoanatomical Problem** 330
- Multiple Choice Questions** 330

24. Kidney and Ureter

312

- Kidneys 312
- Dissection** 312
 - Hilum 313
- Relations of the Kidneys 313
- Capsules or Coverings of Kidney 314
 - Blood Supply of Kidney 316
 - Lymphatic Drainage 316
 - Nerve Supply 316
- Exposure of the Kidney from Behind 316

26. Diaphragm

331

- Gross Anatomy 331
- Dissection** 331
- Openings in the Diaphragm 333
 - Relations 333
 - Nerve Supply 333
 - Actions 334
- Development 334
- Clinical Anatomy** 334
- Mnemonics** 335



Facts to Remember 335

Clinicoanatomical Problem 335

Multiple Choice Questions 336

27. Posterior Abdominal Wall 337

Introduction 337

Blood Vessels, Muscles and Nerves 337

Dissection 337

Abdominal Aorta 337

Relations 337

Branches 338

Common Iliac Arteries 339

Inferior Vena Cava 339

Tributaries 339

Clinical Anatomy 340

Abdominal Parts of Azygos and Hemiazygos Veins 340

Lymph Nodes of Posterior Abdominal Wall 340

Cisterna Chyli 341

Muscles of the Posterior Abdominal Wall 341

Clinical Anatomy 342

Thoracolumbar Fascia (Lumbar Fascia) 343

Nerves of the Posterior Abdominal Wall 343

Abdominal Part of the Autonomic Nervous System 344

Lumbar Sympathetic Chain 344

Coeliac Ganglia and Coeliac Plexus 344

Layers of the Abdomen 346

Clinical Anatomy 348

Mnemonics 348

Facts to Remember 348

Clinicoanatomical Problem 348

Multiple Choice Questions 349

28. Perineum 350

Superficial Boundaries 350

Deep Boundaries of the Perineum 350

Divisions of the Perineum 350

Anal Region 351

Dissection 351

Perineal Body 352

External Anal Sphincter 352

Ischioanal Fossa 352

Spaces and Canals of the Fossa 353

Contents of Ischioanal Fossa 354

Clinical Anatomy 354

Male Perineum 354

Dissection 354

Male Urogenital Region 355

Clinical Anatomy 355

Deep Perineal Space 355

Boundaries 356

Deep Transverse Perineal 356

Distal Urethral Sphincter Mechanism 357

Perineal Membrane 357

Clinical Anatomy 357

Female Perineum 358

Female External Genital Organs/Pudendum/Vulva 358

Female Urogenital Region 359

Clinical Anatomy 359

Deep Perineal Space 360

Boundaries 360

Contents 360

Urethral Sphincter Mechanism 360

Action 360

Nerve Supply 360

Compressor Urethrae 361

Sphincter Urethrovaginalis 361

Actions 361

Perineal Spaces/Pouches 361

Pudendal Canal 362

Pudendal Nerve 363

Clinical Anatomy 364

Internal Pudendal Artery 364

Internal Pudendal Vein 365

Histology of Body of Penis/Clitoris 365

Facts to Remember 366

Clinicoanatomical Problem 366

Multiple Choice Questions 366

29. Preliminary Consideration of Boundaries and Contents of Pelvis 367

Lesser Pelvis 367

Muscles 367

Pelvic Inlet: Superior Aperture of Pelvis 367

Pelvic Outlet: Inferior Aperture of Pelvis 368

Clinical Anatomy 369

Pelvic Floor 369

Clinical Anatomy 369

Pelvic Cavity 370

Contents 370

Structures Crossing the Pelvic Inlet/Brim of the Pelvis 370

Facts to Remember 371

Clinicoanatomical Problem 371

Multiple Choice Questions 371



30. Urinary Bladder and Urethra

372

- Introduction 372
- Dissection** 372
- Urinary Bladder 372
 - External Features 372
 - Relations 373
 - Ligaments of the Bladder 374
 - Interior of the Bladder 374
- Clinical Anatomy** 375
 - Arterial Supply 375
 - Venous Drainage 375
 - Lymphatic Drainage 375
 - Nerve Supply 375
- Clinical Anatomy** 375
- Male Urethra 376
 - Posterior Part 377
 - Anterior Part 378
- Clinical Anatomy** 378
- Female Urethra 379
 - Arteries 379
 - Veins 379
 - Lymphatic 379
 - Innervation 379
 - Walls of Urethra 379
- Micturition 380
- Histology of Urinary Bladder 380
- Development of Urinary Bladder and Urethra 380
- Clinical Anatomy** 380
- Facts to Remember** 381
- Clinicoanatomical Problem** 381
- Multiple Choice Questions** 381

31. Female Reproductive Organs

382

- Internal Genital Organs 382
- Dissection** 382
- Ovaries 382
- External Features 383
 - Relations 383
 - Arterial Supply 384
 - Venous Drainage 384
- Histology 384
- Clinical Anatomy** 384
- Uterine Tubes 385
 - Course and Relations 385
 - Blood Supply 385
 - Lymphatic Drainage 385
 - Nerve Supply 386

Histology 386

Clinical Anatomy 386

Uterus 387

- Size and Shape 387
- Normal Position and Angulation 387
- Parts of Uterus 387
- Cervix of Uterus 387
- Ligaments of Uterus 389
- Arterial Supply 389
- Venous Drainage 389
- Lymphatic Drainage 390
- Nerve Supply 390
- Age and Reproductive Changes 390
- Supports of the Uterus 390
- Role of Individual Supports 390

Histology 392

Clinical Anatomy 392

Vagina 392

- Extent and Situation 393
- Fornices of Vagina 393
- Relations 393
- Arterial Supply 394
- Venous Drainage 394
- Lymphatic Drainage 394
- Nerve Supply 394
- Ureter in Female Pelvis 394

Histology 395

Clinical Anatomy 395

Development 395

Mnemonics 397**Facts to Remember** 397**Clinicoanatomical Problem** 397**Multiple Choice Questions** 398

32. Male Reproductive Organs

399

- Introduction 399
- Dissection** 399
- Ductus Deferens 399
 - Course and Relations 399
 - Arterial Supply 400
 - Venous Drainage 400
- Histology 400
- Development 400
- Clinical Anatomy** 400
- Seminal Vesicles 401
- Prostate 401
 - Situation 401
 - Gross Features 401
 - Zones of the Prostate 402
 - Capsules and Ligaments of Prostate 402
 - Structures within the Prostate 402
 - Structural Zones of the Prostate 402



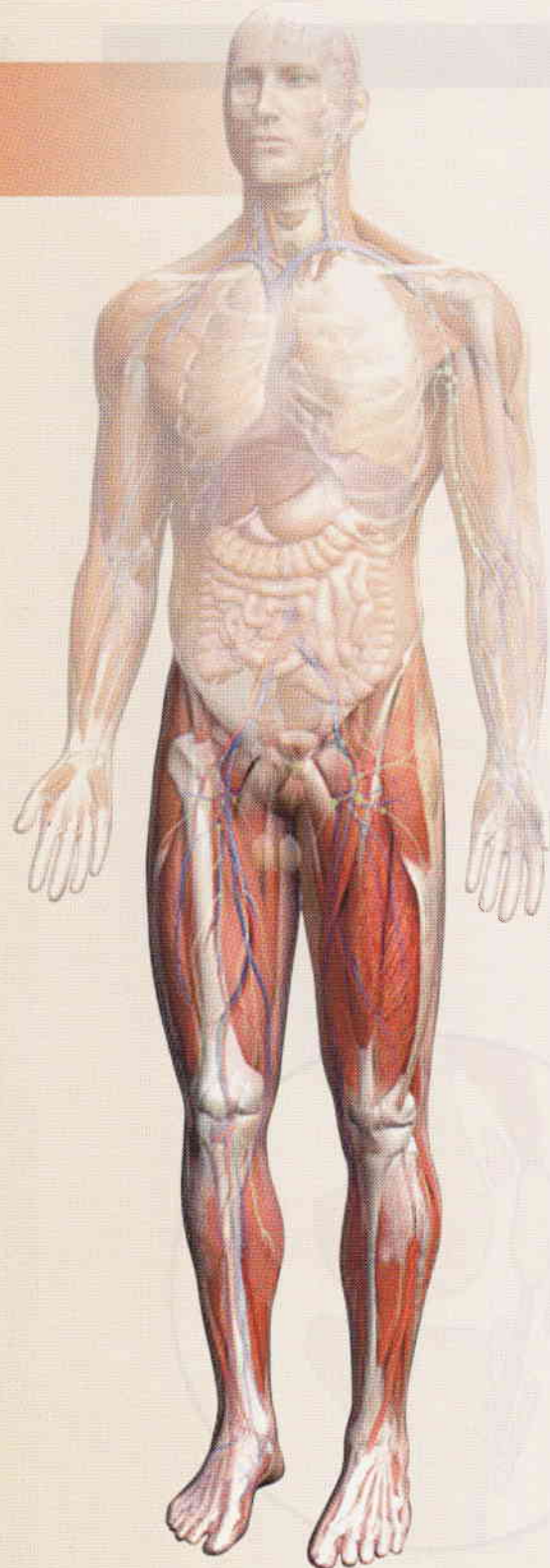- Blood Supply 402
 - Lymphatic Drainage 403
 - Nerve Supply 403
 - Age Changes in Prostate 404
 - Histology 404
 - Development 404
 - Clinical Anatomy 404
 - Vertebral System of Veins 405
 - Communications and Implications 405
 - Facts to Remember 405
 - Clinicoanatomical Problems 406
 - Multiple Choice Questions 406
- 33. Rectum and Anal Canal** 407
- Rectum 407
 - Dissection 407
 - Situation 407
 - Dimensions 407
 - Relations 408
 - Mucosal Folds 409
 - Arterial Supply 410
 - Venous Drainage 410
 - Lymphatic Drainage 411
 - Nerve Supply 411
 - Supports of Rectum 411
 - Clinical Anatomy 412
 - Anal Canal 413
 - Dissection 413
 - Situation 413
 - Length, Extent and Direction 413
 - Relations of the Anal Canal 413
 - Interior of the Anal Canal 413
 - Musculature of the Anal Canal 414
 - Anorectal Ring 415
 - Surgical Spaces Related to the Anal Canal 415
 - Arterial Supply 415
 - Venous Drainage 415
 - Lymphatic Drainage 416
 - Nerve Supply 416
 - Histology 416
 - Development 416
 - Clinical Anatomy 416
 - Facts to Remember 417
 - Clinicoanatomical Problem 417
 - Multiple Choice Questions 418
- 34. Walls of Pelvis** 419
- Vessels of the Pelvis 419
 - Dissection 419
 - Internal Iliac Artery 419
 - Course 419
 - Relations 419
 - Branches 419
 - Branches of Anterior Division 419
 - Branches of Posterior Division 420
 - Internal Iliac Vein 421
 - Lymph Nodes of the Pelvis 422
 - Nerves of the Pelvis 422
 - Dissection 422
 - Lumbosacral Plexus 422
 - Branches from Dorsal Divisions 423
 - Branches from Ventral Division 423
 - Coccygeal Plexus 423
 - Clinical Anatomy 423
 - Pelvic Autonomic Nerves 423
 - Pelvic Sympathetic System 423
 - Pelvic Splanchnic Nerves 423
 - Pelvic Fascia and Muscles 423
 - Pelvic Muscles 424
 - Dissection 424
 - The Levator Ani 425
 - Pubococcygeus Part 425
 - Iliococcygeus Part 425
 - Coccygeus 425
 - Nerve Supply 426
 - Actions of Levators Ani and Coccygeus 426
 - Relations of the Levator Ani 426
 - Clinical Anatomy 426
 - Joints of Pelvis 426
 - Dissection 426
 - Lumbosacral Joints 426
 - Sacrococcygeal and Intercoccygeal Joints 427
 - Sacroiliac Joint 427
 - Ligaments 427
 - Factors Providing Stability 429
 - Blood Supply 429
 - Nerve Supply 429
 - Movements 429
 - Pubic Symphysis 429
 - The Mechanism of Pelvis 429
 - Clinical Anatomy 429
 - Facts to Remember 430
 - Clinicoanatomical Problem 430
 - Multiple Choice Questions 430
- 35. Surface Marking of Abdomen and Pelvis** 431
- Planes and Regions of the Abdomen 431
 - Viscera 431



Spleen	431	
Stomach	431	
Duodenum	432	
Caecum	432	
Ileocaecal Orifice or Valve	432	
Appendix	432	
Ascending Colon	432	
Transverse Colon	433	
Descending Colon	433	
Rectum and Anal Canal	433	
Liver	433	
Gallbladder	433	
Bile Duct	433	
Pancreas	433	
Kidney	433	
Ureter	434	
Vessels	434	
Abdominal Aorta	434	
Common Iliac Artery	434	
External Iliac Artery	434	
Coeliac Trunk and its Branches	434	
Superior Mesenteric Artery	434	
Inferior Mesenteric Artery	435	
Inferior Vena Cava	435	
Portal Vein	435	
Miscellaneous	435	
Inguinal Canal	435	
Root of Mesentery	435	
36. Radiological and Imaging Procedures		436
Plain Skiagram of Abdomen	436	
Alimentary Canal: Barium Studies	437	
Barium Meal Examination	437	
Barium Enema	438	
Excretory (Intravenous or Descending) Pyelography	438	
Retrograde (Instrumental or Ascending) Pyelography	439	
Biliary Apparatus	439	
Hysterosalpingography	440	
Foetogram	440	
Appendix 2		441
Lower Intercostal Nerves	441	
Upper Lumbar Nerves	441	
Lumbar Plexus	441	
Sacral Plexus	442	
Pudendal Nerve	442	
Abdominal Part of Sympathetic Trunk	442	
Aortic Plexus	442	
Pelvic Part of Sympathetic Trunk	442	
Collateral or Prevertebral Ganglia and Plexuses	443	
Coeliac Plexus	443	
Gastrointestinal Tract	443	
Genitourinary Tract	444	
Clinical Anatomy	445	
Clinical Terms	448	
Multiple Choice Questions	450	
Further Reading	452	
Spots on Lower Limb	453	
Answers	456	
Spots on Abdomen and Pelvis	455	
Answers	456	
Index		457

Lower Limb

1. Introduction	3
2. Bones of Lower Limb	6
3. Front of Thigh	40
4. Medial Side of Thigh	59
5. Gluteal Region	65
6. Popliteal Fossa	76
7. Back of Thigh	83
8. Front, Lateral and Medial Sides of Leg and Dorsum of Foot	90
9. Back of Leg	103
10. Sole of Foot	113
11. Venous and Lymphatic Drainage, Segmental Innervation, and Comparison of Lower and Upper Limbs	124
12. Joints of Lower Limb	136
13. Arches of Foot	159
14. Surface and Radiological Anatomy	165
Appendix 1	172





Introduction

Arise, awake and stop not till the goal is reached
—Swami Vivekanand

The lower limb in its basic structure is similar to the upper limb because both of them formerly (as in animals) were used for locomotion. Each limb has a girdle, hip girdle for lower limb or shoulder girdle for upper limb, by which it is attached to the axial skeleton. The girdle supports three main segments of the limb, a proximal thigh or arm, a middle leg or forearm and a distal foot or hand. The similarity between the two limbs is not only outward, but to a great extent it is also found in the bones, joints, muscles, vessels, nerves and lymphatics.

However, with the evolution of erect or plantigrade posture in man, the two limbs despite their basic similarities have become specialized in different directions to meet the new functional needs. The emancipated upper limb is specialized for prehension and free mobility whereas the lower limb is specialized for support and locomotion. In general, the lower limbs attain stability at the cost of some mobility, and the upper limbs attain freedom of mobility at the cost of some stability. Thus the lower limbs are bulkier and stronger than the upper limbs (Fig. 1.1). A few of the distinguishing features of the lower limbs are listed below.

- 1 During early stages of development, the lower limb buds rotate medially through 90 degrees, so that their preaxial or tibial border faces medially and the extensor surface forwards (Fig. 1.2). The upper limb buds, on the other hand, rotate laterally through 90 degrees, so that their preaxial or radial border faces laterally and the extensor surface backwards (Fig. 1.1).
- 2 The antigravity muscles in the lower limb are much better developed than in the upper limb because they have to lift the whole body up during attaining the erect posture and also in walking up the staircase. These muscles are the gluteus maximus, extensor of

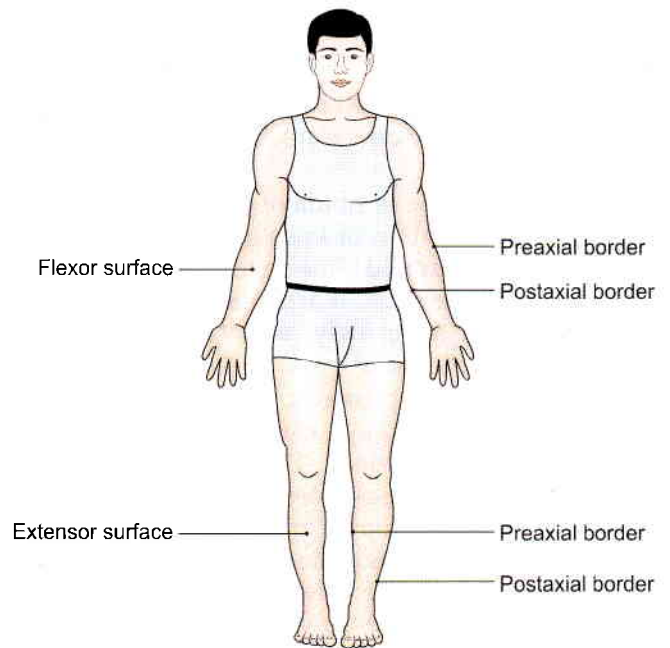


Fig. 1.1: Bulkier and stronger lower limbs

hip; the quadriceps femoris, extensor of knee and the gastrocnemius and soleus, plantar flexors of ankle at the back of leg. They have an extensive origin and a large, bulky, fleshy belly.

- 3 The distal end or insertion of the muscles of lower limb moves only when feet are off the ground; this is known as the action from above. But when feet are supporting the body weight, the muscles act in reverse from below, i.e. the proximal end or origin moves towards the distal end or insertion. This is typically seen while rising up from a sitting posture, and in going upstairs. Maintenance of posture in erect attitude, both at rest and in walking, running, etc. also involves the reverse action when the

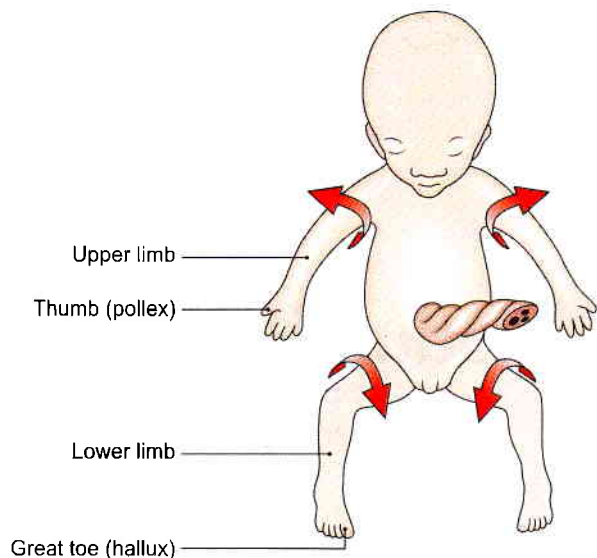


Fig. 1.2: Rotations of limb buds

antagonist muscles must balance against each other. Reverse muscular actions are far less common in the upper limb.

- 4 The postaxial bone or fibula of the leg does not take part in the formation of knee joint. Patella or knee cap is a large sesamoid bone developed in the tendon of quadriceps femoris. It articulates with the lower end of femur anteriorly, and takes part in the formation of knee joint.
- 5 The foot in lower primates is a prehensile organ. The apes and monkeys can very well grasp the boughs with their feet. Their great toe can be opposed over the lesser toes. In man, however, the foot has changed from a grasping to a supporting organ. In fact, foot has undergone maximum change during evolution. The great toe comes in line with the other toes, loses its power of opposition, and is greatly enlarged to become the principal support of the body (Fig. 1.1). The four lesser toes, with the loss of prehensile function, have become vestigial and reduced in size. The tarsal bones become large, strong and wedge-shaped, which contribute to the stable support on one hand, and form the elastic arches of the foot on the other hand. The small and insignificant heel of the grasping primate foot becomes greatly enlarged and elongated to which is attached the tendocalcaneus that can lift the heel in walking. The bony alterations are associated with numerous ligamentous and muscular modifications which aim at the maintenance of the arches of foot.
- 6 Certain diseases, like varicose veins and Buerger's disease, occur specifically in the lower limb. The developmental deformities of the foot like talipes equinovarus are more common than those of the hand.

PARTS OF THE LOWER LIMB

The parts of the lower limb are shown in Table 1.1.

Table 1.1: Parts of the lower limb

Parts	Bones	Joints
1. Gluteal region, covers the side and back of the pelvis	• Hip bone	• Hip joint
2. Thigh, from hip to knee	• Femur • Patella	• Knee joint
3. Leg or crus, from knee to ankle	• Tibia • Fibula	• Tibiofibular joints
4. Foot or pes, from heel to toes	• Tarsus, made up of 7 tarsal bones • Metatarsus, made up of 5 metatarsals • 14 phalanges, two for great toe, and three for each of the four toes	• Ankle joint • Subtalar and transverse tarsal (TT) joints • Tarsometatarsal (TM) joints • Intermetatarsal (IM) joints • Metatarsophalangeal (MP) joints • Interphalangeal (IP) joints

Related Terms

- 1 The *hip bone* is made up of three elements, ilium, pubis and ischium, which are fused at the acetabulum. Two hip bones form the *hip girdle* which articulates posteriorly with the sacrum at the sacroiliac joints. The bony *pelvis* includes the two hip bones, a sacrum and a coccyx. *Hip joint* is an articulation between the hip bone and femur.
- 2 The *gluteal region*, overlying the side and back of the pelvis, includes the hip and the buttock which are not sharply distinguished from each other. *Hip* or *coxa* is the superolateral part of the gluteal region presented in a side view, while the *buttock* or *natis* is the inferomedial rounded bulge of the region presented in a back view.
- 3 The junction of thigh and anterior abdominal wall is indicated by the groove of groin or inguinal region. The *gluteal fold* is the upper limit of the thigh posteriorly.
- 4 *Ham* or *poples* is the lower part of the back of thigh and the back of the knee.
- 5 *Calf* or *sura* is the soft, bulky posterior part of the leg. The bony prominences, one on each side of the ankle, are called the *malleoli*. These are formed by the lower ends of tibia and fibula.

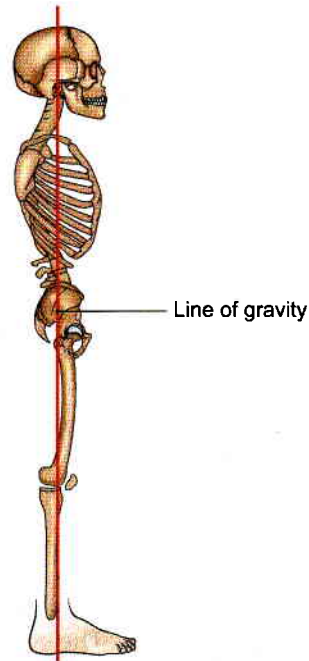
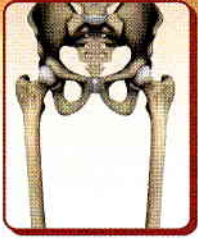


Fig. 1.3: The line of gravity

6 The foot or *pes* has an upper surface, called the *dorsal surface*, and a lower surface, called the *sole* or *plantar surface*. Sole is homologous with the palm of the hand.

The line of gravity passes through cervical and lumbar vertebrae. In the lower limbs, it passes behind the hip joint and in front of knee and ankle joints (Fig. 1.3).

2



Bones of Lower Limb

Do instead of dream, move instead of meditate, work instead of wish
—Swami Vivekanand

INTRODUCTION

Various bones of the lower limb have been enumerated in the previous chapter. The bones are described one by one below. The description of each bone is given in two parts. The first part introduces the main features and the second part describes the muscular and ligamentous attachments.

HIP BONE

Hip/innominate bone is a large irregular bone. It is made up of three parts. These are the *ilium* (Latin *loin*) superiorly, the *pubis* (Latin *genital area*) anteroinferiorly, and the *ischium* (Greek *hip joint*) posteroinferiorly. The three parts are joined to each other at a cup-shaped hollow, called the *acetabulum* (Latin *vinegar cup*). The pubis and ischium are separated by a large oval opening called the *obturator foramen*.

The acetabulum articulates with the head of the femur to form the *hip joint*. The pubic parts of the two hip bones meet anteriorly to form the *pubic symphysis*. The two hip bones form the *pelvic* or hip girdle. The bony pelvis is formed by the two hip bones along with the sacrum and coccyx.

Side Determination

- 1 The acetabulum is directed laterally.
- 2 The flat, expanded ilium forms the upper part of the bone, that lies above the acetabulum.
- 3 The obturator foramen lies below the acetabulum. It is bounded anteriorly by the thin pubis, and posteriorly by the thick and strong ischium.

Anatomical Position

- 1 The pubic symphysis and anterior superior iliac spine lie in the same coronal plane.

- 2 The pelvic surface of the body of the pubis is directed backwards and upwards.
- 3 The symphyseal surface of the body of the pubis lies in the median plane.

ILIUM

The ilium or *flank* forms the upper expanded plate like part of the hip bone. Its lower part forms the upper two-fifths of the acetabulum. The ilium has the following:

- 1 An upper end which is called the iliac crest.
- 2 A lower end which is smaller, and is fused with the pubis and the ischium at the acetabulum. The ilium forms the upper two-fifths of the acetabulum.
- 3 Three borders—anterior, posterior and medial.
- 4 Three surfaces—gluteal surface, iliac surface or iliac fossa, and a sacropelvic surface.

Iliac Crest

The iliac crest (Figs 2.1 to 2.3) is a broad convex ridge forming the upper end of the ilium. It can be felt in the living at the lower limit of the flank.

Curvatures: Vertically it is convex upwards, antero-posteriorly, it is concave inwards in front and concave outwards behind (Fig. 2.1).

The highest point of the iliac crest is situated a little behind the midpoint of the crest. It lies at the level of the interval between the spines of vertebrae L3 and L4.

Ends: The anterior end of the iliac crest is called the *anterior superior iliac spine* (ASIS). This is a prominent landmark that is easily felt in the living. The posterior end of the crest is called the *posterior superior iliac spine*. Its position on the surface of the body is marked by a *dimple* 5 cm lateral of the second sacral spine (S2) (see Fig. 5.1).

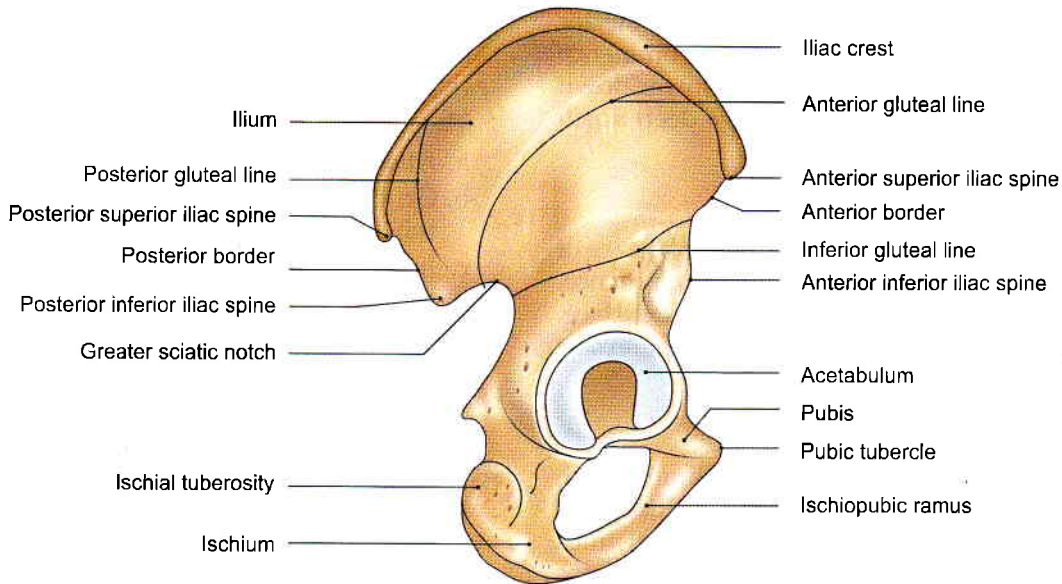


Fig. 2.1: Outer surface of right hip bone

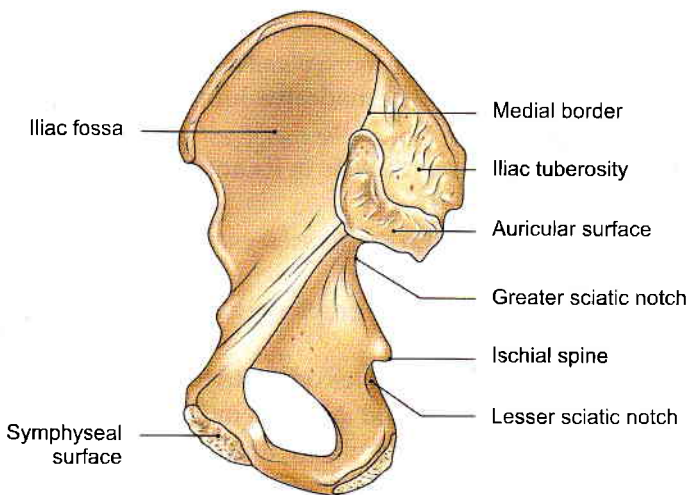


Fig. 2.2: Inner surface of right hip bone

Morphological divisions: Morphologically, the iliac crest is divided into a long *ventral segment* and a short *dorsal segment*.

The ventral segment forms more than the anterior two-thirds of the crest. It has an outer lip, an inner lip, and an intermediate area. The tubercle of the iliac crest is an elevation that lies on the outer lip about 5 cm behind the anterior superior iliac spine (Fig. 2.3).

The dorsal segment forms less than the posterior one-third of the crest. It has a lateral and a medial slope separated by a ridge.

Anterior Border of Ilium

Anterior border starts at the *anterior superior iliac spine* and runs downwards to the acetabulum. The upper part

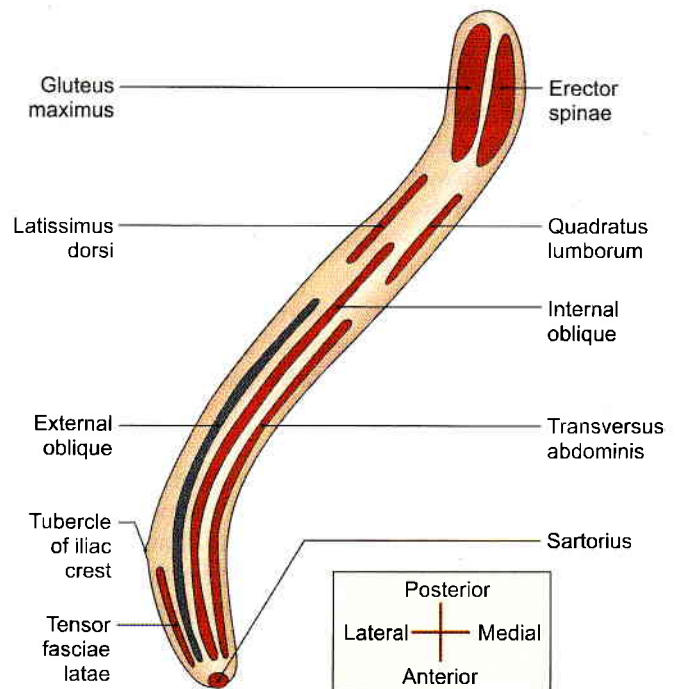


Fig. 2.3: Scheme to show the attachments on the right iliac crest (as seen from above)

of the border presents a notch, while its lower part shows an elevated area called the *anterior inferior iliac spine*. The lower half of this spine is large, triangular and rough.

Posterior Border of Ilium

Posterior border extends from the *posterior superior iliac spine* to the upper end of the posterior border of



the ischium. A few centimetres below the posterior superior iliac spine it presents another prominence called the *posterior inferior iliac spine*. Still lower down the posterior border is marked by a large deep notch called the *greater sciatic notch*.

Medial Border

Medial border extends on the inner or pelvic surface of the ilium from the iliac crest to the iliopubic eminence. It separates the iliac fossa from the sacropelvic surface. Its lower rounded part forms the iliac parts of the *arcuate line* or inlet of pelvis.

Gluteal Surface

Gluteal surface is the outer surface of the ilium, which is convex in front and concave behind, like the iliac crest. It is divided into four areas by three gluteal lines (Fig. 2.1). The *posterior gluteal line*, the shortest, begins 5 cm in front of the posterior superior iliac spine, and runs downwards to end at upper part of greater sciatic notch. The *anterior gluteal line*, the longest, begins about 4 cm behind the anterior superior iliac spine, runs backwards and then downwards to end at the middle of the upper border of the greater sciatic notch. The *inferior gluteal line*, the most ill-defined, begins a little above and behind the anterior inferior spine, runs backwards and downwards to end near the apex of the greater sciatic notch.

Iliac Fossa

Iliac fossa is the large concave area on the inner surface of the ilium, situated in front of its medial border. It forms the lateral wall of the false pelvis (Fig. 2.2).

Sacropelvic Surface

Sacropelvic surface is the uneven area on the inner surface of the ilium, situated behind its medial border. It is subdivided into three parts; the iliac tuberosity, the auricular surface and the pelvic surface. The *iliac tuberosity* is the upper, large, roughened area, lying just below the dorsal segment of the iliac crest. It is raised in the middle and depressed both above and below. The *auricular surface* is articular but pitted. It lies anteroinferior to the iliac tuberosity. It articulates with the sacrum to form the sacroiliac joint. The *pelvic surface* is smooth and lies anteroinferior to the auricular surface. It forms a part of the lateral wall of the true pelvis. Along the upper border of the greater sciatic notch, this surface is marked by the *preauricular sulcus*. This sulcus is deeper in females than in males.

Attachments on the Ilium

1 The *anterior superior iliac spine* gives attachment to the lateral end of the inguinal ligament. It also gives

origin to the *sartorius* muscle; the origin extends onto the upper half of the notch below the spine (Figs 2.3 and 2.4).

- 2 The *outer lip of the iliac crest* provides:
 - a. Attachment to the *fascia lata* in its whole extent.
 - b. Origin to the *tensor fasciae latae* in front of the tubercle.
 - c. Insertion to the *external oblique muscle* in its anterior two-thirds.
 - d. Origin to the *latissimus dorsi* just behind the highest point of the crest. The tubercle of the crest gives attachment to the *iliotibial tract* (Figs 2.3 and 3.8).
- 3 The *inner lip of the iliac crest* provides:
 - a. Origin to the *transversus abdominis* in its anterior two-thirds (Fig. 2.3).
 - b. Attachment to the *fascia transversalis* and to the *fascia iliaca* in its anterior two-thirds, deep to the attachment of the transversus abdominis.
 - c. Origin to the *quadratus lumborum* in its posterior one-third (Fig. 2.3).
 - d. Attachment to the *thoracolumbar fascia* around the attachment of the quadratus lumborum.
- 4 The *intermediate area of the iliac crest* gives origin to the *internal oblique* muscle in its anterior two-thirds (Figs 2.3 and 2.4).
- 5 The attachments on the *dorsal segment of the iliac crest* are as follows.
 - a. The lateral slope gives origin to the *gluteus maximus* (Fig. 2.3).
 - b. The medial slope gives origin to the *erector spinae*.
 - c. The *interosseous* and *dorsal sacroiliac ligaments* are attached to the medial margin deep to the attachment of the *erector spinae* (Fig. 2.5).
- 6 The upper half of the *anterior inferior iliac spine* gives origin to the *straight head of the rectus femoris*. The rough lower part of this spine gives attachment to the *iliofemoral ligament* (Figs 2.4 and 2.14).
- 7 The *posterior border of the ilium* provides:
 - a. Attachment to upper fibres of the *sacrospinous ligament* above the greater sciatic notch.
 - b. Origin to few fibres of the *piriformis* from upper margin of the greater sciatic notch.
- 8 The attachments on the *gluteal surface* are as follows.
 - a. The area behind the posterior gluteal line gives origin to upper fibres of the *gluteus maximus* (Fig. 2.4).
 - b. The *gluteus medius* arises from the area between the anterior and posterior gluteal lines (Fig. 2.4).
 - c. The *gluteus minimus* arises from the area between the anterior and inferior gluteal lines (Fig. 2.4).

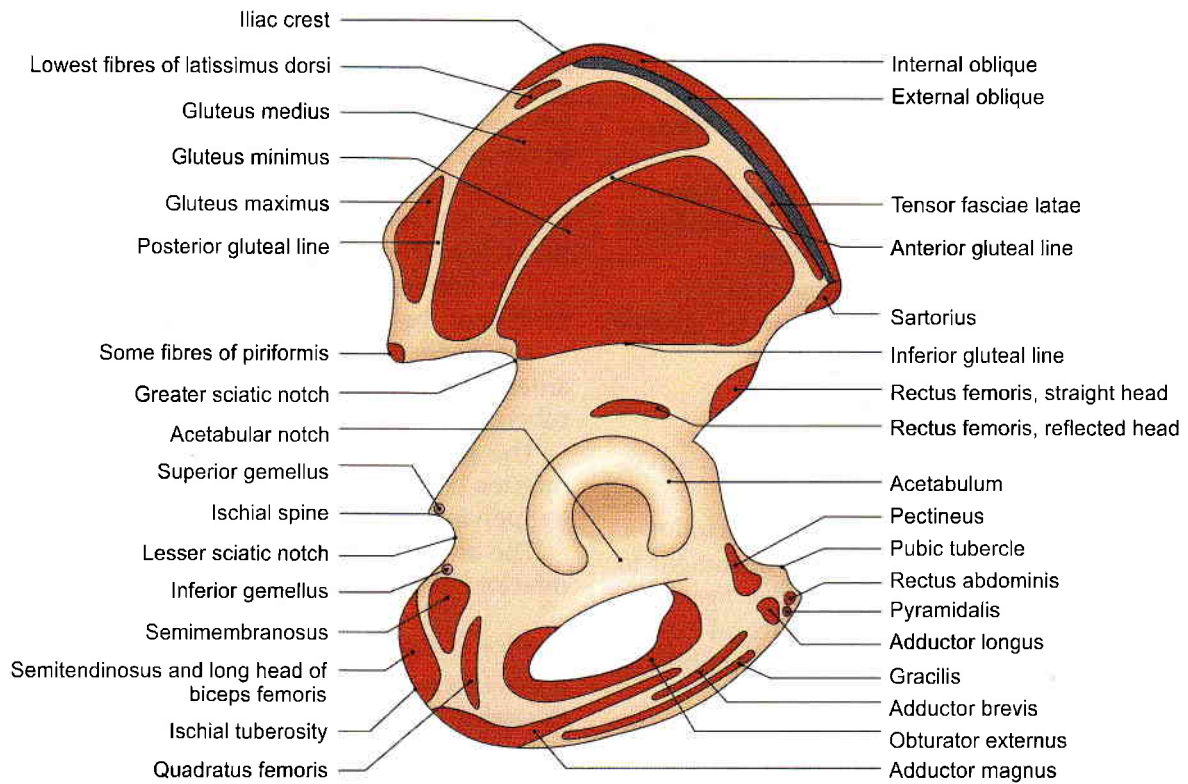


Fig. 2.4: Attachments on the outer surface of the right hip bone

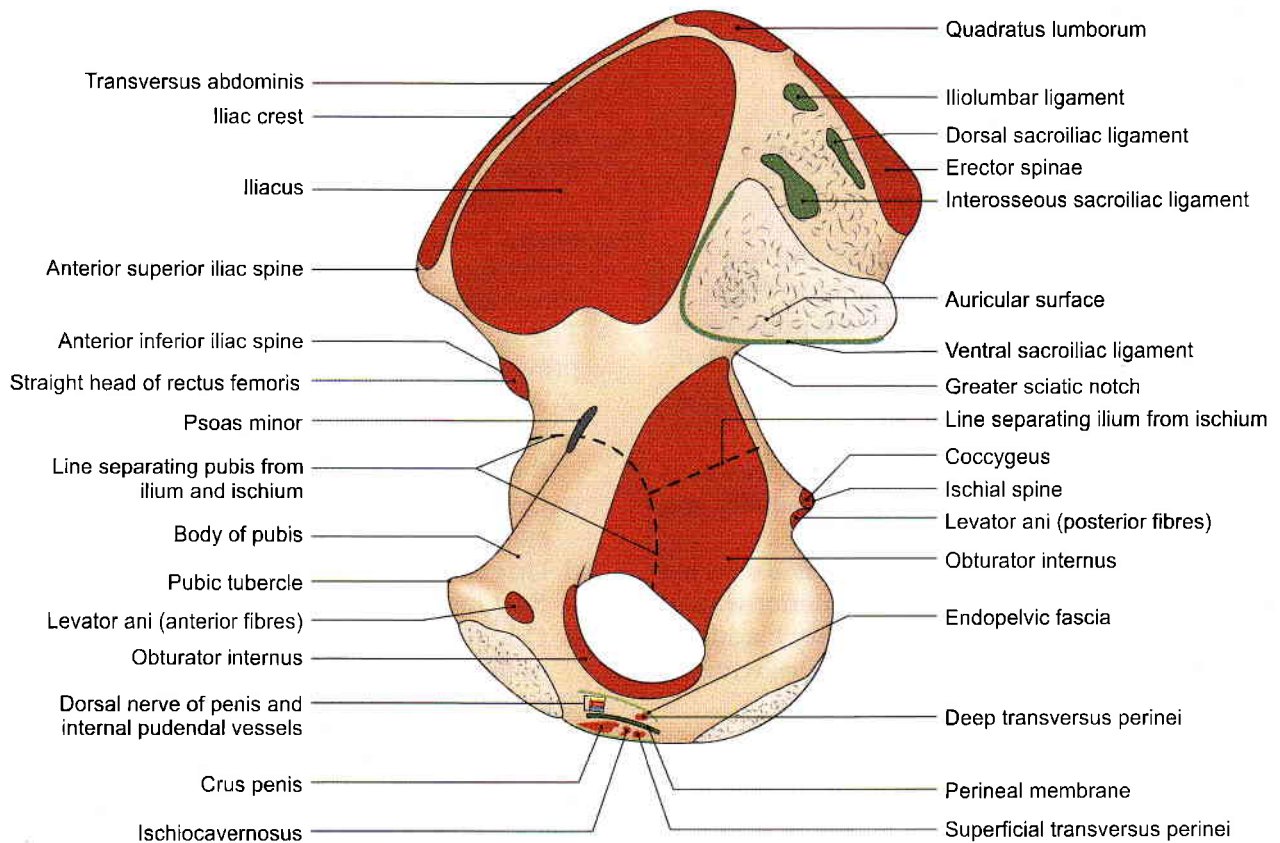
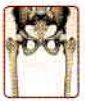

Fig. 2.5: Attachments of the inner surface of the right hip bone



- d. Below the inferior gluteal line, the *reflected head of the rectus femoris* arises from the groove above the acetabulum (Fig. 2.4).
- e. The *capsular ligament of the hip joint* is attached along the margin of acetabulum.
- 9 The iliac fossa gives origin to the *iliacus* from its upper two-thirds (Fig. 2.5). The lower grooved part of the fossa is covered by the iliac bursa.
- 10 The *iliac tuberosity* provides attachment to:
 - a. The *interosseous sacroiliac ligament* in its greater part (Fig. 2.5).
 - b. The *dorsal sacroiliac ligament* posteriorly.
 - c. The *iliolumbar ligament* superiorly.
- 11 The convex margin of the *auricular surface* gives attachment to *ventral sacroiliac ligament*.
- 12 The attachments on the pelvic surface are as follows.
 - a. The preauricular sulcus provides attachment to the lower fibres of the *ventral sacroiliac ligament*.
 - b. The part of the pelvic surface lateral to the preauricular sulcus gives origin to a few fibres of the *piriformis*.
 - c. The rest of the pelvic surface gives origin to the upper half of the *obturator internus* (Fig. 2.5).

PUBIS

It forms the anteroinferior part of the hip bone and the anterior one-fifth of the acetabulum, forms the anterior boundary of the obturator foramen. It has:

- a. A *body* anteriorly.
- b. A *superior ramus* superolaterally.
- c. An *inferior ramus* inferolaterally (Figs 2.1 and 2.2).

Body of Pubis

This is flattened from before backwards, and has:

- 1 A superior border called the *pubic crest*.
- 2 A *pubic tubercle* at the lateral end of the pubic crest.
- 3 Three surfaces, viz. anterior, posterior and medial.

The *pubic tubercle* is the lateral end of the pubic crest, forming an important landmark (Fig. 2.5).

The *anterior surface* is directed downwards, forwards and slightly laterally. It is rough superomedially and smooth elsewhere.

The *posterior or pelvic surface* is smooth. It is directed upwards and backwards. It forms the anterior wall of the true pelvis, and is related to the urinary bladder.

The *medial or symphyseal surface* articulates with the opposite pubis to form the pubic symphysis.

Superior Ramus

It extends from the body of the pubis to the acetabulum, above the obturator foramen. It has three borders and three surfaces.

The superior border is called the *pectineal line* or *pecten pubis*. It is a sharp crest extending from just behind the pubic tubercle to the posterior part of the iliopubic eminence. With the pubic crest it forms the pubic part of the arcuate line.

The anterior border is called the *obturator crest*. The border is a rounded ridge, extending from the pubic tubercle to the acetabular notch.

The *inferior border* is sharp and forms the upper margin of the obturator foramen.

The *pectineal surface* is a triangular area between the anterior and superior borders, extending from the pubic tubercle to the iliopubic eminence.

The *pelvic surface* lies between the superior and inferior borders. It is smooth and is continuous with the pelvic surface of the body of the pubis.

The *obturator surface* lies between the anterior and inferior borders. It presents the obturator groove.

Inferior Ramus

It extends from the body of the pubis to the ramus of the ischium, medial to the obturator foramen. It unites with the ramus of the ischium to form the conjoined ischiopubic rami. For convenience of description, the conjoined rami will be considered together at the end. (refer to 8).

Attachments and Relations of the Pubis

- 1 The *pubic tubercle* provides attachment to the *medial end of the inguinal ligament* and to *ascending loops of the cremaster muscle*. In males, the tubercle is crossed by the spermatic cord.
- 2 The medial part of the *pubic crest* is crossed by the medial head of the *rectus abdominis*. The lateral part of the crest gives origin to the lateral head of the *rectus abdominis*, and to the *pyramidalis* (Fig. 2.4).
- 3 The anterior surface of the body of the pubis provides:
 - a. Attachment to the *anterior pubic ligament* medially.
 - b. Origin to the *adductor longus* in the angle between the crest and the symphysis.
 - c. Origin to the *gracilis*, from the margin of symphysis, and from the inferior ramus.
 - d. Origin to the *adductor brevis* lateral to the origin of the *gracilis* (Fig. 2.4).
 - e. Origin to the *obturator externus* near the margin of the obturator foramen (see Fig. 4.1).
- 4 The *posterior surface* of the body of the pubis provides:
 - a. Origin to the *levator ani* from its middle part (Fig. 2.5).
 - b. Origin to the *obturator internus* laterally (Fig. 2.5).
 - c. Attachment to the *puboprostatic ligaments* medial to the attachment of the *levator ani*.



- 5 The *pectineal line* provides attachment to:
 - a. The conjoint tendon at the medial end.
 - b. The lacunar ligament at the medial end, in front of the attachment of the conjoint tendon.
 - c. The pectineal ligament of Cooper along the whole length of the line lateral to the attachment of the lacunar ligament
 - d. The pectineus muscle which arises from the whole length of the line (Figs 2.4 and 4.1).
 - e. The fascia covering the pectineus.
 - f. The psoas minor, which is inserted here when present.
- 6 The upper part of the *pectineal surface* gives origin to the pectineus (Fig. 2.4).
- 7 The pelvic surface is crossed by the ductus deferens in males, and the round ligament of the uterus in females (see Chapters 31 and 32).
- 8 The *obturator groove* transmits the obturator vessels and nerve (see Fig. 4.4).
- 9 See attachments on conjoined ischiopubic rami with ischium.

ISCHIUM

The ischium forms the posteroinferior part of the hip bone, and the adjoining two-fifths of the acetabulum. It forms the posterior boundary of the obturator foramen. The ischium has a body and a ramus (Figs 2.1, 2.2 and 2.4).

Body of the Ischium

This is a thick and massive mass of bone that lies below and behind the acetabulum. It has:

- Two ends—upper and lower;
- Three borders—anterior, posterior and lateral;
- Three surfaces—femoral, dorsal and pelvic.

Two Ends

- 1 The *upper end* forms the posteroinferior two-fifths of the acetabulum. The ischium, ilium and pubis fuse with each other in the acetabulum.
- 2 The *lower end* forms the *ischial tuberosity*. It gives off the ramus of the ischium which forms an acute angle with the body.

Three Borders

- 1 The *anterior border* forms the posterior margin of the obturator foramen.
- 2 The *posterior border* is continuous above with the posterior border of the ilium. Below, it ends at the upper end of the ischial tuberosity. It also forms part of the lower border of the greater sciatic notch. Below the notch the posterior margin shows a projection called the *ischial spine*. Below the spine the posterior border shows a concavity called the *lesser sciatic notch*.

- 3 The *lateral border* forms the lateral margin of the ischial tuberosity, except at the upper end where it is rounded.

Three Surfaces

- 1 The *femoral surface* lies between the anterior and lateral borders.
- 2 The *dorsal surface* is continuous above with the gluteal surface of the ilium. From above downwards it presents a convex surface adjoining the acetabulum, a wide shallow groove, and the upper part of the ischial tuberosity.

The *ischial tuberosity* is divided by a transverse ridge into an upper and a lower area. The upper area is subdivided by an oblique ridge into a superolateral area and an inferomedial area. The lower area is subdivided by a longitudinal ridge into outer and inner area (Fig. 2.6).

- 3 The *pelvic surface* is smooth and forms part of the lateral wall of the true pelvis.

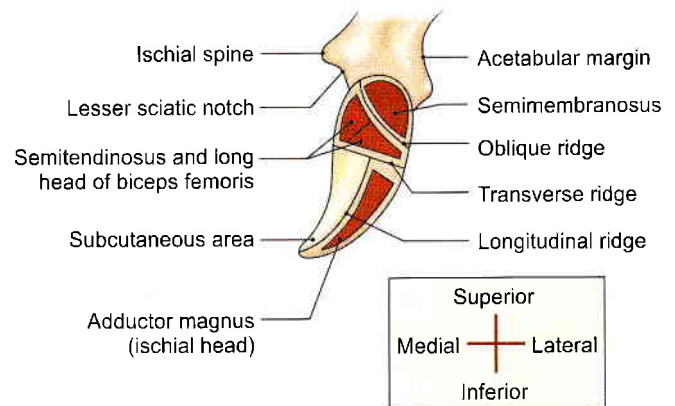


Fig. 2.6: Posterior view of the right ischial tuberosity and its attachments

Conjoined Ischiopubic Rami

The inferior ramus of the pubis unites with the ramus of the ischium on the medial side of the obturator foramen. The site of union may be marked by a localized thickening. The conjoined rami have:

Two Borders: Upper and lower

- 1 The *upper border* forms part of the margin of the obturator foramen.
- 2 The *lower border* forms the pubic arch along with the corresponding border of the bone of the opposite side.

Two Surfaces: Inner and outer

- 1 The *inner surface* is convex and smooth. It is divided into three areas, upper, middle and lower, by two ridges.
- 2 The *outer surface* is rough for the attachment of muscles.



Attachments and Relations of the Ischium

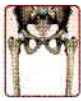- 1 The *ischial spine* provides:
 - a. Attachment to the *sacrospinous ligament* along its margins.
 - b. Origin for the posterior fibres of the *levator ani* from its pelvic surface. Its dorsal surface is crossed by pudendal nerve the internal pudendal vessels and by the nerve to the obturator internus (Figs 2.5 and 5.14).
- 2 The *lesser sciatic notch* is occupied by the tendon of the obturator internus. There is a bursa deep to the tendon. The notch is lined by hyaline cartilage. The upper and lower margins of the notch give origin to the *superior and inferior gemelli* respectively (Fig. 2.4). Gemellus is derived from gemini, which means 'twin'. Gemini is a sun sign.
- 3 The *femoral surface* of the ischium gives origin to:
 - a. The *obturator externus* along the margin of the obturator foramen.
 - b. The *quadratus femoris* along the lateral border of the upper part of the ischial tuberosity (Fig. 2.4).
- 4 The *dorsal surface* of the ischium has the following relationships. The upper convex area is related to the piriformis, the sciatic nerve, and the nerve to the quadratus femoris.
- 5 The attachments on the *ischial tuberosity* are as follows:
 - The superolateral area gives origin to the *semimembranosus*
 - The inferomedial area to the *semitendinosus* and the *long head* of the *biceps femoris*
 - The outer lower area to the *adductor magnus* (Figs 2.4 and 2.6).
 - The inner lower area is covered with fibrofatty tissue which supports body weight in the sitting position.
 - The sharp medial margin of the tuberosity gives attachment to the *sacrospinous ligament*.
 - The lateral border of the ischial tuberosity provides attachment to the *ischiofemoral ligament*, just below the acetabulum.
- 6 The greater part of the pelvic surface of the ischium gives origin to the *obturator internus*. The lower end of this surface forms part of the lateral wall of the ischioanal fossa (Fig. 2.5).
- 7 The attachments on the *conjoined ischiopubic rami* are as follows:
 - a. The upper border gives attachment to the *obturator membrane*.
 - b. The lower border provides attachment to the *fascia lata*, and to the membranous layer of superficial fascia or *Colles' fascia* of the perineum.
- c. The muscles taking origin from the outer surface are:
 - i. The *obturator externus*, near the obturator margin of both rami.
 - ii. The *adductor brevis*, chiefly from the pubic ramus.
 - iii. The *gracilis*, chiefly from the pubic ramus.
 - iv. The *adductor magnus*, chiefly from the ischial ramus (Fig. 2.4).
- d. The attachments on the inner surface are as follows:
 - i. The *perineal membrane* is attached to the lower ridge.
 - ii. The upper area gives origin to the *obturator internus*.
 - iii. The middle area gives origin to the *deep transversus perinei*, and is related to the dorsal nerve of the penis, and to the internal pudendal vessels.
 - iv. The lower area provides attachment to crus penis, and gives origin to the *ischiocavernosus* and to *superficial transversus perinei* (Fig. 2.5).

ACETABULUM

- 1 It is a deep cup-shaped hemispherical cavity on the lateral aspect of the hip bone, about its centre (Fig. 2.1).
- 2 It is directed laterally, downwards and forwards.
- 3 The margin of the acetabulum is deficient inferiorly, this deficiency is called the *acetabular notch*. It is bridged by the transverse ligament.
- 4 The nonarticular roughened floor is called the *acetabular fossa*. It contains a mass of fat which is lined by synovial membrane.
- 5 A horseshoe-shaped articular surface or lunate surface is seen on the anterior, superior, and posterior parts of the acetabulum. It is lined with hyaline cartilage, and articulates with the head of the femur to form the *hip joint*. The fibrocartilaginous *acetabular labrum* is attached to the margins of the acetabulum; it deepens the acetabular cavity.

OBTURATOR FORAMEN

- 1 This is a large gap in the hip bone, situated anteroinferior to acetabulum, between the pubis and the ischium.
- 2 It is large and oval in males, and small and triangular in females (Fig. 2.2).
- 3 It is closed by the obturator membrane which is attached to its margins, except at the obturator groove where the obturator vessels and nerve pass out of the pelvis.

**OSSIFICATION**

The hip bone ossifies in cartilage from three primary centres and five secondary centres. The primary centres appear, one for the ilium during the second month of intrauterine life; one for the ischium during the fourth month; and one for the pubis during the fifth month. At birth the hip bone is ossified except for three cartilaginous parts. These are:

- i. The iliac crest.
- ii. A Y-shaped cartilage separating the ilium, ischium and pubis (Fig. 2.7).
- iii. A strip along the inferior margin of the bone including the ischial tuberosity.

The ischiopubic rami fuse with each other at 7 to 8 years of age.

The secondary centres appear at puberty, two for the iliac crest, two for the Y-shaped cartilage of the acetabulum and one for the ischial tuberosity. Ossification in the acetabulum is complete at 16–17 years, and the rest of the bone is ossified by 20–25 years. The anterior superior iliac spine, pubic tubercle and crest and the symphyseal surface may have separate secondary centres of ossification.

CLINICAL ANATOMY

- Iliac crest is used for taking bone marrow biopsy in cases of anemia or leukemia.
- Weaver's bottom—persons sitting for a long period of time may get inflammation of their ischial tuberosity bursa.

FEMUR

The femur (Latin *thigh*) or thigh bone is the longest and the strongest bone of the body. Like any other typical bone it has two ends upper and lower, and a shaft (Figs 2.8 and 2.9).

Side Determination

- 1 The upper end bears a rounded head whereas the lower end is widely expanded to form two large condyles.
- 2 The head is directed medially.
- 3 The cylindrical shaft is convex forwards.

Anatomical Position

- 1 The head is directed medially upwards and slightly forwards.
- 2 The shaft is directed obliquely downwards and medially so that the lower surfaces of two condyles of femur lie in the same horizontal plane.

Features**Upper End**

The upper end of the femur includes the head, the neck, the greater trochanter (Greek *runner*) the lesser trochanter, the intertrochanteric line, and the intertrochanteric crest. These are described as follows.

Head

- 1 The head forms more than half a sphere, and is directed medially, upwards and slightly forwards (Fig. 2.9).

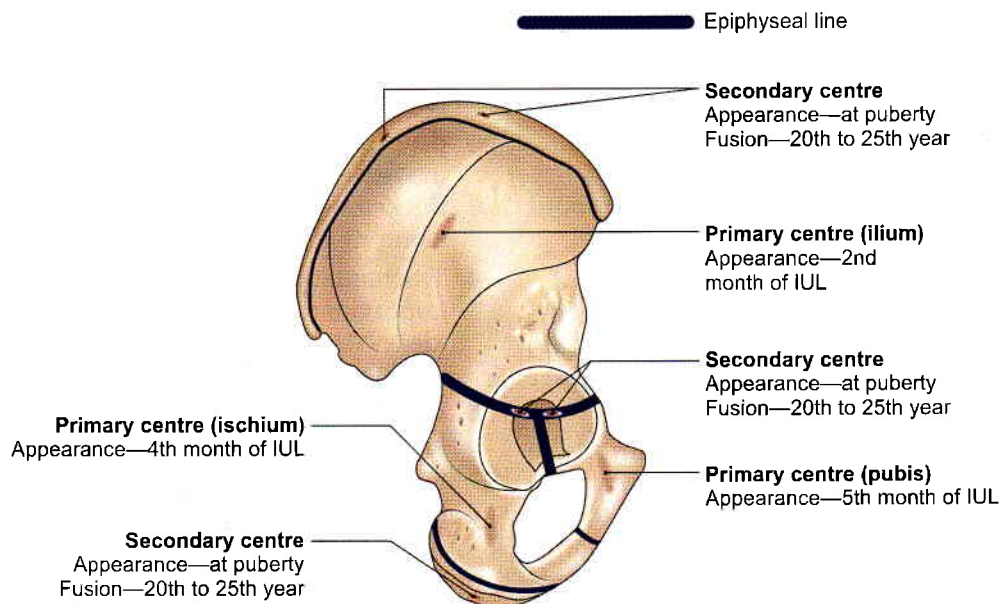


Fig. 2.7: Ossification of the hip bone

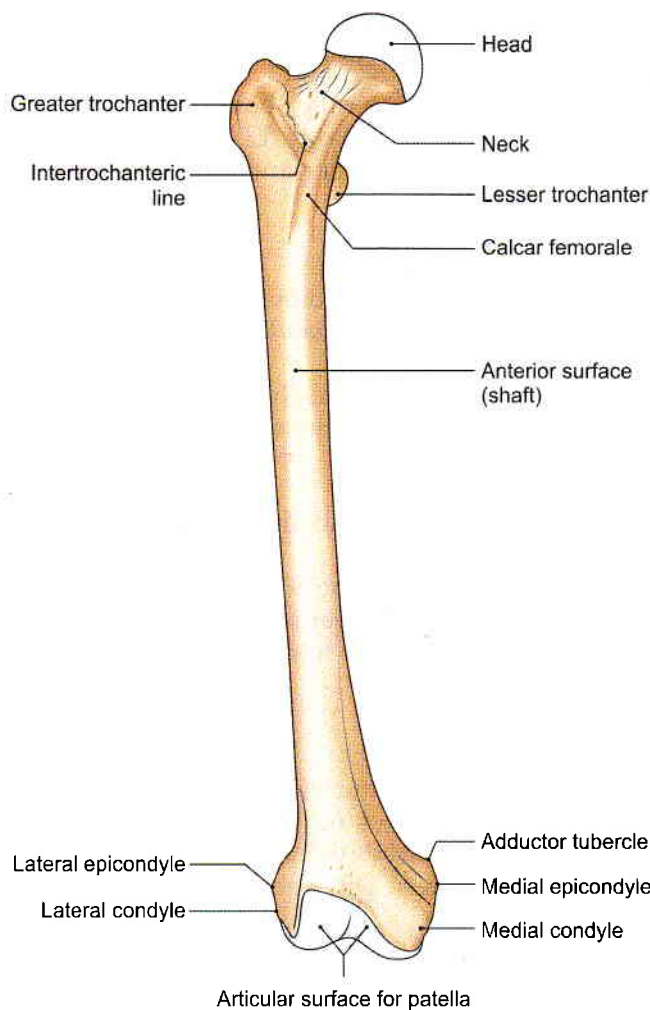


Fig. 2.8: Right femur anterior aspect

- 2 It articulates with the acetabulum to form the hip joint.
- 3 A roughened pit is situated just below and behind the centre of the head. This pit is called the fovea (Fig. 2.9).

Neck

- 1 It connects the head with the shaft and is about 3.7 cm long.
- 2 The neck has two borders and two surfaces.
The *upper border*, concave and horizontal, meets the shaft at the greater trochanter. The *lower border*, straight and oblique, meets the shaft near the lesser trochanter.

The *anterior surface* is flat. It meets the shaft at the intertrochanteric line. It is entirely intracapsular. The articular cartilage of the head may extend to this surface. The *posterior surface* is convex from above downwards and concave from side to side. It meets the shaft at the *intertrochanteric crest*. Only a little more than its medial half is intracapsular.

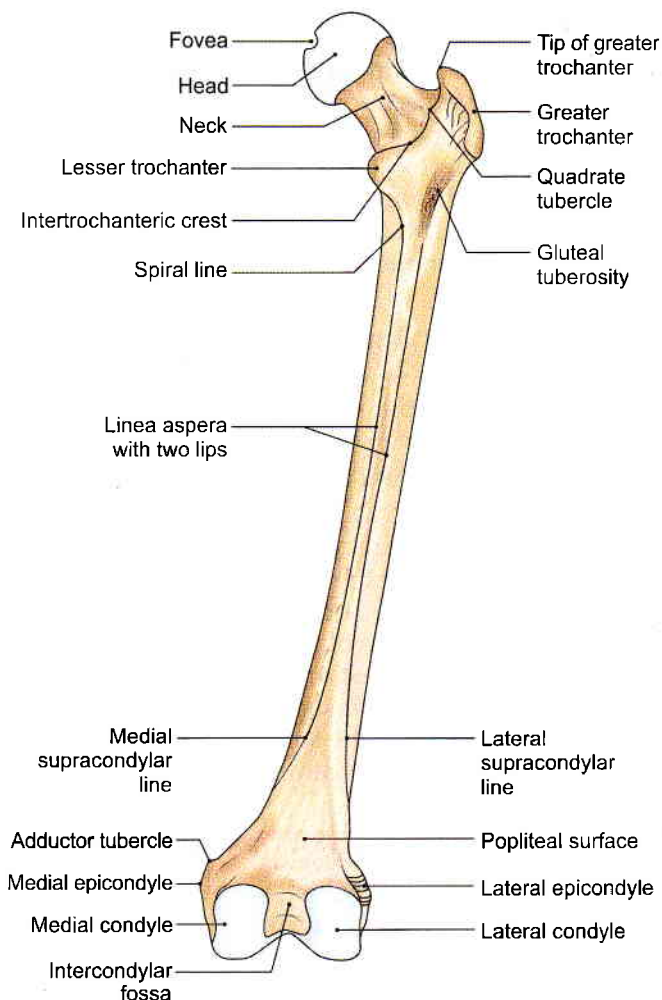
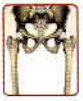

Fig. 2.9: Right femur posterior aspect

- The posterior surface is crossed by a horizontal groove for the tendon of the obturator externus to be inserted into the trochanteric fossa.
- 3 The neck makes an angle with the shaft. The *Neck-shaft angle* is about 125° in adults. It is less in females due to their wider pelvis. The angle facilitates movements of the hip joint. It is strengthened by a thickening of bone called the *calcar femorale* present along its concavity (Figs 2.8 and 2.9).
 - 4 Trochanter-shaft angle is about 8° in adults. It is an important radiological parameter which provides the idea of direction of medullary canal and its alignment with the greater trochanter.
 - 5 The *angle of femoral torsion* or angle of anteversion is formed between the transverse axes of the upper and lower ends of the femur. It is about 15 degrees.
 - 6 *Blood supply:* The intracapsular part of the neck is supplied by the retinacular arteries derived chiefly from the trochanteric anastomosis. The vessels produce longitudinal grooves and foramina directed towards the head, mainly on the anterior and



posterosuperior surfaces. The extracapsular part of the neck is supplied by the ascending branch of the medial circumflex femoral artery.

Greater Trochanter

- 1 This is large quadrangular prominence located at the upper part of the junction of neck with the shaft. The upper border of the trochanter lies at the level of the centre of the head.
- 2 The greater trochanter has an upper border with an apex, and three surfaces, anterior, medial and lateral. The *apex* is the inturned posterior part of the posterior border. The *anterior surface* is rough in its lateral part. The *medial surface* presents a rough impression above, and a deep *trochanteric fossa* below. The *lateral surface* is crossed by an oblique ridge directed downwards and forwards.

Lesser Trochanter

It is a conical eminence directed medially and backwards from the junction of the posteroinferior part of the neck with the shaft.

Intertrochanteric line

It marks the junction of the anterior surface of the neck with the shaft of the femur. It is a prominent roughened ridge which begins above, at the anterosuperior angle of the greater trochanter as a tubercle, and is continuous below with the spiral line in front of the lesser trochanter. The spiral line winds round the shaft below the lesser trochanter to reach the posterior surface of the shaft (Fig. 2.9).

Intertrochanteric crest

It marks the junction of the posterior surface of the neck with the shaft of the femur. It is a smooth-rounded ridge, which begins above at the posterosuperior angle of the greater trochanter and ends at the lesser trochanter. The rounded elevation, a little above its middle, is called the *quadrate tubercle*.

Shaft

The shaft is more or less cylindrical. It is narrowest in the middle, and is more expanded inferiorly than superiorly. It is convex forwards and is directed obliquely downwards and medially, because the upper ends of two femora are separated by the width of the pelvis, and their lower ends are close together.

In the *middle one-third*, the shaft has three borders, medial, lateral and posterior and three surfaces, anterior, medial and lateral.

The medial and lateral borders are rounded and ill-defined, but the posterior border is in the form of a broad roughened ridge, called the *linea aspera*

(Latin *rough line*). The *linea aspera* has distinct medial and lateral lips.

The medial and lateral surfaces are directed more backwards than towards the sides.

In the *upper one-third of the shaft*, the two lips of the *linea aspera* diverge to enclose an additional posterior surface. Thus this part has:

Four borders—medial, lateral, spiral line and the lateral lip of the gluteal tuberosity

Four surfaces—anterior, medial, lateral and posterior. The gluteal tuberosity is a broad roughened ridge on the lateral part of the posterior surface.

In the *lower one-third of the shaft* also, the two lips of the *linea aspera* diverge as supracondylar lines to enclose an additional, *popliteal surface*. Thus, this part of the shaft has:

Four borders—medial, lateral, medial supracondylar line and lateral supracondylar line.

Four surfaces—anterior, medial, lateral and popliteal. The medial border and medial supracondylar line meet inferiorly to obliterate the medial surface (refer to 3).

Lower End

The lower end of the femur is widely expanded to form two large condyles, one medial and one lateral. Anteriorly, the two condyles are united and are in line with the front of the shaft. Posteriorly, they are separated by a deep gap, termed the *intercondylar fossa* or *intercondylar notch*, and project backwards much beyond the plane of the popliteal surface (Fig. 2.9).

Articular Surface

The two condyles are partially covered by a large articular surface which is divisible into patellar and tibial parts.

The *patellar surface* covers the anterior surfaces of both condyles, and extends more on the lateral condyle than on the medial (Fig. 2.8). Between the two condyles, the surface is grooved vertically. It is separated from the tibial surfaces by two faint grooves.

The *tibial surfaces* cover the inferior and posterior surfaces of the two condyles, and merge anteriorly with the patellar surface. The part of the surface over the lateral condyle is short and straight anteroposteriorly. The part over the medial condyle is longer and is curved with its convexity directed medially (Fig. 2.9).

Lateral Condyle

The lateral condyle is flat laterally, and is more in line with the shaft. It, therefore, takes greater part in the transmission of body weight to the tibia. Though it is less prominent than the medial condyle, it is stouter and stronger. The lateral aspect presents the following.



- 1 A prominence called the *lateral epicondyle*.
- 2 The *popliteal groove* which lies just below the epicondyle. It has a deeper anterior part and a shallower posterior part.
- 3 A *muscular impression* posterosuperior to the epicondyle (Fig. 2.15).

Medial Condyle

This condyle is convex medially. The most prominent point on it is called the *medial epicondyle*. Posterosuperior to the epicondyle there is a projection, the *adductor tubercle*. This tubercle is an important landmark. The epiphyseal line for the lower end of the femur passes through it.

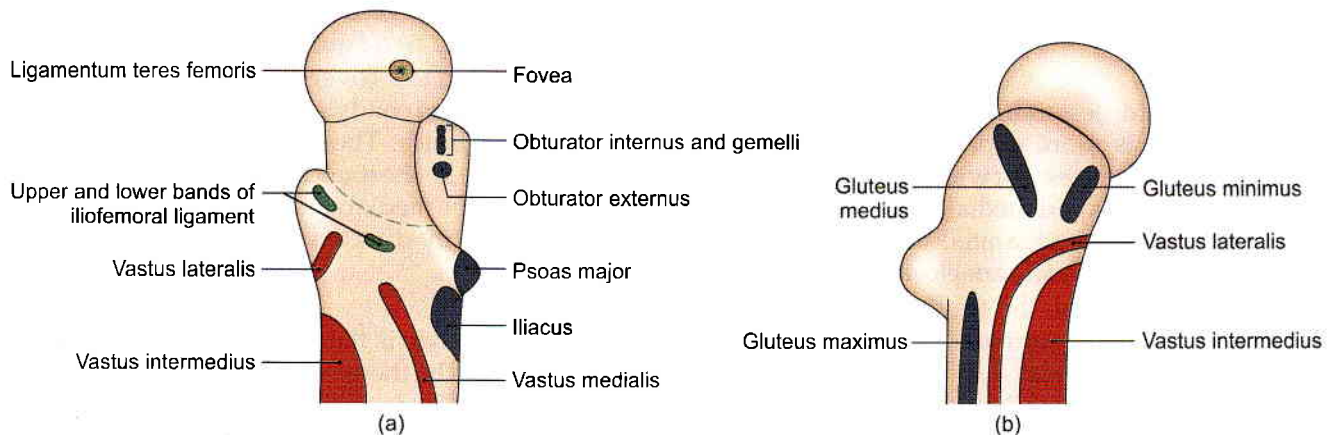
Intercondylar Fossa or Intercondylar Notch

This notch separates the lower and posterior parts of the two condyles. It is limited anteriorly by the patellar articular surface, and posteriorly by the intercondylar line which separates the notch from the popliteal surface.

Attachments on the Femur

- 1 The fovea on the head of the femur provides attachment to the ligament of the head of femur or round ligament, or *ligamentum teres/femoris* (Fig. 2.10a).
- 2 The following are attached to the *greater trochanter*.
 - a. The *piriformis* is inserted into the apex (Fig. 2.11).
 - b. The *gluteus minimus* is inserted into the rough lateral part of the anterior surface (Fig. 2.10b).
 - c. The *obturator internus* and the *two gemelli* are inserted into the upper rough impression on medial surface (Fig. 2.12).
 - d. The *obturator externus* is inserted into the trochanteric fossa (Fig. 2.12).

- e. The *gluteus medius* is inserted into the ridge on the lateral surface (Fig. 2.10b). The trochanteric bursa of the *gluteus maximus* lies behind the ridge.
- 3 The attachments on the *lesser trochanter* are as follows:
 - a. The *psoas* (Greek *loin*) *major* is inserted on the apex and medial part of the rough anterior surface (Figs 2.11 and 2.12).
 - b. The *iliacus* is inserted on the anterior surface of the base of the trochanter and on the area below it (Fig. 2.13).
 - c. The smooth posterior surface of the lesser trochanter is covered by a bursa that lies deep to the upper horizontal fibres of the *adductor magnus*.
- 4 The *intertrochanteric line* provides:
 - a. Attachment to the *capsular ligament* of the hip joint.
 - b. Attachment to the *upper band* of the *iliofemoral ligament* in its upper part.
 - c. Attachment to the *lower band* of *iliofemoral ligament* in its lower part (Fig. 2.14).
 - d. Origin to the *highest fibres* of the *vastus lateralis* from the upper end (Fig. 2.10b).
 - e. Origin to the *highest fibres* of the *vastus medialis* from the lower end of the line (Fig. 2.10a).
- 5 The *quadratus femoris* receives the insertion of the *quadratus femoris* (Fig. 2.12).
- 6 The attachments on the *shaft* are as follows:
 - a. The medial and popliteal surfaces are bare, except for a little extension of the origin of the medial head of the *gastrocnemius* to the medial part of popliteal surface.
 - b. The *vastus intermedius* arises from the upper three-fourths of the anterior and lateral surfaces (Fig. 2.11).
 - c. The *articularis genu* arises just below the *vastus intermedius*.
 - d. The lower 5 cm of the anterior surface are related to *suprapatellar bursa*.



Figs 2.10a and b: Upper end of the right femur: (a) Medial aspect, and (b) lateral aspect

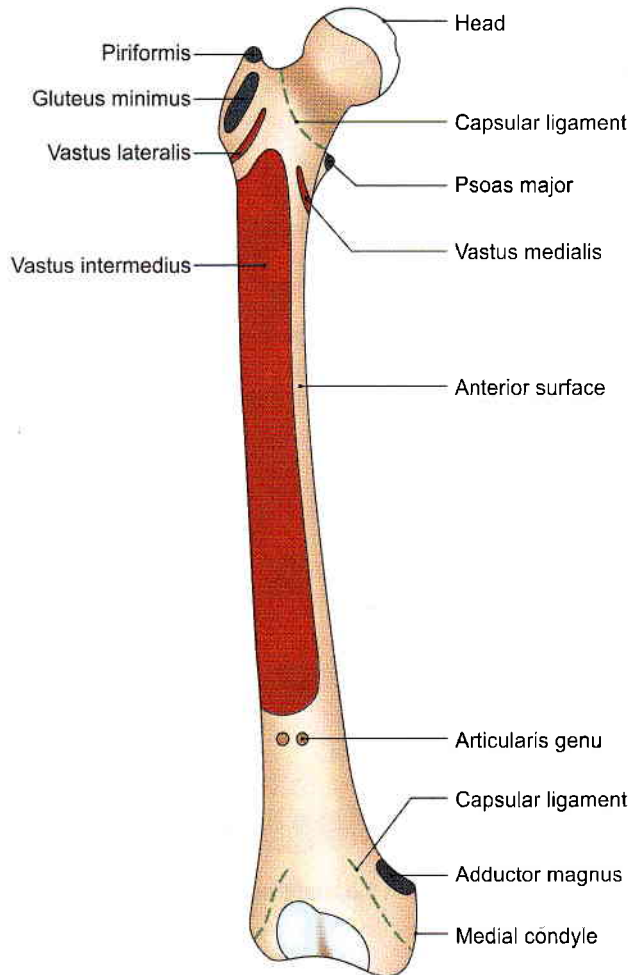
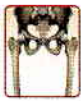

Fig. 2.11: Attachments on the anterior aspect of the right femur

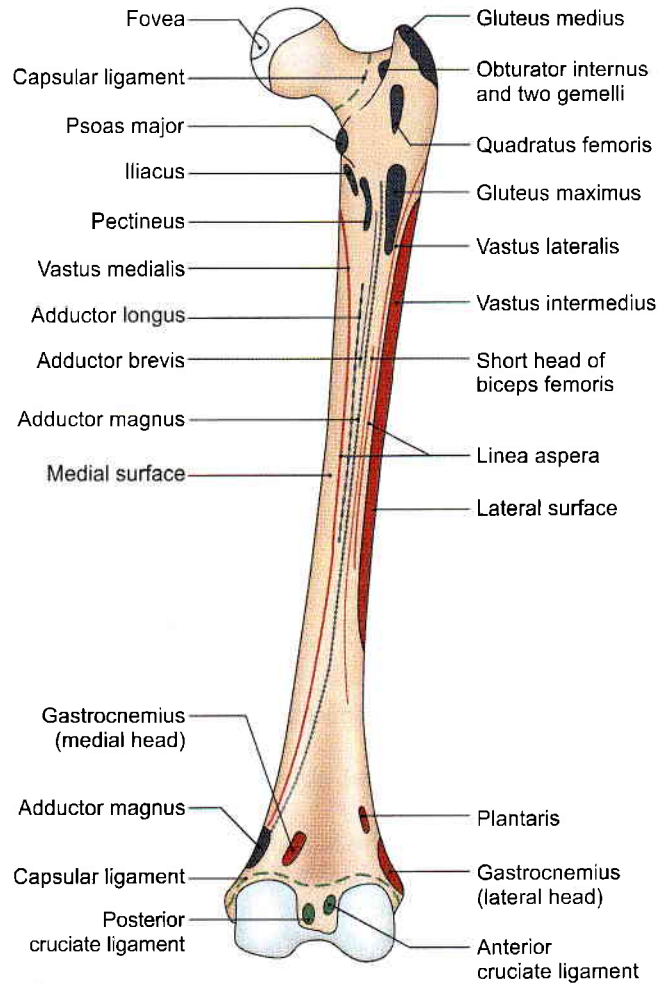


Fig. 2.12: Attachments on the posterior aspect of the right femur

- e. The *vastus lateralis* arises from the upper part of the intertrochanteric line, anterior and inferior aspects of the greater trochanter, the lateral margin of the gluteal tuberosity, and the upper half of the lateral lip of the linea aspera (Figs 2.12 and 2.13).
- f. The *vastus medialis* arises from the lower part of intertrochanteric line, the spiral line, medial lip of the linea aspera, and the medial supracondylar line (Fig. 2.13).
- g. The deeper fibres of the lower half of the *gluteus maximus* are inserted into the gluteal tuberosity.
- h. The *adductor longus* is inserted along the medial lip of the linea aspera between the vastus medialis and the adductors brevis and magnus.
- i. The *adductor brevis* is inserted into a line extending from the lesser trochanter to the upper part of the linea aspera, behind the pectineus and the upper part of the adductor longus.
- j. The *adductor magnus* is inserted into the medial margin of the gluteal tuberosity, the linea aspera, the medial supracondylar line, and the adductor

tubercle, leaving a gap for the popliteal vessels (Fig. 2.13).

- k. The *pectineus* is inserted on a line extending from the lesser trochanter to the linea aspera.
- l. The *short head of the biceps femoris* arises from the lateral lip of the linea aspera between the vastus lateralis and the adductor magnus, and from the upper two-thirds of the lateral supracondylar line (Fig. 2.13).
- m. The medial and lateral *intermuscular septa* are attached to the lips of the linea aspera and to the supracondylar lines. They separate the extensor muscles from the adductors medially, and from the flexors laterally (see Fig. 3.9).
- n. The lower end of the lateral supracondylar line gives origin to the *plantaris* above and the upper part of the *lateral head of the gastrocnemius* below (Fig. 2.12).
- o. The popliteal surface is covered with fat and forms the floor of the popliteal fossa. The origin of the *medial head of the gastrocnemius* extends to the

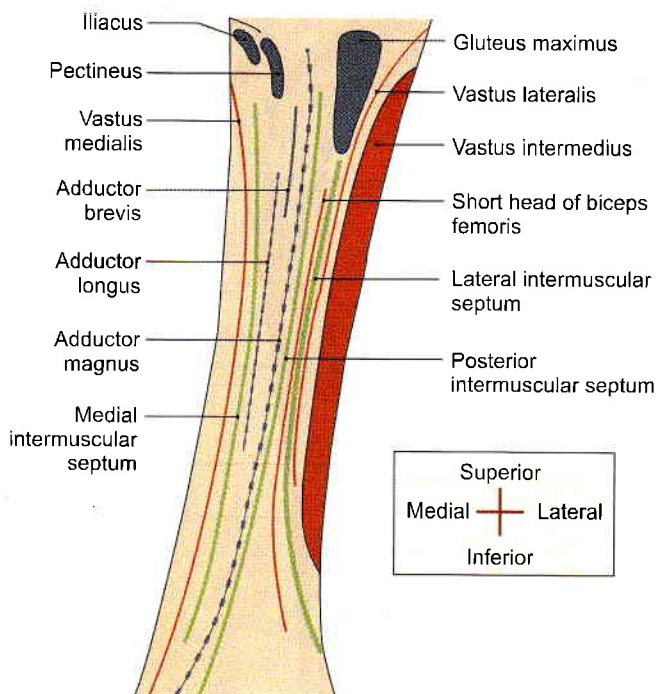


Fig. 2.13: Magnified view of structures attached to linea aspera

popliteal surface just above the medial condyle (Fig. 2.12).

- 7 The attachments on the *lateral condyle* are:
 - a. The *fibular collateral ligament* of the knee joint is attached to the lateral epicondyle (Fig. 2.15).
 - b. The *popliteus* arises from the deep anterior part of the popliteal groove. When the knee is flexed the tendon of this muscle lies in the shallow posterior part of the groove.
 - c. The muscular impression near the lateral epicondyle gives origin to the *lateral head of the gastrocnemius*.
- 8 The attachments on the *medial condyle* are as follows:
 - a. The *tibial collateral ligament of the knee joint* is attached to the medial epicondyle (Fig. 12.11).
 - b. The adductor tubercle receives the insertion of the hamstring part or the *ischial head of the adductor magnus* (Fig. 2.12).
- 9 The attachments on the *intercondylar notch* are as follows:
 - a. The *anterior cruciate ligament* is attached to the posterior part of the medial surface of the lateral condyle, on a smooth impression.
 - b. The *posterior cruciate ligament* is attached to the anterior part of the lateral surface of medial condyle, on a smooth impression (Fig. 2.12).
 - c. The *intercondylar line* provides attachment to the capsular ligament and laterally to the oblique popliteal ligament.
 - d. The *infrapatellar synovial fold* is attached to the anterior border of the intercondylar fossa (Fig. 2.12).

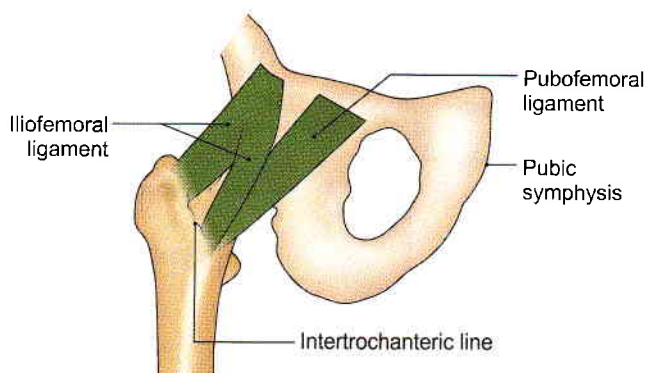


Fig. 2.14: Attachment of iliofemoral ligament

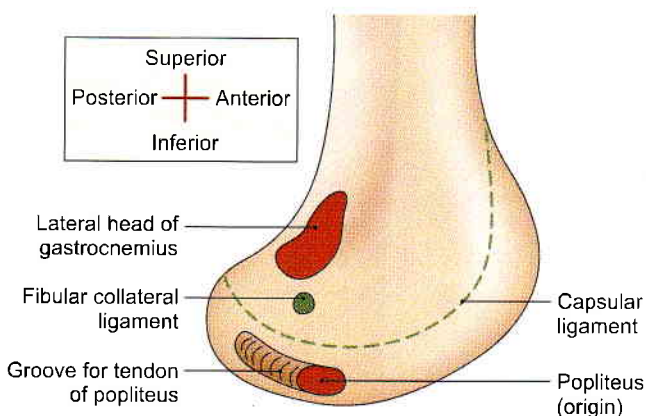


Fig. 2.15: Attachments on the lateral surface of the lateral condyle of the femur

Nutrient Artery to the Femur

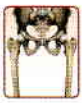This is derived from the *second perforating artery*, branch of profunda femoris artery. The nutrient foramen is located on the medial side of the linea aspera, and is directed upwards.

Structure

The angles and curvatures of the femur are strengthened on their concave sides by bony buttresses. The concavity of the neck-shaft angle is strengthened by a thickened buttress of compact bone, known as the *calcar femorale*. Similarly, the linea aspera is also supported by another buttress. This mechanism helps in resisting stresses including that of body weight.

OSSIFICATION

The femur ossifies from one primary and four secondary centres. The primary centre for the shaft appears in the seventh week of intrauterine life. The secondary centres appear, one for the lower end at the end of the ninth month of intrauterine life, one for the head during the first six months of life, one for the greater trochanter during the fourth year, and



one for the lesser trochanter during the twelfth year (Fig. 2.16).

There are three epiphyses at the upper end and one epiphysis at the lower end. The upper epiphyses; lesser trochanter, greater trochanter and head, in that order, fuse with the shaft at about eighteen years. The lower epiphysis fuses by the twentieth year.

The following points are noteworthy.

1. The neck represents the upper end of the shaft because it ossifies from the primary centre.
2. Ossification of the lower end of the femur is of medicolegal importance. Presence of its centre in a newly born child found dead indicates that the child was viable, i.e. it was capable of independent existence.
3. The lower end of the femur is the growing end.
4. The lower epiphyseal line passes through the adductor tubercle.
5. The epiphyseal line of the head coincides with the articular margins, except superiorly where a part of the monarticular area is included in the epiphysis for passage of blood vessels to the head. In addition, the plane of this epiphysis changes with age from an oblique to a more vertical one.

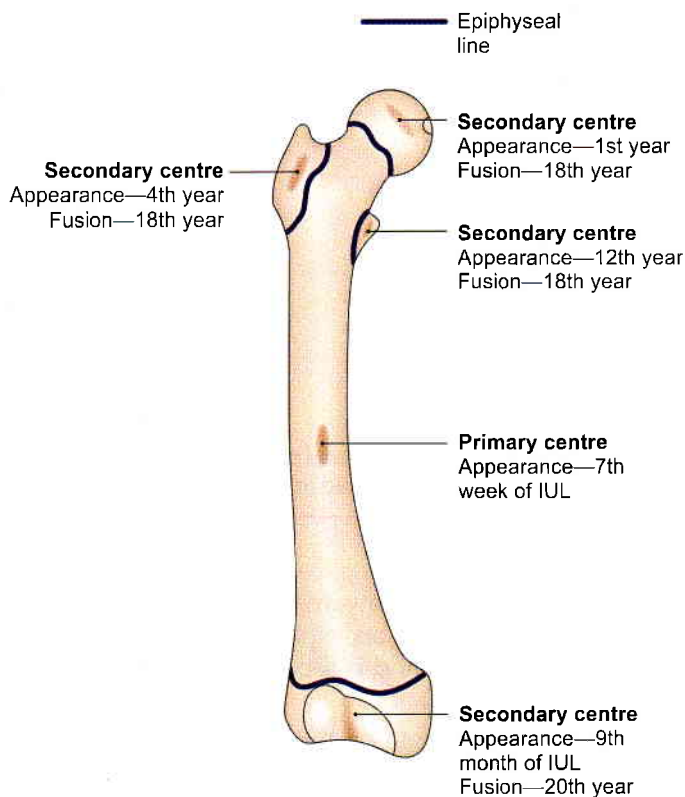


Fig. 2.16: Ossification of femur

CLINICAL ANATOMY

- Tripping over minor obstructions or other accidents causing forced medial rotation of the thigh and leg during the fall results in:
 - a. The fracture of the shaft of femur in persons below the age of 16 years (Fig. 2.17).
 - b. Bucket-handle tear of the medial meniscus between the ages of 14 and 40 years (Fig. 2.18).
 - c. Pott's (British surgeon 1713–88) fracture of the leg between the ages of 40 and 60 years (Fig. 2.19).
 - d. Fracture of neck of the femur over the age of 60 years (Fig. 2.17). This is common in females due to osteoporosis and degeneration of calcar femorale.
- The head of femur is partly supplied by a branch of obturator artery along the ligamentum teres. Main arterial supply is from retinacular arteries, branches of medial femoral circumflex artery. These arteries get injured in intracapsular fracture of neck of femur, leading to avascular necrosis of the head (Figs 2.20a and b). In such cases hip joint need to be replaced.
- The centre of ossification in lower end of femur and even in upper end of tibia seen by X-ray is used as a medicolegal evidence to prove that the newborn (found dead) was nearly full term and was viable.
- In fracture of upper third of shaft of femur, proximal segment is flexed by iliopsoas, laterally rotated by muscles attached to greater trochanter. Distal segment is pulled upwards by hamstrings and laterally rotated by adductor muscles.
- In normal knee, the obliquity of the line of quadriceps muscle and its insertion into the tibia, results in an angle called "Q angle". It is normally 15–20°. If the angle is increased, there may be lateral subluxation of the patella (see Fig. 3.27).

PATELLA

The patella (Latin *small plate*) is the largest sesamoid bone in the body, developed in the tendon of the quadriceps femoris. It is situated in front of the lower end of the femur about 1 cm above the knee joint (Fig. 2.21a).

Side Determination

- 1 The patella is triangular in shape with its apex directed downwards. The apex is nonarticular posteriorly.
- 2 The anterior surface is rough and monarticular. The upper three-fourths of the posterior surface are smooth and articular.

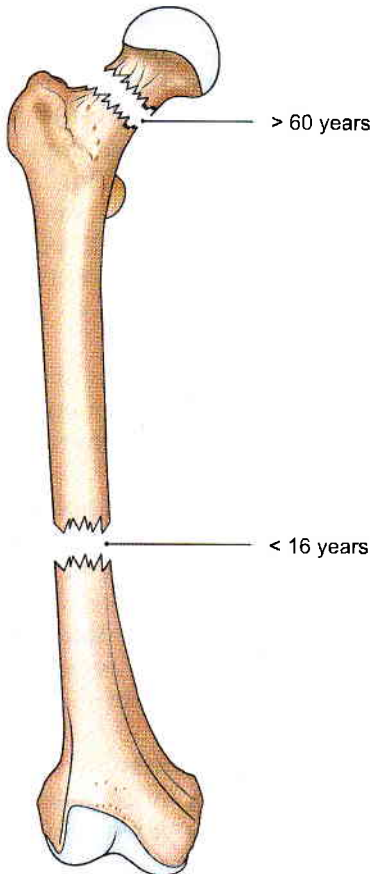


Fig. 2.17: Common sites of fracture

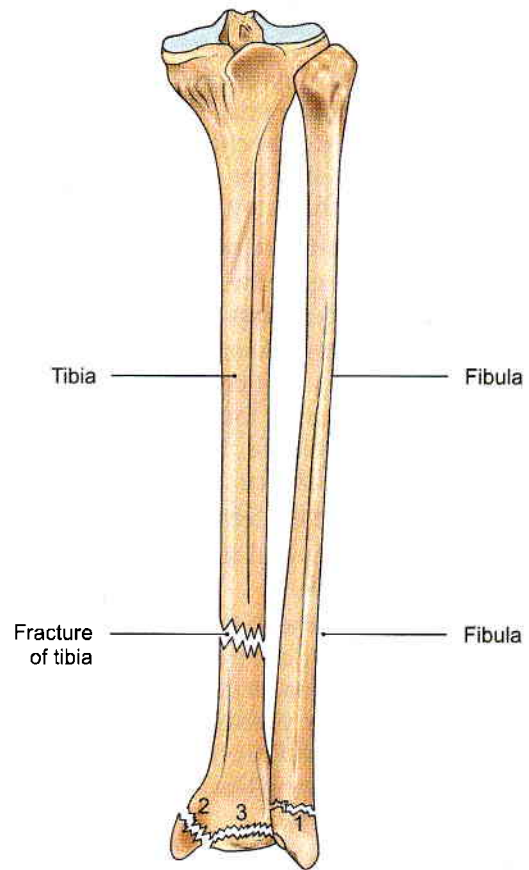


Fig. 2.19: Common sites of Pott's fracture and fracture of tibia

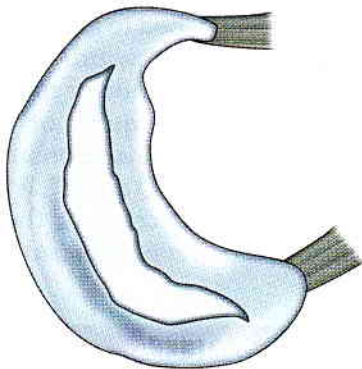
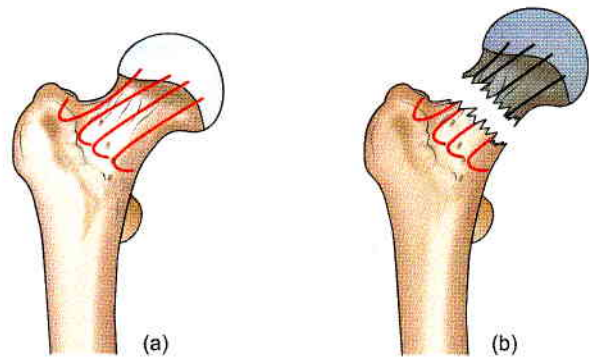


Fig. 2.18: Bucket-handle tear of medial meniscus



Figs 2.20a and b: (a) Normal arterial supply of the head of femur and (b) avascular necrosis of head in fracture neck femur

- 3 The posterior articular surface is divided by a vertical ridge into a larger lateral and a smaller medial areas.
- 4 The bone laid on a table rests on the broad lateral articular area and determines the side of the bone.

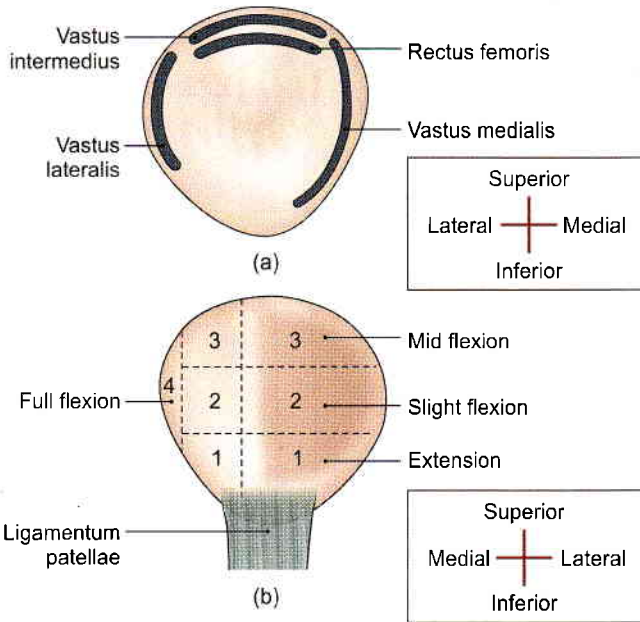
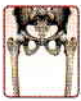Features

The patella has an apex, three borders, superior, lateral and medial, and two surfaces, anterior and posterior.

The *apex* directed downwards, is rough and vertically ridged. It is covered by an expansion from the tendon of the rectus femoris, and is separated from the skin by the prepatellar bursa.

The *posterior surface* is articular in its upper three-fourths and monarticular in its lower one-fourth.

The articular area is divided by a vertical ridge into a larger lateral and smaller medial portion. Another



Figs 2.21a and b: Features of the right patella: (a) Anterior view, and (b) posterior view

vertical ridge separates a medial strip from the medial portion. This strip articulates with a reciprocal strip on the medial side of the intercondylar notch of the femur during full flexion. The rest of the medial portion and the lateral portion of the articular surface are divided by two transverse lines into three pairs of facets.

During different phases of movements of the knee, different portions of the patella articulate with the femur. The lower pair of articular facets articulates during extension; middle pair during beginning of flexion; upper pair during midflexion; and the medial strip during full flexion of the knee (Fig. 2.21b).

Attachments on the Patella

The *superior border* or base provides insertion to the rectus femoris in front and to the vastus intermedius behind. The *lateral border* provides insertion to vastus lateralis in its upper one-third or half. The *medial border* provides insertion to the vastus medialis in its upper two-thirds.

The nonarticular area on the posterior surface provides attachment to the ligamentum patellae below, and is related to infrapatellar pad of fat above.

OSSIFICATION

The patella ossifies from several centres which appear during 3 to 6 years of age. Fusion is complete at puberty.

One or two centres at the superolateral angle of the patella may form separate pieces of bone. Such a patella is known as bipartite or tripartite patella. The condition is bilateral and symmetrical (Fig. 2.22).

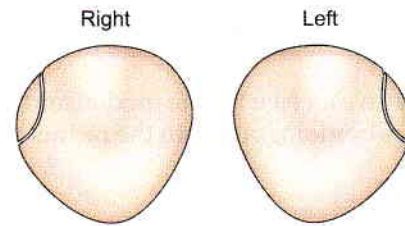


Fig. 2.22: Bipartite patella

CLINICAL ANATOMY

- Fracture of the patella should be differentiated from a bipartite or a tripartite patella (Fig. 2.22).
- The patella has a natural tendency to dislocate outwards because of the outward angulation between the long axes of the thigh and leg. This is prevented by:
 - a. *Bony factor:* The lateral edge of the patellar articular surface of the femur is deeper than the medial edge.
 - b. *Muscular factor:* Insertion of the vastus medialis on the medial border of patella extends lower than that of vastus lateralis on the lateral border (Fig. 2.23). Vastus medialis is first to degenerate and last to recover in diseases of the knee joint.
- *Fascial factor:* Medial and lateral patellar retinacula are extensions of vastus medialis and vastus lateralis. These strengthen the capsule. These three are components of the extensor apparatus of knee joint. During sudden severe contraction of quadriceps, the tibial tuberosity may get avulsed. The tibial tuberosity ossifies as a downward protrusion of upper end.
- Patella may get fractured.
- Quadriceps femoris muscle is inserted into patella, from where ligamentum patellae arises which ends into the tibial tuberosity.
- Bursitis occurs in prepatellar and subcutaneous infrapatellar bursa (see Fig. 3.6).

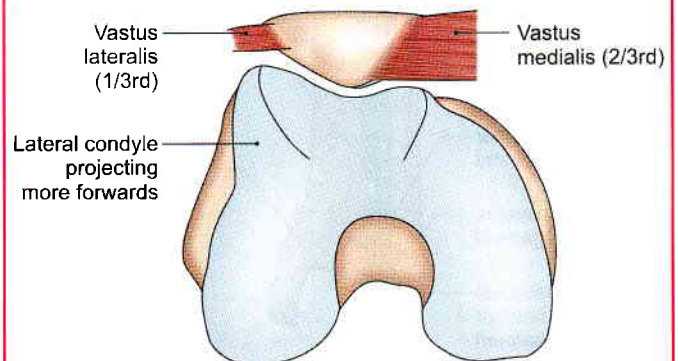


Fig. 2.23: Projecting lateral edge of patellar articular surface



TIBIA

The tibia (Latin *shin bone*) is the medial and larger bone of the leg. It is homologous with the radius of the upper limb.

Side Determination

- 1 The upper end is much larger than the lower end.
- 2 The medial side of the lower end projects downwards beyond the rest of the bone. The projection is called the *medial malleolus*.
- 3 The anterior border of the shaft is most prominent and crest-like. It is sinuously curved and terminates below at the anterior border of the medial malleolus.

Features

The tibia has an upper end, a shaft and a lower end (Figs 2.25 and 2.26).

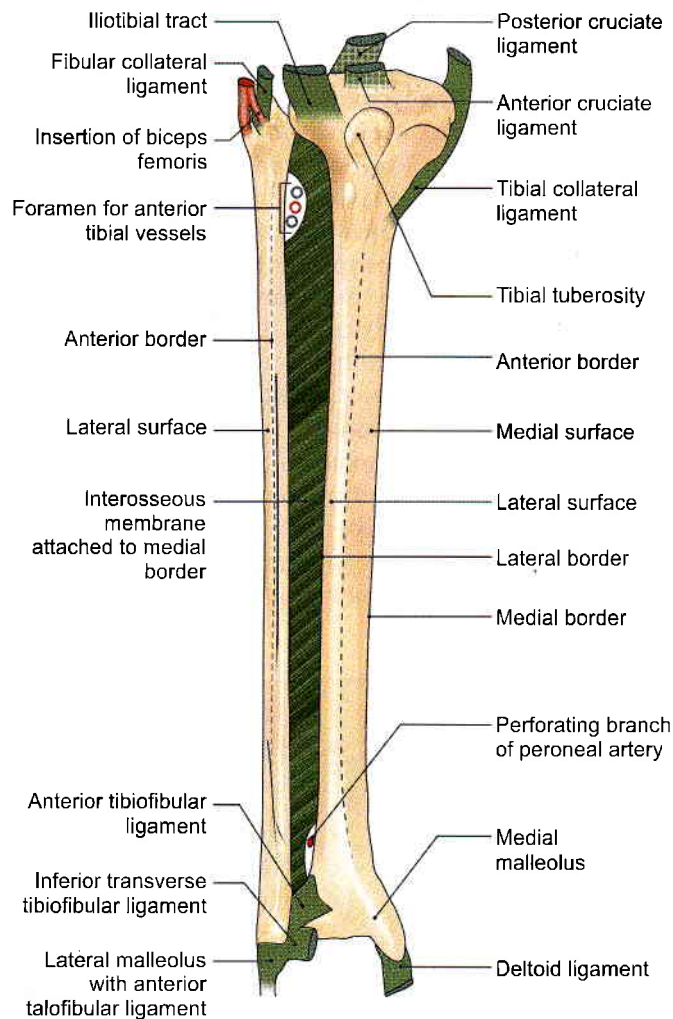


Fig. 2.24: Anterior view of right tibia and fibula including the ligaments

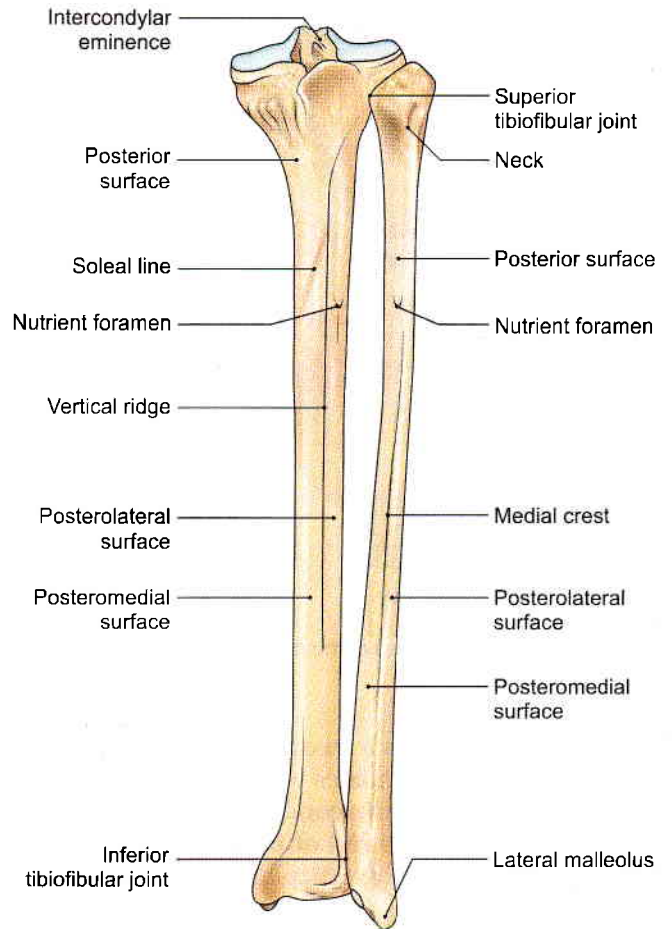


Fig. 2.25: Posterior view of right tibia and fibula

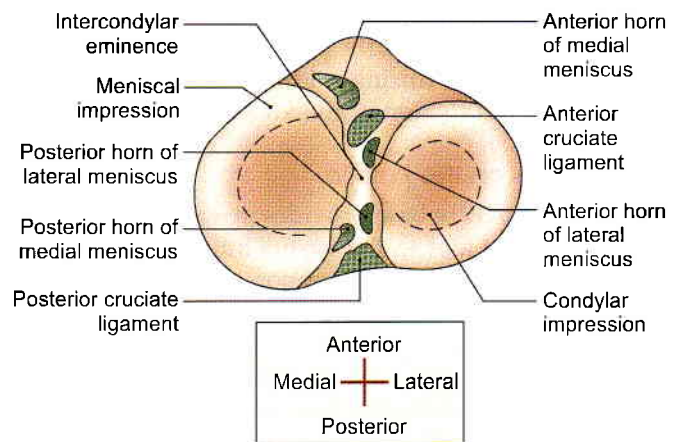
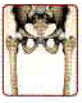

Fig. 2.26: Superior view of the upper end of the right tibia

Upper End

The upper end of the tibia is markedly expanded from side to side, to form two large condyles which overhang the posterior surface of the shaft. The upper end includes:

- 1 A medial condyle,
- 2 A lateral condyle,
- 3 An intercondylar area,
- 4 A tuberosity (refer to §).



Medial Condyle

Medial condyle is larger than the lateral condyle. Its superior surface articulates with the medial condyle of the femur. The articular surface is oval and its long axis is anteroposterior. The central part of the surface is slightly concave and comes into direct contact with the femoral condyle. The peripheral part is flat and is separated from the femoral condyle by the *medial meniscus*. The lateral margin of the articular surface is raised to cover the medial intercondylar tubercle.

The posterior surface of the medial condyle has a groove. The anterior and medial surfaces are marked by numerous vascular foramina.

Lateral Condyle

The lateral condyle overhangs the shaft more than the medial condyle. The superior surface of the condyle articulates with the lateral condyle of the femur. The articular surface is nearly circular. As in the case of the medial condyle, the central part is slightly concave and comes in direct contact with the femur, but the peripheral part is flat and is separated from the femur by the *lateral meniscus*. The articular surface has a raised medial margin which covers the lateral intercondylar tubercle.

The posteroinferior aspect of the lateral condyle articulates with the fibula. The fibular facet is flat, circular, and is directed downwards, backwards and laterally. Superomedial to the fibular facet, the posterior surface of the condyle is marked by a groove (Fig. 2.24).

The anterior aspect of the condyle bears a flattened impression.

Intercondylar Area

Intercondylar area is the roughened area on the superior surface, between the articular surfaces of the two condyles. The area is narrowest in its middle part. This part is elevated to form the intercondylar eminence which is flanked by the medial and lateral intercondylar tubercles (Fig. 2.26).

Tuberosity of the Tibia

Tuberosity of the tibia is a prominence located on the anterior aspect of the upper end of the tibia. It forms the anterior limits of the intercondylar area. Inferiorly it is continuous with the anterior border of the shaft. The tuberosity is divided into an upper smooth area and a lower rough area. The epiphyseal line for the upper end of the tibia passes through the junction of these two parts.

Shaft

The shaft of the tibia is prismoid in shape. It has three borders, anterior, medial and interosseous; and three surfaces, lateral, medial and posterior.

Borders

The *anterior border* is sharp and S-shaped being convex medially in the upper part and convex laterally in the lower part. It extends from the tibial tuberosity above to the anterior border of the medial malleolus below. It is subcutaneous and forms the *shin*.

The *medial border* is rounded. It extends from the medial condyle, above, to the posterior border of the medial malleolus, below (Fig. 2.24).

The *interosseous* or *lateral border* extends from the lateral condyle a little below and in front of the fibular facet, to the anterior border of the fibular notch.

Surfaces

The *lateral surface* lies between the anterior and interosseous borders. In its upper three-fourths, it is concave and is directed laterally, and in its lower one-fourth it is directed forwards.

The *medial surface* lies between the anterior and medial borders. It is broad, and most of it is subcutaneous.

The *posterior surface* lies between the medial and interosseous borders. It is widest in its upper part. This part is crossed obliquely by a rough ridge called the *soleal line*. The soleal line begins just behind the fibular facet, runs downwards and medially, and terminates by joining the medial border at the junction of its upper and middle thirds (Fig. 2.25).

Above the soleal line, the posterior surface is in the form of a triangular area. The area below the soleal line is elongated. It is divided into medial and lateral parts by a *vertical ridge*. A *nutrient foramen* is situated near the upper end of this ridge. It is directed downwards and transmits the nutrient artery which is a branch of the *posterior tibial artery* (Fig. 2.25).

Lower End

The lower end of the tibia is slightly expanded. It has five surfaces. Medially, it is prolonged downwards as the medial malleolus (Fig. 2.24).

The anterior surface of the lower end has an upper smooth part, and a lower rough and grooved part.

The medial surface is subcutaneous and is continuous with the medial surface of the medial malleolus.

The lateral surface of the lower end presents a triangular fibular notch to which the lower end of the fibula is attached. The upper part of the notch is rough. The lower part is smooth and may be covered with hyaline cartilage.

The inferior surface of the lower end is articular. It articulates with the superior trochlear surface of the talus and thus takes part in forming the ankle joint. Medially the articular surface extends on to the medial malleolus.

Posterior surface is smaller.



The *medial malleolus* is a short but strong process which projects downwards from the medial surface of the lower end of the tibia. It forms a subcutaneous prominence on the medial side of the ankle.

Attachments on the Tibia

Figures 2.26 to 2.28 show the attachments on the tibia.

Attachments on the Medial Condyle

- 1 The *semimembranosus* is inserted into the groove on the posterior surface.
- 2 The *capsular ligament of the knee joint* is attached to the upper border, which also gives attachment to the deeper fibres of the tibial collateral ligament.
- 3 The medial patellar retinaculum is attached to the anterior surface.

Attachments on the Lateral Condyle

- 1 The *iliotibial tract* is attached to the flattened impression on the anterior surface (Figs 2.24 and 2.27).
- 2 The *capsular ligament of the superior tibiofibular joint* is attached around the margins of the fibular facet.

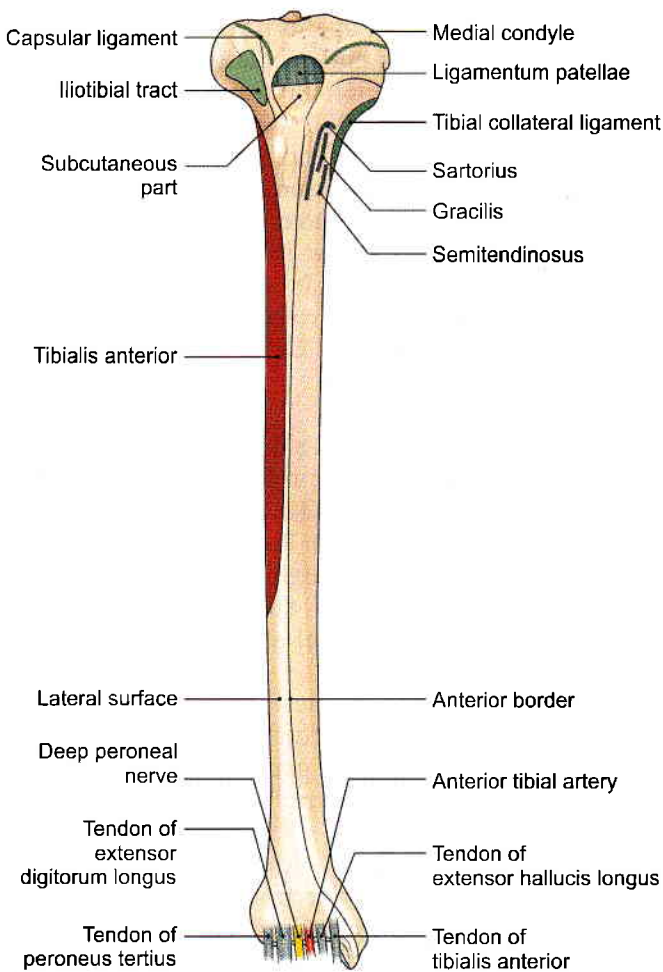


Fig. 2.27: Attachments and relations on the anterior aspect of the right tibia

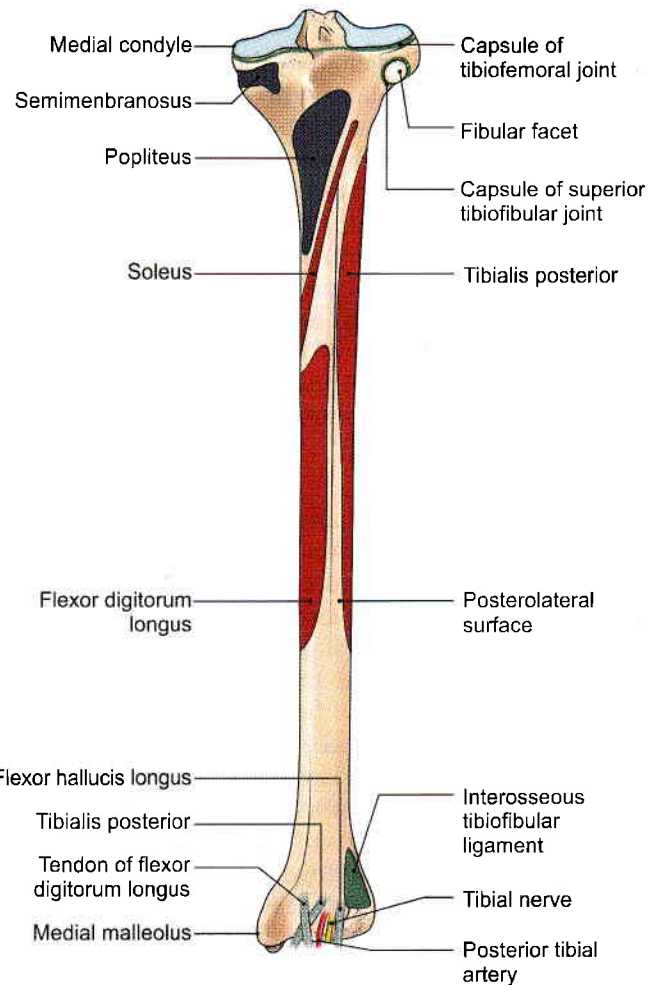


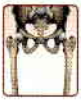Fig. 2.28: Attachments and relations on the posterior aspect of the right tibia

- 3 The groove on the posterior surface of the lateral condyle is occupied by the *tendon of the popliteus* with a bursa intervening.

Attachments on the Intercondylar Area

The following are attached from before backwards.

- 1 The *anterior horn of the medial meniscus* (Greek *small moon*) just in front of the medial articular surface (Fig. 2.26).
- 2 The *anterior cruciate* (Latin *cross*) *ligament* on a smooth area just behind the previous attachment.
- 3 The *anterior horn of the lateral meniscus*, to the front of the intercondylar eminence, and lateral to the anterior cruciate ligament.
- 4 The *posterior horn of the lateral meniscus*, to the posterior slope of the intercondylar eminence.
- 5 The *posterior horn of the medial meniscus*, to the depression behind the base of the medial intercondylar tubercle.
- 6 The *posterior cruciate ligament*, to the posterior-most smooth area.



Attachment on the Tibial Tuberosity

The *ligamentum patellae* is attached to the upper smooth part of the *tibial tuberosity*. The lower rough area of the tuberosity is subcutaneous, but is separated from the skin by the subcutaneous infrapatellar bursa (Fig. 2.27).

Attachments on the Shaft

- 1 The *tibialis anterior* arises from the upper two-thirds of the lateral surface.
- 2 The upper part of the medial surface receives the insertions of the *sartorius*, the *gracilis* and the *semitendinosus*, from before backwards (Fig. 2.27). Still further posteriorly this surface gives attachment to the *tibial collateral ligament* along the medial border (Fig. 2.27).
- 3 The *soleus* arises from the soleal line (Fig. 2.28). The soleal line also gives attachment to the fascia covering the soleus, the fascia covering the popliteus, and the transverse fascial septum. The tendinous arch for origin of the soleus is attached to a tubercle at the upper end of the soleal line.
- 4 The *popliteus* is inserted on the posterior surface, into the triangular area above the soleal line.
- 5 The medial area of the posterior surface below the soleal line gives origin to the *flexor digitorum longus* while the lateral area gives origin to the *tibialis posterior*.
- 6 The anterior border of the tibia gives attachment to the *deep fascia of the leg* and, in its lower part, to the *superior extensor retinaculum*.
- 7 The rough upper part of the fibular notch gives attachment to the *interosseous tibiofibular ligament*.
- 8 The *capsular ligament of the ankle joint* is attached to the lower end along the margins of articular surface. The *deltoid ligament* of the ankle joint is attached to the lower border of the *medial malleolus* (Fig. 2.24).

Relations of the Tibia

Apart from the relations mentioned above, the following may be noted.

- 1 The lower part of the anterior surface of the shaft, and the anterior aspect of the lower end, are crossed from medial to lateral side by the *tibialis anterior*, the *extensor hallucis longus*, the *anterior tibial artery*, the *deep peroneal nerve*, the *extensor digitorum longus*, and the *peroneus tertius* (Fig. 2.27).
- 2 The lower most part of the posterior surface of the shaft and the posterior aspect of the lower end are related from medial to lateral side to the *tibialis posterior*, which lies in a groove, the *flexor digitorum longus*, the *posterior tibial artery*, the *tibial nerve*, and the *flexor hallucis longus*. The groove for the tendon of the *tibialis posterior* continues downwards

on the posterior surface of the *medial malleolus* (Fig. 2.28).

- 3 The lower one-third of the medial surface of the shaft is crossed by the *great saphenous vein* (see Fig. 8.1).

Blood Supply

The nutrient artery to the tibia is the largest nutrient artery in the body. It is a branch of the posterior tibial artery which enters the bone on its posterior surface at the upper end of vertical ridge. It is directed downwards.

OSSIFICATION

The tibia ossifies from one primary and two secondary centres. The primary centre appears in the shaft during the seventh week of intrauterine life. A secondary centre for the upper end appears just *before birth*, and fuses with the shaft at 16–18 years. The upper epiphysis is prolonged downwards to form the *tibial tuberosity*. A secondary centre for the lower end appears during the first year, forms the *medial malleolus* by the seventh year, and fuses with the shaft by 15–17 years (Fig. 2.29).

CLINICAL ANATOMY

- The upper end of tibia is one of the commonest sites for acute osteomyelitis. The knee joint remains safe because the capsule is attached near the articular margins of the tibia, proximal to the epiphyseal line (Fig. 2.30).
- The tibia is commonly fractured at the junction of upper two-thirds and lower one-third of the shaft as the shaft is most slender here. Such fractures may unite slowly, or may not unite at all as the blood supply to this part of the bone is poor. This may also be caused by tearing of the nutrient artery.
- Forward dislocation of the tibia on the talus produces a characteristic prominence of the heel. This is the commonest type of injury of the ankle.

FIBULA

The fibula (Latin *clasp/pin*) is the lateral and smaller bone of the leg. It is very thin as compared to the tibia. It is homologous with the *ulna* of the upper limb (Figs 2.24 and 2.25). It forms a mortice of the ankle joint.

Side Determination

- 1 The upper end, or head, is slightly expanded in all directions. The lower end or lateral malleolus is expanded anteroposteriorly and is flattened from side to side.

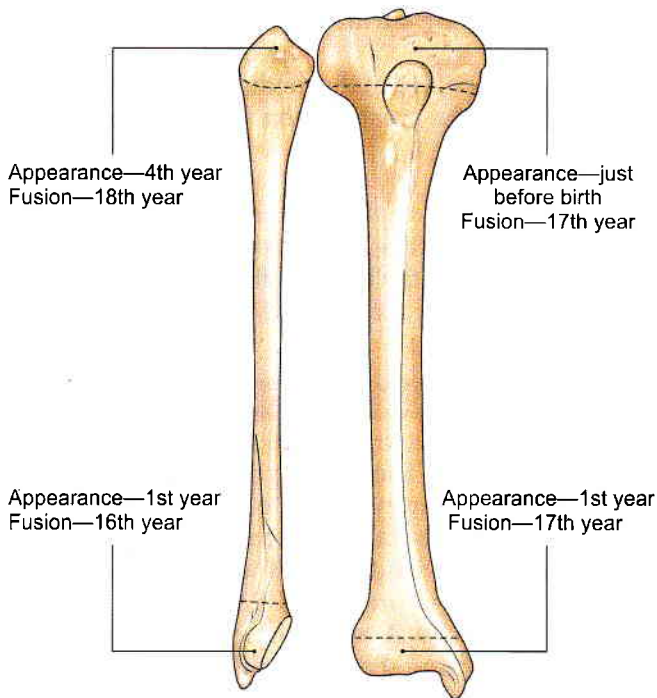


Fig. 2.29: Ossification of tibia and fibula

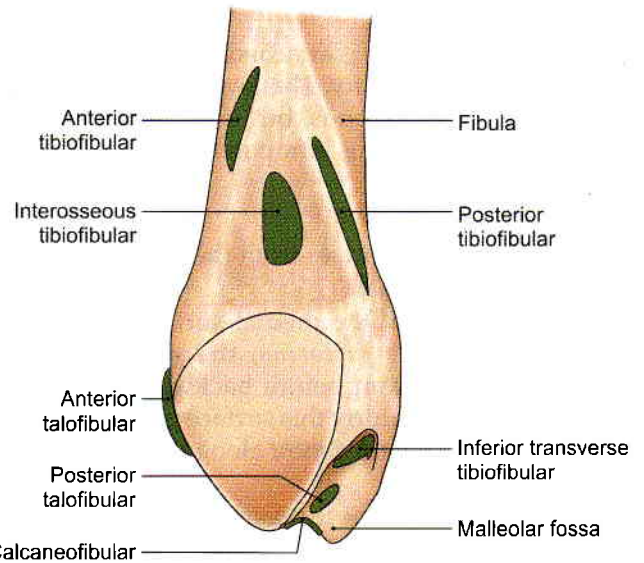


Fig. 2.31: Ligaments attached on the medial aspect of lower end of fibula

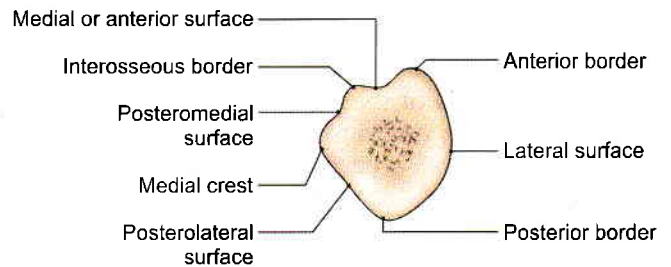


Fig. 2.32: Transverse section through shaft of middle two-fourths of fibula to show its borders and surfaces

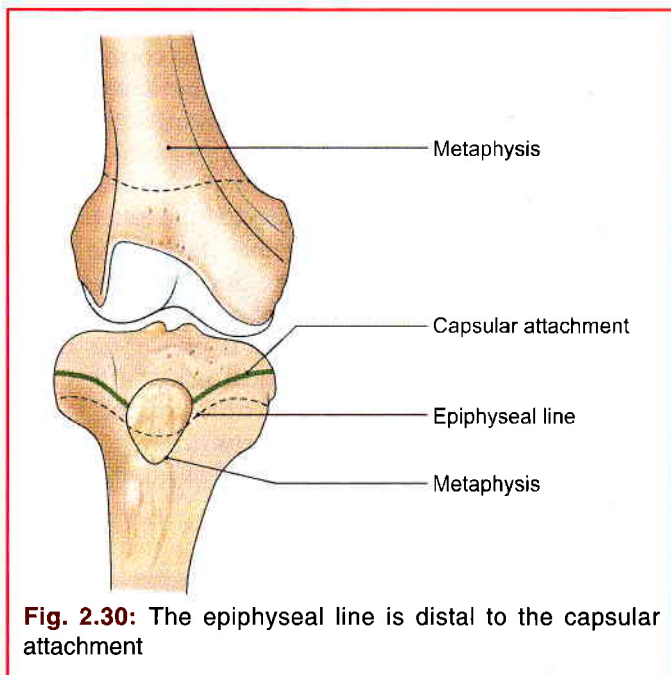


Fig. 2.30: The epiphyseal line is distal to the capsular attachment

- 2 The medial side of the lower end bears a triangular articular facet anteriorly, and a deep or *malleolar fossa* posteriorly (Fig. 2.31).

Features

The fibula has an upper end, a shaft (Fig. 2.32) and a lower end.

Upper End or Head

It is slightly expanded in all directions. The superior surface bears a circular articular facet which articulates with the lateral condyle of the tibia. The *apex* of the head or the *styloid process* projects upwards from its posterolateral aspect.

The constriction immediately below the head is known as the *neck* of the fibula (Figs 2.25 and 2.33).

Shaft

The shaft shows considerable variation in its form because it is moulded by the muscles attached to it. It has three borders—*anterior*, *posterior* and *interosseous*; and three surfaces—*medial*, *lateral* and *posterior* (Fig. 2.32).

Borders

The *anterior border* begins just below the anterior aspect of the head. At its lower end it divides to enclose an elongated triangular area which is continuous with the lateral surface of the lateral malleolus (Fig. 2.33).

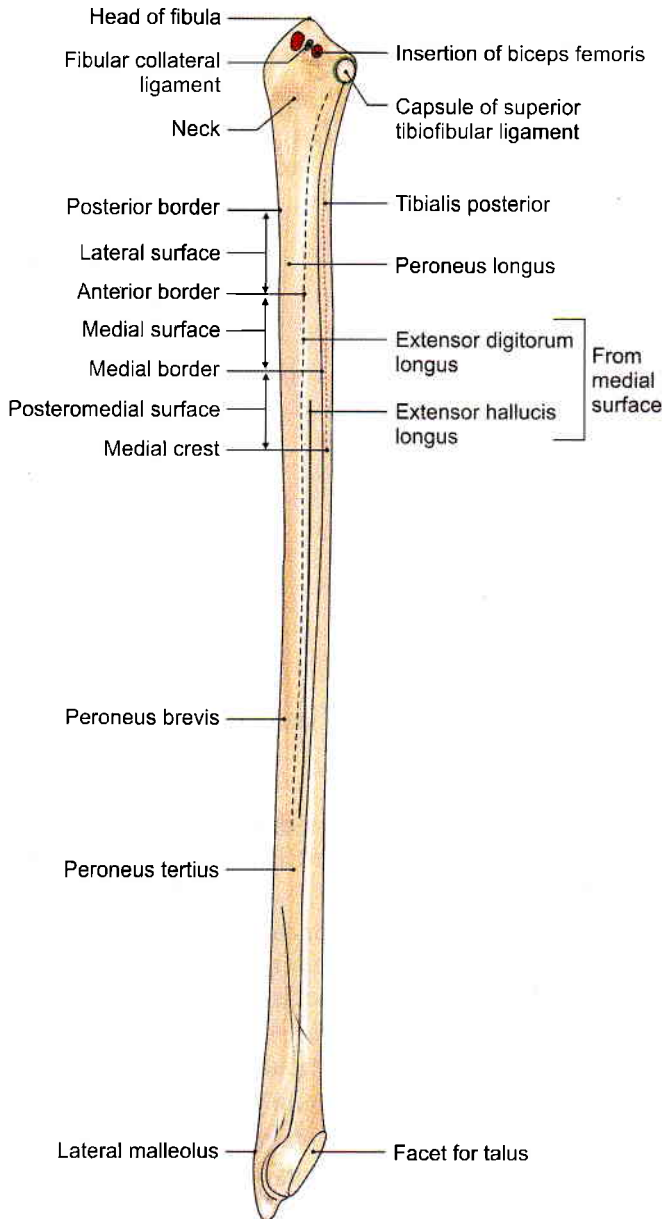
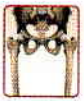

Fig. 2.33: Right fibula: Anterior aspect (schematic)

The *posterior border* is rounded. Its upper end lies in line with the styloid process. Below, the border is continuous with the medial margin of the groove on the back of the lateral malleolus (Fig. 2.34).

The *interosseous* or *medial border* lies just medial to the anterior border, but on a more posterior plane. It terminates below at the upper end of a roughened area above the talar facet of the lateral malleolus. In its upper two-thirds, the interosseous border lies very close to the anterior border and may be indistinguishable from it.

Surfaces

The *medial surface* lies between the anterior and interosseous borders. In its upper two-thirds, it is very narrow, measuring 1 mm or less (Figs 2.33 and 2.35).

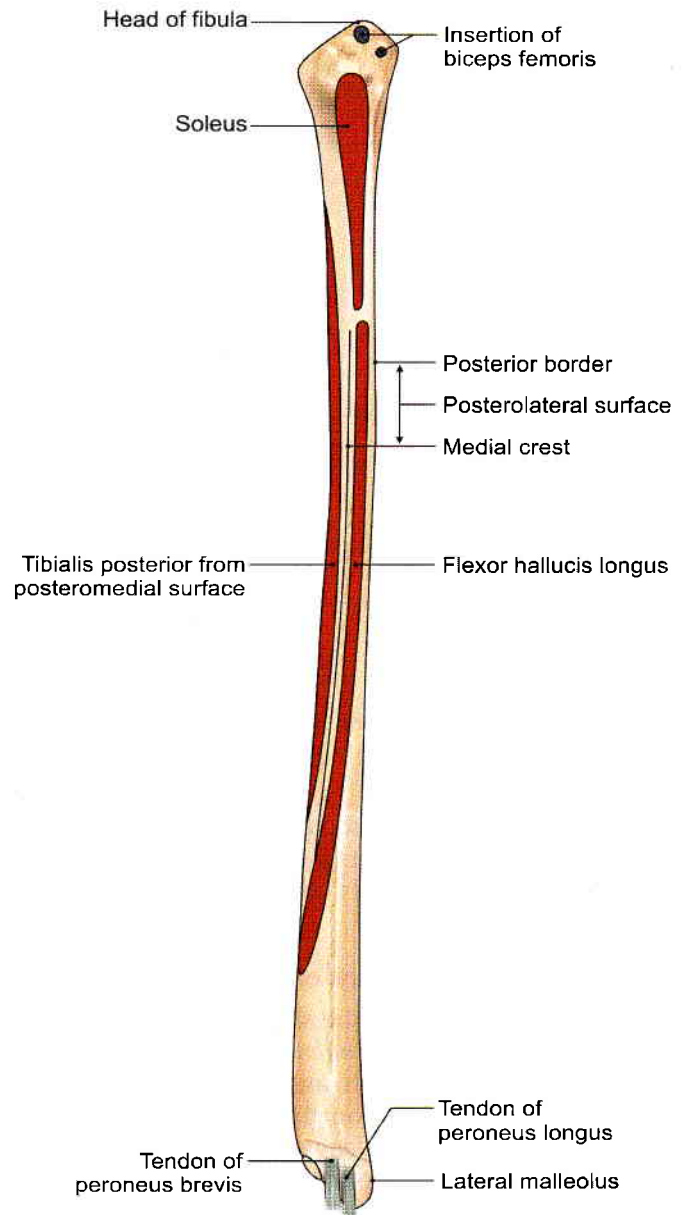


Fig. 2.34: Right fibula: Posterior aspect

The *lateral surface* lies between the anterior and posterior borders. It is twisted backwards in its lower part.

The *posterior surface* is the largest of the three surfaces. It lies between the interosseous and posterior borders. In its upper two-thirds, it is divided into two parts by a vertical ridge called the *medial crest* (Fig. 2.34).

Lower End or Lateral Malleolus

The tip of the lateral malleolus is 0.5 cm lower than that of the medial malleolus, and its anterior surface is 1.5 cm posterior to that of the medial malleolus. It has the following four surfaces.

- 1 The anterior surface is rough and rounded.
- 2 The posterior surface is marked by a groove.

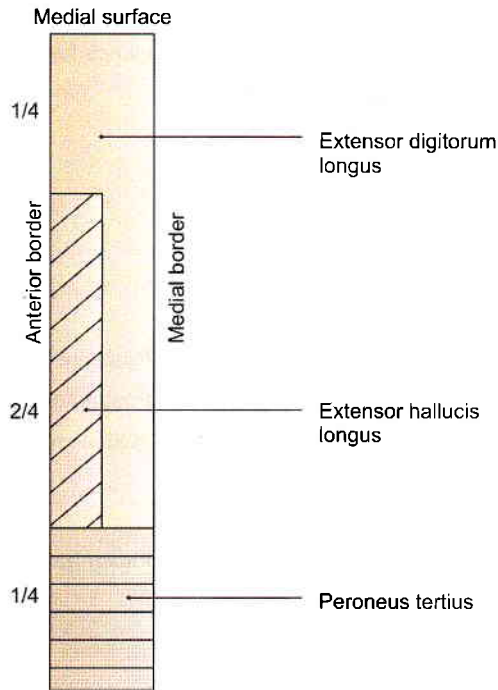


Fig. 2.35: Attachment on medial surface of fibula

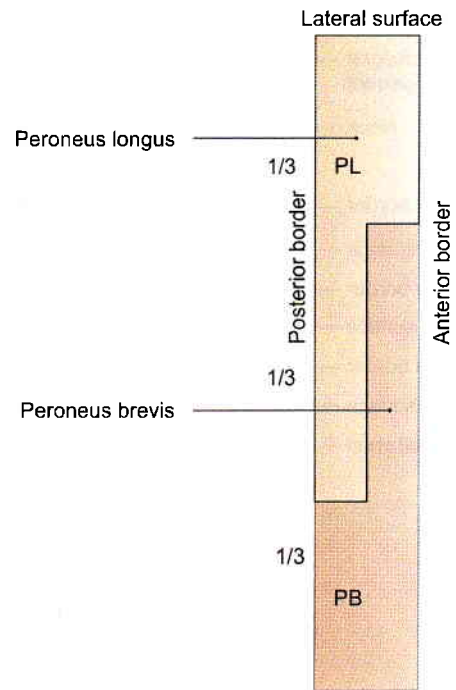


Fig. 2.36: Attachment on lateral surface of fibula

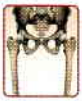- 3 The lateral surface is subcutaneous.
- 4 The medial surface bears a triangular articular facet for the talus anteriorly and the malleolar fossa posteriorly.

Attachments and Relations of the Fibula

- 1 The medial surface of the shaft gives origin to:
 - a. The *extensor digitorum longus*, from the whole of the upper one-fourth, and from the anterior half of the middle two-fourths.
 - b. The *extensor hallucis longus*, from the posterior half of its middle two-fourths.
 - c. The *peroneus tertius*, from its lower one-fourth (Fig. 2.35).
- 2 The part of the posterior surface between the medial crest and the interosseous border, the grooved part, gives origin to the *tibialis posterior*.
- 3 The part of the posterior surface between the medial crest and the posterior border gives origin to:
 - a. *Soleus* from the upper one-fourth.
 - b. *Flexor hallucis longus* from its lower three-fourths.
- 4 The lateral surface of the shaft gives origin to:
 - a. *Peroneus longus (PL)* from its upper one-third, and posterior half of the middle one-third.
 - b. The *peroneus brevis (PB)* from the anterior half of its middle one-third, and the whole of lower one-third (Fig. 2.36). The common peroneal nerve terminates in relation to the neck of fibula.
- 5 The head of the fibula receives the insertion of the *biceps femoris* on the anterolateral slope of the apex.
- 6 The *capsular ligament of the superior tibiofibular joint* is attached around the articular facet.
- 7 The anterior border of fibula gives attachment to:
 - a. *Anterior intermuscular septum* of the leg (see Fig. 8.3).
 - b. *Superior extensor retinaculum*, to lower part of the anterior margin of triangular area.
 - c. *Superior peroneal retinaculum*, to the lower part of the posterior margin of triangular area.
- 8 The posterior border gives attachment to the *posterior intermuscular septum*.
- 9 The interosseous border gives attachment to the *interosseous membrane*. The attachment leaves a gap at the upper end for passage of the *anterior tibial vessels* (Fig. 2.24).
- 10 The triangular area above the medial surface of the lateral malleolus gives attachment to:
 - a. The *interosseous tibiofibular ligament*, in the middle. The joint between lower ends of tibia and fibula is called *syndesmoses* (Greek *binding together*) (Fig. 2.24).
 - b. The *anterior tibiofibular ligament*, anteriorly (Fig. 2.24).
 - c. The *posterior tibiofibular*, posteriorly.

This insertion is C-shaped. The *fibular collateral ligament* of the knee joint is attached within the C-shaped area (Fig. 2.33).

The origins of the *extensor digitorum*, the *peroneus longus*, and the *soleus*, described above, extend on to the corresponding aspects of the head.



- 11 The attachments on the lateral malleolus are as follows:
- Anterior talofibular ligament* to the anterior surface (Fig. 2.31).
 - Inferior transverse tibiofibular* (a part of posterior tibiofibular) ligament above and *posterior talofibular ligament* below to the *malleolar fossa* (Fig. 2.31).
 - The *capsule of the ankle joint* along the edges of the malleolar articular surface.
 - Slight notch on the lower border gives attachment to *calcaneofibular ligament* (Fig. 2.31).
- 12 The groove on the posterior surface of the malleolus lodges the tendon of the *peroneus brevis*, which is deep, and of the *peroneus longus*, which is superficial (Fig. 2.34).

Blood Supply

The peroneal artery gives off the nutrient artery for the fibula, which enters the bone on its posterior surface. The nutrient foramen is directed downwards.

OSSIFICATION

The fibula ossifies from one primary and two secondary centres. The primary centre for the shaft appears during the eighth week of intrauterine life. A secondary centre for the lower end appears during the first year, and fuses with the shaft by about sixteen years. A secondary centre for the upper end appears during the fourth year, and fuses with the shaft by about eighteen years (Fig. 2.29).

The fibula *violates* the law of ossification because the secondary centre which appears first in the lower end does not fuse last. The reasons for this violation are:

- The secondary centre appears first in the lower end because it is a pressure epiphysis (law states that pressure epiphysis appear before the traction epiphysis).
- The upper epiphysis fuses last because this is the growing end of the bone. It continues to grow afterwards along with the upper end of tibia which is a growing end.

CLINICAL ANATOMY

- Sometimes a surgeon takes a piece of bone from the part of the body and uses it to repair a defect in some other. This procedure is called a *bone graft*. For this purpose pieces of bone are easily obtained from the subcutaneous medial aspect of tibia and shaft of fibula.
- If the foot gets caught in a hole in the ground, there is forcible abduction and external rotation. In such

an injury, first there occurs a spiral fracture of lateral malleolus, then fracture of the medial malleolus. Finally the posterior margin of the lower end of tibia shears off. These stages are termed 1st, 2nd and 3rd degrees of Pott's fracture (Fig. 2.19).

- The upper and lower ends of the fibula are subcutaneous and palpable (Fig. 2.37).
- The common peroneal nerve can be rolled against the neck of fibula. This nerve is commonly injured here resulting in *foot drop* (see Figs 6.8 and 7.11).
- Fibula is an ideal spare bone for a bone graft.
- Though fibula does not bear any weight, the lateral malleolus and the ligaments attached to it are very important in maintaining stability at the ankle joint.

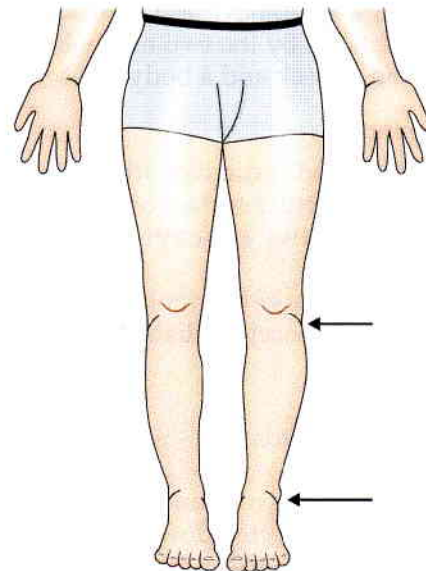


Fig. 2.37: Subcutaneous upper and lower ends of fibula

BONES OF THE FOOT

TARSUS/TARSALS

The tarsus is made up of seven tarsal bones, arranged in two rows. In the proximal row, there is the talus above, and the calcaneus below. In the distal row, there are four tarsal bones lying side by side. From medial to lateral side these are the medial cuneiform, the intermediate cuneiform, the lateral cuneiform and the cuboid. Another bone, the navicular, is interposed between the talus and the three cuneiform (Latin *wedge*) bones. In other words, it is interposed between the proximal and distal rows (Fig. 2.38).

The tarsal bones are much larger and stronger than the carpal bones because they have to support and

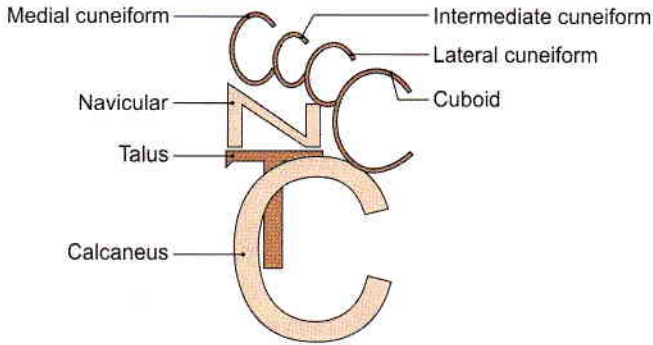


Fig. 2.38: Tarsus

distribute the body weight. Each tarsal bone is roughly cuboidal in shape, having six surfaces.

TALUS

The talus (Latin *ankle*) is the second largest tarsal bone. It lies between the tibia above and the calcaneum below, gripped on the sides by the two malleoli.

It has a head, a neck and a body.

Side Determination

- 1 The rounded head is directed forwards.
- 2 The trochlear articular surface of the body is directed upwards, and the concave articular surface downwards.
- 3 The body bears a large triangular, facet laterally, and a comma-shaped facet medially.

Head

- 1 It is directed forwards and slightly downwards and medially.
- 2 Its anterior surface is oval and convex. The long axis of this surface is directed downwards and medially. It articulates with the posterior surface of the navicular bone.
- 3 The inferior surface is marked by three articular areas separated by indistinct ridges. The posterior facet is largest, oval and gently convex; it articulates with the middle facet on sustentaculum tali of the calcaneum. The anterolateral facet articulates with the anterior facet of the calcaneum, and the medial facet with the spring ligament (Fig. 2.39b) (refer to 3).

Neck

- 1 This is the constricted part of the bone between the head and the body.
- 2 It is set obliquely on the body, so that inferiorly it extends further backwards on the medial side than on the lateral side. However, when viewed from dorsal side, the long axis of the neck is directed downwards, forwards and medially. The *neck-body* angle is 130 to 140 degrees in infants and 150 degrees

in adults. The smaller angle in young children accounts for the inverted position of their feet.

- 3 The medial part of its plantar surface is marked by a deep groove termed the *sulcus tali*. The *sulcus tali* lies opposite the *sulcus calcanei* on the calcaneum, the two together enclosing a space called the *sinus tarsi*.
- 4 In habitual squatters, a squatting facet is commonly found on the upper and lateral part of the neck. The facet articulates with the anterior margin of the lower end of the tibia during extreme dorsiflexion of the ankle.

Body

The body is cuboidal in shape and has five surfaces.

The *superior surface* bears an articular surface, which articulates with the lower end of the tibia to form the ankle joint (Fig. 2.39a). This surface is also called the *trochlear surface*. It is convex from before backwards and concave from side to side. It is wider anteriorly than posteriorly. The medial border of the surface is straight, but the lateral border is directed forwards and laterally. The trochlear surface articulates with the inferior surface of lower end of tibia.

The *inferior surface* bears an oval, concave articular surface which articulates with the posterior facet of the calcaneum to form the subtalar joint (Fig. 12.22a).

The *medial surface* is articular above and nonarticular below. The articular surface is comma-shaped and articulates with the medial malleolus of tibia (Fig. 2.39c).

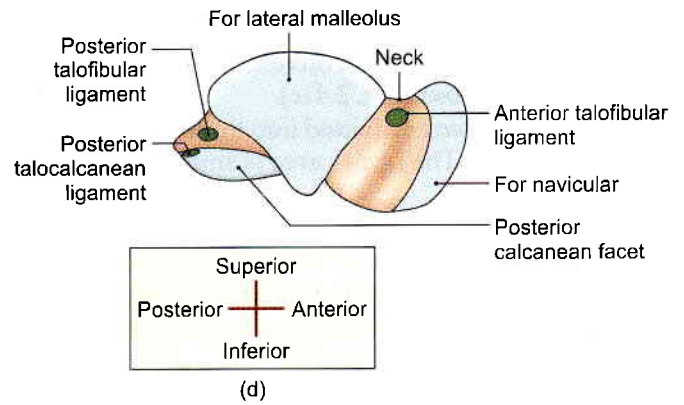
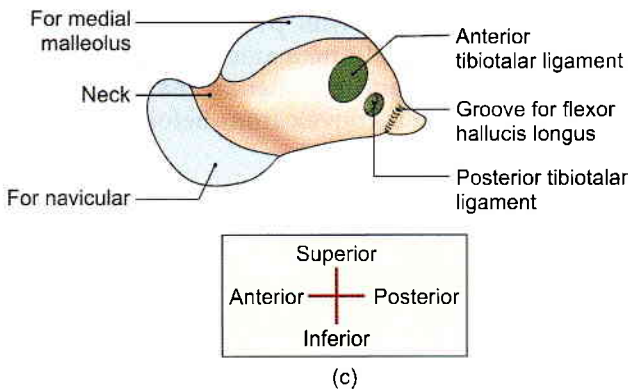
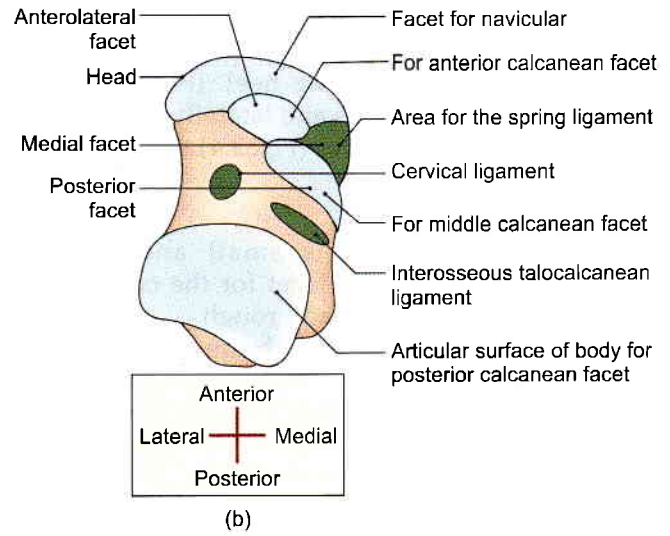
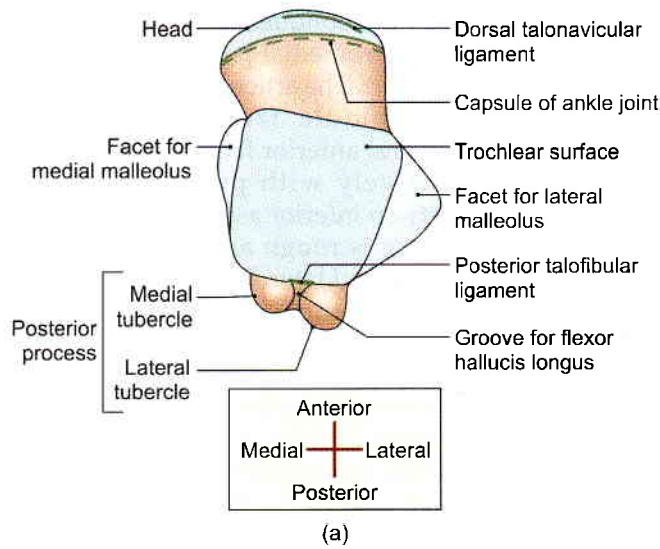
The *lateral surface* bears a triangular articular surface for the lateral malleolus. The surface is concave from above downwards, and its apex forms the lateral tubercle of the talus. The posterior part of the lateral surface is separated from the trochlea by an ill-defined, small triangular area which articulates with the inferior transverse tibiofibular ligament (Fig. 2.39d).

The *posterior process* is small and is marked by an oblique groove. The groove is bounded by medial and lateral tubercles. The lateral tubercle is occasionally separate (5%) and is then called the *os trigonum*.

Attachments on the Talus

The talus is devoid of muscular attachments, but numerous ligaments are attached to it because it takes part in three joints, e.g. ankle, talocalcaneal and talonavicular:

- 1 The following ligaments are attached to the neck
 - a. The distal part of the dorsal surface provides attachment to the *capsular ligament of the ankle joint* and to the *dorsal talonavicular ligament*. The proximal part of the dorsal surface lies within the ankle joint.
 - b. The inferior surface provides attachment to the *interosseous talocalcaneal and cervical ligaments*.



Figs 2.39a to d: Right talus: (a) Superior view, (b) inferior view, (c) medial view, and (d) lateral view

- c. The lateral part of the neck provides attachment to the anterior talofibular ligament (Figs 2.31 and 2.39d).
- 2 The lower, nonarticular part of the medial surface of the body gives attachment to the *deep fibres of the deltoid or anterior tibiotalar ligament* (Fig. 2.39c).
- 3 The groove on the posterior process lodges the tendon of the flexor hallucis longus (Fig. 2.39a).

The medial tubercle provides attachment to the *superficial fibres of the deltoid ligament (posterior tibiotalar)* above and the *medial talocalcanean ligament* below.

Posterior talofibular ligament is attached to upper part of posterior process while *posterior talocalcanean ligament* is attached to its plantar border (Figs 2.39a and d).

OSSIFICATION

The talus ossifies from one centre which appears during the 6th month of intrauterine life.

CLINICAL ANATOMY

- Forced dorsiflexion may cause fracture of the neck of the talus.
- If arteries to body of talus go through the neck only as occurs in some cases, the body would get avascular necrosis in fracture of its neck (Fig. 2.40).

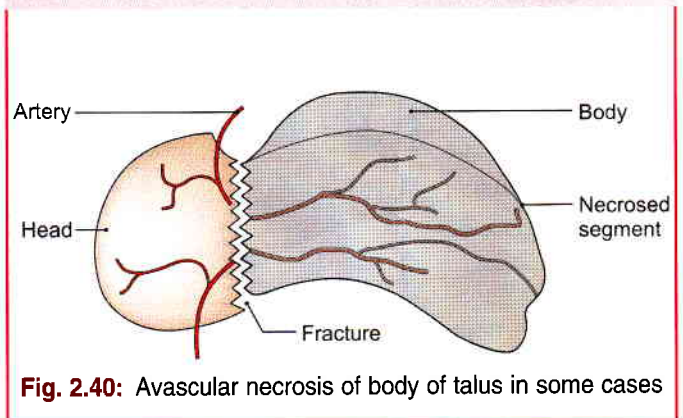


Fig. 2.40: Avascular necrosis of body of talus in some cases



CALCANEUS OR CALCANEUM

The calcaneus (Latin *heel*) is the largest tarsal bone. It forms the prominence of the heel. Its long axis is directed forwards, upwards and laterally. It is roughly cuboidal and has six surfaces (Fig. 2.41a).

Side Determination

- 1 The anterior surface is small and bears a concavoconvex articular facet for the cuboid. The posterior surface is large and rough.
- 2 The dorsal or upper surface bears a large convex articular surface in the middle. The plantar surface is rough and triangular (Figs 2.41a and b).
- 3 The lateral surface is flat, and the medial surface concave from above downwards (Fig. 2.41c).

Features

The *anterior surface* is the smallest surface of the bone. It is covered by a concavoconvex, sloping articular surface for the cuboid (Fig. 2.41c).

The *posterior surface* is divided into three areas, upper, middle and lower. The upper area is smooth while the others are rough.

The *dorsal or superior surface* can be divided into three areas. The posterior one-third is rough. The middle one-third is covered by the posterior facet for articulation with the facet on inferior surface of body of talus. This

facet is oval, convex and oblique. The anterior one-third is articular in the anteromedial part, and nonarticular in its posterolateral part. The articular part is in the form of an elongated middle facet present on the sustentaculum tali and anterior facet. These two facets articulate respectively with posterior facet and anteromedial facets on inferior aspect of head of talus.

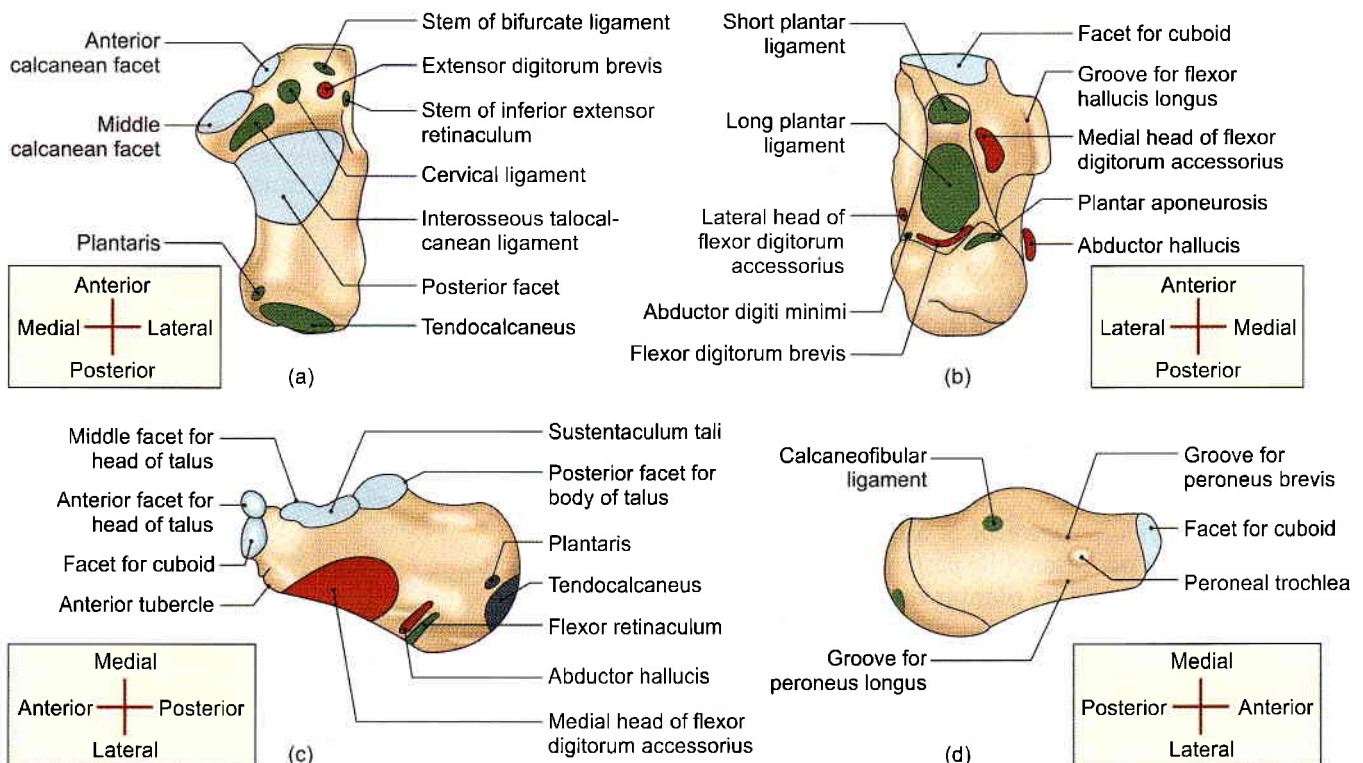
The *plantar surface* is rough and marked by three tubercles. The medial and lateral tubercles are situated posteriorly, whereas the anterior tubercle lies in the anterior part.

The *lateral surface* is rough and almost flat. It presents in its anterior part, a small elevation termed the *peroneal trochlea* or *tubercle* (Fig. 2.41d).

The *medial surface* is concave from above downwards. The concavity is accentuated by the presence of a shelf-like projection of bone, called the *sustentaculum tali*, which projects medially from its anterosuperior border. The upper surface of this process assists in the formation of the talocalcaneonavicular joint. Its lower surface is grooved; and the medial margin is in the form of a rough strip convex from before backwards (Fig. 2.41c).

Attachments and Relations of the Calcaneus

- 1 The middle rough area on the posterior surface receives the insertion of the tendocalcaneus and of the plantaris. The upper area is covered by a bursa.



Figs 2.41a to d: Right calcaneus: (a) Superior view, (b) inferior view, (c) medial view, and (d) lateral view

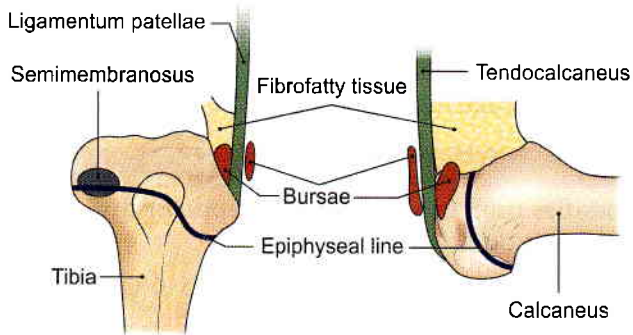


Fig. 2.42: Comparison of the tendocalcaneus and the ligamentum patellae

The lower area is covered by dense fibrofatty tissue and supports the body weight while standing. It can be compared to the attachment of ligamentum patellae (Fig. 2.42).

- 2 The lateral part of the nonarticular area on the anterior part of the dorsal surface provides:
 - a. Origin to the *extensor digitorum brevis* (Fig. 2.41a).
 - b. Attachment to the stem of the *inferior extensor retinaculum*.
 - c. Attachment to the stem of the *bifurcate ligament*. The medial, narrow part of the nonarticular area forms the sulcus calcanei, and provides attachment to the *interosseous talocalcanean ligament* medially and the *cervical ligament* laterally (Fig. 12.17).
- 3 Plantar surface:
 - i. The *medial tubercle*:
 - a. Origin for the *abductor hallucis* medially.
 - b. Attachment to the *flexor retinaculum* medially.
 - c. Origin to the *flexor digitorum brevis* anteriorly.
 - d. Attachment to the *plantar aponeurosis* anteriorly (Fig. 2.41b).
 - ii. The *lateral tubercle* gives origin to the *abductor digiti minimi*, the origin extending to the front of the tubercle.
 - iii. The *anterior tubercle* and the rough area in front of it provide attachment to the *short plantar ligament*. The rough strip between the three tubercles affords attachment to the *long plantar ligament* (Fig. 2.41b).
- 4 The attachments and relations of the lateral surface are as follows. The peroneal tubercle lies between the tendons of the *peroneus brevis* above and the *peroneus longus* below. The trochlea itself gives attachment to a slip from the inferior peroneal retinaculum. The *calcaneofibular ligament* is attached about 1 cm behind the peroneal trochlea (Fig. 2.41d).
- 5 The attachments and relations of the medial surface are as follows. The groove on the lower surface of the sustentaculum tali is occupied by the tendon of the *flexor hallucis longus*. The medial margin of the

sustentaculum tali is related to the tendon of the *flexor digitorum longus* and provides attachment to:

- a. The *spring ligament* anteriorly (see Fig. 13.5).
- b. A slip from the *tibialis posterior* in the middle.
- c. Some of the superficial fibres of the *deltoid ligament* along the whole length.
- d. The *medial talocalcanean ligament* posteriorly. Below the groove for the flexor hallucis longus, the medial groove gives origin to the fleshy fibres of the *medial head of the flexor digitorum accessorius* (Fig. 2.41b).

OSSIFICATION

The calcaneus ossifies from one primary and one secondary centres. The primary centre appears during the 3rd month of intrauterine life. The secondary centre appears between 6 and 8 years to form a scale-like epiphysis on the posterior surface, which fuses with the rest of the bone by 14–16 years.

CLINICAL ANATOMY

- Fracture of the calcaneum results by a fall from a height. Sustentaculum tali may get fractured in forced inversion of the foot.
- Calcaneum may develop a 'spur', which is painful (Fig. 2.43).

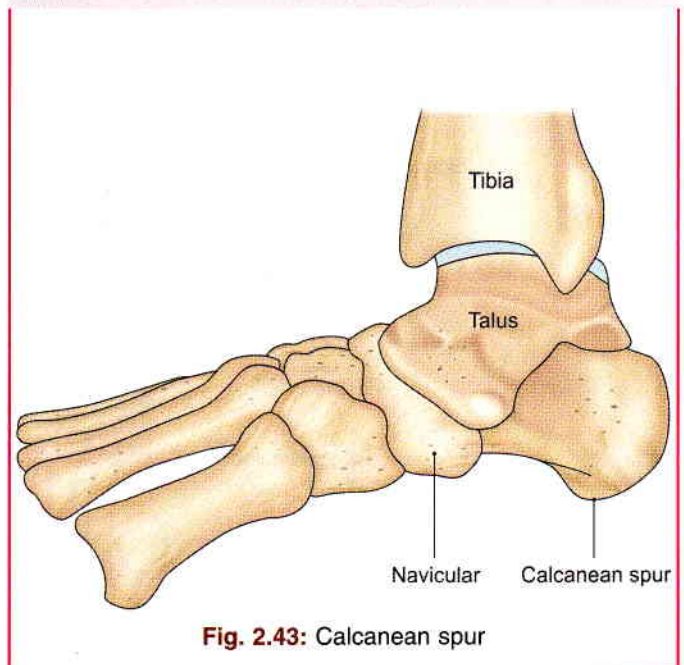


Fig. 2.43: Calcanean spur

NAVICULAR BONE

The navicular bone is boat-shaped. It is situated on the medial side of the foot, in front of the head of the talus, and behind the three cuneiform bones.



Features

- 1 The anterior surface is convex, is divided into three facets for the three cuneiform bones.
- 2 The posterior surface is concave and oval for articulation with the head of the talus.
- 3 The dorsal surface is broad and convex from side to side. It is rough for the attachment of ligaments (Fig. 2.44).
- 4 The plantar surface is small and slightly concave from side to side. It is rough and nonarticular.
- 5 The medial surface has a blunt and prominent *tuberosity*, directed downwards, the tuberosity is separated from the plantar surface by a *groove*.
- 6 The lateral surface is rough and irregular, but frequently has a facet for the cuboid.

Attachments

- 1 Tuberosity of the navicular bone receives the principal insertion of the tibialis posterior. The groove below the tuberosity transmits a part of the tendon of this muscle to other bones.
- 2 Plantar surface provides attachment to the spring ligament or plantar calcaneonavicular ligament.

- 3 Calcaneonavicular part of the bifurcate ligament is attached to the lateral surface. To the dorsal surface are attached the talonavicular, cuneonavicular and cubonavicular ligaments.

OSSIFICATION

It ossifies from one centre which appears during the third year of life.

CUNEIFORM BONES

Common Features

- 1 There are three cuneiform bones, medial, intermediate and lateral. The medial cuneiform is the largest and the intermediate cuneiform, the smallest (Fig. 2.44).
- 2 As their name suggests, these are wedge-shaped bones. In the medial cuneiform, the edge of the wedge forms the dorsal surface. In the intermediate and lateral cuneiforms, the thin edge of wedge forms the plantar surface.
- 3 The anterior parts of the medial and lateral cuneiforms project further forwards than the intermediate cuneiform. This forms a deep recess for the base of second metatarsal bone.

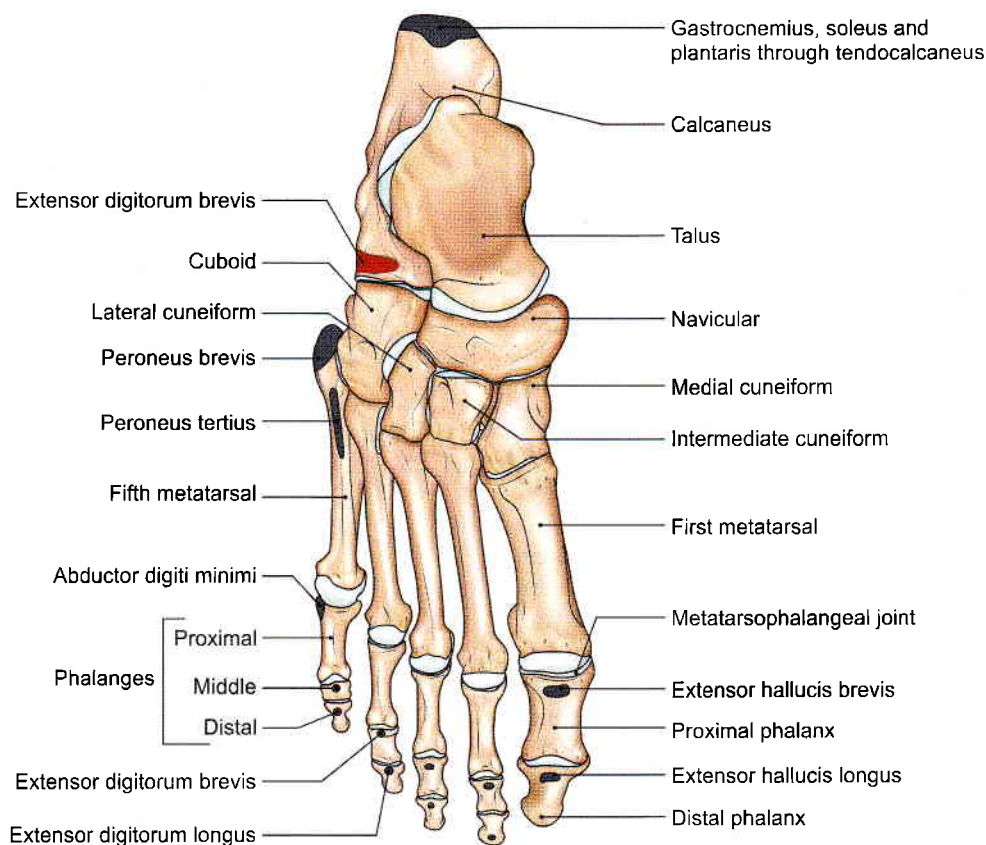
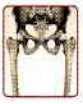

Fig. 2.44: Skeleton of the foot as seen from the dorsal aspect



MEDIAL CUNEIFORM

Features

- 1 Dorsal surface is formed by the rough edge of the wedge.
- 2 Plantar surface is formed by the base of the wedge.
- 3 Distal surface has a large kidney-shaped facet for the base of the first metatarsal bone, with its hilum directed laterally.
- 4 Proximal surface is a pyriform facet for the navicular.
- 5 Medial surface is rough and subcutaneous.
- 6 Lateral surface is marked by an inverted L-shaped facet along the posterior and superior margins for the intermediate cuneiform bone. The anterosuperior part of the facet is separated by a vertical ridge. This part is for the base of second metatarsal bone. The anteroinferior part of the lateral surface is roughened.

Attachments

- 1 The greater part of the tibialis anterior is inserted into an impression on the anteroinferior angle of the medial surface (see Fig. 8.5).
- 2 The plantar surface receives a slip from the tibialis posterior (see Fig. 12.23).
- 3 A part of the peroneus longus is inserted into the rough anteroinferior part of the lateral surface (see Fig. 8.12).

INTERMEDIATE CUNEIFORM

Features

- 1 The proximal and distal surfaces bear triangular articular facets.
- 2 The lateral surface is marked by a vertical facet along its posterior margin. This facet is for the lateral cuneiform bone. It is indented in the middle.
- 3 The plantar surface is formed by the edge of the wedge.

Attachments

The plantar surface receives a slip from the tibialis posterior.

LATERAL CUNEIFORM

Features

- 1 The proximal surface is rough in its lower one-third, and has a triangular facet in its upper two-thirds for the navicular bone.
- 2 The lateral surface is marked in its posterosuperior part by a triangular or oval facet for the cuboid.
- 3 The plantar surface is formed by the edge of the wedge.

Attachments

The plantar surface receives a slip from the *tibialis posterior*.

OSSIFICATION

Each cuneiform bone ossifies from one centre, which appears during the first year in the lateral cuneiform, during the second year in the medial cuneiform, and during the third year in the intermediate cuneiform bone.

CUBOID

The cuboid is the lateral bone of the distal row of the tarsus, situated in front of the calcaneum and behind the fourth and fifth metatarsal bones. It has six surfaces.

Features

- 1 The *proximal surface* is concavoconvex for articulation with the calcaneum.
- 2 The *distal surface* is also articular. It is divided by a vertical ridge into two areas for the fourth and fifth metatarsal bones.
- 3 The *dorsal surface* is rough for the attachment of ligaments. It is directed upwards and laterally.
- 4 The *plantar surface* is crossed anteriorly by an *oblique groove*. The groove is bounded posteriorly by a prominent ridge.
- 5 The *lateral surface* is short and notched.
- 6 The *medial surface* is extensive, being partly articular and partly nonarticular. An oval facet in the middle articulates with the lateral cuneiform bone. Proximal to this a small facet may present for the navicular bone.

Attachments

- 1 The notch on the lateral surface, and the groove on the plantar surface, are occupied by the tendon of the *peroneus longus* (see Fig. 12.23).
- 2 The ridge posterior to the groove gives attachment to the deep fibres of the long *plantar ligament* (see Fig. 12.23).
- 3 The *short plantar ligament* is attached to the posterior border of the plantar surface.
- 4 The posteromedial part of the plantar surface provides:
 - a. Insertion to a slip from the *tibialis posterior*.
 - b. Origin to the *flexor hallucis brevis*.
- 5 The nonarticular part of the medial surface provides attachment to ligaments, including the lateral limb of the *bifurcate ligament*.

OSSIFICATION

The cuboid bone ossifies from one centre which appears just before birth.



METATARSUS

- 1 The metatarsus is made up of 5 metatarsal bones, which are numbered from medial to lateral side.
- 2 Each metatarsal is a miniature long bone and has the following parts.
 - a. The *shaft* which is slightly convex dorsally and concave ventrally in its longitudinal axis. It is prismoid in form, and tapers from base to the head.
 - b. The *base* or proximal end is set obliquely in such a way that it projects backwards and laterally.
 - c. The *head* or distal end is flattened from side to side.

Metacarpals versus Metatarsals

The metatarsals are quite similar to metacarpals. The differences between the metacarpals and metatarsals shown in Table 2.1.

Table 2.1: Differences between metacarpals and metatarsals

Metacarpal	Metatarsal
1. The head and shaft are prismoid	1. The head and shaft are flattened from side to side
2. The shaft is of uniform thickness	2. The shaft tapers distally
3. The dorsal surface of the shaft has an elongated, flat triangular area	3. The dorsal surface of the shaft is uniformly convex
4. The base is irregular	4. The base appears to be cut sharply and obliquely

Identification

First Metatarsal

- 1 This is the *shortest*, *thickest* and *stoutest* of all metatarsal bones and is adapted for transmission of the body weight (Fig. 2.44).
- 2 The proximal surface of the base has a kidney-shaped facet, which is concave outwards.

Second Metatarsal

- 1 This is the *longest* metatarsal. It has a wedge-shaped base (Fig. 2.44).
- 2 The lateral side of the base has two articular facets, a larger dorsal, and a smaller plantar each of which is subdivided into a proximal part for the lateral cuneiform bone and a distal part for the third metatarsal.
- 3 The medial side of the base bears one facet, placed dorsally, for the medial cuneiform.

Third Metatarsal

- 1 The lateral side of the base has one facet, placed dorsally, for the fourth metatarsal bone.

- 2 The medial side of the base has two facets, dorsal and plantar for second metatarsal bone.

Fourth Metatarsal

- 1 The proximal surface of the base is quadrangular. It articulates with the cuboid bone.
- 2 The lateral side of the base has one facet, placed dorsally, for the fifth metatarsal bone.
- 3 The medial side of the base has one facet placed dorsally, which is subdivided into a proximal part for the lateral cuneiform and a distal part, for third metatarsal bone.

Fifth Metatarsal

- 1 The lateral side of the base has a large tuberosity or styloid process projecting backwards and laterally.
- 2 The medial side of the base has one facet for the fourth metatarsal bone.
- 3 The plantar surface of the base is grooved by the tendon of the *abductor digiti minimi*.

Important Attachments to Metatarsal Bones

- 1 A part of the *tibialis anterior* is inserted on the medial side of the base of the first metatarsal bone (see Fig. 12.23).
- 2 The greater part of the *peroneus longus* is inserted on a large impression at the inferior angle of the lateral surface of the base of the first metatarsal bone (see Fig. 12.23).
- 3 The *peroneus brevis* is inserted on the dorsal surface of the tuberosity of the fifth metatarsal bone (Fig. 2.44).
- 4 The *peroneus tertius* is inserted on the medial part of the dorsal surface of the base and the medial border of the shaft of the fifth metatarsal bone (Fig. 2.44).
- 5 The *flexor digiti minimi brevis* arises from the plantar surface of the base of the fifth metatarsal bone.
- 6 The shafts of metatarsal bones give origin to *interossei* (see Figs 10.7 and 10.8).

OSSIFICATION

Each metatarsal bone ossifies from one primary and one secondary centre. The primary centre appears in the shaft during the tenth week of foetal life in the first metatarsal, and during the ninth week of foetal life in the rest of the metatarsals (Fig. 2.45).

A secondary centre appears for the base of the first metatarsal during the third year, and for the heads of the other metatarsals between three and four years. All secondary centres unite with the shaft by 18th year. A separate centre for the tuberosity of the fifth metatarsal bone may be present.

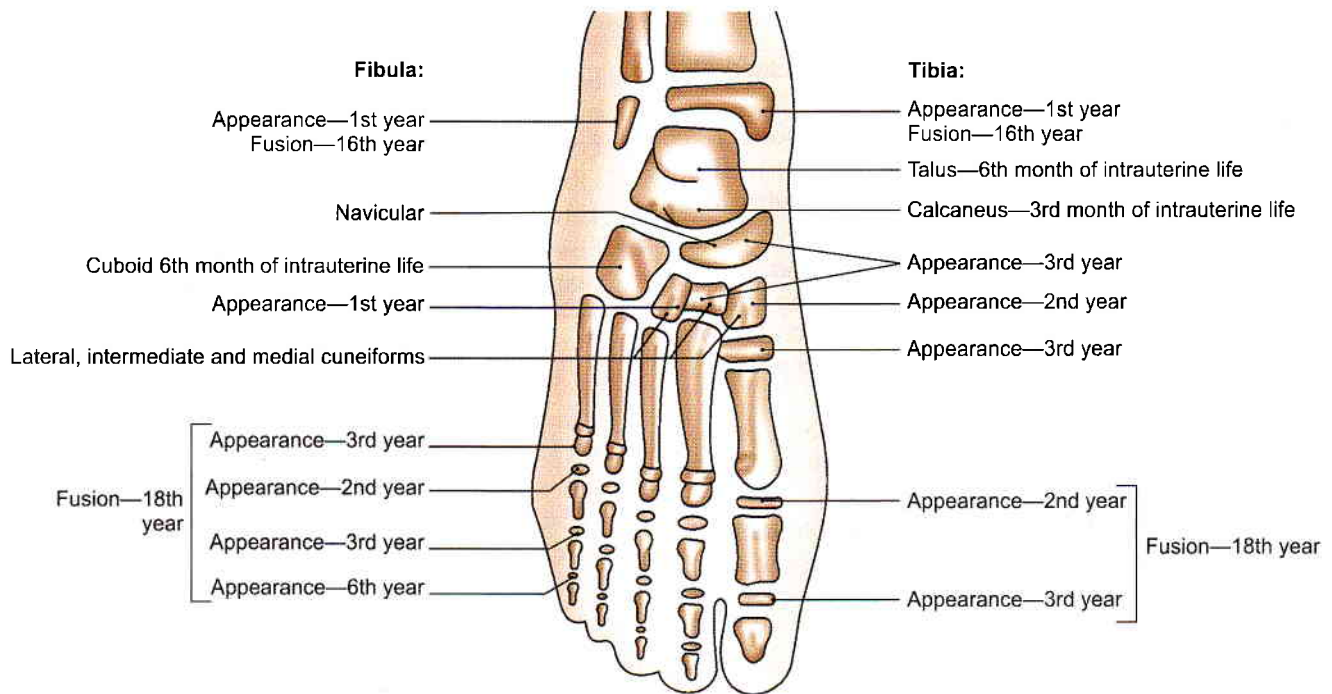
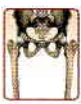

Fig. 2.45: Ossification of foot bones

PHALANGES

There are 14 phalanges in each foot; 2 for the great toe and 3 for each of the other toes. As compared to the phalanges of the hand, these are much smaller in size, and the shafts particularly of first row are compressed from side to side. Otherwise their arrangement and features are similar in two limbs.

Attachments

- 1 On bases of distal phalanges
 - a. Lateral four toes, *flexor digitorum longus* on the plantar surface, and the *extensor expansion* on the dorsal surface (see Fig. 10.5).
 - b. Great toe, *flexor hallucis longus* on the plantar surface, and the *extensor hallucis longus* on the dorsal surface (see Fig. 10.5).
- 2 On shaft and bases of middle phalanges
Flexor digitorum brevis on each side of the shaft on plantar surface (see Fig. 10.4a); and *extensor expansion* on the dorsal surface.
- 3 On bases of proximal phalanges
 - a. Second, third and fourth toes: A *lumbrical* muscle on the medial side, and an *interosseous* muscle on each side (see Figs 10.5, 10.7 and 10.8).
 - b. Fifth toe: A *plantar interosseous* muscle on the medial side, and the *abductor digiti minimi* and the *flexor digiti minimi brevis* on the lateral side (see Figs 10.6a and 10.7).
 - c. Great toe, *abductor hallucis* and part of the *flexor hallucis* medially, *adductor hallucis* and the remaining

part of the *flexor hallucis brevis* laterally (see Figs 10.4a. and 10.6a).

- 4 The *fibrous flexor sheath* is attached to the margins of the proximal and middle phalanges of the lateral four toes.

OSSIFICATION

Phalanx ossifies by one primary centre for the shaft which appears in tenth week of foetal life. The single secondary centre appears in the base. It appears in the proximal phalanx in second year, middle phalanx in third year and in distal phalanx in the sixth year. These fuse with the respective shafts by eighteenth year. The big toe has two phalanges and their secondary centres appear in second and third years to fuse with shaft in 18th year (Fig. 2.45).

CLINICAL ANATOMY

- Adventitious bursae develop due to excessive or abnormal friction, e.g. bursa over tendocalcaneus due to ill fitting shoes.
- Bunion is an adventitious bursa on the medial side of the head of 1st metatarsal bone.
- Fracture of tuberosity of 5th metatarsal bone may occur due to the pull of peroneus brevis muscle.
- Fracture of 2nd, 3rd, 4th or 5th metatarsal bones is common in soldiers and policemen and is called "march fracture".



SESAMOID BONES

The sesamoid (sesum, seed like) bones are located at the following sites.

- 1 The patella is, by far, the largest sesamoid bone.
- 2 There is one sesamoid bone (os peroneum) in the tendon of peroneus longus. It articulates with the cuboid.
- 3 Sesamoid bones may be present in the tendons of the tibialis anterior, the tibialis posterior, the lateral head of the gastrocnemius (fabella), the tendon of adductor longus (rider's bone) and the gluteus maximus.
- 4 There are two small sesamoids in the tendon of the flexor hallucis brevis. They articulate with the head of the first metatarsal bone.
- 5 Other tendons crossing the metatarsal, phalangeal and interphalangeal joints may have sesamoids.

Mnemonics

Attachments on linea aspera

I love **B**, **Mr. B** loves **me**

From lateral to medial side:

- Vastus **i**ntermedius
- Vastus **l**ateralis
- Short head of **b**iceps femoris
- Adductor **m**agnus
- Adductor **b**revis
- Adductor **l**ongus and **p**ectineus
- Vastus **m**edialis



FACTS TO REMEMBER

- Iliac crest of lower limb is used for bone marrow biopsy.
- Femur is the longest and strongest bone.
- Fibula is mostly used for bone graft.
- Talus bone has no muscle attachment.
- First metatarsal has two sesamoid bones on the plantar surface of its head.

CLINICOANATOMICAL PROBLEM

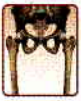A player was kicked hard on the lateral surface of right knee during a hockey game

- How do you feel the head of fibula?
- What important structure lies in relation to the neck of fibula?
- What are the effects of injury to the neck of fibula?

Ans: The head of fibula is palpated from the posterior aspect of knee joint. The head of fibula is subcutaneous and lies at the posterolateral aspect of the knee joint. The neck of fibula lies just beyond the head. The common peroneal nerve winds around the neck of fibula where it divides into superficial peroneal and deep peroneal nerves. In injury to the neck of fibula, common peroneal nerve is usually injured, causing paralysis of the dorsiflexors of foot supplied by deep peroneal nerve and of evertors of foot supplied by the superficial peroneal nerve, resulting in "foot drop" (see Fig. 8.10)

MULTIPLE CHOICE QUESTIONS

1. Which part of hip bone is used for taking bone marrow biopsy in anaemia or leukaemia?
 - a. Ilium
 - b. Iliac crest
 - c. ASIS
 - d. PSIS
2. The bone which is devoid of any muscle attachment?
 - a. Calcaneum
 - b. Navicular
 - c. Talus
 - d. Cuboid
3. Slight notch on lower border of the lateral malleolus of fibula give attachment to:
 - a. Anterior talofibular ligament
 - b. Inferior transverse tibiofibular ligament
 - c. Calcaneofibular ligament
 - d. Anterior Tibiofibular ligament
4. Which nerve is commonly injured in relation to neck of fibula?
 - a. Common peroneal nerve
 - b. Deep peroneal nerve
 - c. Superficial peroneal nerve
 - d. Tibial nerve
5. Medial strip on posterior surface of patella comes in contact with femur in:
 - a. Full flexion of knee
 - b. Midflexion
 - c. Extension
 - d. Slight flexion
6. Patella is developed in the tendon of:
 - a. Rectus femoris
 - b. Quadriceps femoris
 - c. Vastus medialis
 - d. Vastus intermedius
7. Which part of ischium forms efficient cushion for support body weight in sitting position?
 - a. Superolateral part of upper area
 - b. Inferomedial part of upper area



- c. Inner lower area
d. Outer lower area
8. The greater trochanter of femur does not give attachment to:
a. Gluteus minimus
b. Obturator internus
c. Gluteus medius
d. Psoas major
9. Which of the following bone has a groove on inferior surface for tendon of peroneus longus?
a. Talus b. Calcaneus
c. Navicular d. Cuboid
10. The medial surface of tibia gives insertion to all *except*:
a. Sartorius b. Gracilis
c. Semitendinosus d. Soleus
11. The nerve supply of tibialis anterior is:
a. Superficial peroneal nerve
b. Deep peroneal nerve
c. Tibial
d. None of above
12. Adductor tubercle close to medial condyle of femur gives insertion to:
a. Adductor longus b. Adductor brevis
c. Adductor magnus d. Pectineus

ANSWERS

1. b 2. c 3. c 4. a 5. a 6. b 7. c 8. d 9. d 10. d 11. b 12. c

3



Front of Thigh

Those who sit idly in the expectation for Gods help are great fools
—Swami Dayanand Saraswati

INTRODUCTION

Front of thigh extends between the hip and knee joints. The superficial fascia contains one big vein, the great saphenous vein, besides the cutaneous nerves, vessels, lymphatics and lymph nodes. The upper third of thigh medially contains the femoral triangle, middle third carries the femoral vessels through the adductor canal. Front of thigh also contains a vast four-headed muscle, the quadriceps femoris, besides the iliopsoas in the uppermost region and adductor muscles on its medial side. Femoral hernia if occurs is seen in the upper medial region of front of thigh.

SURFACE LANDMARKS

Iliac crest is a thick, curved bony margin, forming laterally the lower margin of the waist. The hands are often supported on the iliac crests in a relaxed standing posture. *Anterior superior iliac spine* is the anterior end of the iliac crest (Fig. 3.1). *Tubercle of the iliac crest* is a low bony prominence situated on the outer lip of the iliac crest about 5.0 cm behind the anterior superior iliac spine.

Fold of groin is a shallow curved groove which separates the front of the thigh from the anterior abdominal wall. It represents the flexion crease of the thigh and overlies the inguinal ligament which extends from the anterior superior iliac spine to the pubic tubercle. The downward convexity of the ligament is due to the pull exerted by the fascia lata of the thigh.

Pubic tubercle is a small bony projection felt at the medial end of the fold of groin. Pubic symphysis is formed in the median plane between the right and left pubic bones. Pubic crest is a short bony ridge between the pubic tubercle and pubic symphysis (Fig. 3.2).

The *greater trochanter* of femur lies a hand's-breadth (about 12.5 cm) below the *tubercle of iliac crest*, forming

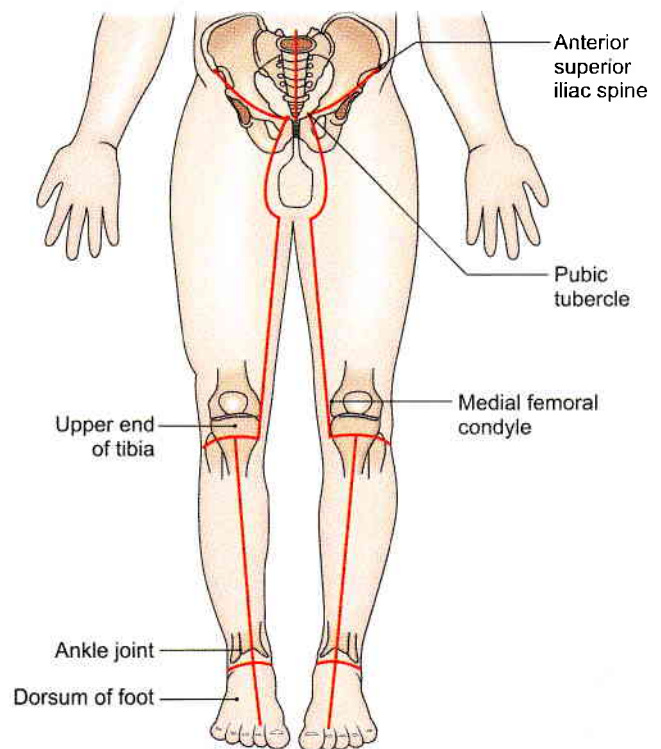


Fig. 3.1: Lines of dissection

a wide (4.5 cm) prominence just in front of the hollow on the side of the hip. The upper margin of the trochanter lies about the same level as the pubic crest.

Midinguinal point lies midway between the anterior superior iliac spine and the pubic symphysis. The femoral artery and the head of the femur lie beneath the midinguinal point (Fig. 3.2).

Midpoint of inguinal ligament lies slightly lateral to midinguinal point. It is the middle point of inguinal ligament. Femoral nerve lies beneath it.

Patella (knee cap) is the largest sesamoid bone of the body, developed in the tendon of quadriceps femoris.

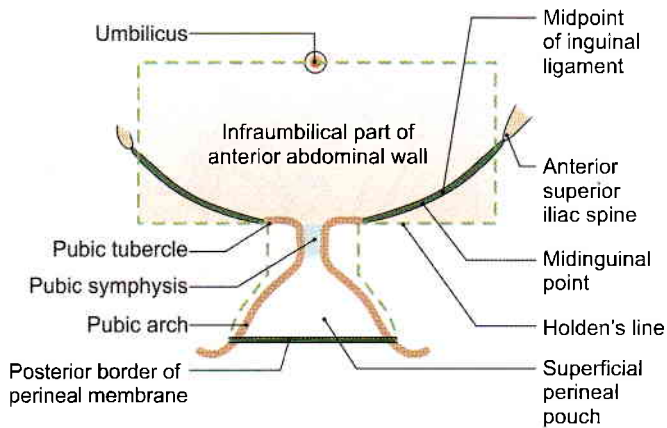


Fig. 3.2: The superficial area into which urine may pass when urethra is injured. The areas within the interrupted lines have a well-defined membranous layer of superficial fascia

It is easily seen and felt in front of the knee. It can be moved freely in a fully extended knee.

Tibial tuberosity is a blunt prominence in front of the upper end of tibia, marking the upper end of the shin.

Ligamentum patellae extends from the apex of patella to the tibial tuberosity. It represents the tendon (5×2.5 cm) of the quadriceps femoris which can be felt best in a half flexed knee.

The medial and lateral *condyles of the femur* and of the *tibia* form large bony masses at the sides of the knee. The most prominent points on the sides of the femoral condyles are called the medial and lateral epicondyles. Vastus medialis forms a fleshy prominence above the medial condyle of femur, particularly in an extended knee.

Adductor tubercle is a bony projection from the uppermost part of the medial condyle of femur to which the tendon of adductor magnus is attached. To palpate the tubercle, flex the knee partly and note the wide, shallow groove that appears posterior to the mass of vastus medialis. The tendon of adductor magnus can be felt in this groove. The tendon can be traced down to the adductor tubercle.

SKIN AND SUPERFICIAL FASCIA

DISSECTION

Make a curved incision from anterior superior iliac spine to the pubic tubercle.

Give a curved incision around the scrotum/pudendal cleft towards upper medial side of thigh. Extend it vertically down below the medial condyle of tibia till the level of tibial tuberosity.

Now make a horizontal incision below the tibial tuberosity till the lateral side of leg (Fig. 3.1).

Reflect the skin laterally, exposing the superficial fatty and deeper membranous layers of superficial fascia. Remove the fatty layer.

Identify the great saphenous vein in the medial part of anterior surface of thigh. Draining into its upper part are its three superficial tributaries, namely superficial circumflex iliac, superficial epigastric and superficial external pudendal. The vertical group of superficial inguinal lymph nodes lie along the upper part of great saphenous vein.

Dissect the superficial inguinal ring 1 cm above and lateral to the pubic tubercle. The spermatic cord and ilioinguinal nerve leave the abdomen through this ring.

Trace the great saphenous vein backwards till it pierces the specialised deep fascia known as cribriform fascia to drain into the femoral vein enclosed in the femoral sheath.

SKIN

The skin of thigh in the region around pubic symphysis, is studded with hair. The presence of few stitches indicates that embalming for preservation of the body has been done from this site.

Procedure for embalming: A 6 cm long vertical incision is given in the upper medial side of thigh. After reflecting skin and fasciae, femoral sheath is incised to visualise the femoral artery. About 10 litres of embalming fluid prepared by mixing appropriate amounts of formalin, glycerine, water, red lead, common salt, etc. is put in the embalming machine connected to a cannula.

A small nick is given in the femoral artery and cannula introduced so that its tip points towards the head end and 8.5 litres of fluid is pumped under 20 lb pressure. Then the direction of cannula is reversed and rest of fluid is pumped in. Lastly, the skin and fasciae are sutured.

SUPERFICIAL FASCIA

The superficial fascia has *two layers*, a superficial fatty layer and a deep membranous layer, which are continuous with the corresponding layers of the anterior abdominal wall. The two layers are most distinct in the uppermost part of the thigh, near the groin, where the cutaneous nerves, vessels and lymph nodes lie between the two layers.

The membranous layer is loosely attached to the deep fascia of the thigh except near the inguinal ligament, where it is firmly attached along a horizontal line. The line of firm attachment is called *Holden's line*. It begins a little lateral to the pubic tubercle and extends laterally for about 8 cm (Fig. 3.2).

The importance of this Holden's line is as follows.

When the urethra is injured in the perineum, urine may flow out or extravasate into the interval deep to the membranous layer of superficial fascia. This urine can pass up into the anterior abdominal wall from where it can enter the upper part of the thigh. However, the firm attachment of the membranous layer of superficial fascia to the deep fascia along Holden's line prevents urine from descending into the thigh beyond the line.

The superficial fascia contains cutaneous nerves, cutaneous arteries, the great saphenous vein and its tributaries, and the superficial inguinal lymph nodes. The nerves and vessels are described below. The inguinal lymph nodes are described later.

Cutaneous Nerves

The skin of the front of the thigh is supplied by following cutaneous nerves derived directly, or indirectly, from the lumbar plexus (Fig. 3.3).

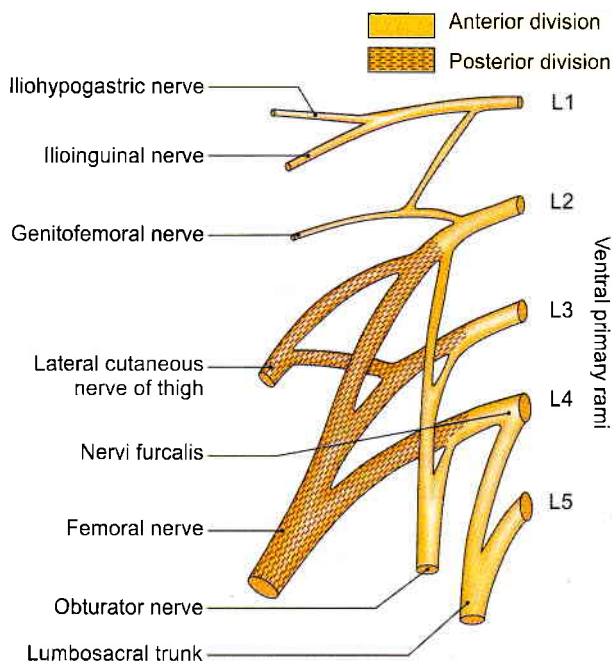


Fig. 3.3: The lumbar plexus and its branches

The *ilioinguinal nerve* (L1) emerges at the superficial inguinal ring, and supplies the skin at the root of the penis or over the mons pubis in the female, the anterior one-third of the scrotum or labium majus, and the superomedial part of the thigh (Fig. 3.4).

The *femoral branch of genitofemoral nerve* (L1, L2) pierces the femoral sheath and the overlying deep fascia 2 cm below the midinguinal point, and supplies most of the skin over the femoral triangle (Fig. 3.4).

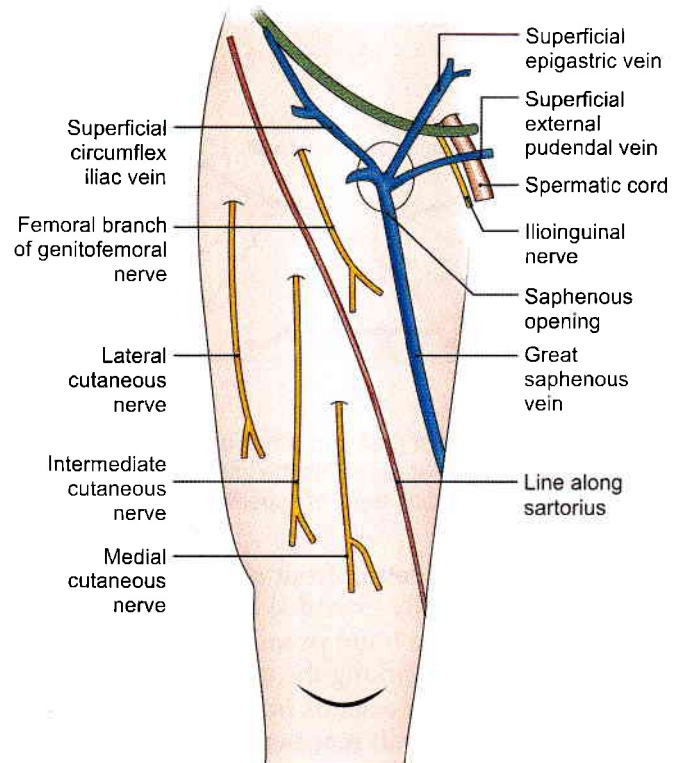


Fig. 3.4: Superficial veins and nerves seen on the front of the thigh

The *lateral cutaneous nerve of thigh* (L2, L3) is a branch of the lumbar plexus. It emerges behind the lateral end of the inguinal ligament, divides into anterior and posterior branches, and supplies the skin on the anterolateral side of the thigh and on the anterior part of the gluteal region.

The *intermediate cutaneous nerve of thigh* (L2, L3) is a branch of the anterior division of the femoral nerve. It pierces the deep fascia at the junction of the upper one-third and middle one-third of the thigh. It divides into two or more branches and supplies a strip of skin on the front of the thigh extending from the sartorius to the knee.

The *medial cutaneous nerve of the thigh* (L2, L3) is a branch of the anterior division of the femoral nerve. It divides into anterior and posterior divisions. The nerve supplies the skin on the medial side of the lower two-thirds of the thigh.

The *saphenous nerve* (L3, L4) is a branch of the posterior division of the femoral nerve. It pierces the deep fascia on the medial side of the knee, runs down in front of the great saphenous vein, and supplies the skin on the medial side of the leg and foot up to the ball of the big toe (see Fig. 8.2).

Before piercing the deep fascia the saphenous nerve gives off the *infrapatellar branch* which runs downwards



and laterally, and supplies the skin over the ligamentum patellae.

Patellar Plexus

It is a plexus of fine nerves situated in front of the patella, the ligamentum patellae and the upper end of the tibia. It is formed by contributions from:

- 1 The anterior division of the lateral cutaneous nerve
- 2 The intermediate cutaneous nerve
- 3 The anterior division of the medial cutaneous nerve
- 4 The infrapatellar branch of the saphenous nerve.

Cutaneous Arteries

Three small arteries arising from the femoral artery can be seen a little below the inguinal ligament (Fig. 3.11).

- 1 *Superficial external pudendal artery* pierces the cribriform fascia, runs medially in front of the spermatic cord, and supplies the external genitalia.
- 2 *Superficial epigastric artery* pierces the cribriform fascia, runs towards the umbilicus, and supplies the lower part of anterior abdominal wall.
- 3 *Superficial circumflex iliac artery* pierces the fascia lata lateral to saphenous opening, runs upwards below the inguinal ligament, and anastomoses at the anterior superior iliac spine with deep circumflex iliac, superior gluteal and lateral circumflex femoral arteries.

Great or Long Saphenous Vein

This is the largest and longest superficial vein of the lower limb (*Saphes* = easily seen).

It begins on the dorsum of the foot from the medial end of the dorsal venous arch, and runs upwards in front of the medial malleolus, along the medial side of the leg, and behind the knee. In the thigh, it inclines forwards to reach the saphenous opening where it pierces the cribriform fascia and opens into the femoral vein. Before piercing the cribriform fascia, it receives three named tributaries corresponding to the three cutaneous arteries, and also many unnamed tributaries (see Figs 3.4 and 11.1).

Superficial Inguinal Lymph Nodes

The superficial inguinal lymph nodes are variable in their number and size. Their arrangement is T-shaped, there being a lower vertical group and an upper horizontal group. The upper nodes can be subdivided into the upper lateral and upper medial groups (Fig. 3.5).

- 1 Lower vertical group drains lymph from most of the lower limb.
- 2 Upper lateral group drains lymph from infra-umbilical part of anterior abdominal wall and gluteal region.

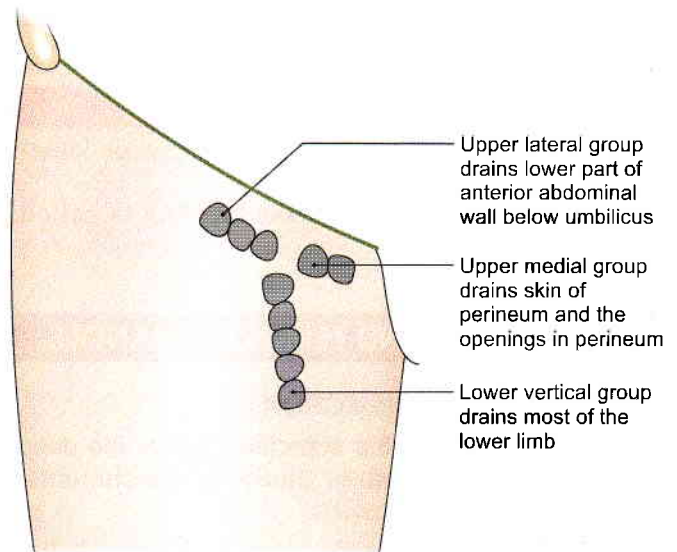


Fig. 3.5: Superficial inguinal lymph nodes

- 3 Upper medial group drains lymph from external genital organs including the terminal ends of the urethra, anal canal and vagina.

Subcutaneous Bursae

Bursae are lubricating mechanisms which are provided at sites of friction to smoothen movement. Undue pressure on them may cause their pathological enlargement. Bursae present in relation to the patella are described here (Fig. 3.6).

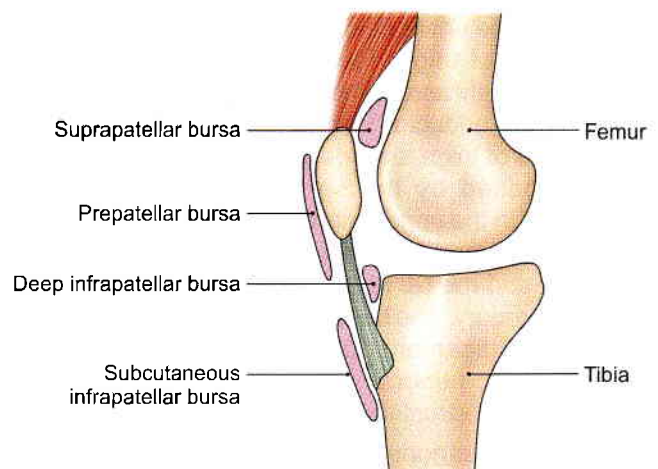


Fig. 3.6: The patellar bursae

Prepatellar Bursa

It lies in front of the lower part of the patella and of the upper part of the ligamentum patellae.

Subcutaneous Infrapatellar Bursa

It lies in front of lower part of the tibial tuberosity and of the lower part of the ligamentum patellae.

Two deep bursae are also present. These are suprapatellar bursa and deep infrapatellar bursa.

CLINICAL ANATOMY

- Prepatellar bursitis is called "housemaids knee" or miner's knee.
- Subcutaneous infrapatellar bursitis is called "clergyman's knee."

DEEP FASCIA AND FEMORAL TRIANGLE

DISSECTION

After the reflection of the superficial fascia, the deep fascia of thigh is visible. Study its attachments, modifications and extensions.

Follow the great saphenous vein through the cribriform fascia and the anterior wall of femoral sheath into the femoral vein. The femoral vein occupies the intermediate compartment of the femoral sheath. Medial compartment of femoral sheath is the femoral canal occupied by a lymph node while the lateral compartment is occupied by the femoral artery.

Give a vertical incision in the deep fascia of thigh from tubercle of iliac crest till the lateral condyle of femur and remove the deep fascia or fascia lata in lateral part of thigh. This will expose the tensor fasciae latae muscle and gluteus maximus muscle getting attached to iliotibial tract. Identify the four heads of quadriceps femoris muscle.

Remove the entire deep fascia from upper one-third of the front of thigh. Identify the sartorius muscle stretching gently across the thigh from lateral to medial side and the adductor longus muscle extending from medial side of thigh towards lateral side into the femur, being crossed by the sartorius. This triangular depression in the upper one-third of thigh is the femoral triangle. The medial border of sartorius forms lateral boundary and medial border of adductor longus forms medial boundary. The base of this triangle is formed by the inguinal ligament. Dissect its boundaries, and contents, e.g. femoral nerve, artery and vein, and accompanying structures.

Expose the sartorius muscle till its insertion into the upper medial surface of shaft of tibia.

DEEP FASCIA/FASCIA LATA

The fascia lata is a tough fibrous sheath that envelops the whole of the thigh like a sleeve. Its attachments, shown in Fig. 3.7, are as follows:

Superiorly it is attached to the boundary line between the lower limb and the pelvis. Thus anteriorly it is attached to the inguinal ligament; laterally to the iliac

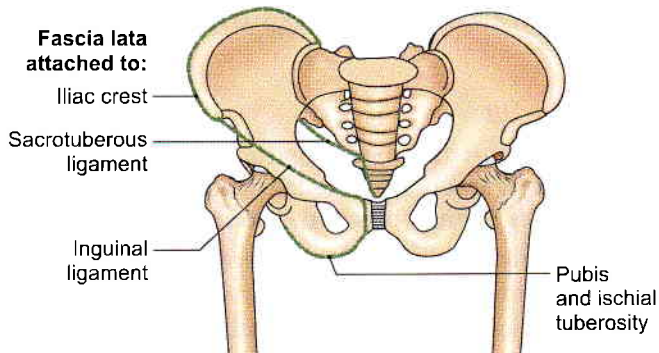


Fig. 3.7: The upper attachments of the fascia lata

crest; posteriorly, through the gluteal fascia to the sacrum, coccyx and sacrotuberous ligament; and medially to the pubis, the pubic arch and the ischial tuberosity.

Inferiorly, on the front and sides of the knee, the fascia lata is attached to subcutaneous bony prominences and the capsule of the knee joint. Posteriorly, it forms the strong popliteal fascia which is continuous below with the fascia of the back of the leg.

Modifications of Fascia Lata

Iliotibial Tract

The fascia lata is thickened laterally where it forms a 5 cm wide band called the iliotibial tract (Fig. 3.8). Superiorly the tract splits into two layers. The superficial lamina is attached to tubercle of iliac crest, and deep lamina to the capsule of hip joint. Inferiorly, the tract is attached to a smooth area on anterior surface of the lateral condyle of tibia. The importance of the iliotibial tract is as follows.

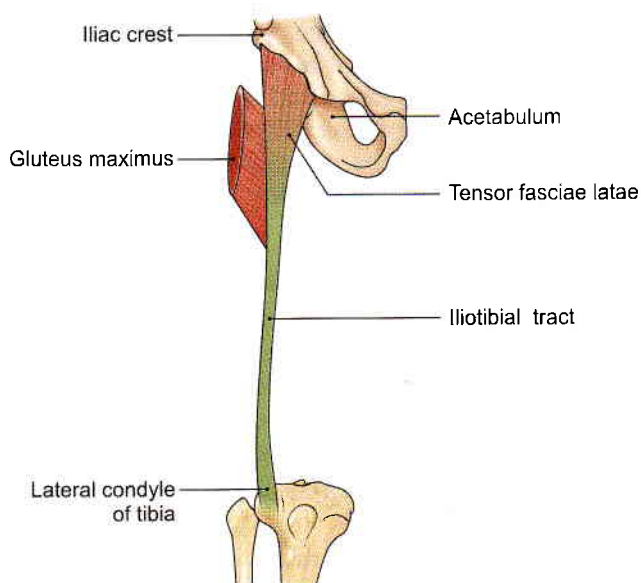


Fig. 3.8: The iliotibial tract with insertion of two muscles



- Two important muscles are inserted into its upper part, between the superficial and deep laminae. These are the three-fourths part of the *gluteus maximus*; and the *tensor fasciae latae*.
- The iliotibial tract stabilizes the knee both in extension and in partial flexion; and is, therefore, used constantly during walking and running. In leaning forwards with slightly flexed knees, the tract is the main support of the knee against gravity.

Saphenous Opening

This is an oval opening in the fascia lata. The centre of the opening is 4 cm below and 4 cm lateral to the pubic tubercle. It is about 2.5 cm long and 2 cm broad with its long axis directed downwards and laterally. The opening has a sharp crescentic lateral margin or falciform margin which lies in front of the femoral sheath. The medial well defined margin of the opening lies at a deeper level. It is formed by the fascia overlying the pectineus. The fascia passes behind the femoral sheath (Fig. 3.4).

The saphenous opening is closed by the *cribriform fascia* formed by modification of superficial fascia which covers the opening.

Intermuscular Septa

Three intermuscular septa divide the thigh into three compartments (Fig. 3.9).

The *lateral intermuscular septum* is the thickest of these septa. It extends from the iliotibial tract to the lateral lip of the linea aspera. It separates the anterior compartment of the thigh from the posterior compartment.

The *medial intermuscular septum* is attached to the medial lip of the linea aspera, and separates the anterior compartment of the thigh from the medial compartment.

The *posterior intermuscular septum* is poorly defined. It separates the medial compartment of the thigh from the posterior compartment.

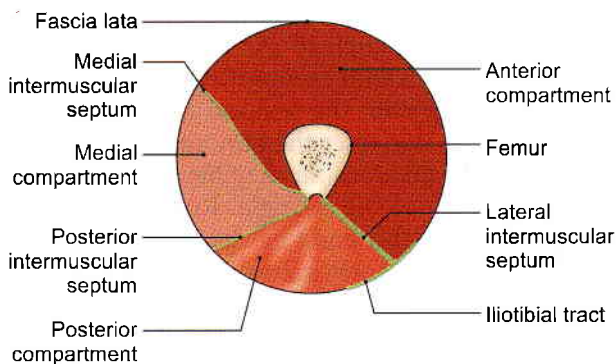


Fig. 3.9: Intermuscular septa and compartments of thigh

CLINICAL ANATOMY

The fascia lata is attached to the inguinal ligament. Extension of the thighs pulls the abdominal wall downwards and makes it tense. To relax the abdomen fully for palpation by an examining physician, the patient is asked to draw the legs up. This overcomes the pull of the fascia lata on the abdominal wall.

FEMORAL TRIANGLE

It is a triangular depression on the front of the upper one-third of the thigh immediately below the inguinal ligament.

Boundaries

The femoral triangle is bounded *laterally* by the medial border of *sartorius*; and *medially* by the medial border of the *adductor longus* (Figs 3.10 to 3.12). Its *base* is formed by the *inguinal ligament*. The *apex*, which is directed downwards, is formed by the point where the medial and lateral boundaries cross.

The apex is continuous, below, with the adductor canal.

The *roof* of the femoral triangle is formed by:

- Skin.
- Superficial fascia containing the superficial inguinal lymph nodes, the femoral branch of the genitofemoral nerve, branches of the ilioinguinal nerve, superficial branches of the femoral artery with accompanying veins, and the upper part of the great saphenous vein.
- Deep fascia*, with the saphenous opening and the cribriform fascia (Fig. 3.10b).

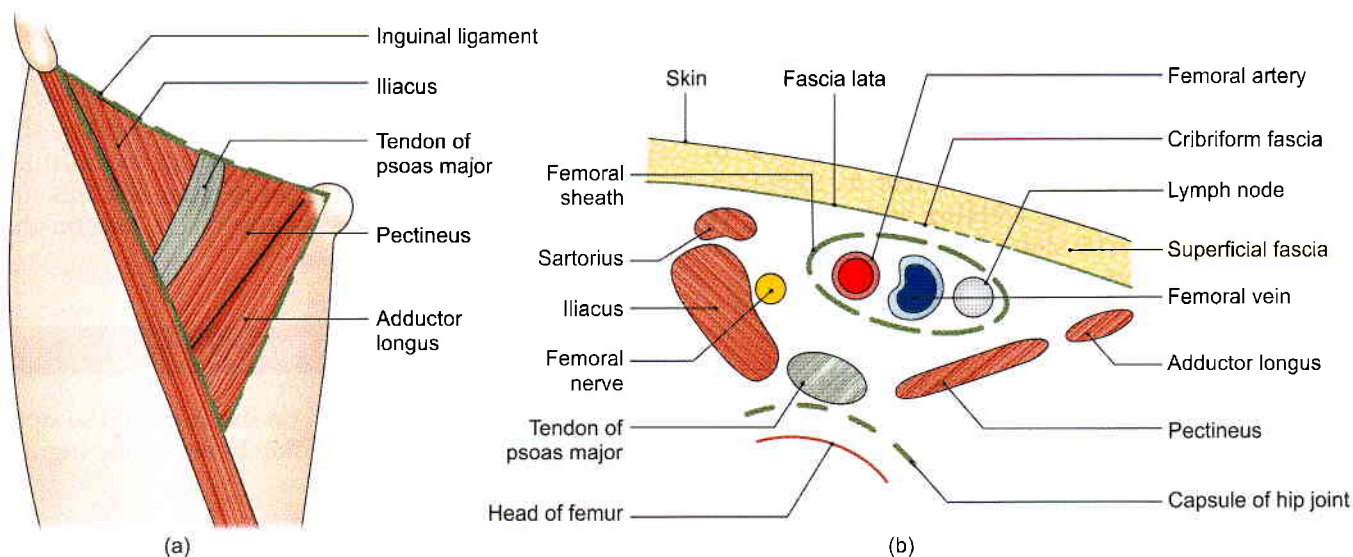
The *floor* of the triangle is formed medially by the *adductor longus* and *pectineus*, and laterally by the *psaos major* and *iliacus* (Figs 3.10 a and b).

Contents

The contents of the femoral triangle (Fig. 3.11) are as follows:

- Femoral artery and its branches:** The femoral artery traverses the triangle from its base at the midinguinal point to the apex. In the triangle, it gives off six branches, three superficial and three deep.
- Femoral vein and its tributaries:** The femoral vein accompanies the femoral artery. The vein is medial to the artery at base of triangle, but posteromedial to artery at the apex.

The femoral vein receives the great saphenous vein, circumflex veins and veins corresponding to the branches of femoral artery.



Figs 3.10a and b: Floor of the femoral triangle: (a) Surface view, and (b) sectional view

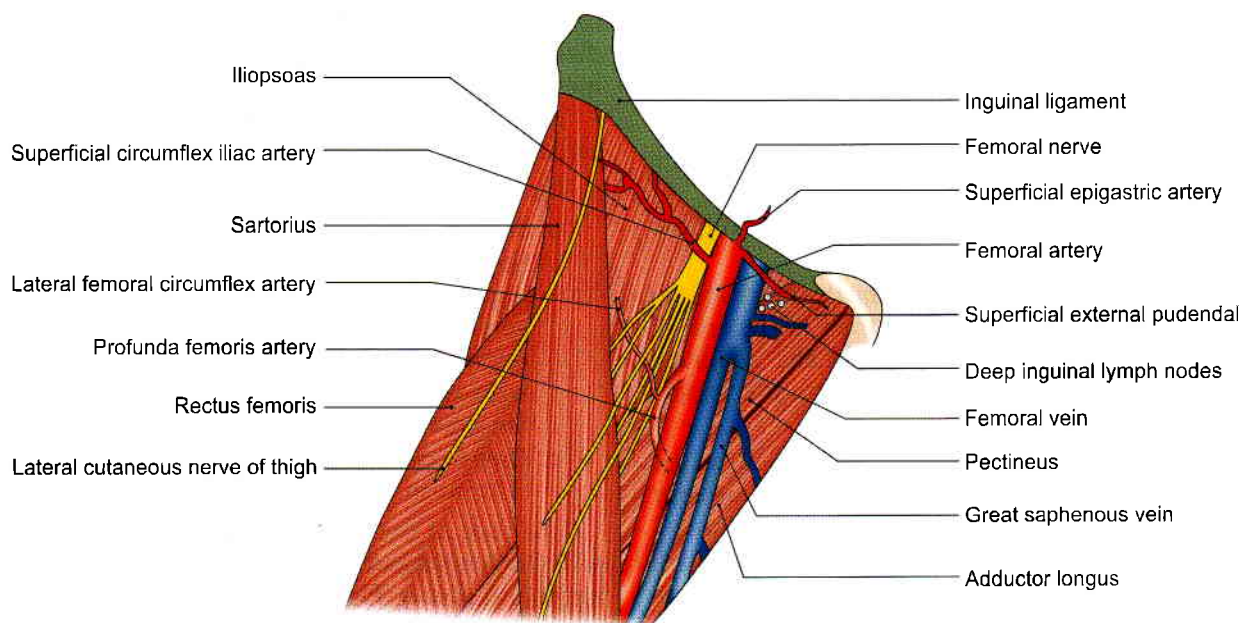


Fig. 3.11: Contents of the right femoral triangle

3 The *femoral sheath* encloses the upper 4 cm of the femoral vessels (Fig. 3.12).

4 *Nerves:*

a. The *femoral nerve* lies lateral to the femoral artery, *outside the femoral sheath*, in the groove between the iliacus and the psoas major muscles. It is described later.

b. The *nerve to the pectineus* arises from the femoral nerve just above the inguinal ligament. It passes behind femoral sheath to reach the anterior surface of pectineus.

c. The *femoral branch of the genitofemoral nerve* occupies the lateral compartment of the femoral sheath along with the femoral artery. It supplies most of the skin over the femoral triangle.

d. The *lateral cutaneous nerve of the thigh* crosses the lateral angle of the triangle. Runs on the lateral side of thigh and ends by dividing into anterior and posterior branches. These supply anterolateral aspect of front of thigh and lateral aspect of gluteal region respectively.

5 The *deep inguinal lymph nodes* lie deep to the deep fascia. These lie medial to upper part of femoral vein

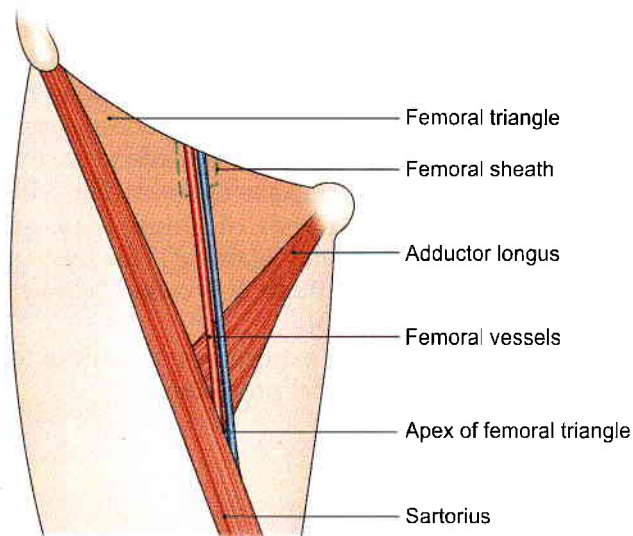


Fig. 3.12: Femoral sheath enclosing the upper parts of the femoral vessels

and receive lymph from superficial inguinal lymph nodes, from glans penis or clitoris and deep lymphatics of lower limb.

Femoral Sheath

This is a funnel-shaped sleeve of fascia enclosing the upper 3 to 4 cm of the femoral vessels. The sheath is formed by downward extension of two layers of the fascia of the abdomen. The anterior wall of the sheath is formed by the fascia transversalis which lies in the anterior abdominal wall deep to the transversus abdominis; and the posterior wall is formed by the fascia iliaca, which covers the iliacus muscle (Fig. 3.13). Inferiorly, the sheath merges with connective tissue around the femoral vessels.

The femoral sheath is asymmetrical. Its lateral wall is vertical, and the medial wall is oblique being directed downward and laterally (Fig. 3.14).

The sheath is divided into the following three compartments by septa (Fig. 3.14).

- The *lateral* or *arterial compartment* contains the *femoral artery* and the *femoral branch of the genitofemoral nerve*.
- The *intermediate* or *venous compartment* contains the *femoral vein*.
- The *medial* or *lymphatic compartment* is the smallest of all, and is known as the *femoral canal* which is described below.

Femoral Canal

This is the medial compartment of the femoral sheath. It is conical in shape, being wide above or at base and narrow below. It is about 1.5 cm long, and about 1.5 cm wide at the base (Figs 3.14, 3.15 and 3.18).

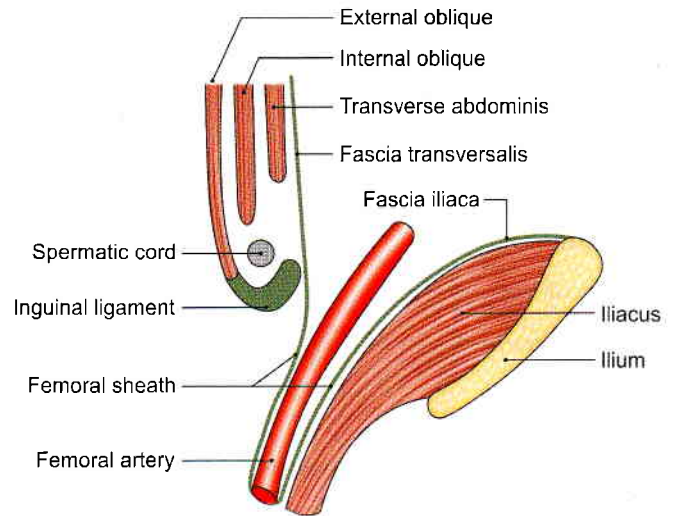


Fig. 3.13: Formation of the femoral sheath by extension of the fascia transversalis and the fascia iliaca into the thigh

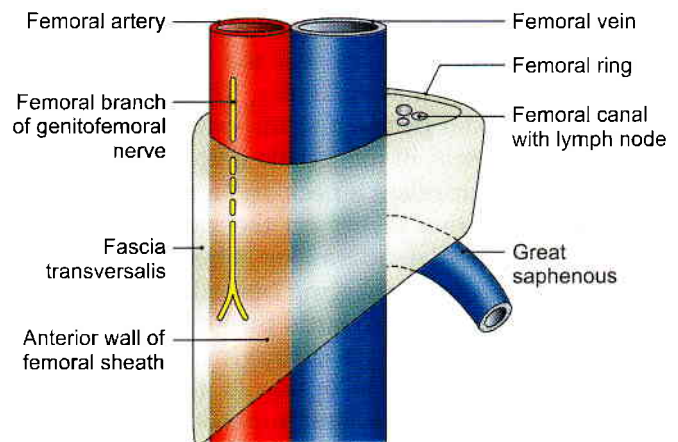


Fig. 3.14: Asymmetry of the right femoral sheath

The base or upper end of femoral canal is called *femoral ring*. The boundaries of ring are important.

It is *bounded* anteriorly by the inguinal ligament, posteriorly by pectineus and its covering fascia, medially by the concave margin of lacunar ligament, and laterally by the septum separating it from femoral vein.

The *inferior epigastric vessels* are closely related to junction of the anterior and lateral walls of ring. The femoral ring is closed by a condensation of extraperitoneal connective tissue called the *femoral septum*.

The parietal peritoneum covering septum from above shows a depression called *femoral fossa*.

The femoral canal contains a lymph node of *Cloquet* or of *Rosenmüller*, lymphatics, and a small amount of areolar tissue. The lymph node drains the glans penis in males and the clitoris in females.

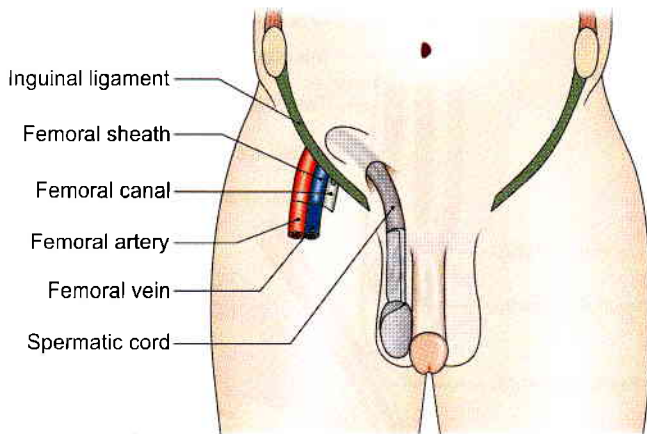


Fig. 3.15: Three compartments of femoral sheath

CLINICAL ANATOMY

- **Femoral hernia:** The femoral canal is an area of potential weakness in the abdominal wall through which abdominal contents may bulge out forming a femoral hernia. A femoral hernia is more common in females because the femoral canal is wider in them than in males. This is associated with the wider pelvis, and the smaller size of the femoral vessels, in the female (Fig. 3.16).

Hernia comprises a neck and a sac. Coverings are the various layers on the sac. Mostly the content of hernial sac is a loop of bowel (Fig. 3.17).

- The course of an enlarging hernial sac is typical. First it passes downwards through the femoral canal, then forwards through the saphenous opening, and finally upwards along with the superficial epigastric and superficial circumflex iliac vessels. For reduction of such a hernia the reverse course has to be followed (Fig. 3.18).
- In cases of strangulation of a femoral hernia, the surgeon has to enlarge the femoral ring. This is possible only by cutting the lacunar ligament; which forms the medial boundary of the ring. Normally this can be done without danger. Occasionally, however, an abnormal obturator artery may lie along the edge of the lacunar ligament; and cutting it may cause alarming haemorrhage (Fig. 3.19).
- **Abnormal obturator artery:** The normal obturator artery is a branch of the internal iliac. It gives a pubic branch which anastomoses with the pubic branch of the inferior epigastric artery. Occasionally, this anastomosis is large and the obturator artery then appears to be a branch of the inferior epigastric. Usually, the abnormal artery passes lateral to the femoral canal in contact with the femoral vein and is safe in an operation

to enlarge the femoral ring. Sometimes, however, the abnormal obturator artery may lie along the medial margin of the femoral ring, i.e. along the free margin of the lacunar ligament. Such an artery is likely to be cut if an attempt is made to enlarge the femoral ring cutting lacunar ligament (Fig. 3.19).

- Lateral cutaneous nerve of thigh may get entangled in the inguinal ligament. This leads to pain on lateral side of thigh. It is called "*meralgia parasthetica*" (Fig. 3.20B).
- The femoral artery is exposed in the adductor canal for various surgical procedures.

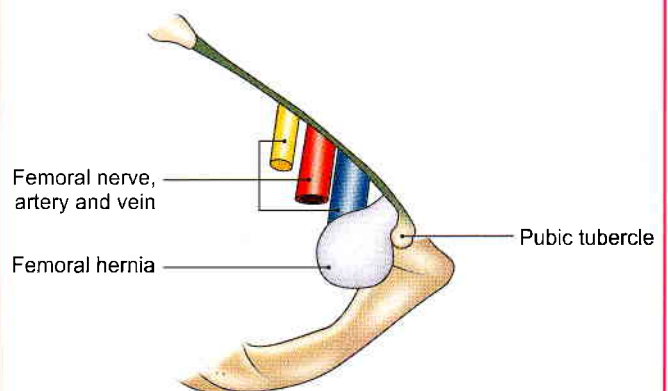


Fig. 3.16: Femoral hernia

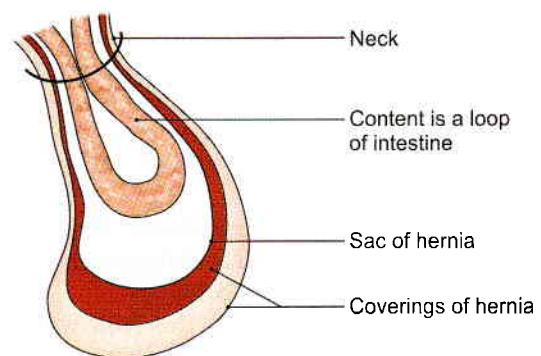


Fig. 3.17: Hernial sac with loop of bowel

FEMORAL ARTERY

This is the chief artery of the lower limb. Developmentally it is not derived from the axis artery. The original axis artery in the uppermost part of the limb is represented by the inferior gluteal artery.

Origin

It is the continuation of external iliac artery. It begins behind the inguinal ligament at the midinguinal point.

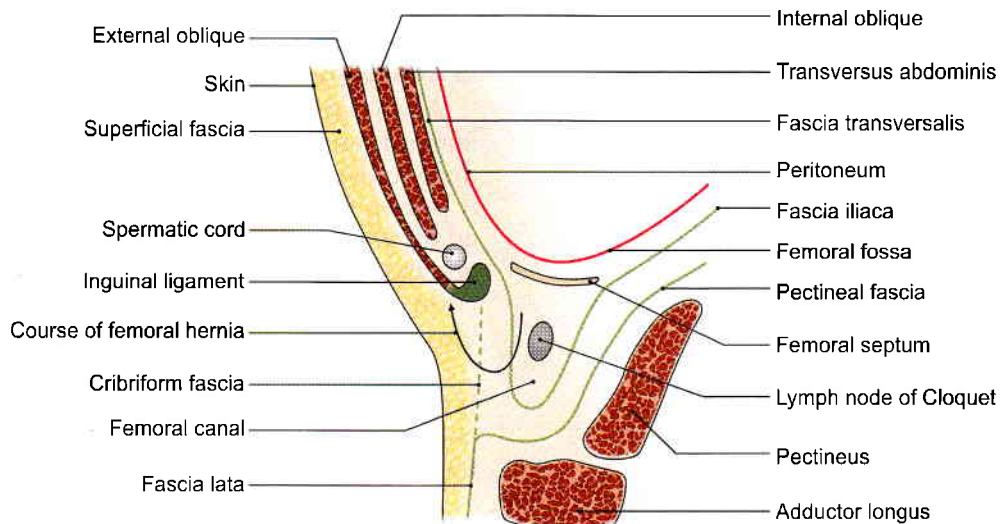


Fig. 3.18: Femoral canal and the course of a femoral hernia

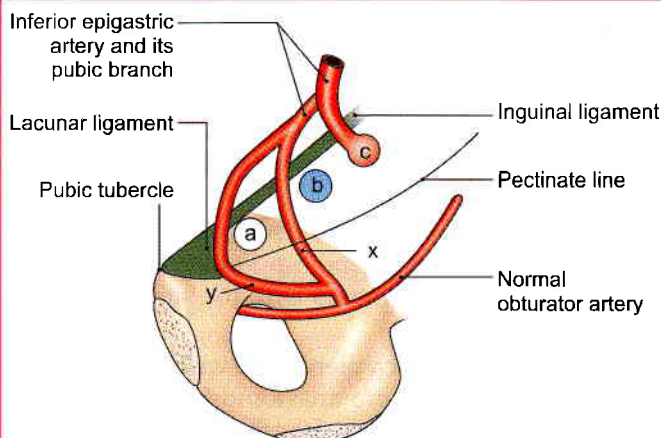


Fig. 3.19: Pubic region seen from behind to show the course of an abnormal obturator artery: a = femoral canal; b = femoral vein; c = junction of external iliac and femoral arteries; x = usual safe course of abnormal obturator artery; y = occasional dangerous position of artery

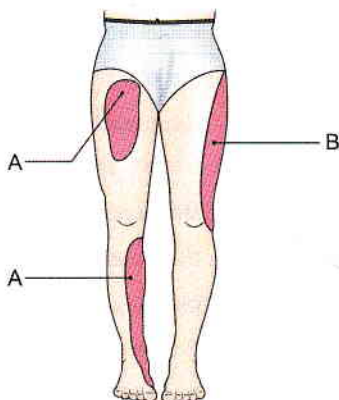


Fig. 3.20: (A) Sensory loss due to injury to femoral nerve, and (B) meralgia parasthetica

Extent and Course

It passes downwards and medially, first in the femoral triangle, and then in the adductor canal. At the lower end of the adductor canal, i.e. at the junction of the middle and lower thirds of the thigh it passes through an opening in the adductor magnus to become continuous with the popliteal artery (Fig. 3.21).

Relations of Femoral Artery in Femoral Triangle

Anterior: Skin, superficial fascia, deep fascia and the anterior wall of the femoral sheath.

Posterior: Psoas major, the pectineus, and the adductor longus. The posterior wall of the femoral sheath intervenes between these structures and the artery (Fig. 3.22).

Medial: The femoral vein. Just below the inguinal ligament the vein is medial to the artery. However, the vein gradually crosses to the lateral side posterior to the artery. It is directly behind the artery at the apex of the femoral triangle, and lateral to the lower end of the artery.

Lateral: The femoral nerve is lateral to the upper part of the artery. Lower down the artery is related to the branches of the nerve.

Branches in the Femoral Triangle

The femoral artery gives off three superficial and three deep branches in the femoral triangle.

The superficial branches are:

- Superficial external pudendal supplies the skin of external genital organs (Fig. 3.11).
- Superficial epigastric for skin and fasciae of lower part of anterior abdominal wall.
- Superficial circumflex iliac for skin along the iliac crest.

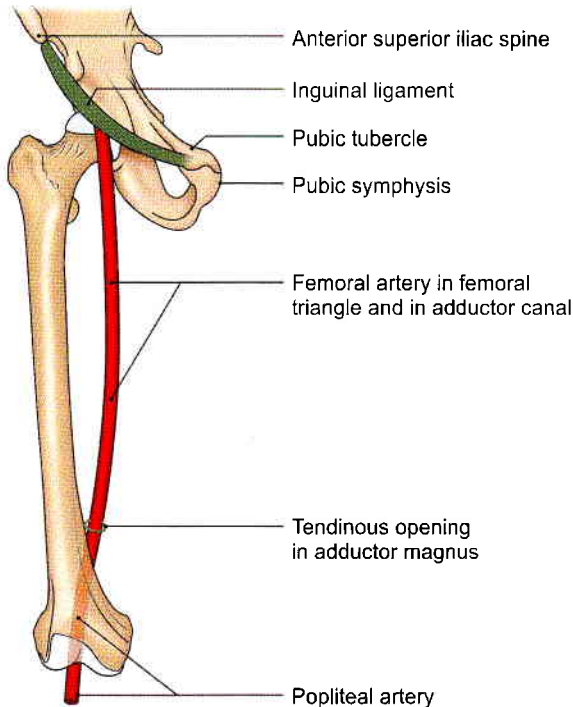


Fig. 3.21: Course and extent of the femoral artery

The deep branches are:

- Profunda femoris (Fig. 3.22)
- Deep external pudendal supplies the external genital organs.
- Muscular branches.

Profunda Femoris Artery

This is the largest branch of the femoral artery (Fig. 3.22). It is the chief artery of supply to all the three compartments of the thigh.

It arises from the lateral side of the femoral artery about 4 cm below the inguinal ligament. The origin lies in front of the iliacus.

As the artery descends, it passes posterior to the femoral vessels. It leaves the femoral triangle by passing deep to the adductor longus. Continuing downwards, it passes first between the adductor longus and the adductor brevis, and then between the adductor longus and the adductor magnus. Its terminal part pierces the adductor magnus to anastomose with upper muscular branches of the popliteal artery.

The profunda femoris artery gives off the medial and lateral circumflex femoral arteries, and three perforating arteries (see Fig. 7.12). It itself ends as the fourth perforating artery.

The *medial circumflex femoral artery* leaves the femoral triangle by passing posteriorly, between the pectineus and the psoas major muscles. It gives an acetabular branch and divides into an ascending and transverse branches. It supplies adductor muscles and head of femur.

The *lateral circumflex femoral artery* runs laterally between the anterior and posterior divisions of the femoral nerve, passes behind the sartorius and the rectus femoris, and divides into ascending, transverse and descending branches.

The ascending branch runs deep to the tensor fasciae latae, gives branches to the hip joint and the greater trochanter, and anastomoses with the superior gluteal artery.

The transverse branch pierces the vastus lateralis and takes part in the cruciate anastomosis on the back of the thigh just below the greater trochanter.

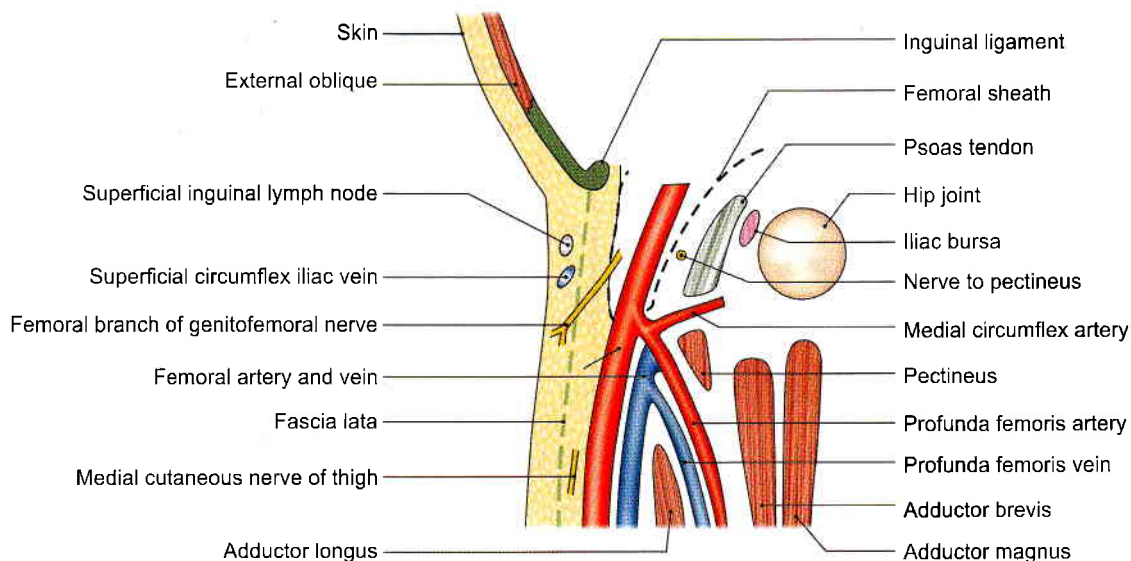


Fig. 3.22: Anterior and posterior relations of the femoral artery in the femoral triangle



The descending branch runs down along the anterior border of the vastus lateralis, accompanied by the nerve to that muscle.

Four *perforating arteries* are described in Chapter 7. These supply muscles attached to linea aspera.

Deep External Pudendal Artery

This branch of the femoral artery passes deep to the spermatic cord, or the round ligament of the uterus, and supplies the scrotum or the labium majus.

Muscular Branches

Numerous *muscular branches* arise from the femoral and profunda femoris artery, or its branches, to supply the muscles of the thigh.

CLINICAL ANATOMY

- The femoral artery can be compressed at the midinguinal point against the head of the femur or against the superior ramus of the pubis to control bleeding from the distal part of the limb in the thigh or leg.
- Pulsations of the femoral artery can be felt at the midinguinal point, against the head of the femur and the tendon of the psoas major. A bilateral absence or feebleness of the femoral pulse may result from coarctation or narrowing of the aorta, or thrombosis, i.e. clotting of blood within the aorta (Fig. 3.23).
- Stab wounds at the apex of the femoral triangle may cut all the large vessels of the lower limb because the femoral artery and vein, and the profunda femoris artery and vein are arranged in one line from before backwards at this site (Fig. 3.24). Injury to femoral vessels results in fatal haemorrhage.
- Since the femoral artery is quite superficial in the femoral triangle, it can be easily exposed for ligation, i.e. tying, or for passing a cannula or a thick needle. Catheters are passed upwards till the heart for certain minor operation (Fig. 3.25).
- The femoral vein is commonly used for *intravenous infusions in infants* and in patients with peripheral circulatory failure.

FEMORAL VEIN

It begins as an upward continuation of the popliteal vein at the lower end of the adductor canal, and ends by becoming continuous with the external iliac vein behind the inguinal ligament, medial to the femoral artery (Figs 3.11 and 3.14).

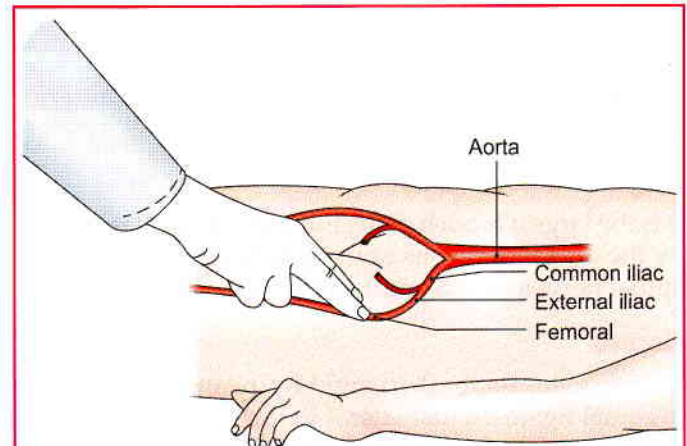


Fig. 3.23: Palpation of femoral pulse at midinguinal point

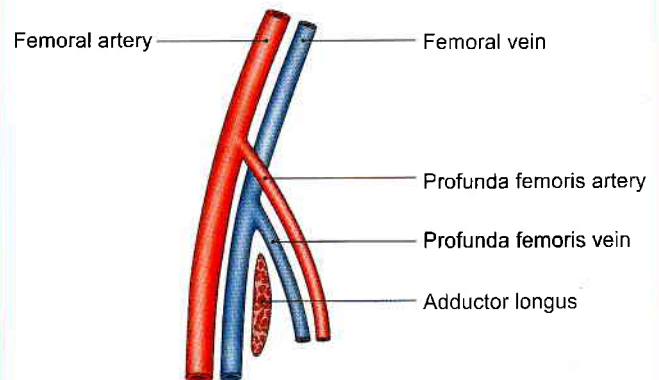


Fig. 3.24: Sagittal sectional view of four vessels

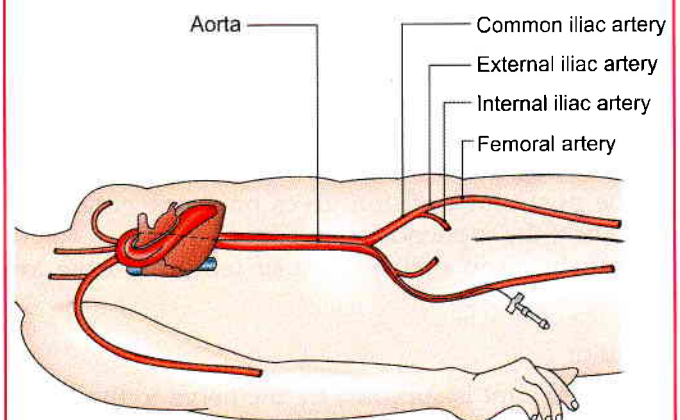


Fig. 3.25: Catheterisation of femoral artery

Tributaries: It receives:

- The great saphenous vein.
- Veins accompanying three deep branches of femoral artery in femoral triangle, i.e. profunda, deep external pudendal, and muscular.
- Lateral and medial circumflex femoral veins.
- The descending genicular and muscular veins in the adductor canal.



FEMORAL NERVE

The femoral nerve is the chief nerve of the anterior compartment of the thigh.

Origin and Root Value

It is the largest branch of the lumbar plexus. It is formed by the dorsal divisions of the anterior primary rami of spinal nerves L2, L3 and L4 (Fig. 3.3).

Course

It enters the femoral triangle by passing behind the inguinal ligament just lateral to the femoral artery.

In the thigh, it lies in the groove between the iliacus and the psoas major, outside the femoral sheath, and lateral to the femoral artery. The nerve is not included in the femoral sheath as its formation is behind the fascia iliaca which is forming posterior wall of the sheath.

After a short course of about 2.5 cm below the inguinal ligament, the nerve divides into anterior and posterior divisions which are separated by the lateral circumflex femoral artery (Figs 3.11 and 3.26).

BRANCHES AND DISTRIBUTION

Muscular

- 1 The anterior division supplies the sartorius.
- 2 The posterior division supplies the rectus femoris, the three vasti and the articularis genu. The articularis genu is supplied by a branch from the nerve to vastus intermedius.

Cutaneous

- 1 The anterior division gives two cutaneous branches, the intermediate and the medial cutaneous nerves of the thigh.
- 2 The posterior division gives only one cutaneous branch, the saphenous nerve.

Branches and distribution of femoral nerve are shown in Fig. 3.26.

Articular

- 1 The hip joint is supplied by the nerve to the rectus femoris.
- 2 The knee joint is supplied by the nerves to the three vasti. The nerve to the vastus medialis contains numerous proprioceptive fibres from the knee joint, accounting for the thickness of the nerve. This is in accordance with *Hilton's law*: Nerve supply to a muscle which lies across a joint, not only supplies the muscle, but also supplies the joint beneath and the skin overlying the muscle.

Vascular

To the femoral artery and its branches.

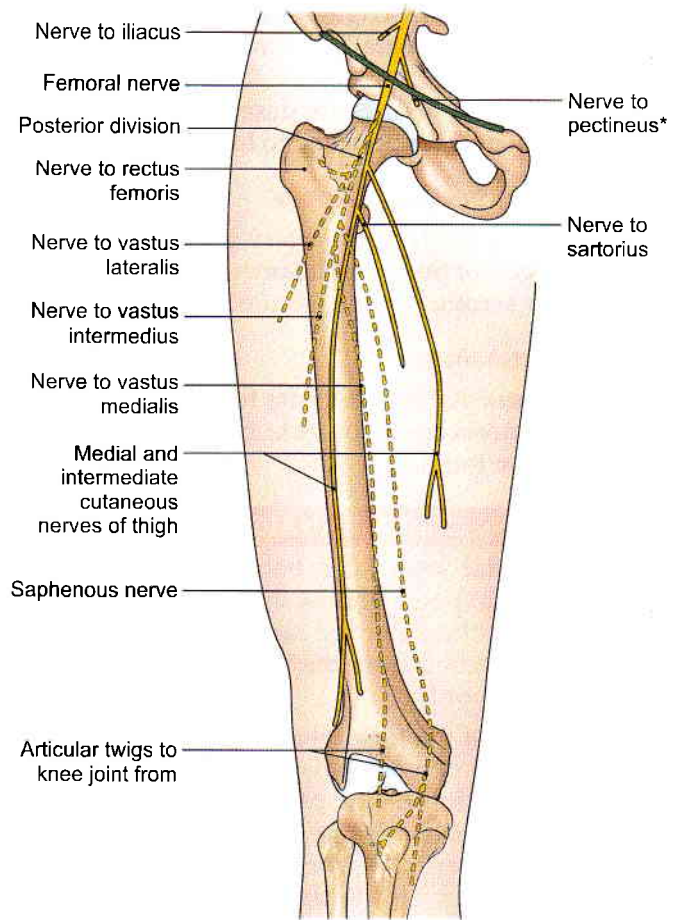


Fig. 3.26: The branches and distribution of femoral nerve

*The nerve to the pectineus arises from the medial side of the femoral nerve just above the inguinal ligament. It passes obliquely downwards and medially, behind the femoral sheath, to reach the anterior surface of the muscle.

CLINICAL ANATOMY

Injury to the femoral nerve by wounds in the groin, though rare, causes paralysis of the quadriceps femoris and a sensory deficit on the anterior and medial sides of the thigh and medial side of leg (Fig. 3.20A).

MUSCLES OF THE FRONT OF THE THIGH

The muscles of the anterior compartment of the thigh are the sartorius, the quadriceps femoris, and the articularis genu (Figs 3.27 and 3.28). In addition to these, some muscles belonging to other regions are also encountered on the front of the thigh. The iliacus and psoas major muscles, which form part of the floor of the femoral triangle, have their origin within the abdomen. The pectineus and adductor longus, also seen in relation to the femoral triangle, are muscles of the

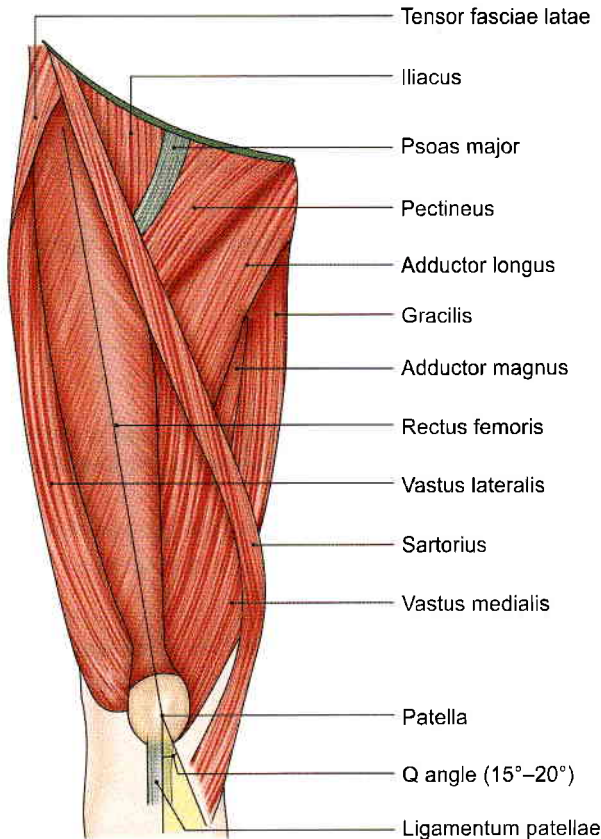


Fig. 3.27: Muscles seen on the front of the thigh

medial compartment of the thigh. They are described in Chapter 4. In the upper lateral corner of the front of the thigh, we see the tensor fasciae latae. This is a muscle of the gluteal region and is described in Chapter 5.

The *sartorius* (sartor = tailor) is long, narrow and ribbon—like. It runs downwards and medially across the front of the thigh. It is the longest muscle in the

body (Fig. 3.29). Its attachments are given in Table 3.1. Its nerve supply and actions are given in Table 3.2.

The *quadriceps femoris* is so called because it consists of four parts. These are the rectus femoris, the vastus lateralis, the vastus medialis, and the vastus intermedius. The rectus femoris is fusiform. It runs more or less vertically on the front of the thigh superficial to the vasti. The three vasti are wrapped around the shaft of the femur in the positions indicated by their names. The attachments of the components of the quadriceps femoris are given in Table 3.1. Their nerve supply and actions are given in Table 3.2.

The *articularis genu* consists of a few muscular slips that arise from the anterior surface of the shaft of the femur, a few centimetres above the patellar articular margin. They are inserted into the upper part of the synovial membrane of the knee joint. They pull the synovial membrane upwards during extension of the knee, thus preventing damage to it.

Iliacus and Psoas Major

These muscles form the lateral part of the floor of the femoral triangle. They are classified as muscles of the iliac region, and also among the muscles of the posterior abdominal wall. Since the greater parts of their fleshy bellies lie in the posterior abdominal wall, they will be described in detail in the section on the abdomen. However, on account of their principal action on the hip joint, the following points may be noted.

- 1 Both have a common insertion on the lesser trochanter of the femur and are the chief and powerful flexors of the hip joint.
- 2 Because of their common insertion and action, the two muscles are often referred to by a common name, the iliopsoas.

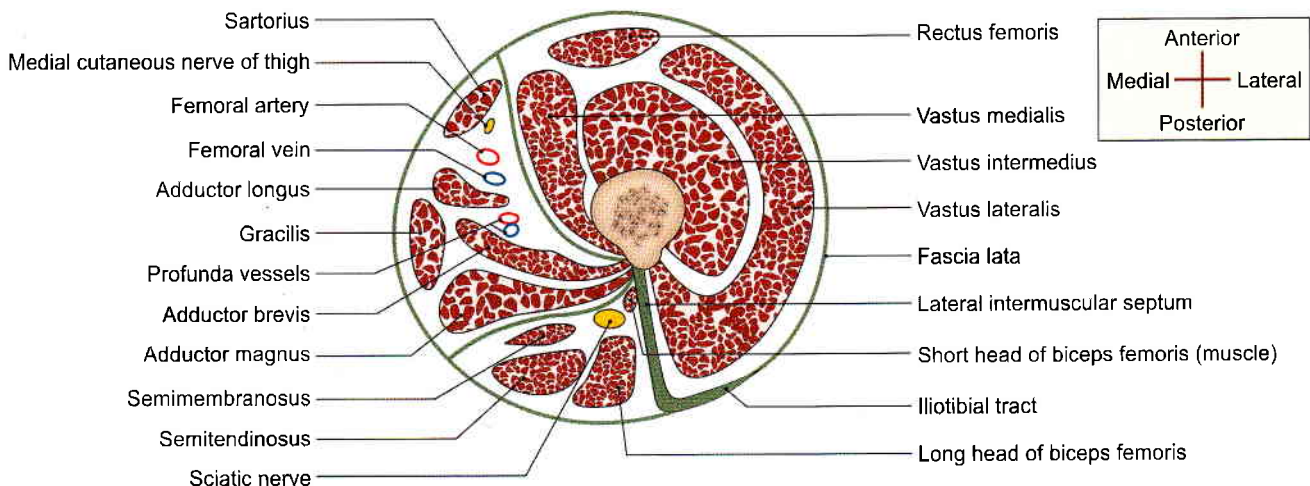


Fig. 3.28: Transverse section through the upper third of the thigh

**Table 3.1: Muscles of the anterior or extensor compartment of thigh**

<i>Muscle</i>	<i>Origin from</i>	<i>Insertion into</i>
1. Sartorius (Latin <i>tailor</i>) (Fig. 3.27)	<ul style="list-style-type: none"> • Anterior superior iliac spine • Upper half of the notch below the spine 	Upper part of the medial surface of the shaft of the tibia in front of the insertions of the gracilis and the semitendinosus
2. Quadriceps femoris		
A. Rectus femoris (Fig. 3.27) fusiform, superficial fibres bipennate, deep fibres straight	<ul style="list-style-type: none"> • Straight head: from the upper half of the anterior inferior iliac spine • Reflected head: from the groove above the margin of the acetabulum and the capsule of the hip joint 	Base of patella, anterior to vastus intermedius
B. Vastus lateralis (Fig. 3.27) forms large part of quadriceps femoris	The origin is linear from <ul style="list-style-type: none"> • Upper part of intertrochanteric line • Anterior and inferior borders of greater trochanter • Lateral lip of gluteal tuberosity • Upper half of lateral lip of linea aspera 	<ul style="list-style-type: none"> • Lateral part of the base of patella • Upper one-third of the lateral border of patella • Expansion to the capsule of knee joint, tibia and iliotibial tract
C. Vastus medialis (Fig. 3.27)	The origin is linear from <ul style="list-style-type: none"> • Lower part of intertrochanteric line • Spiral line • Medial lip of linea aspera • Upper one-fourth of medial supracondylar line 	Medial one-third of the base and upper two-thirds of the medial border of the patella
D. Vastus intermedius (Fig. 3.28)	Upper three-fourths of the anterior and lateral surfaces of the shaft of femur	Base of patella*
3. Articularis genu	Anterior surface of femur	Suprapatellar bursa/synovial membrane of knee joint

*The patella is a sesamoid bone in the tendon of the quadriceps femoris. The ligamentum patellae is the actual tendon of the quadriceps femoris, which is inserted into the upper part of tibial tuberosity

Table 3.2: Nerve supply and actions of muscles

<i>Muscle</i>	<i>Nerve supply</i>	<i>Actions</i>
1. Sartorius	Femoral nerve	Abductor and lateral rotator of thigh Flexor of leg at knee joint These actions are involved in assuming the position in which a tailor work, i.e. palthi posture used during prayer sessions also.
2. Quadriceps femoris		
A. Rectus femoris	Femoral nerve, this branch also supplies hip joint	Extensor of knee joint, also called "kicking muscle". Flexor of hip joint
B. Vastus lateralis	Femoral nerve, this branch also supplies knee joint	Extends knee joint, helps in standing, walking and running
C. Vastus medialis	Same as above	Extends knee joint, prevents lateral displacement of patella. Rotates femur medially during locking stage of extension of knee joint. Action is extremely important for stability of patella.
D. Vastus intermedius	Same as above	Extends knee joint
3. Articularis genu	Femoral nerve	It pulls the synovial membrane upwards during extension of the knee, thus preventing damage to it



- 3 Both are supplied by spinal segments L2 and L3. The psoas is supplied by the branches from the nerve roots, whereas the iliacus is supplied by the femoral nerve.

CLINICAL ANATOMY

- *Testing for Quadriceps Femoris:* A person lies supine with one bare lower limb and hip and knee joints partially flexed. The right hand of physician presses the person's right leg downwards. He is requested to straighten the knee against resistance of the physician's right hand, while his left hand feels the contracting quadriceps muscle above the knee (Fig. 3.29).
- Patellar tendon reflex or knee jerk (L3, L4). The knee joint gets extended on tapping the ligamentum patellae (Fig. 3.30).
- Psoas abscess formed due to tubercular infection of lumbar vertebrae can track down between psoas major muscles and its fascia to reach behind the inguinal ligament into the femoral triangle. It may be mistaken for enlarged lymph nodes (Fig. 3.31).
- Intramuscular injection can be given in anterolateral region of thigh in the vastus lateralis muscle (Fig. 3.32).

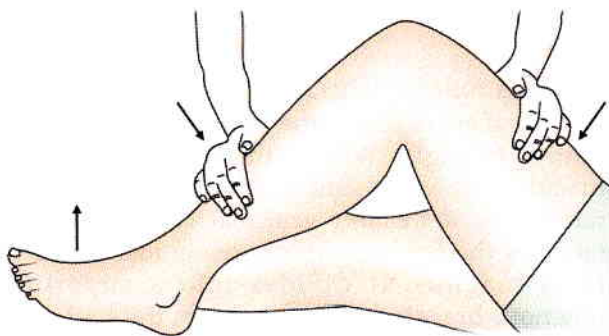

Fig. 3.29: Shows how to test the quadriceps femoris muscle

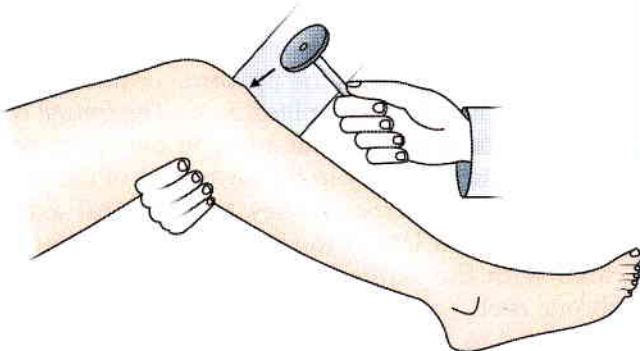


Fig. 3.30: Patellar tendon reflex

Paravertebral abscess

Psoas abscess

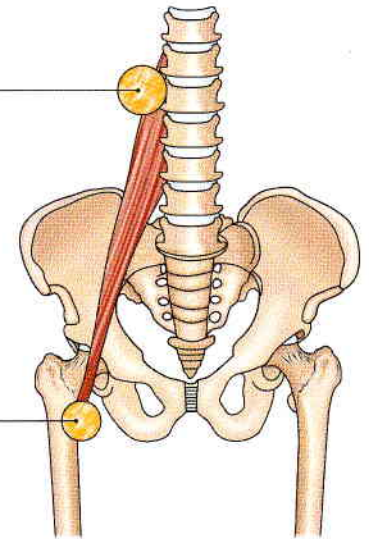


Fig. 3.31: Course of psoas abscess

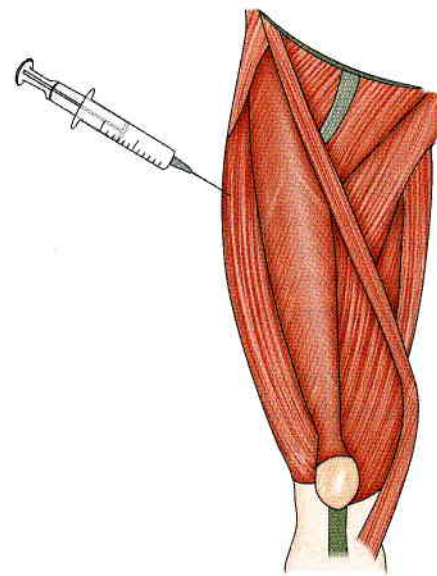


Fig. 3.32: Anterolateral region of thigh

ADDUCTOR/HUNTER'S/SUBSARTORIUS CANAL

DISSECTION

Upper one-third of sartorius forms the lateral boundary of the femoral triangle.

On lifting the middle one-third of sartorius, a part of deep fascia stretching between vastus medialis and adductor muscles is exposed. On longitudinal division of this strong fascia, the adductor canal/subsartorial canal/Hunter's canal is visualised (Fig. 3.33).

Dissect its contents, e.g. femoral vessels, saphenous nerve and nerve to vastus medialis, and distal parts of both divisions of obturator nerve.

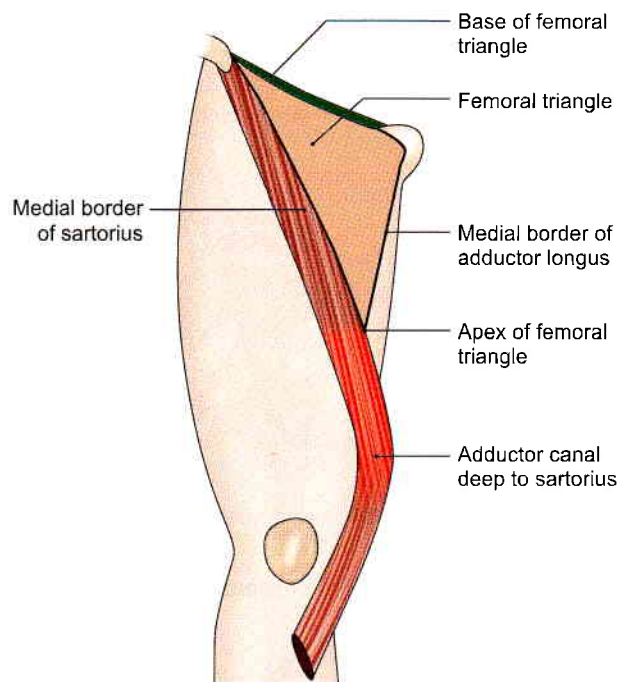


Fig. 3.33: Location of the adductor canal

Features

This is also called the subsartorial canal or Hunter's canal. John Hunter (1729–93) was an anatomist and surgeon at London. Hunter's operation for the treatment of popliteal aneurysm by ligating the femoral artery in the adductor canal is a landmark in the history of vascular surgery.

The adductor canal is an intermuscular space situated on the medial side of the middle one-third of the thigh (Figs 3.33 and 3.34).

Extent

The canal extends from the apex of the femoral triangle, above, to the tendinous opening in the adductor magnus, below.

Shape

The canal is triangular on cross-section.

Boundaries

- It has anterolateral, posteromedial and medial walls.
- The anterolateral wall is formed by the vastus medialis.
- The posteromedial wall or floor is formed by the adductor longus, above, and the adductor magnus, below.
- The medial wall or roof is formed by a strong fibrous membrane joining the anterolateral and posteromedial walls. The roof is overlapped by the sartorius.

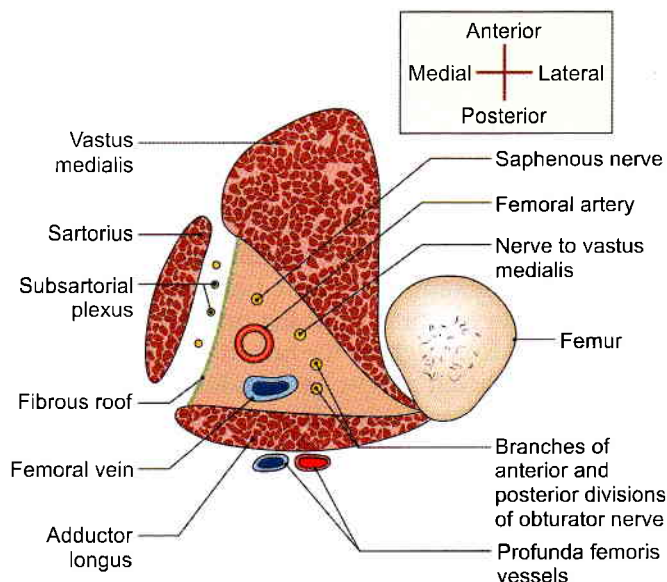


Fig. 3.34: Transverse section through the middle of the right adductor canal, seen from above. Note the boundaries and contents of the canal

The *subsartorial plexus* of nerves lies on the fibrous roof of the canal under cover of the sartorius. The plexus is formed by branches from the medial cutaneous nerve of the thigh, the saphenous nerve, and the anterior division of the obturator nerve. It supplies the overlying fascia lata and the neighbouring skin.

Contents

These are as follows (Fig. 3.35).

- 1 The *femoral artery* enters the canal at the apex of the femoral triangle. Within the canal it gives off muscular branches and a descending genicular branch. The *descending genicular artery* is the last branch of the femoral artery arising just above the hiatus magnus. It divides into a superficial saphenous branch that accompanies the saphenous nerve, and a deep muscular branch that enters the vastus medialis and reaches the knee. Femoral artery leaves the adductor canal through the opening in adductor magnus muscle to continue as popliteal artery in the popliteal fossa.
- 2 Femoral vein begins as the upward continuation of popliteal vein from the popliteal fossa. The *femoral vein* lies posterior to the femoral artery in the upper part, and lateral to the artery in the lower part of the canal.
- 3 The *saphenous nerve* crosses the femoral artery anteriorly from lateral to medial side. It leaves the canal with the saphenous artery by piercing the fibrous roof.
- 4 The *nerve to the vastus medialis* lies lateral to the femoral artery, and enters the vastus medialis in the upper part of the canal.

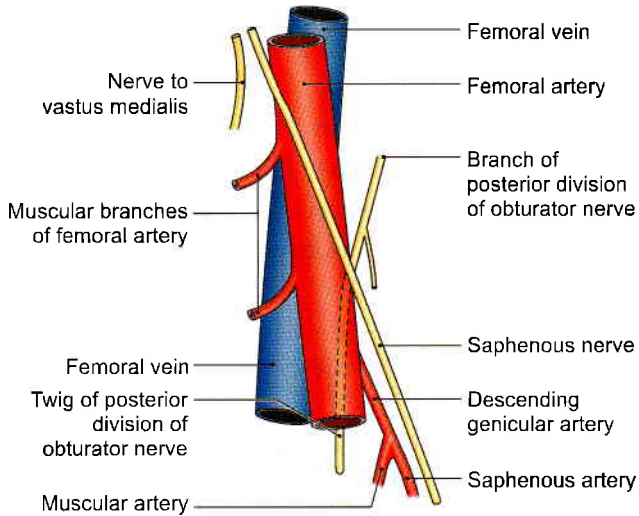


Fig. 3.35: Contents of the adductor canal

- 5 *Branches of two divisions of obturator nerve:* The anterior division emerges at the lower border of the adductor longus, gives branches to the subsartorial plexus, and ends by supplying the femoral artery. The posterior division of the obturator nerve runs on the anterior surface of the adductor magnus, accompanies the femoral and popliteal arteries, and ends by supplying the knee joint (Fig. 3.34).

FACTS TO REMEMBER

- Sartorius is the longest muscle of the body.
- Saphenous is the longest cutaneous nerve.
- Femoral hernia is common in female, while inguinal hernia is common in male
- Embalming for preservation of the dead body is also done through femoral artery
- Insertion of vastus medialis extends to lower level on patella than that of vastus lateralis to stabilise the patella.

CLINICOANATOMICAL PROBLEM

A 50-year-old woman complained of a swelling in upper medial side of her right thigh, when she coughs.

- Where is the swelling and why does it appear when she coughs?
- What is the position of the swelling in relation to pubic tubercle?

Ans: The swelling is the femoral hernia which appears at saphenous opening when she coughs due to raised intra-abdominal pressure. The swelling is inferolateral to the pubic tubercle. The femoral hernia is more common in females due to larger pelvis, larger femoral canal and smaller femoral vessels.

MULTIPLE CHOICE QUESTIONS

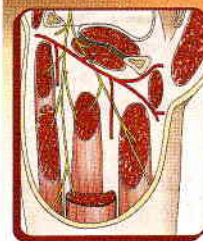
- Which is longest superficial vein of lower limb?
 - Long saphenous vein
 - Femoral vein
 - Popliteal vein
 - None of these
- Which of these pair of muscle are inserted into upper part of iliotibial tract?
 - Gluteus maximus and tensor fasciae latae
 - Gluteus maximus and pectineus
 - Pectineus and tensor fasciae latae
 - Adductor longus and pectineus
- Iliotibial tract stabilizes knee in:
 - Extension
 - Partial flexion
 - Both a and b
 - None of above
- Which one of the following make lateral boundary of femoral triangle?
 - Inguinal ligament
 - Adductor longus
 - Medial border of sartorius muscle
 - Pectineus
- Femoral artery is the continuation of:
 - Popliteal artery
 - External iliac artery
 - Profunda femoris artery
 - Obturator artery
- Medial boundary of femoral ring is formed by:
 - Inguinal ligament
 - Pectineus
 - Lacunar ligament
 - Femoral vein
- Which is the largest branch of femoral artery?
 - Superficial external pudendal
 - Superficial epigastric
 - Deep external pudendal
 - Profunda femoris artery
- Which is not a part of quadriceps femoris?
 - Rectus femoris
 - Vastus medialis
 - Sartorius
 - Vastus lateralis



9. Which muscles have common insertion on lesser trochanter of femur?
- Iliacus and psoas major
 - Pectineus and adductor longus
 - Psoas major and Pectineus
 - None of these
10. A femoral hernia is more common in female due to:
- Wider pelvis
 - Smaller size of femoral vessel
 - Femoral canal is wider
 - All of above
11. Which region of thigh is preferred to give intramuscular injection in children?
- Anterolateral region
 - Anteromedial region
 - Posterolateral region
 - Posteromedial region
12. Which vein is commonly used for intravenous infusions in children?
- Femoral vein
 - Long saphenous vein
 - Popliteal vein
 - Short saphenous vein

ANSWERS

1. a 2. a 3. c 4. c 5. b 6. c 7. d 8. c 9. a 10. d 11. a 12. a



Medial Side of Thigh

We make a living by what we get, but we make a life by what we give.

INTRODUCTION

The adductor or medial compartment of thigh is very well developed and is derived, as indicated by its nerve supply from both the flexors and extensors between which it lies. Its counterpart in the arm is represented only by coracobrachialis muscle, as the arm can be adducted by pectoralis major and latissimus dorsi muscles.

ADDUCTOR COMPARTMENT

DISSECTION

The triangular adductor longus was seen to form the medial boundary of femoral triangle (see Fig. 3.11). Cut this muscle 3 cm below its origin and reflect the distal part laterally. On its deep surface, identify the anterior division of obturator nerve which supplies both adductor longus and gracilis muscles.

Lateral to adductor longus on the same plane is the pectineus muscle. Cut it close to its origin and reflect laterally, tracing the branch of anterior division of obturator nerve to this muscle. Obturator nerve is accompanied by the branches of obturator artery and medial circumflex femoral arteries.

Deeper to adductor longus and pectineus is the adductor brevis. Look for its nerve supply either from anterior/posterior division.

Divide adductor brevis close to its origin. Deepest plane of muscles comprises adductor magnus (Fig. 4.2) and obturator externus, both supplied by posterior division of obturator nerve.

Lying vertically along the medial side of thigh is the graceful gracilis. Study these muscles and the course of obturator nerve.

Look for accessory obturator nerve. If present, it supplies pectineus.

Lastly, remove the obturator externus from its origin to expose the obturator artery and its branches.

BOUNDARIES

The adductor or medial compartment of the thigh is bounded anteriorly by the medial intermuscular septum which separates it from the extensor (anterior) compartment; and posteriorly by an ill-defined posterior intermuscular septum which separates it from the flexor (posterior) compartment (see Fig. 3.9).

The structures to be studied in this region are muscles, nerves and arteries. These are as follows.

Muscles

Intrinsic

- 1 Adductor longus
- 2 Adductor brevis
- 3 Adductor magnus
- 4 Gracilis
- 5 Pectineus.

Extrinsic

The obturator externus lies deep in this region. It is functionally related to the gluteal region.

Nerves

- 1 Obturator nerve.
- 2 Accessory obturator nerve.

Arteries

- 1 Obturator artery.
- 2 Medial circumflex femoral artery.

MUSCLES OF ADDUCTOR COMPARTMENT OF THIGH

The attachments of the muscles are given in Table 4.1. Their nerve supply and actions are given in Table 4.2.

**Table 4.1: Muscles of the medial compartment of thigh**

Muscle	Origin from	Insertion into
Adductor longus (Fig. 4.1) This is a triangular muscle, forming the medial part of the floor of the femoral triangle. It lies in the plane of the pectineus	It arises by a narrow, flat tendon from the front of the body of the pubis in the angle between the pubic crest and the pubic symphysis. Sometimes sesamoid bone is seen near its origin (rider's bone)	The linea aspera in middle one-third of the shaft of the femur between the vastus medialis and the adductor brevis and magnus (Fig. 4.2a)
Adductor brevis (Fig. 4.1) The muscle lies behind the pectineus and adductor longus	a. Anterior surface of body of the pubis b. Outer surface of inferior ramus of the pubis between the gracilis and obturator externus c. Outer surface of ramus of the ischium between gracilis and the adductor magnus	Line extending from the lesser trochanter to upper part of linea aspera, behind the upper part of adductor longus (Fig. 4.2a)
Adductor magnus (Fig. 4.1) This is the largest muscle of this compartment. Because of its double nerve supply, it is called a hybrid muscle	a. Inferolateral part of the ischial tuberosity b. Ramus of the ischium c. Lower part of inferior ramus of the pubis	a. Medial margin of gluteal tuberosity b. Linea aspera c. Medial supracondylar line d. Adductor tubercle
Gracilis (Fig. 4.1) (Greek <i>slender</i>)	a. Medial margin of the lower half of the body of the pubis b. Inferior ramus of the pubis c. Adjoining part of the ramus of the ischium	Upper part of the medial surface of tibia behind the sartorius and in front of the semitendinosus (Fig. 4.2b)
Pectineus (see Figs 3.11 and 4.1) This is flat, quadrilateral muscle. It forms a part of the floor of the femoral triangle	a. Pecten pubis b. Upper half of the pectineal surface of superior ramus of the pubis c. Fascia covering the pectineus	Line extending from lesser trochanter to the linea aspera

Table 4.2: Nerve supply and actions of muscles

Muscle	Nerve supply	Actions
Adductor longus	Anterior division of obturator nerve	Powerful adductor of thigh at hip joint These act as posture controllers
Adductor brevis	Anterior or posterior division of obturator nerve	Adductor longus, adductor brevis help in adduction and flexion of thigh
Adductor magnus (hybrid muscle)	Double nerve supply: Adductor part by posterior division of obturator nerve Hamstring part by tibial part of sciatic nerve	Adductor part causes adduction of thigh and hamstring part helps in extension of hip and flexion of knee
Gracilis	Anterior division of obturator nerve	Flexor and medial rotator of thigh. It is a weak adductor of thigh. It is used for transplantation of any damaged muscles
Pectineus (hybrid or composite muscle)	Double nerve supply: Anterior fibres by femoral nerve Posterior fibres by anterior division of obturator nerve	Flexor of thigh Adductor of thigh

The obturator externus is described in Chapter 5 (see also Tables 5.1 and 5.2).

RELATIONS OF ADDUCTOR LONGUS

The relations of the adductor longus are important. They are as follows.

Anterior Surface

- 1 Spermatic cord
- 2 Great saphenous vein with fascia lata
- 3 Femoral vessels
- 4 Sartorius (Fig. 4.3).

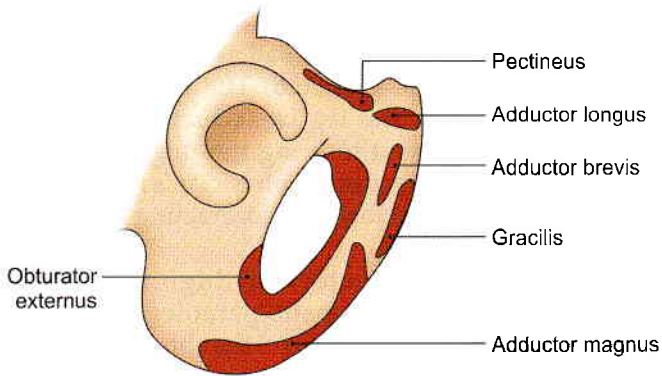
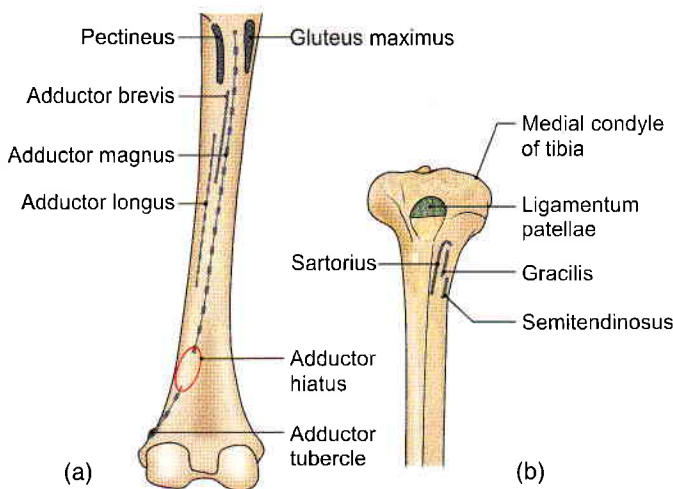


Fig. 4.1: Origin of muscles of medial compartment of the thigh



Figs 4.2a and b: Insertion of muscles: (a) Posterior aspect of femur, and (b) upper part of medial surface of tibia

Posterior Surface

- 1 Adductor brevis
- 2 Adductor magnus

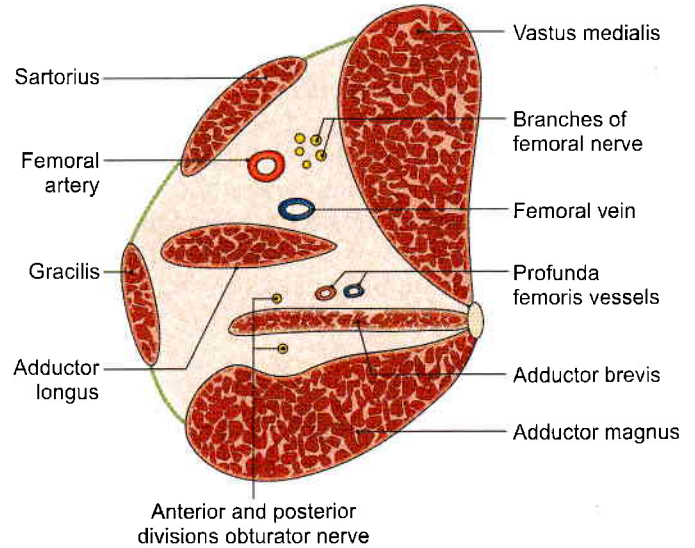


Fig. 4.3: Transverse section through the femoral triangle showing the relations of the adductor longus

- 3 Anterior division of obturator nerve
- 4 Profunda femoris vessels.

Lateral border: Pectineus.

Medial border: Gracilis.

OBTURATOR NERVE

The obturator nerve is the chief nerve of the medial compartment of the thigh.

Origin and Root Value

It is a branch of the lumbar plexus. It is formed by the ventral divisions of the anterior primary rami of spinal nerves L2, L3, L4. The upper part of the nerve lies in the pelvis. It enters the thigh by passing through the obturator canal (Fig. 4.4) (refer to 3).

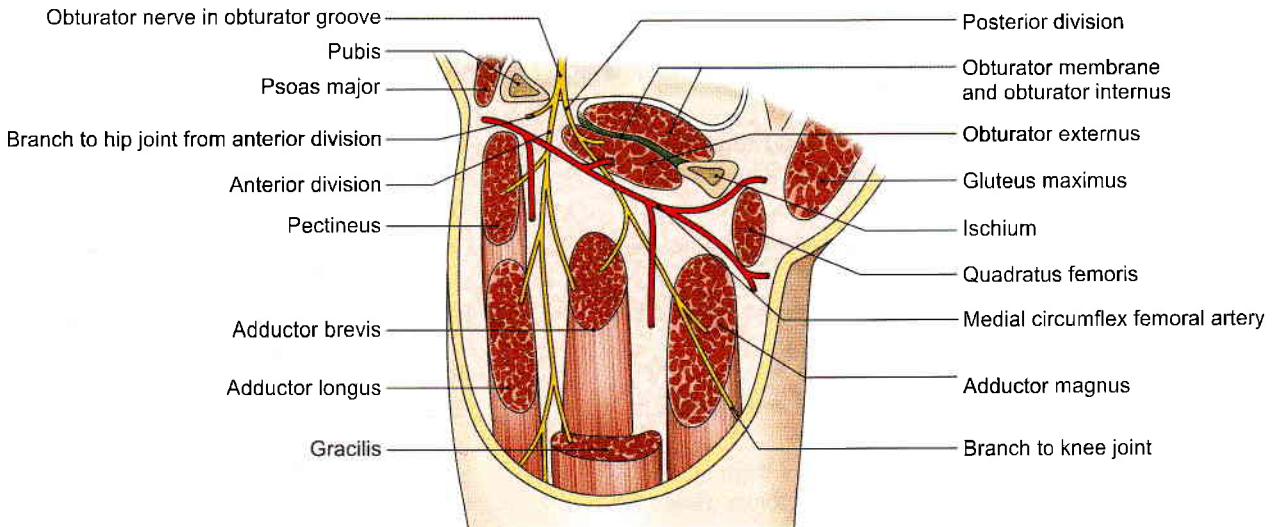


Fig. 4.4: The course and distribution of the obturator nerve



Course and Relations in Thigh

- 1 Within the obturator canal the nerve divides into anterior and posterior divisions.
- 2 The *anterior division* passes downwards in front of the obturator externus being separated from the posterior division by a few fibres of this muscle. It then descends behind the pectineus and the adductor longus, and in front of the adductor brevis. The anterior division supplies the following muscles.
 - a. Pectineus
 - b. Adductor longus
 - c. Gracilis
 - d. Adductor brevis if not supplied by the posterior division.

The anterior division also gives a branch to the hip joint. Below the lower border of the adductor longus, it supplies a twig to the subsartorial plexus, and ends by supplying the femoral artery in the adductor canal.
- 3 The *posterior division* enters the thigh by piercing the upper border of the obturator externus muscle. It descends behind the adductor brevis and in front of the adductor magnus. It gives branches to the following muscles.
 - a. Obturator externus
 - b. Adductor magnus
 - c. Adductor brevis if not supplied by the anterior division.

In the adductor canal, it is reduced to a thin genicular branch which enters the popliteal fossa, pierces the oblique popliteal ligament and ends by supplying the capsule and the cruciate ligaments of the knee joint. Some of its fibres end by innervating the popliteal artery.

Table 4.3 shows the comparison between femoral and obturator nerves

Table 4.3: Comparison between femoral and obturator nerves

	<i>Femoral nerve</i>	<i>Obturator nerve</i>
Root value	Dorsal divisions of ventral primary rami of lumbar 2, 3, 4 segments of spinal cord	Ventral divisions of ventral primary rami of lumbar 2, 3, 4 segments of spinal cord
Size	Thicker in size	Thinner in size
Position in abdomen	Emerges at the lateral border of psoas major	Emerges at the medial border of psoas major
Exit	Exits from abdomen by passing deep to the inguinal ligament	Exits from abdomen by lying on the lateral wall of true pelvis and then through the obturator foramen
Branches in abdomen	Gives branches in the abdomen to iliacus and pectineus	Gives no branches in abdomen
Branches in thigh	Supplies muscles of front of thigh of, i.e. quadriceps femoris and sartorius. Gives big cutaneous branches.	Supplies adductor muscles of thigh. Gives very small unnamed cutaneous branches.

CLINICAL ANATOMY

- Testing the adductors: The patient lies supine with right lower limb abducted. The right hand of physician holds the leg in abducted position. Patient is requested to bring the thigh medially against the resistance of the physician's right hand, while his left hand feels the contracting adductor muscles (Fig. 4.5).
- Spasm of the adductors of thigh in certain intractable cases of spastic paraplegia may be relieved by surgical division of the obturator nerve.
- A disease of the hip joint may cause referred pain in the knee and on the medial side of the thigh because of their common nerve supply by the obturator nerve.
- Obturator nerve may be involved with femoral nerve in retroperitoneal tumors. A nerve entrapment syndrome leading to chronic pain on the medial side of thigh may occur in athletes with big adductor muscles.

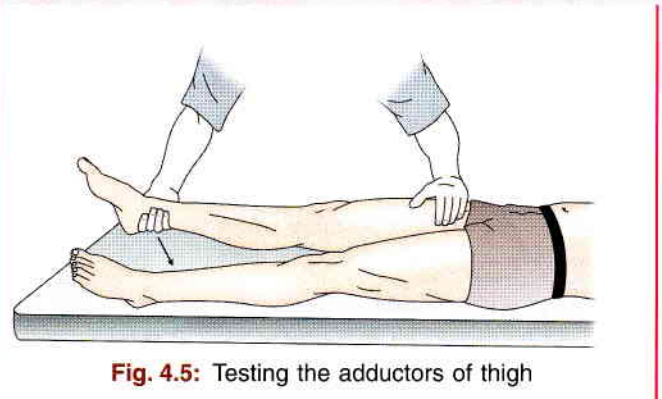


Fig. 4.5: Testing the adductors of thigh

ACCESSORY OBTURATOR NERVE

This nerve is present in about 30% of subjects. It is a branch of the lumbar plexus, and is formed by the



ventral divisions of the anterior primary rami of spinal nerves L3 and L4. It descends along the medial border of the psoas major, crosses the superior ramus of the pubis behind the pectineus, and terminates by dividing into three branches. One branch supplies the deep surface of the pectineus, another supplies the hip joint, and the third communicates with the anterior division of the obturator nerve. Sometimes the nerve is very small, and ends by supplying the pectineus only (Fig. 4.6).

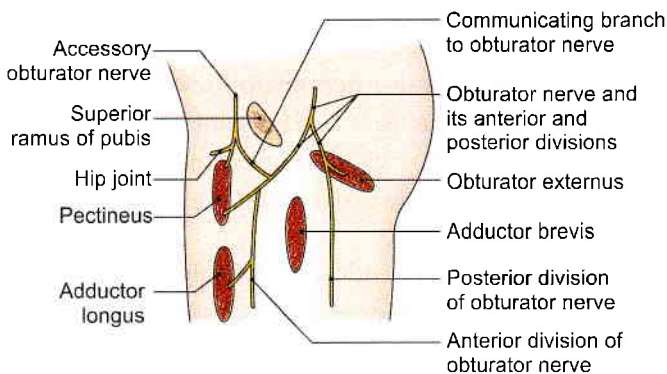


Fig. 4.6: The accessory obturator nerve

OBTURATOR ARTERY

- 1 The obturator artery is a branch of the internal iliac, and accompanies (lies below) the obturator nerve in the pelvis.
- 2 At the upper margin of the obturator foramen, the obturator artery divides into anterior or medial and posterior or lateral branches which form a circle over the obturator membrane and anastomoses with the medial circumflex femoral artery.
- 3 Both branches supply the neighbouring muscles, the posterior branch also gives an *acetabular branch* which passes through the acetabular notch to supply the fat in the acetabular fossa and sends a twig to the head of the femur along the round ligament (foveolar artery) (Fig. 4.7).

MEDIAL CIRCUMFLEX FEMORAL ARTERY

- 1 This artery arises from the profunda femoris.
- 2 It leaves the femoral triangle by passing backwards and ends by dividing into ascending and transverse branches.
- 3 Ascending branch of medial circumflex femoral anastomoses with ascending branch of lateral circumflex femoral and superior gluteal artery to form "trochanteric anastomoses". This gives retinacular branches which lie along the retinacula of capsule of hip joint to supply head of femur.
- 4 Transverse branch anastomoses with transverse branch of lateral circumflex femoral, inferior gluteal

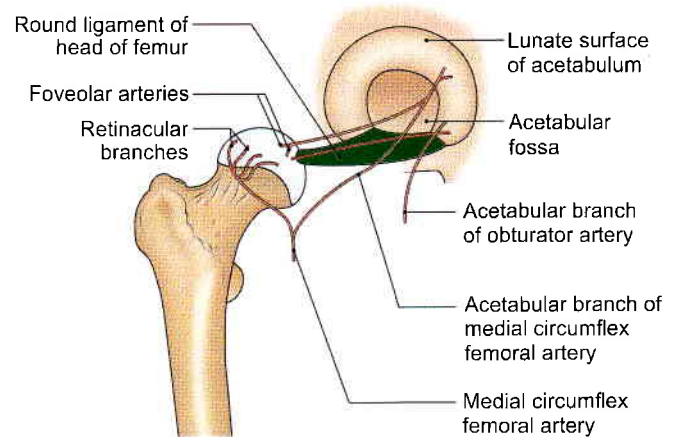


Fig. 4.7: Acetabular arteries and their foveolar branches

and first perforating branch of profunda femoris to form "cruciate anastomoses" (Fig. 4.7).

- 5 Before giving off the terminal branches, the artery gives off many muscular branches, and an *acetabular branch* which passes through the acetabular notch to supply fat in the acetabular fossa and sends a twig to the head of the femur along the round ligament (foveolar artery) (Fig. 4.7).

CLINICAL ANATOMY

- The gracilis muscle is most superficial muscle of the adductor compartment. This muscle is often used for transplantation of any damaged muscle.
- Intracapsular fracture of neck of femur causes damage to the retinacular branches (which supply head of femur), leading to avascular necrosis of head of femur.

FACTS TO REMEMBER

- Obturator nerve arises from ventral divisions of ventral primary rami of L2, L3 and L4 segments of spinal cord; whereas femoral nerve arises from dorsal divisions of ventral primary rami of the same segments.
- Adductor magnus and pectineus are two hybrid or composite muscles
- Since femoral and obturator nerves supply both the hip joint and knee joint, pain from one joint may be referred to the other joint.
- Obturator nerve is seen at the medial border of psoas major muscle, crosses the ala of sacrum to enter the pelvis. It exits the pelvis through the obturator foramen to enter the medial aspect of the thigh.
- Obturator artery, branch of internal iliac and medial circumflex femoral, branch of profunda femoris are seen on the medial side of the thigh.



CLINICOANATOMICAL PROBLEM

A 50-year-old female complained of pain in her right knee. She was diagnosed as osteoarthritis and has been doing physiotherapy. After 2 months, she felt pain in her right hip as well.

- What is the reason for development of pain in right hip joint as well?
- What nerve supplies these two joints? Mention its root value?

Ans: The pain in her hip joint is a referred pain from the knee joint. Obturator nerve supplies both the hip and knee joints, and the pain from one joint can be referred to the other. The root value of obturator nerve is ventral division of ventral primary rami of L2, L3 and L4 segments of the spinal cord. Femoral nerve also supplies both these joints. Its root value is dorsal division of ventral primary rami of L2, L3 and L4 segments of the spinal cord.

MULTIPLE CHOICE QUESTIONS

1. Which muscle is most medial muscle of adductor compartment?
 - a. Gracilis
 - b. Pectineus
 - c. Adductor magnus
 - d. Sartorius
2. What is nerve supply of hamstring part of adductor magnus?
 - a. Anterior division of obturator nerve
 - b. Posterior division of obturator nerve
 - c. Tibial part of sciatic nerve
 - d. Femoral nerve
3. Accessory obturator nerve supplies:
 - a. Pectineus muscle
 - b. Hip joint
 - c. Psoas major
 - d. Both a and b
4. What is the action of ischial part of adductor magnus?
 - a. Flexion of thigh, adductor of thigh
 - b. Flexion of knee, extension of hip
 - c. Flexor and medial rotator of thigh
 - d. Flexion of knee only
5. Which of the following is a hybrid muscle?
 - a. Gracilis
 - b. Adductor magnus
 - c. Adductor longus
 - d. Adductor brevis

ANSWERS

1. a 2. c 3. d 4. b 5. b



Gluteal Region

High heels make gluteal region and torso prominent, making the wearer vulnerable to "hot comments". That was her intention in fact.

INTRODUCTION

The gluteal (Greek *rump*) region overlies the side and back of the pelvis, extending from the iliac crest above to the gluteal fold below. The lower part of the gluteal region which presents a rounded bulge due to excessive amount of subcutaneous fat is known as the buttock or natis. The anterosuperior part of the region seen in a side view is called the hip. The muscles, nerves and vessels emerging from pelvis are covered by gluteus maximus and buttock.

Morphologically, the erect posture of man has led to extension at the hip and appearance of gluteal fold, which is a transverse skin crease of the hip joint. This puts greater responsibility on gluteus maximus which makes the body erect and maintains it in erect posture at the hip; this involves raising and supporting the trunk against gravity. The gluteus maximus, covering the hip joint is, therefore, one of the most powerful and bulkiest muscles in man.

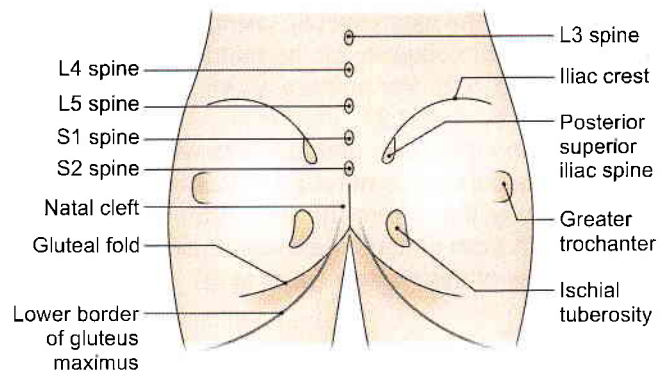


Fig. 5.1: Landmarks of the gluteal region

by placing the fingers in the medial part of the gluteal fold and pressing them upwards.

- 3 *Greater trochanter* of femur is a large bony prominence situated immediately in front of the hollow on the side of the hip and about a hands breadth below the tubercle of iliac crest.
- 4 *Iliac crest* is a thick curved bony ridge felt in a groove in the lower margin of the waist. The hands spanning the waist are often supported by the iliac crest. The *highest point* of iliac crest corresponds to the interval between the spines of the third and fourth lumbar vertebrae; site of lumbar puncture.

The anterior end of iliac crest is known as the *anterior superior iliac spine*. A line drawn from here to the front of the greater trochanter marks the junction between gluteal region and the front of thigh.

The posterior end of iliac crest is known as the *posterior superior iliac spine*. It lies in the floor of a dimple about 5 cm from the median plane and at the level of second sacral spine opposite the middle of sacroiliac joint.

- 5 *Sacrum* lies posteriorly between the two hip bones. The upper three sacral spines are usually palpable

SURFACE LANDMARKS

- 1 *Buttock* is the rounded bulge in the lower part of the gluteal region. The two buttocks are separated from each other in the posterior median line by the *natal cleft* which begins at the third sacral spine and deepens inferiorly. The gluteal fold marks the lower limit of the buttock. Note that the *gluteal fold* is the transverse skin crease of the hip joint and that it does not correspond to the lower border of gluteus maximus which crosses the fold obliquely downwards and laterally (Fig. 5.1).
- 2 *Ischial tuberosity* is a large bony prominence which lies deep to the lower border of gluteus maximus about 5 cm from the median plane and about the same distance above the gluteal fold. It can be felt



in the median plane. The *second spine*, lying between the *two posterior superior iliac spines*, is the guide to the other two spines. The lower part of sacrum and the coccyx lie in the floor of the natal cleft.

- 6 *Coccyx* lies just behind the anus. It is slightly mobile under pressure.
- 7 The *sacrospinous ligament* lying deep to the lower border of gluteus maximus can be felt by a firm pressure between the lower part of sacrum and ischial tuberosity (Fig. 5.14).

SUPERFICIAL AND DEEP FASCIAE

DISSECTION

Make a curved incision from spine of second sacral vertebra (i); along the iliac crest till its tubercle (ii); make a vertical incision from the second sacral spine downwards till the natal cleft (iii); taking it further laterally with downward convexity till the middle of the back of thigh (iv) (Fig. 5.2). For points v, vi, vii, viii, and ix refer to Chapters 6, 7, and 9.

Reflect the thick skin and fascia towards the lateral aspect. The cutaneous nerves and vessels are difficult to find. Study them from the text. After removing the deep fascia from gluteus maximus muscle, define the attachments of this muscle (refer to 8).

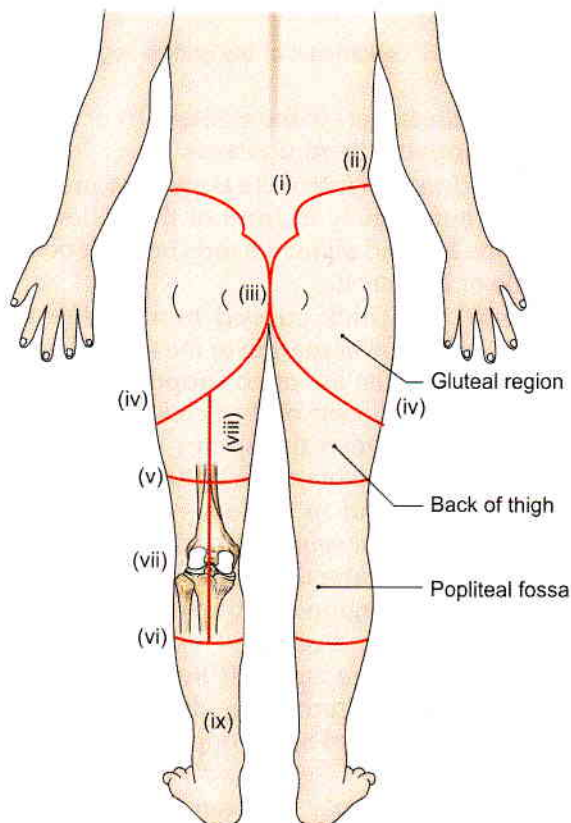


Fig. 5.2: Lines for dissection

SUPERFICIAL FASCIA

It is heavily laden with fat, more so in females, and is tough and stringy over the ischial tuberosity where it forms an efficient cushion for supporting the body weight in the sitting posture. It contains cutaneous nerves, vessels and lymphatics.

Cutaneous Nerves

The cutaneous nerves converge on the gluteal region from all directions (Fig. 5.3a).

- 1 The upper and anterior part is supplied by the lateral cutaneous branches of the subcostal T12 and iliohypogastric L1 nerves.
- 2 The upper and posterior part is supplied by the posterior primary rami of spinal nerves L1, L2, L3 and S1, S2, S3.
- 3 The lower and anterior part is supplied by branches from the posterior division of the lateral cutaneous nerve of the thigh (L2, L3).
- 4 The lower and posterior part is supplied by branches from the posterior cutaneous nerve of the thigh (S1, S2, S3) and the perforating cutaneous nerve (S2, S3) (Fig. 5.3b).

Cutaneous Vessels and Lymphatics

The *blood supply* of the skin and subcutaneous tissue is derived from perforating branches of the superior and inferior gluteal arteries.

The *lymphatics* from the gluteal region drain into the lateral group of the superficial inguinal lymph nodes.

DEEP FASCIA

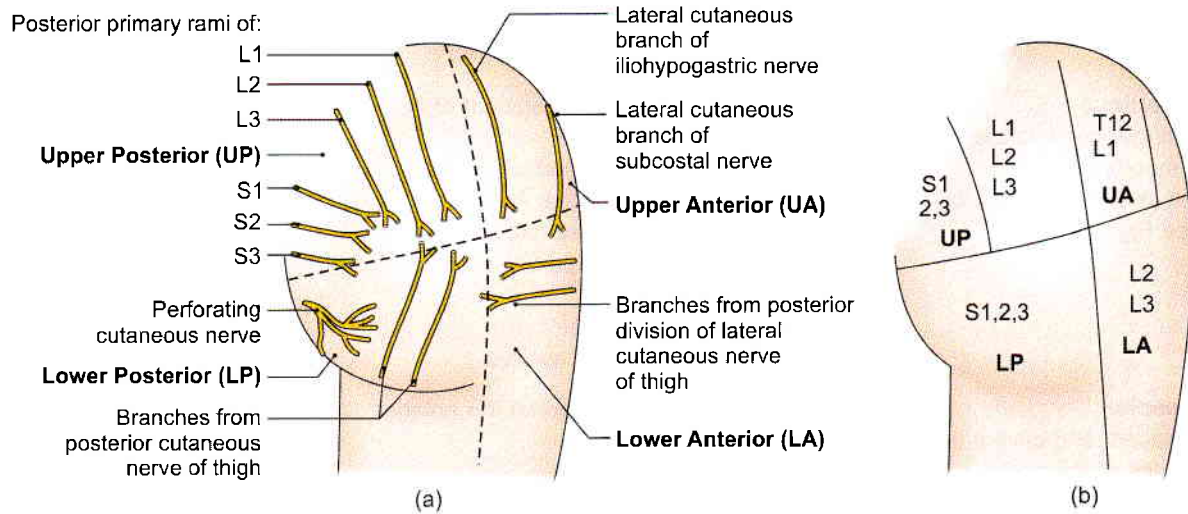
The deep fascia above and in front of the gluteus maximus, i.e. over the gluteus medius, is thick, dense, opaque and pearly white. Over the gluteus maximus, however, it is thin and transparent. The deep fascia splits and encloses the gluteus maximus muscle (Fig. 5.4).

MUSCLES OF GLUTEAL REGION

DISSECTION

Reflect the gluteus maximus to examine the underlying structures. For this, identify the lower border of muscle. Insert a forceps on the deep surface of muscle which is to be cut from below upwards midway between its origin and insertion along the course of posterior cutaneous nerve of thigh. Reflect two parts on either side.

Piriformis is *key muscle* of the region, define its margins. Identify the structures above and below this muscle, most important being the sciatic nerve. Above



Figs 5.3a and b: Cutaneous innervation of the gluteal region: (a) Cutaneous nerves, and (b) root values of the nerves in the four quadrants

piriformis are superior gluteal vessels and nerve. Below piriformis are inferior gluteal vessels and nerve.

The thickest nerve of the body, sciatic nerve also enters the gluteal region through the greater sciatic notch below piriformis muscle.

Pudendal nerve and vessels appear here through greater sciatic notch and disappear through the lesser sciatic notch (Fig. 5.14).

Under the lower and medial part of the gluteus maximus muscle, ischial tuberosity is easily palpable. Separate the hamstring muscles from the ischial tuberosity.

Identify long vertical sacrotuberous ligament and smaller horizontal sacrospinous ligament to demarcate the greater and lesser sciatic foramina and structures entering and leaving them. Greater sciatic notch is the 'gateway' of the gluteal region.

Define the borders of the gluteus medius muscle. Cut through the muscle 5 cm above its insertion into the greater trochanter of femur. The superior gluteal vessels and nerve are now exposed which are to be traced into gluteus minimus and tensor fascia latae.

Reflect gluteus minimus from its origin towards the insertion to expose the straight and reflected heads of rectus femoris muscle and the capsule of the hip joint.

Features

These muscles are the gluteus maximus, the gluteus medius, the gluteus minimus, the piriformis, the superior and inferior gemelli, the obturator internus obturator externus, and quadratus femoris. The tensor fasciae latae which lies on the lateral side of thigh, just in front of gluteal region, is also considered here. The attachments and nerve supply of these muscles are

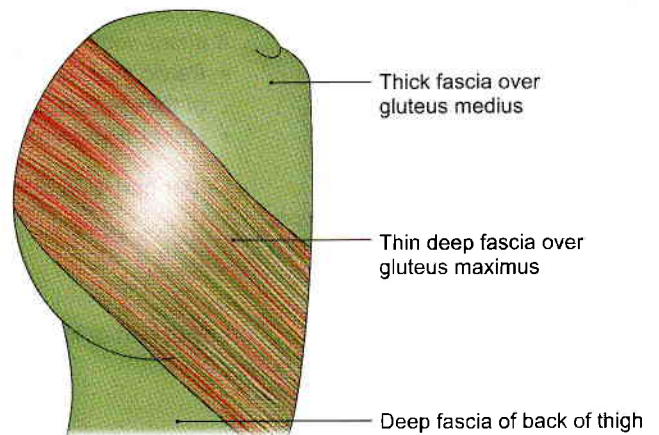


Fig. 5.4: Deep fascia of the gluteal region

given in Tables 5.1 and 5.2. Their actions and some other features are considered below.

STRUCTURES UNDER COVER OF GLUTEUS MAXIMUS

These are numerous as follows.

Muscles

- 1 Gluteus medius (refer to 3).
- 2 Gluteus minimus.
- 3 Reflected head of the rectus femoris.
- 4 Piriformis.
- 5 Obturator internus with two gemelli.
- 6 Quadratus femoris.
- 7 Obturator externus.
- 8 Origin of the four hamstrings from the ischial tuberosity.
- 9 Insertion of the upper or pubic fibres of the adductor magnus (Figs 5.5 and 5.6).


Table 5.1: Muscles of the gluteal region

<i>Muscle</i>	<i>Origin</i>	<i>Insertion</i>
<p>Gluteus maximus This is a large, quadrilateral powerful muscle covering mainly the posterior surface of pelvis (see Fig. 5.4)</p>	<ul style="list-style-type: none"> • Outer slope of the dorsal segment of iliac crest • Posterior gluteal line • Posterior part of gluteal surface of ilium behind the posterior gluteal line • Aponeurosis of erector spinae • Dorsal surface of lower part of sacrum • Side of coccyx • Sacrotuberous ligament • Fascia covering gluteus medius 	<ul style="list-style-type: none"> • The deep fibres of the lower part of the muscle are inserted into the gluteal tuberosity (1/4th part) • The greater part of the muscle is inserted into the iliotibial tract (3/4 th part)
<p>Gluteus medius It is fan-shaped, and covers the lateral surface of the pelvis and hip (see Figs 2.4 and 5.5)</p>	Gluteal surface of ilium between the anterior and posterior gluteal lines	Into the greater trochanter of femur, on oblique ridge on the lateral surface. The ridge runs downwards and forwards
<p>Gluteus minimus It is fan-shaped, and is covered by the gluteus medius (see Fig. 2.4)</p>	Gluteal surface of ilium between the anterior and inferior gluteal lines	Into greater trochanter of femur, on a ridge on its anterior surface
<p>Piriformis Lies below and parallel to the posterior border of the gluteus medius (Fig. 5.5)</p>	<p>It arises within the pelvis from:</p> <ul style="list-style-type: none"> • Pelvic surface of the middle three pieces of the sacrum, by three digitations • Upper margin of the greater sciatic notch 	The rounded tendon is inserted into the apex of the greater trochanter of the femur
<p>Gemellus superior Small muscle lying along the upper border of the tendon of the obturator internus (see Figs 2.4 and 5.5)</p>	Upper part of lesser sciatic notch	Blends with tendon of obturator internus, and gets inserted into medial surface of greater trochanter of femur
<p>Gemellus inferior Small muscle lying along the lower border of the tendon of the obturator internus (Fig. 5.5)</p>	Lower part of lesser sciatic notch	Same as above
<p>Obturator internus Fan-shaped, flattened belly lies in pelvis and the tendon in the gluteal region (Figs 5.5 and 5.6)</p>	<ul style="list-style-type: none"> • Pelvic surface of obturator membrane • Pelvic surface of the body of the ischium, ischial tuberosity, ischiopubic rami, and ilium below the pelvic brim • Obturator fascia 	The tendon of the obturator internus leaves the pelvis through the lesser sciatic foramen. Here it bends at a right angle around the lesser sciatic notch and runs laterally to be inserted into the medial surface of the greater trochanter of the femur
<p>Quadratus femoris Quadrilateral muscle lying between inferior gemellus and adductor magnus (Figs 5.5 and 5.6)</p>	Upper part of the outer border of ischial tuberosity	Quadratus tubercle and the area below it
<p>Obturator externus Triangular in shape, covers the outer surface of the anterior wall of the pelvis (Figs 5.6 and 5.7)</p>	<ul style="list-style-type: none"> • Outer surface of obturator membrane • Outer surface of the bony margins of obturator foramen 	The muscle ends in a tendon which runs upwards and laterally behind the neck of the femur to reach the gluteal region where it is inserted into the trochanteric fossa (on medial side of the greater trochanter)
<p>Tensor fasciae latae Lies between the gluteal region and the front of the thigh (Fig. 5.6)</p>	Anterior 5 cm of the outer lip of the iliac crest up to the tubercle of iliac crest	Iliotibial tract 3–5 cm below the level of greater trochanter



Table 5.2: Nerve supply and actions of muscles

Muscle	Nerve supply	Actions
Gluteus maximus	Inferior gluteal nerve (L5, S1, S2)	Chief extensor of the thigh at the hip joint. This action is very important in rising from a sitting position. It is essential for maintaining the erect posture. Other actions are: a. Lateral rotation of the thigh b. Abduction of the thigh (by upper fibres) c. Along with the tensor fasciae latae the muscle stabilises the knee through the iliotibial tract It supports both the hip and the knee when these joints are slightly flexed. It is an antigravity muscle as well.
Gluteus medius Gluteus minimus	Superior gluteal nerve (L4, L5, S1) Superior gluteal nerve (L4, L5, S1)	The <i>gluteus medius</i> and <i>gluteus minimus</i> are: Powerful abductors of the thigh. Their anterior fibres are also medial rotators. However, their most important action is to maintain the balance of the body when the opposite foot is off the ground, as in walking and running. They do this by preventing the opposite side of the pelvis from tilting downwards under the influence of gravity.
Piriformis Gemellus superior Gemellus inferior Obturator internus Quadratus femoris Obturator externus	Ventral rami of S1, S2 Nerve to obturator internus (L5, S1, S2) Nerve to quadratus femoris (L4, L5, S1) Nerve to obturator internus (L5, S1, S2) Nerve to quadratus femoris (L4, L5, S1) Posterior division of obturator nerve (L2, L3, L4)	Lateral rotators of thigh at the hip joint
Tensor fasciae latae	Superior gluteal nerve (L4, L5, S1)	Abductor and medial rotator of thigh and an extensor of knee joint

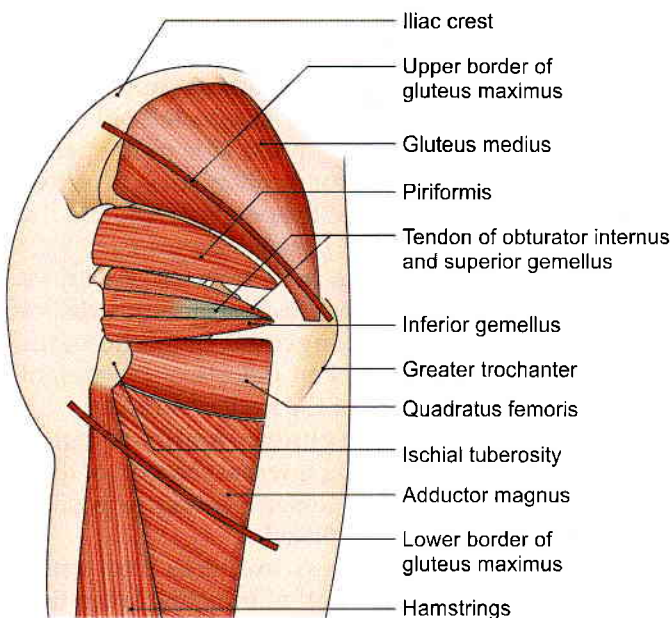


Fig. 5.5: Muscles under cover of the gluteus maximus. The upper and lower borders of this muscle are indicated in thick lines

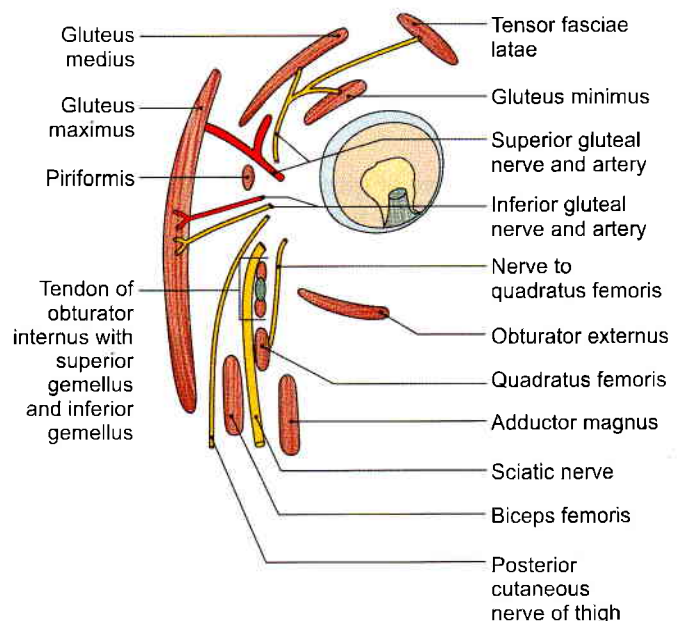


Fig. 5.6: Scheme of an oblique vertical section showing muscles of the gluteal region. Structures under cover of the gluteus maximus



Vessels

- 1 Superior gluteal vessels (Fig. 5.6).
- 2 Inferior gluteal vessels.
- 3 Internal pudendal vessels.
- 4 Ascending branch of the medial circumflex femoral artery.
- 5 Trochanteric anastomoses (described with arteries of gluteal region).
- 6 Cruciate anastomoses (described with arteries of gluteal region).
- 7 The first perforating artery.

Nerves

- 1 Superior gluteal (L4, L5, S1) as in Fig. 5.6.
- 2 Inferior gluteal (L5, S1, S2).
- 3 Sciatic (L4, S5, S1, S2, S3).
- 4 Posterior cutaneous nerve of thigh (S1, S2, S3).
- 5 Nerve to the quadratus femoris (L4, L5, S1).
- 6 Pudendal nerve (S2, S3, S4).
- 7 Nerve to the obturator internus (L5, S1, S2).
- 8 Perforating cutaneous nerves (S2, S3).

Bones and Joints

- 1 Ilium.
- 2 Ischium with ischial tuberosity.
- 3 Upper end of femur with the greater trochanter.
- 4 Sacrum and coccyx.
- 5 Hip joint.
- 6 Sacroiliac joint.

Ligaments

- 1 Sacrotuberous.
- 2 Sacrospinous.
- 3 Ischiofemoral.

Bursae

- 1 Trochanteric bursa of gluteus maximus.
- 2 Bursa over the ischial tuberosity.
- 3 Bursa between the gluteus maximus and vastus lateralis.

STRUCTURES DEEP TO THE GLUTEUS MEDIUS

The gluteus medius covers:

- The superior gluteal nerve,
- The deep branch of the superior gluteal artery,
- The gluteus minimus,
- The trochanteric bursa of the gluteus medius.

STRUCTURES DEEP TO THE GLUTEUS MINIMUS

Structures lying deep to the gluteus minimus include the reflected head of the rectus femoris, and the capsule of the hip joint.

CLINICAL ANATOMY

- Testing gluteus maximus the patient lies prone. The right hand of physician presses the patient's right leg downwards. Patient is requested to extend his hip against resistance provided by the physician's right hand; while his left hand feels the contracting gluteus maximus muscle (Fig. 5.7).
- *When the gluteus maximus is paralysed* as in muscular dystrophy, the patient cannot stand up from a sitting posture without support. Such patients, while trying to stand up, rise gradually, supporting their hands first on legs and then on the thighs; they climb on themselves (Fig. 5.8).
- *Intramuscular injections* are given in the anterosuperior quadrant of the gluteal region, i.e. in the glutei medius and minimus, to avoid injury to large vessels and nerves which pass through the lower part of this region (Fig. 5.9). Gluteal region is not the prominence of the buttock only. It is a very big area over the iliac bone.
- *When the glutei medius and minimus (of right side) are paralysed*, the patient cannot walk normally. He bends or waddles on the right side or paralysed side to clear the opposite foot, i.e. left, off the ground. This is known as *lurching gait*; when bilateral, it is called *waddling gait* (Fig. 5.10).
- The normal gait depends on the proper abductor mechanism at both hips (Fig. 5.11). This mechanism comprises:
 - a. The adequate power, provided by the glutei medius and minimus (Figs 5.12a to c).
 - b. The fulcrum, formed by a normal relationship of the head of the femur with the acetabulum.
 - c. The weight transmitted by the head and neck of the femur.
- Normally when the body weight is supported on one limb, the glutei of the supported side raise the opposite and unsupported side of the pelvis. However, if the abductor mechanism is defective, the unsupported side of the pelvis drops, and this is known as a positive *Trendelenburg's sign*.
The sign is positive in defects of power, i.e. paralysis of the glutei medius and minimus; defects of the fulcrum, i.e. congenital or pathological dislocation of the hip; and defects of the weight, i.e. ununited fracture of the neck of femur.
- Gluteus medius and gluteus minimus can be tested together by doing internal rotation of thigh against resistance. The person is in supine position with the hip and knee flexed.
- Gluteus medius, gluteus minimus and tensor fasciae latae are tested by the abducting lower limb against resistance. The person in the supine position and the knee is extended (Fig. 5.13).

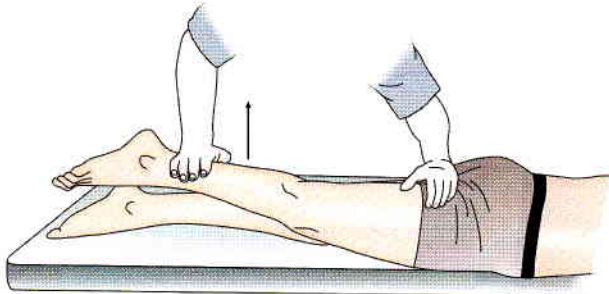


Fig. 5.7: How to test the gluteus maximus

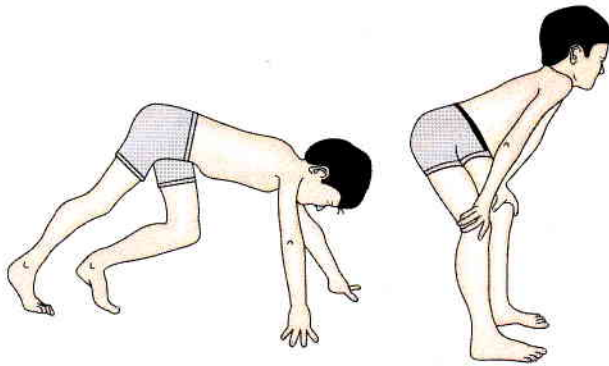


Fig. 5.8: Trying to stand up in paralysis of gluteus maximus muscle

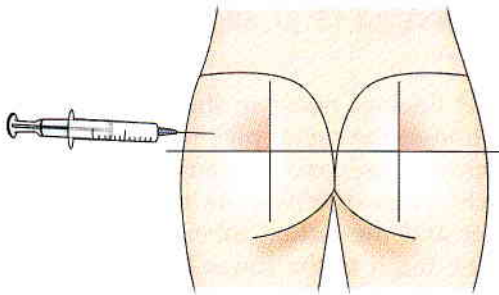
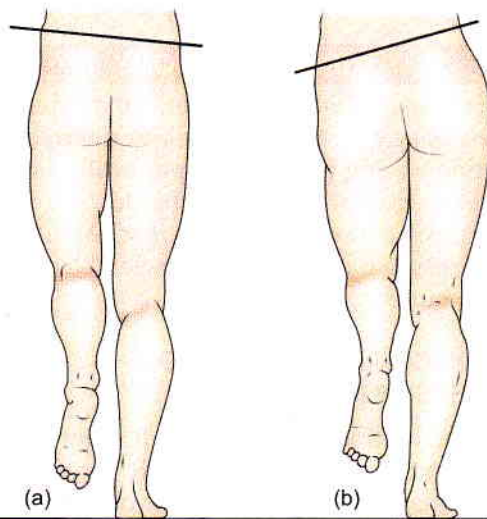


Fig. 5.9: Site of intramuscular injection



Figs 5.10a and b: (a) Normal gait, and (b) lurching gait

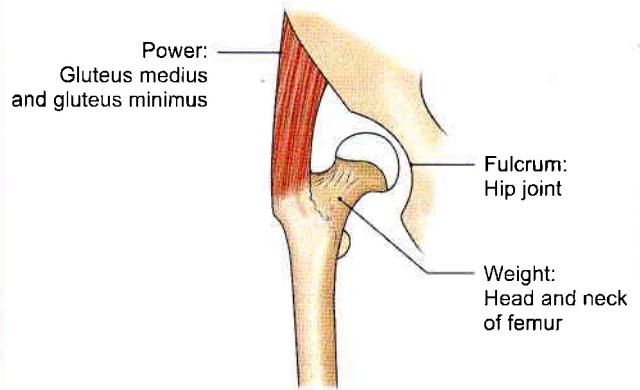
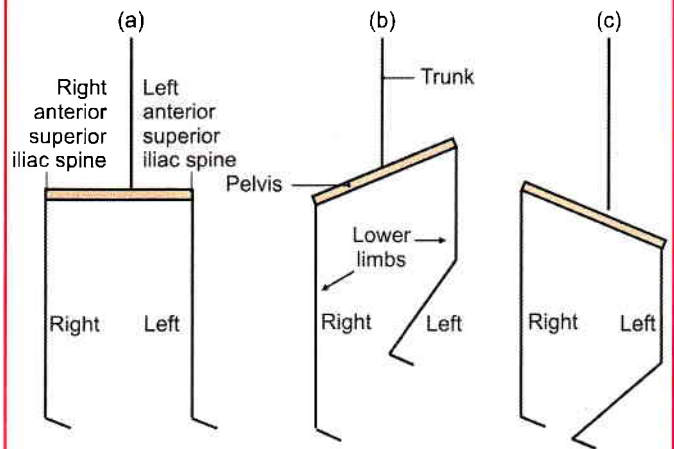


Fig. 5.11: Abductor mechanism at the hip joint



Figs 5.12a to c: Trendelenburg's sign. (a) When both feet are supporting the body weight, the pelvis (anterior superior iliac spine) on the two sides lies in the same horizontal plane, (b) when only the right foot is supporting the body weight, the unsupported side of the pelvis is normally raised by the opposite gluteal medius and minimus, and (c) if the right glutei medius and minimus are paralysed, the unsupported left side of the pelvis drops. This is a positive Trendelenburg's sign

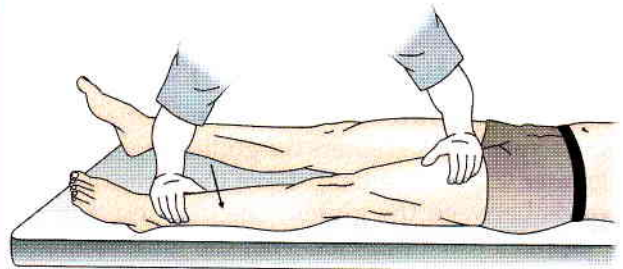


Fig. 5.13: How to test the gluteus medius

SACROTUBEROUS AND SACROSPINOUS LIGAMENTS

These two ligaments convert the greater and lesser sciatic notches of the hip bone into foramina of the same name.

The *sacrospinous ligament* is a long and strong ligament extending between the medial margin of

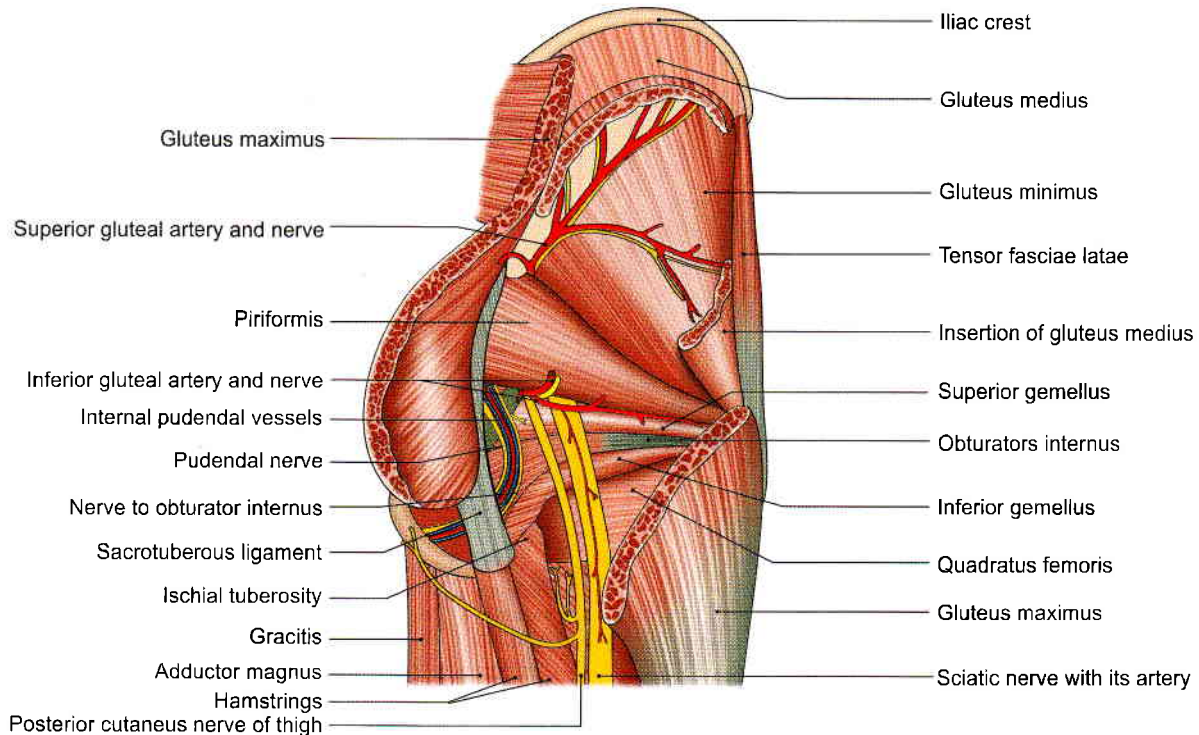


Fig. 5.14: Structures in the gluteal region

ischial tuberosity and the posterior iliac spines. It forms the posterolateral boundary of the outlet of the pelvis (Fig. 5.14).

The *sacrospinous ligament* is a short, thick, triangular band situated deep to the sacrotuberous ligament. It is attached:

- Laterally to the ischial spine
- Medially to the sacrococcygeal junction.

NERVES OF THE GLUTEAL REGION

SUPERIOR GLUTEAL NERVE (L4, L5, S1)

The superior gluteal nerve is a branch of the lumbosacral plexus. It enters the gluteal region through the greater sciatic foramen, above the piriformis, runs forwards between the gluteus medius and minimus, and supplies three muscles, viz., the gluteus medius, the gluteus minimus and the tensor fasciae latae (Fig. 5.14).

INFERIOR GLUTEAL NERVE (L5, S1, S2)

This is also a branch of the sacral plexus given off in the pelvis. It enters the gluteal region through the greater sciatic foramen below the piriformis, and ends by supplying the gluteus maximus only, to which it is fully committed (Fig. 5.14).

SCIATIC NERVE (L4, L5; S1, S2, S3)

Course

This is the thickest nerve in the body. It is the main continuation of the sacral plexus. It enters the gluteal region through the greater sciatic foramen below the piriformis, runs downwards between the greater trochanter and the ischial tuberosity, and enters the back of the thigh at the lower border of the gluteus maximus. It does not give any branches in the gluteal region (Fig. 5.14).

It is described in detail in Chapter 7.

CLINICAL ANATOMY

- “*Sciatic nerve block*” is done by injecting an anaesthetic agent few cm below the midpoint of the line joining posterior superior iliac spine and upper border of greater trochanter.
- Piriformis syndrome occurs if sciatic nerve gets compressed by piriformis muscle. It leads to pain in the buttock.

POSTERIOR CUTANEOUS NERVE OF THE THIGH (S1, S2, S3)

It is a branch of the sacral plexus. It enters the gluteal region through the greater sciatic foramen, below the piriformis, and runs downwards medial or posterior to the sciatic nerve. It continues in the back of the thigh immediately deep to the deep fascia (Figs 5.6 and 5.14).



The nerve gives:

- a. A perineal branch which crosses the ischial tuberosity, enters the urogenital triangle of the perineum, and supplies the skin of the posterior two-thirds of the scrotum, or labium majus.
- b. Gluteal branches which wind upwards round the lower border of the gluteus maximus, and supply the skin of the posteroinferior quadrant of the gluteal region.

NERVE TO QUADRATUS FEMORIS (L4, L5, S1)

This nerve arises from the sacral plexus, enters the gluteal region through the greater sciatic foramen below the piriformis, and runs downwards deep to the sciatic nerve, the obturator internus and the gemelli. It supplies the quadratus femoris, the gemellus inferior and the hip joint (Fig. 5.9).

PUDENDAL NERVE (S2, S3, S4)

This is a branch of the sacral plexus. Only a small part of this nerve is seen in the gluteal region. It enters this region through the greater sciatic foramen. It then crosses the apex or lateral end of the sacrospinous ligament, medial to the internal pudendal vessels. It leaves the gluteal region by passing into the lesser sciatic foramen through which it enters the ischioanal fossa (Fig. 5.14).

NERVE TO THE OBTURATOR INTERNUS (L5, S1, S2)

This is a branch of the sacral plexus. It enters the gluteal region through the greater sciatic foramen and crosses the ischial spine, lateral to the internal pudendal vessels, to re-enter the pelvis. It supplies both the obturator internus and the gemellus superior muscles.

PERFORATING CUTANEOUS NERVE (S2, S3)

This is a branch of the sacral plexus. It pierces the lower part of the sacrotuberous ligament, winds round the lower border of the gluteus maximus, and supplies the skin of the posteroinferior quadrant of the gluteal region.

ARTERIES OF GLUTEAL REGION

SUPERIOR GLUTEAL ARTERY

It is a branch of the posterior division of the internal iliac artery.

Course and Distribution

It enters the gluteal region through the greater sciatic foramen passing above the piriformis along with the superior gluteal nerve. In the foramen, it divides into superficial and deep branches. The *superficial branch* supplies the gluteus maximus (Figs 5.6 and 5.14).

The *deep branch* subdivides into superior and inferior branches, which run along the anterior and inferior gluteal lines respectively, between the gluteus medius and the gluteus minimus. The superior division ends at the anterior superior iliac spine by anastomosing with the ascending branch of the lateral circumflex femoral artery. The inferior division takes part in the trochanteric anastomoses.

INFERIOR GLUTEAL ARTERY

It is a branch of the anterior division of the internal iliac artery.

Course and Distribution

It enters the gluteal region by passing through the greater sciatic foramen, below the piriformis, along with the inferior gluteal nerve. It supplies:

- 1 *Muscular branches* to gluteus maximus and to all the muscles deep to it below the piriformis.
- 2 *Cutaneous branches* to the buttock and the back of the thigh (Figs 5.6 and 5.14).
- 3 *An articular branch* to the hip joint.
- 4 *A cruciate anastomotic branch*.
- 5 *An artery to the sciatic nerve*, which represents the axis artery in this region, and may at times be quite large.
- 6 *A coccygeal branch* which supplies the area over the coccyx.

INTERNAL PUDENDAL ARTERY

This is a branch of the anterior division of the internal iliac artery.

It enters the gluteal region through the greater sciatic foramen (Fig. 5.14). It has a very short course in the gluteal region.

It crosses the ischial spine and leaves the gluteal region by passing into the lesser sciatic foramen through which it reaches the ischioanal fossa.

TROCHANTERIC ANASTOMOSES

This is situated near the trochanteric fossa, and supplies branches to the head of the femur. It is shown in Flow chart 5.1.

CRUCIATE ANASTOMOSES

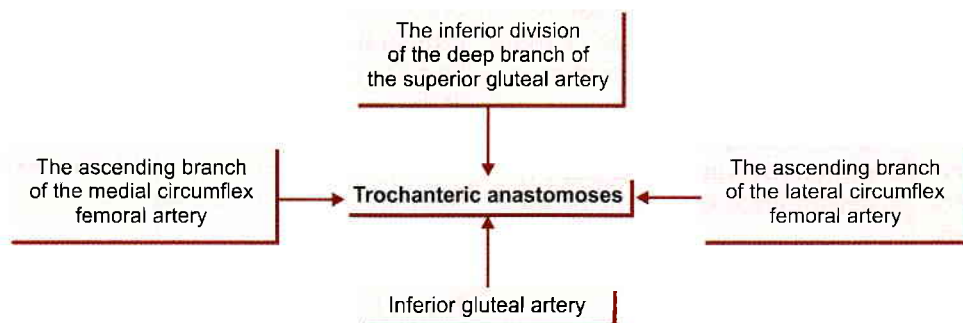
This anastomosis is situated over the upper part of the back of the femur at the level of the middle of the lesser trochanter. It is shown in Flow chart 5.2.

STRUCTURES PASSING THROUGH THE GREATER SCIATIC FORAMEN (GATEWAY OF GLUTEAL REGION)

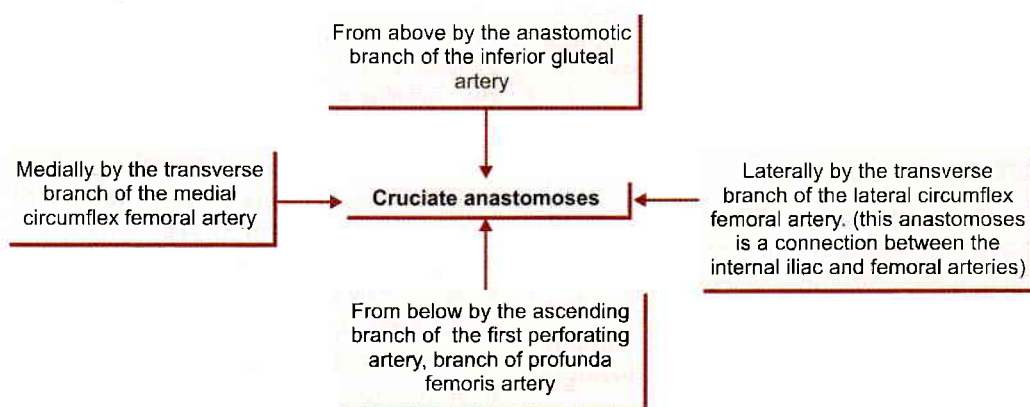
- 1 The piriformis, emerging from the pelvis fills the foramen almost completely. It is the key muscle of the region.



Flow chart 5.1: Trochanteric anastomoses



Flow chart 5.2: Cruciate anastomoses



2 Structures passing above the piriformis are:

- a. Superior gluteal nerve.
- b. Superior gluteal vessels (Fig. 5.14).

3 Structures passing below the piriformis are:

- a. Inferior gluteal nerve.
- b. Inferior gluteal vessels.
- c. Sciatic nerve (Fig. 5.14).
- d. Posterior cutaneous nerve of thigh.
- e. Nerve to quadratus femoris.
- f. Pudendal nerve.
- g. Internal pudendal vessels.
- h. Nerve to obturator internus.

The last three structures, after a short course in the gluteal region, enter the lesser sciatic foramen, where the pudendal nerve and internal pudendal vessels run in the pudendal canal.

STRUCTURES PASSING THROUGH THE LESSER SCIATIC FORAMEN

- 1 Tendon of obturator internus.
- 2 Pudendal nerve (Fig. 5.14).
- 3 Internal pudendal vessels.
- 4 Nerve to obturator internus.

The upper and lower parts of the foramen are filled up by the origins of the two gemelli muscles.

FACTS TO REMEMBER

- Gluteus maximus is the antigravity, postural thickest muscle of the body. It contains red fibres.
- Sciatic nerve is the thickest nerve of the body.
- Intramuscular injections are given in the upper and lateral quadrant of the gluteal region.
- Greater sciatic notch is the gateway of the gluteal region.
- Sciatic nerve and pudendal nerve do not supply any structure in the gluteal region.
- Piriformis is the key muscle of the gluteal region.
- Sciatic nerve and its branches supply the hamstring muscles, muscles of all the three compartments of the leg and the muscles of the sole.
- Sciatic nerve is accompanied by a thin artery, the sciatic artery, which is part of the axial artery of the lower limb.
- Lesser sciatic foramen is the gateway of the perineal region.
- Sciatic nerve lies on the femur for a very short distance between lower border of quadratus femoris and upper border of adductor magnus muscles. At this site it may get compressed when one sits on a stool or a bench; leading to harmless condition, the sleeping foot.

**CLINICOANATOMICAL PROBLEM**

A woman of 30 years complained of pain in her elbow joints. She also has pain in her calf muscles, and was advised "Neurobion injections".

Where should the injection be given and why?

Ans: The "neurobion injections" are to be given by intramuscular route. The site of the injection is upper lateral quadrant of the gluteal region. Gluteal region

is a big region extending along the iliac crest till the midline posteriorly. It extends below on the ischial tuberosity and laterally till the greater trochanter of femur. The upper lateral quadrant is safe as there are no important nerve or blood vessel here. The lower and medial quadrant contains sciatic nerve and must be avoided. The injection is given in big gluteus medius muscle and is well absorbed in the circulating system.

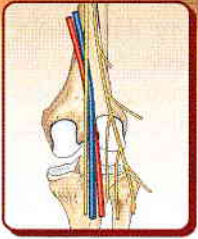
MULTIPLE CHOICE QUESTIONS

- Intramuscular injections in upper and lateral quadrant of gluteal region are given in:
 - Glutei maximus and minimus
 - Gluteus medius
 - Glutei maximus and erector spinae
 - Gluteus maximus
- Lurching gait is due to paralysis of which two muscles?
 - Glutei medius and minimus
 - Glutei maximus and minimus
 - Glutei maximus and medius
 - Gluteus maximus
- Which muscle is not under cover of gluteus maximus?
 - Piriformis
 - Quadratus femoris
 - Sartorius
 - Obturator internus with two gemelli
- What is origin of piriformis?
 - From upper three sacral vertebrae
 - Lower margin of lesser sciatic notch
 - Upper margin of lesser sciatic notch
 - Lower margin of greater sciatic notch
- Which of the following is not supplied by superior gluteal nerve?
 - Gluteus medius
 - Gluteus minimus
 - Gluteus maximus
 - Tensor fasciae latae
- Which muscle is one of the most powerful and bulkiest muscle in human?
 - Gluteus maximus
 - Obturator internus
 - Quadriceps femoris
 - Soleus

ANSWERS

1. b 2. a 3. c 4. a 5. c 6. a

6



Popliteal Fossa

The popliteal artery is auscultated for measuring the blood pressure in the lower limb.

INTRODUCTION

Popliteal (Latin *hamstring of knee*) fossa is a shallow diamond shaped depression felt best at the back of knee joint, when the joint is semi-flexed. It corresponds to the cubital fossa of the forearm.

SURFACE LANDMARKS

- 1 *Lateral and medial condyles* of femur and tibia can be identified easily on the sides and front of the knee.
- 2 *Head of the fibula* is a bony prominence situated just below the posterolateral aspect of the lateral condyle of tibia.
- 3 *Common peroneal nerve* can be palpated against the posterolateral aspect of the neck of fibula, medial to the tendon of biceps femoris, by moving the finger from below upwards.
- 4 *Fibular collateral ligament* of the knee joint is felt like a rounded cord just above the head of the fibula in a flexed knee.
- 5 When the knee is flexed against resistance, the *hamstrings* can be seen and palpated easily right up to their insertion. Medially, the rounded tendon of the *semitendinosus* lies superficial to the flat tendon of *semimembranosus*. In front of these tendons there is a groove bounded anteriorly by the tendon of *adductor magnus*. Laterally, there is the tendon of *biceps femoris*. In front of this tendon there is a shallow groove bounded anteriorly by the *iliotibial tract*.
- 6 Pulsations of the *popliteal artery* can be felt in the middle of the popliteal fossa by applying deep pressure.
- 7 In the lower part of popliteal fossa, two heads of the *gastrocnemius* form rounded cushions that merge inferiorly into the calf.

POPLITEAL FOSSA

DISSECTION

Make a horizontal incision across the back of thigh at its junction of upper two-thirds with lower one-third and another horizontal incision at the back of leg at its junction of upper one-third and lower two-thirds (v), (vi) (see Fig. 5.2).

Draw a vertical incision joining the midpoints of the two horizontal incisions made (vii) (see Fig. 5.2). Reflect the skin and fascia on either side.

Find the cutaneous nerves, e.g. posterior cutaneous nerve of thigh, posterior division of medial cutaneous nerve, sural communicating nerve and short saphenous vein. Cut and clean the deep fascia.

Identify the boundaries and contents of the fossa.

Trace the tibial nerve as it courses through the centre of the popliteal fossa. Its three delicate articular branches are given off in the upper part of the fossa, cutaneous branch in the middle part and muscular branches in lower part of the fossa.

Common peroneal nerve is lying just medial to the tendon of biceps femoris muscle. Trace its branches.

Popliteal vein is deep to the tibial nerve and popliteal artery is the deepest as seen from the back. Trace all the muscular, cutaneous, genicular and terminal branches of the popliteal artery (refer to 8).

LOCATION

The popliteal fossa is a diamond-shaped depression lying behind the knee joint, the lower part of the femur, and the upper part of the tibia.

Boundaries

Superolaterally: The biceps femoris (Fig. 6.1).

Superomedially: The semitendinosus and the semimembranosus, supplemented by the gracilis, the sartorius and the adductor magnus.

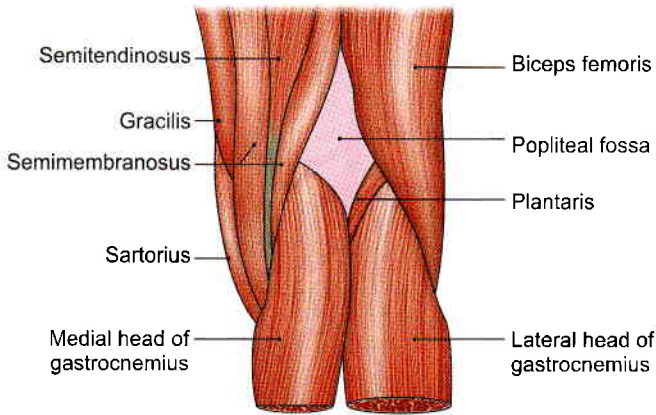


Fig. 6.1: Boundaries of the right popliteal fossa

Inferolaterally: Lateral head of the gastrocnemius supplemented by the plantaris.

Inferomedially: Medial head of the gastrocnemius.

The *roof* of the fossa is formed by deep fascia or popliteal fascia (Fig. 6.2). The superficial fascia over the roof contains:

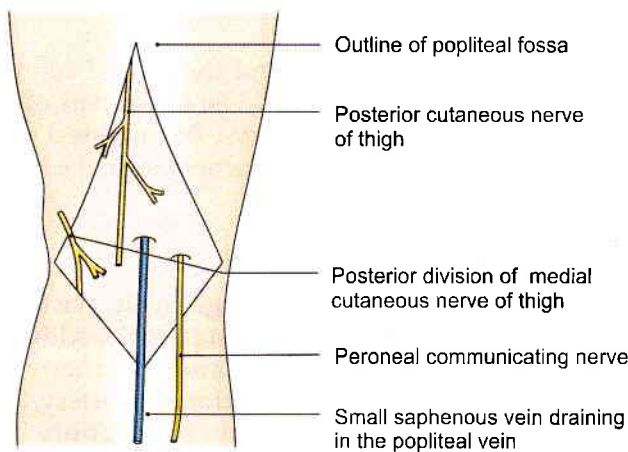


Fig. 6.2: Structures in the roof of the popliteal fossa

- a. The small saphenous vein and cutaneous nerves.
- b. Three cutaneous nerves, namely, the branches and terminal part of the posterior cutaneous nerve of the thigh, the posterior division of the medial cutaneous nerve of the thigh, and the peroneal or sural communicating nerve.

The *floor* of the popliteal fossa is formed from above downwards by:

- a. The popliteal surface of the femur.
- b. The capsule of the knee joint and the oblique popliteal ligament.
- c. The strong popliteal fascia covering the popliteus muscle (Figs 6.3a and b).

Contents of the Fossa

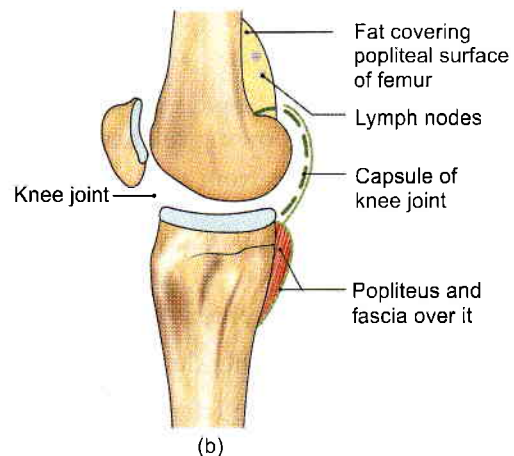
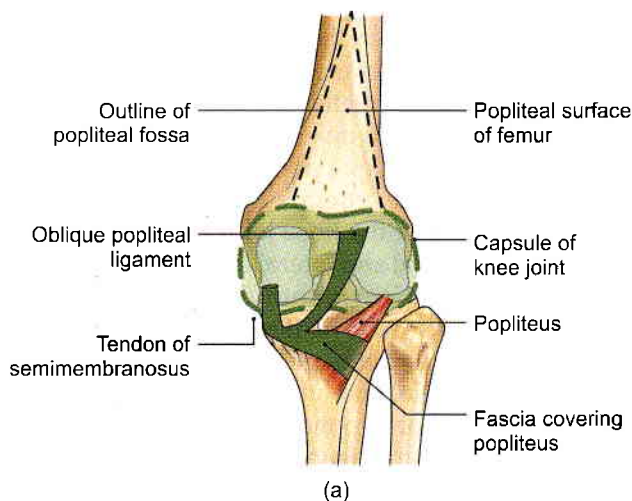
- 1 The popliteal artery and its branches (Fig. 6.4).
- 2 The popliteal vein and its tributaries.
- 3 The tibial nerve and its branches.
- 4 The common peroneal nerve and its branches.
- 5 The posterior cutaneous nerve of the thigh.
- 6 The genicular branch of the obturator nerve.
- 7 The popliteal lymph nodes.
- 8 Fat.

The popliteal vessels and the tibial nerve cross the fossa vertically, and are arranged one over the other. The tibial nerve is most superficial; the popliteal vein lies deep or anterior to tibial nerve; and the popliteal artery is deepest of all. The artery is crossed posteriorly by the vein and by the nerve. The relative position of these structures is as follows.

In the upper part of the fossa, from medial to lateral side: artery, vein and nerve (A, V, N).

In the middle part, from behind forwards: nerve, vein and artery (N, V, A).

In the lower part, from medial to lateral side: nerve, vein and artery (Fig. 6.4) (N, V, A).



Figs 6.3a and b: Floor of the popliteal fossa: (a) Surface view, and (b) vertical sectional view

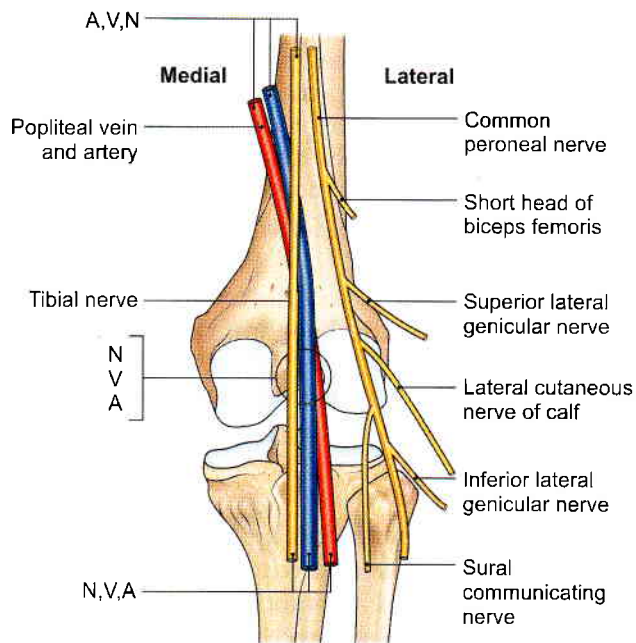


Fig. 6.4: The arrangement of the main nerves and vessels in the popliteal fossa

The common peroneal nerve crosses the fossa obliquely from the superior angle to the lateral angle, along the medial border of the biceps femoris, lying in the same superficial plane as the tibial nerve.

POPLITEAL ARTERY

Beginning, Course and Termination

Popliteal artery is the continuation of the femoral artery. It begins at the opening in the adductor magnus or hiatus magnus, i.e. at the junction of middle one-third with the lower one-third of thigh.

It runs downwards and slightly laterally, to reach the lower border of the popliteus.

It terminates at the lower border of popliteus by dividing into the anterior and posterior tibial arteries (Fig. 6.5).

Relations

The popliteal artery is the deepest structure in the popliteal fossa. It has the following relations.

Anterior or deep to the artery, from above downwards, there are:

- The popliteal surface of the femur.
- The back of the knee joint.
- The fascia covering the popliteus muscle (Fig. 6.3).

Posterior or superficially: To the tibial nerve (Fig. 6.4).

Laterally: Biceps femoris and the lateral condyle of the femur in the upper part, plantaris and the lateral head of the gastrocnemius in the lower part.

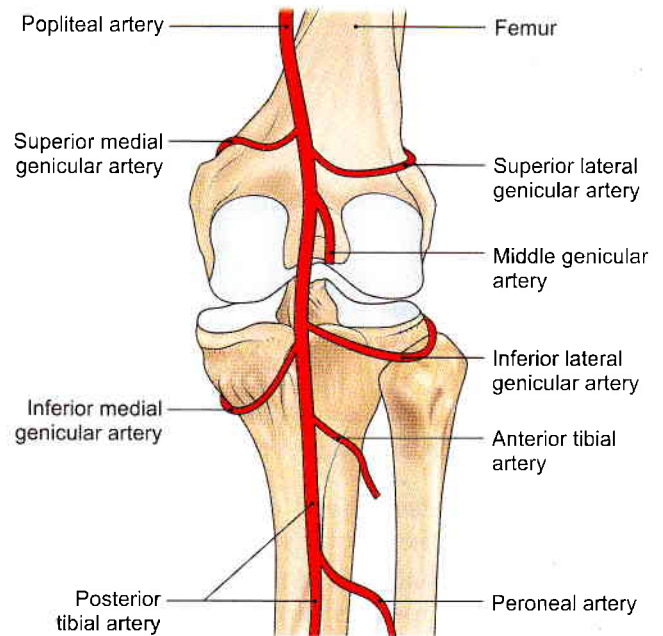


Fig. 6.5: Course of the genicular branches of the popliteal artery

Medially: Semimembranosus and the medial condyle of the femur in the upper part. The lower part of the artery is related to the tibial nerve, the popliteal vein, and the medial head of the gastrocnemius in the lower part.

Branches

Several large *muscular* branches are given off. The upper (two or three) muscular branches supply the adductor magnus and the hamstrings, and terminate by anastomosing with the fourth perforating artery. The lower muscular or sural branches supply the gastrocnemius, the soleus and the plantaris.

Cutaneous branches arise either directly from the popliteal artery, or indirectly from its muscular branches. One cutaneous branch usually accompanies the small saphenous vein.

Genicular branches are five in number, two superior, two inferior and one middle. The *middle genicular artery* pierces the oblique popliteal ligament of the knee, and supplies the cruciate ligaments and the synovial membrane of the knee joint (Fig. 6.5).

The medial and lateral *superior genicular arteries* wind round the corresponding sides of the femur immediately above the corresponding condyle, and pass deep to the hamstrings.

The medial and lateral *inferior genicular arteries* wind round the corresponding tibial condyles, and pass deep to the collateral ligaments of the knee. All these arteries reach the front of the knee and take part in forming the anastomoses around the knee.



CLINICAL ANATOMY

- Blood pressure in the lower limb is recorded from the popliteal artery. In coarctation of the aorta, the popliteal pressure is lower than the brachial pressure. Figure 6.6 shows palpation of artery.
- Constant pulsations of the popliteal artery against the unyielding tendon of the adductor magnus may cause changes in the vessel wall, leading to narrowing and occlusion of the artery. Sudden occlusion of the artery may cause gangrene up to the knee, but this is usually prevented by the collateral circulation through the profunda femoris artery.
- The popliteal artery is fixed to the capsule of the knee joint by a fibrous band present just above the femoral condyles. This may be a source of continuous traction or stretching on the artery, causing primary thrombosis of the artery in young subjects.
- When the popliteal artery is affected by atherosclerosis, the lower part of artery usually remains patent where grafts can be tried.
- The popliteal artery is more prone to aneurysm than many other arteries of the body.

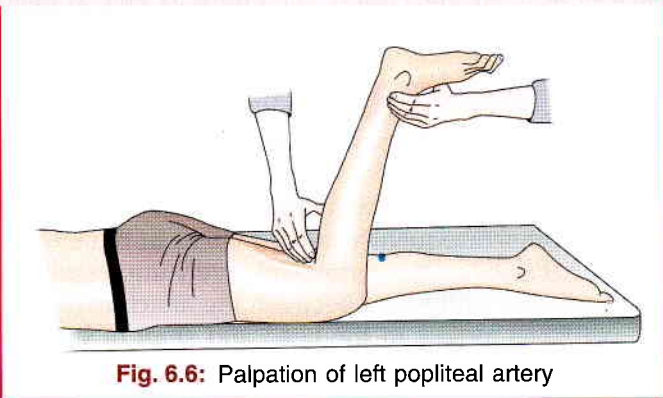


Fig. 6.6: Palpation of left popliteal artery

POPLITEAL VEIN

It begins at the lower border of the popliteus by the union of veins accompanying the anterior and posterior tibial arteries. It is medial to the popliteal artery in the lower part of the fossa; posterior to the artery in the middle; and posterolateral to it in the upper part of the fossa. The vein continues as the femoral vein at the opening in the adductor magnus. The popliteal vein receives:

- 1 The small saphenous vein (Fig. 6.2).
- 2 The veins corresponding to the branches of the popliteal artery (Fig. 6.4).

TIBIAL NERVE

Root value: Ventral divisions of ventral rami of L4, L5, S1, S2, S3.

Course

This is the larger terminal branch of the sciatic nerve. It lies superficial or posterior to the popliteal vessels (Fig. 6.7). It extends from the superior angle to the inferior angle of the popliteal fossa, crossing the popliteal vessels from lateral to medial side.

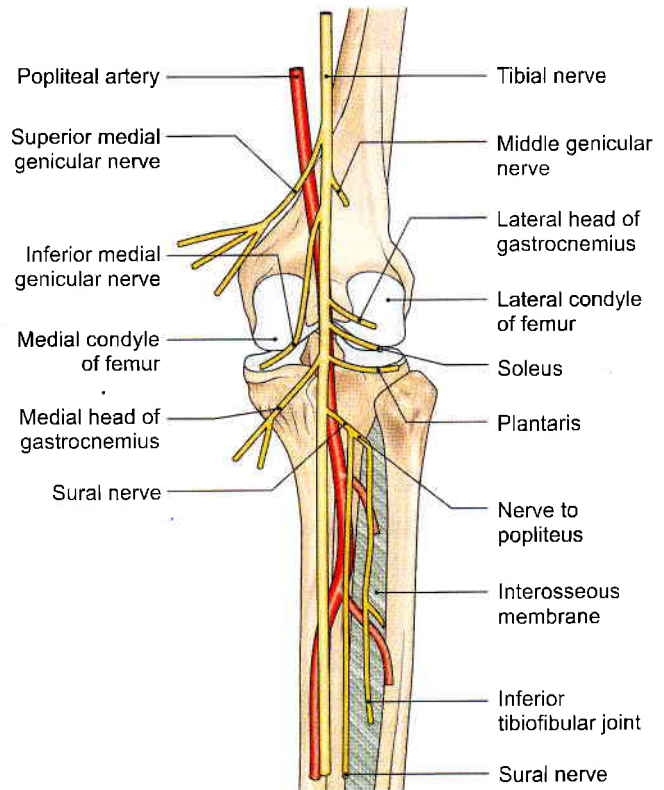


Fig. 6.7: The distribution of tibial nerve

Branches

- 1 Three genicular or articular branches arise in the upper part of the fossa these are:
 - a. Superior medial genicular nerve lies above the medial condyle of femur, deep to the muscles.
 - b. Middle genicular nerve pierces the posterior part of the capsule of the knee joint to supply structures in the intercondylar notch of femur (Fig. 6.7).
 - c. Inferior medial genicular nerve lies along the upper border of popliteus and reaches inferior to the medial condyle of tibia.
- 2 Cutaneous nerve is called *sural* which originates in the middle of the fossa and leaves it at the inferior angle. It supplies the skin of lower half of back of leg and whole of lateral border of the foot till the tip of little toe.
- 3 Muscular branches arise in the distal part of the fossa for the lateral and medial heads of gastrocnemius, soleus, plantaris and popliteus.



The nerve to the popliteus crosses the popliteal artery, runs downwards and laterally, winds round the lower border of the popliteus, and supplies it from its deep (anterior) surface. In addition to the popliteus, the nerve also supplies the tibialis posterior, the superior tibiofibular joint, the tibia, the interosseous membrane, and the inferior tibiofibular joint.

CLINICAL ANATOMY

- Most of the muscular branches of tibial nerve arise from its lateral side except to medial head of gastrocnemius. So the medial side of the nerve is safe.
- Damage to tibial nerve causes motor and sensory loss.
 - a. **Motor loss:** Superficial and deep muscles of calf and intrinsic muscles of sole.
 - b. **Sensory loss:** Loss of sensation on whole of sole of foot, plantar aspect of digits and nail beds on dorsum of foot.

COMMON PERONEAL NERVE

Root value: Dorsal divisions of ventral rami of L4, L5, S1, S2.

Course

This is the smaller terminal branch of the sciatic nerve. It lies in the same superficial plane as the tibial nerve (Fig. 6.4). It extends from the superior angle of the fossa to the lateral angle, along the medial border of the biceps femoris. Continuing downwards and forwards, it winds round the posterolateral aspect of the neck of the fibula, pierces the peroneus longus, and divides into the superficial and deep peroneal nerves.

Branches

- 1 Cutaneous branches are two types:
 - a. Lateral cutaneous nerve of the calf descends to supply the skin of the upper two-thirds of the lateral side of the leg (Figs 6.4 and 9.1).
 - b. Sural communicating nerve arises in the upper part of the fossa. It runs on the posterolateral aspect of calf and joins the sural nerve (Fig. 6.4).
- 2 Articular branches:
 - a. Superior lateral genicular nerve accompanies the artery of the same name and lies above the lateral femoral condyle.
 - b. Inferior lateral genicular nerve also runs with the artery of the same name to the lateral aspect of knee joint above the head of fibula (Fig. 6.4).
 - c. Recurrent genicular nerve arises where common peroneal nerve divides into superficial and deep

peroneal nerves. It ascends anterior to the knee joint and supplies tibialis anterior muscle in addition to the knee joint (*see* Fig. 8.9).

- 3 Muscular branches do not arise from this nerve. However, it may give a branch to the short head of biceps femoris.

POSTERIOR CUTANEOUS NERVE OF THIGH

It is a content of the upper half of the popliteal fossa. It pierces the deep fascia about the middle of the fossa, and supplies the skin up to the middle of the back of the leg.

GENICULAR BRANCH OF OBTURATOR NERVE

This is the continuation of the posterior division of the obturator nerve. It runs on the posterior surface of the popliteal artery, pierces the oblique popliteal ligament, and supplies the capsule of the knee joint.

POPLITEAL LYMPH NODES

These lie deep to the deep fascia near the termination of the small saphenous vein. They receive afferents from lateral part of sole, both superficial and deep parts of back of leg and knee joint. The efferents end in deep inguinal lymph nodes.

CLINICAL ANATOMY

- The common peroneal nerve can be palpated against the posterolateral side of the neck of the fibula (*see* Fig. 8.9). It may be injured in this area. It is the most frequently injured nerve in the lower limb (Fig. 6.8). This nerve is relatively unprotected. It may get entrapped between the attachments of peroneus longus to the head and shaft of fibula. Patients present "foot drop" which is usually painless. There is weakness of dorsiflexion of ankle and of eversion of the foot. Inversion and plantar flexion are normal and ankle jerk is intact (Fig. 6.8).
- Popliteal lymph nodes get enlarged in infection on lateral side of sole/foot. These are lying along the short saphenous vein. Short saphenous vein pierces deep fascia to drain into popliteal vein (Fig. 6.9).

ANASTOMOSES AROUND THE KNEE JOINT

- 1 Anastomoses around the knee joint is a complicated, arterial network situated around the patella and around the lower end of the femur and the upper end of the tibia.
- 2 The network is divisible into a superficial and a deep part. The *superficial part* lies partly in the superficial fascia around the patella and partly in fat behind the ligamentum patellae. The *deep part* lies on the femur

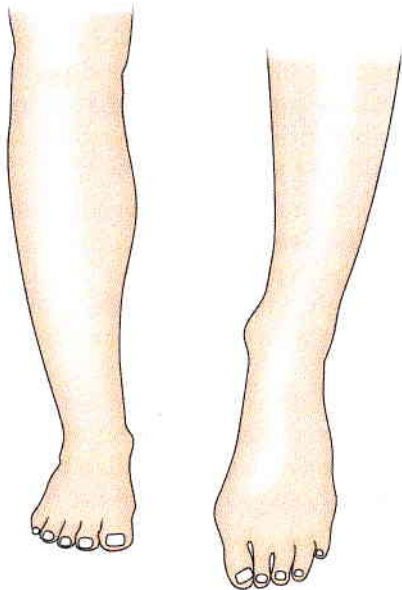


Fig. 6.8: Foot drop on the left side

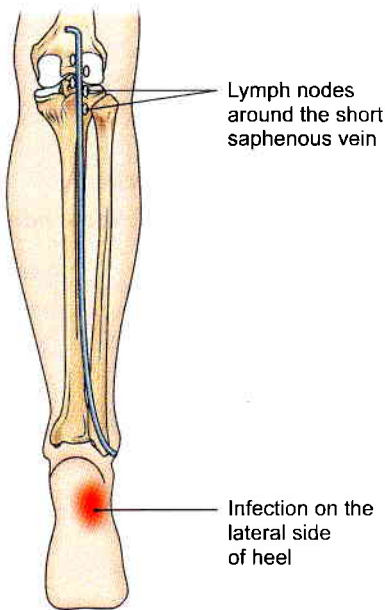


Fig. 6.9: Enlarged popliteal lymph nodes

and the tibia all around their adjoining articular surfaces.

3 It is formed:

Medially, and above the condyle

- a. The descending genicular branch of femoral (Fig. 6.10) and its saphenous branch.
- b. The superior medial genicular.

Medially and below the condyle

- a. Saphenous branch of descending genicular
- b. The inferior medial genicular.

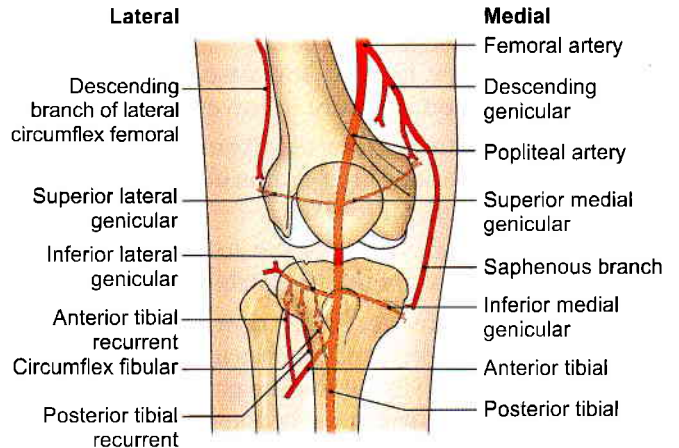


Fig. 6.10: Anastomoses around the knee joint

Laterally, and above the condyle

- a. The descending branch of the lateral circumflex femoral.

- b. The superior lateral genicular.

Laterally and below the condyle

- a. The inferior lateral genicular.

- b. Anterior tibial recurrent.

- c. Posterior tibial recurrent from anterior tibial.

- d. Circumflex fibular from posterior tibial

The medial and lateral arteries form longitudinal anastomoses on each side of the patella. The longitudinal anastomoses are interconnected to form transverse anastomoses just above and below the patella and above the tibial tuberosity.

- 4 The anastomoses supply the bones taking part in forming the knee joint, and the capsule and synovial membrane of the knee joint.

Mnemonics

Popliteal fossa

Upper part, from medial to lateral side

A V N

A—Popliteal artery

V—Popliteal vein

N—Tibial nerve

Middle part, from behind forwards

N V A

N—Tibial nerve

V—Popliteal vein

A—Popliteal artery

Lower part, from medial to lateral side

N V A

N—Tibial nerve

V—Popliteal vein

A—Popliteal artery





FACTS TO REMEMBER

- Popliteal artery is used for auscultating while measuring blood pressure in lower limb
- Short saphenous vein starting from the lateral end of the dorsal venous arch drains into the popliteal vein in the popliteal fossa.
- Popliteus muscle unlocks the locked knee joint before it is flexed by the hamstring muscles.
- Tibial nerve runs vertically down the popliteal fossa. It gives genicular branches in the upper part, cutaneous branch in the middle part and muscular branches in the lower part of the fossa.
- Common peroneal nerve as it winds round the neck of fibula is the most common injured nerve in the lower limb, resulting in foot drop.

CLINICOANATOMICAL PROBLEM

A middle aged person complains of severe weakness in both the lower limbs. This blood pressure in the lower limbs was quite less than that of upper limb

- How is blood pressure in lower limb taken?
- What could be the cause of low BP?

Ans: The blood pressure in lower limb is taken by auscultating the deeply placed popliteal artery. The patient has to lie in prone position. The larger cuff is tied in the thigh. Pressure is raised and released slowly. Auscultatory sounds are heard on the popliteal artery.

The possible reason could be "coarctation of aorta", i.e. narrowing of the aorta so that blood supply to lower limb decreases causing a fall in blood pressure. The coarctation needs to be treated surgically.

MULTIPLE CHOICE QUESTIONS

- The inferomedial boundaries of popliteal fossa is formed by:
 - Lateral head of gastrocnemius
 - Medial head of gastrocnemius
 - Biceps femoris
 - Semitendinosus, gracilis, sartorius
- Which is not the content of popliteal fossa?
 - Popliteal artery and its branches
 - Popliteal vein and its tributaries
 - Tibial nerve
 - Long saphenous vein
- Popliteal artery is continuation of:
 - Femoral artery
 - Tibial artery
 - Internal pudendal artery
 - Obturator artery
- Blood pressure in lower limb is recorded from:
 - Internal pudendal artery
 - Popliteal artery
 - Tibial artery
 - Femoral artery
- Which of the following is the thickest nerve of the body?
 - Sciatic nerve
 - Pudendal nerve
 - Superior gluteal nerve
 - Nerve to quadratus femoris
- Structure passing through lesser sciatic foramen is:
 - Sciatic nerve
 - Pudendal nerve
 - Nerve to quadratus femoris
 - Superior gluteal vessels
- Tibial nerve is a subdivision of:
 - Obturator nerve
 - Sciatic nerve
 - Femoral nerve
 - Common peroneal nerve
- Foot drop is due to injury of:
 - Common peroneal nerve
 - Superficial peroneal nerve
 - Femoral nerve
 - Tibial nerve

ANSWERS

1. b 2. d 3. a 4. b 5. a 6. b 7. b 8. a



Back of Thigh

Pressure on the sciatic nerve between the edge of a chair and the hard femur results in sleeping foot, even if one is wide awake.
—Krishna Garg

INTRODUCTION

The posterior compartment of the thigh is also called the flexor compartment. It is incompletely separated from the medial compartment by the poorly defined posterior intermuscular septum. The adductor magnus is a component of both these compartments.

MUSCLES AND NERVES

DISSECTION

Give a vertical incision on the back of intact skin left after the dissections of gluteal region and the popliteal fossa (viii) (see Fig. 5.2). Reflect the skin and fasciae on either side. Clean the hamstring muscles and study their features from the Tables 7.1 and 7.2.

Sciatic nerve was seen in the gluteal region. Identify its branches in back of thigh to each of the hamstring muscles including occasionally for the short head of biceps femoris muscle. Trace the two terminal divisions of this nerve.

Separate the hamstring muscles to expose the ischial part of the composite or hybrid adductor magnus muscle.

Look for insertion of adductor longus, into the linea aspera of femur.

Trace the profunda femoris vessels behind adductor longus including its perforating branches (refer to 6.2).

Cutaneous Innervation

The skin over the back of the thigh is supplied by branches from the posterior cutaneous nerve of the thigh (see Fig. 6.2).

MUSCLES OF THE BACK OF THIGH

The muscles of the back of the thigh are called the *hamstring muscles*. They are the semitendinosus, the

semimembranosus, the long head of the biceps femoris, and the ischial head of the adductor magnus (Figs 7.1 to 7.4).

The hamstrings share the following characters.

- Origin from the ischial tuberosity (see Fig. 2.6).
- Insertion into one of the bones of the leg.

The adductor magnus reaches only up to the adductor tubercle of the femur, but is included amongst the hamstrings because the tibial collateral ligament of the knee joint is, morphologically, the degenerated tendon of this muscle. The ligament is attached to medial epicondyle, two millimeters from the adductor tubercle.

- Nerve supply from the tibial part of the sciatic nerve.
- The muscles act as flexors of the knee and extensors of the hip.

The attachments hamstrings are given in Tables 7.1 and 7.2.

CLINICAL ANATOMY

- Hamstring muscles lying at the back of the knee can be accidentally or deliberately slashed or cut. If cut, the person cannot run, as these muscles are required for extension of the hip and flexion of the knee, movements essential in walking/running.
- Hamstrings have variable length. Some persons cannot touch their toes with fingers while standing straight as their hamstring muscles are rather short.
- The inflammation of semimembranosus bursa is called *semimembranosus bursitis*. The bursa becomes more prominent during extension of knee, and disappears during flexion of knee (Fig. 7.5).

**Table 7.1: Muscles of the back of thigh**

<i>Muscle</i>	<i>Origin from</i>	<i>Insertion into</i>
1. Semitendinosus It is so named because it is muscular in upper part and has a long tendon of insertion. It lies posteromedially in the thigh, superficial to the semimembranosus (Fig. 7.1)	From the inferomedial impression on the upper part of the ischial tuberosity, in common with the long head of the biceps femoris (Fig. 7.1)	Into the upper part of the medial surface of the tibia behind the sartorius and the gracilis (see Fig. 4.2b)
2. Semimembranosus It is so named because it has a flat tendon of origin. It lies posteromedially in the thigh, deep to the semitendinosus (Fig. 7.2)	From the superolateral impression on the upper part of the ischial tuberosity.	Into the groove on the posterior surface of the medial condyle of the tibia. Expansions from the tendon form the oblique popliteal ligament, and the fascia covering the popliteus (see Fig. 6.3a)
3. Biceps femoris It has two heads of origin long and short. It lies posterolaterally in the thigh (Fig. 7.1)	a. <i>Long head:</i> From the inferomedial impression on the upper part of the ischial tuberosity; in common with the semitendinosus, and also from the lower part of the sacrotuberous ligament b. <i>Short head:</i> From the lateral lip of the linea aspera between the adductor magnus and the vastus lateralis, from the upper two-thirds of the lateral supracondylar line, and from the lateral intermuscular septum	The tendon is either folded around, by the fibular collateral ligament. It is inserted into the head of the fibula in front of its apex or styloid process (see Fig. 2.24)
4. Adductor magnus (see Fig. 4.1) This is the largest muscle of this compartment. Because of its double nerve supply, it is called a hybrid muscle (Figs 7.3 and 7.4)	a. Lower lateral part of the ischial tuberosity b. Ramus of the ischium c. Lower part of the inferior ramus of the pubis	a. Medial margin of gluteal tuberosity b. Linea aspera c. Medial supracondylar line d. Adductor tubercle

Table 7.2: Nerve supply and actions of muscles

<i>Muscle</i>	<i>Nerve supply</i>	<i>Actions</i>
1. Semitendinosus	Tibial part of sciatic nerve (L5, S1, S2)	Chief flexor of the knee and medial rotator of the leg in semiflexed knee. Weak extensor of the hip
2. Semimembranosus	Tibial part of sciatic nerve (L5, S1, S2)	Chief flexor of the knee and medial rotator of the leg in semiflexed knee. Weak extensor of the hip
3. Biceps femoris	a. Long head, by tibial part of sciatic nerve b. Short head, by common peroneal part of sciatic nerve (L5, S1, S2)	Chief flexor of the knee and lateral rotator of leg in semiflexed knee. Weak extensor of the hip
4. Adductor magnus (hybrid muscle)	Double nerve supply: Adductor part by posterior division of obturator nerve Hamstring part by tibial part of sciatic nerve	Adductor part causes adduction of thigh; Ischial part helps in extension of hip and flexion of knee

SCIATIC NERVE

The sciatic nerve is the thickest nerve in the body. In its upper part, it forms a band about 2 cm wide. It begins in the pelvis and terminates at the superior angle of the popliteal fossa by dividing into the tibial and common peroneal nerves.

Origin and Root Value

This is the largest branch of the sacral plexus. Its root value is L4, L5, S1, S2, S3. It is made up of two parts, the tibial part and the common peroneal part. The tibial part is formed by the ventral divisions of the anterior primary rami of L4, L5, S1, S2, S3. The common peroneal

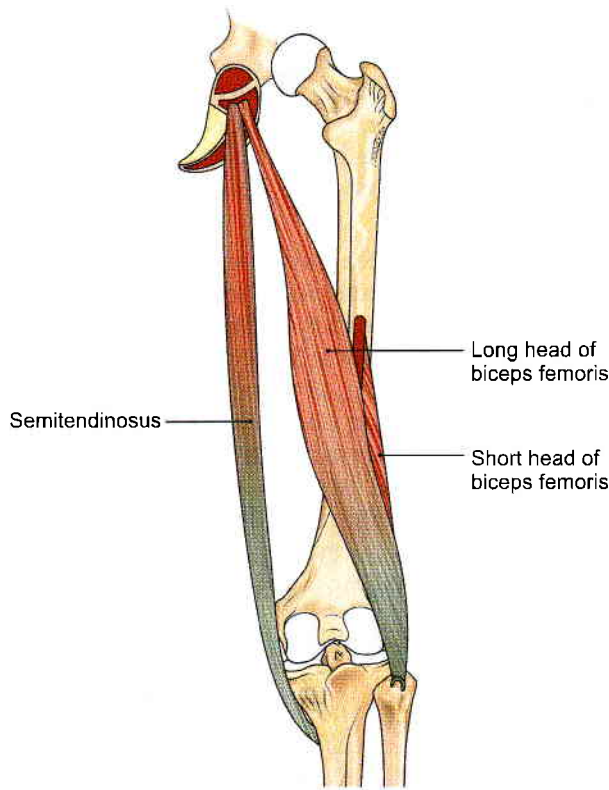


Fig. 7.1: Semitendinosus and biceps femoris

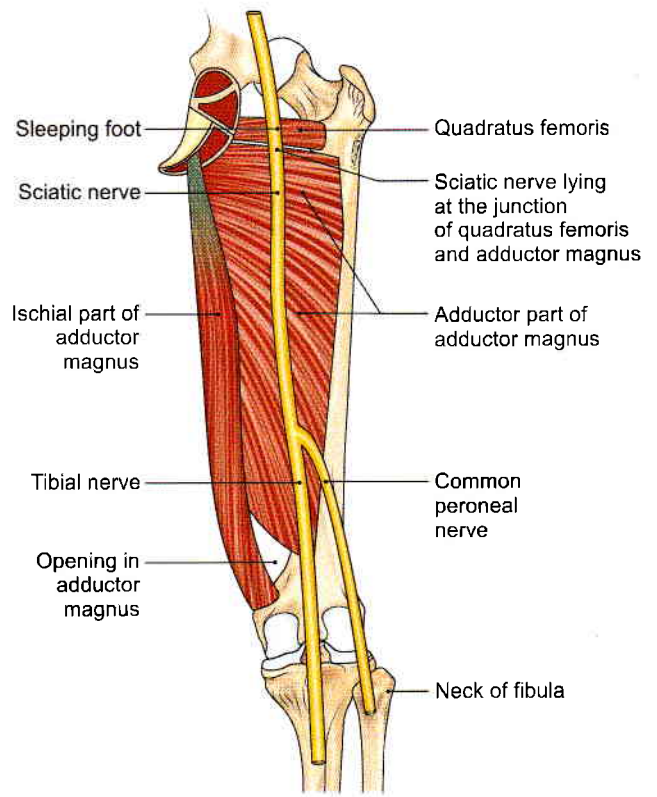


Fig. 7.3: Adductor magnus and quadratus femoris muscles with terminal branches of sciatic nerve

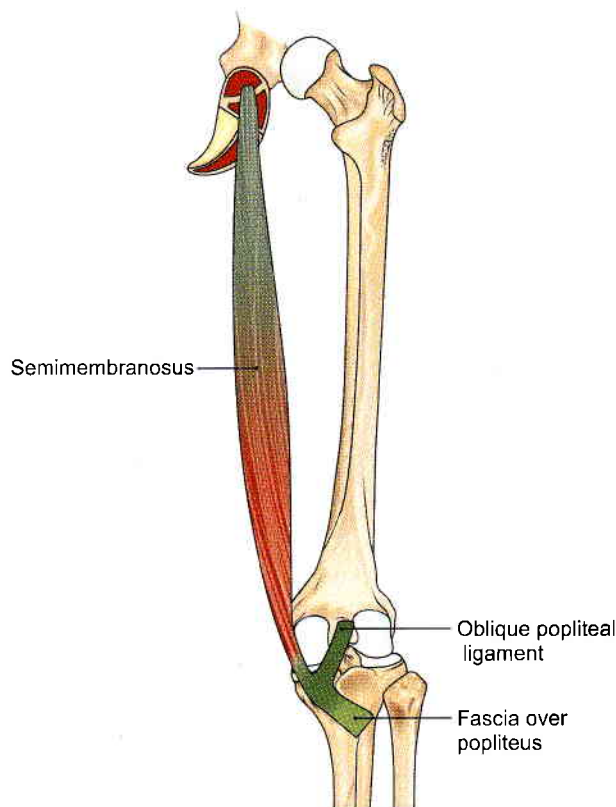


Fig. 7.2: Semimembranosus muscle

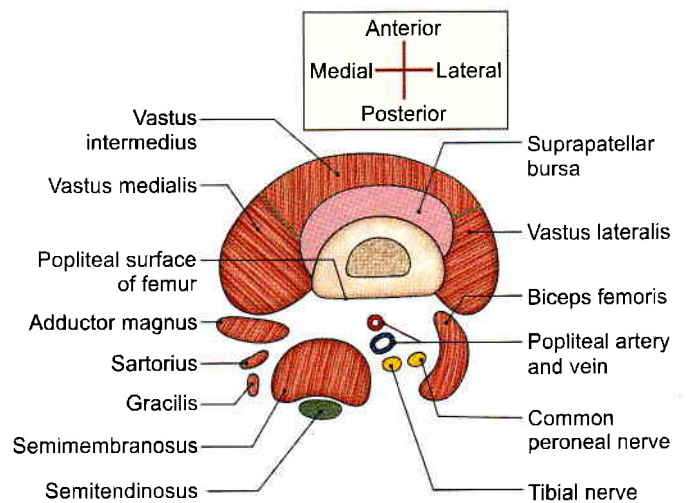


Fig. 7.4: Muscles of back of the thigh. Cross-section above the adductor tubercle

part is formed by the dorsal divisions of the anterior primary rami of L4, L5, S1, S2 (Fig. 7.6).

Course and Relations

- In the pelvis:* The nerve lies in front of the piriformis, under cover of its fascia.
- In the gluteal region:* The sciatic nerve enters the gluteal region through the greater sciatic foramen

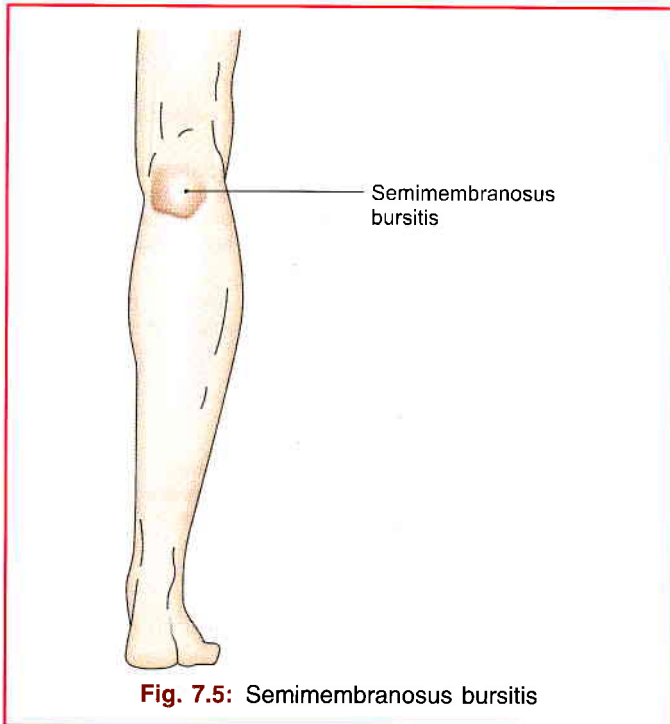


Fig. 7.5: Semimembranosus bursitis

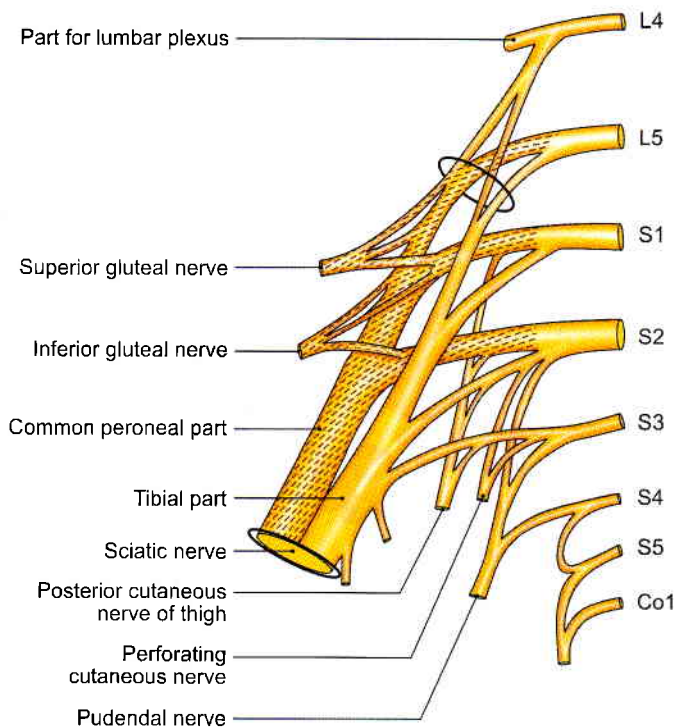


Fig. 7.6: Scheme to show the sacral plexus and its branches

below the piriformis. It runs downwards with a slight lateral convexity, passing between the ischial tuberosity and the greater trochanter. It has the following relations in the gluteal region.

Superficial or posterior: Gluteus maximus (see Fig. 5.14).

Deep or anterior:

- a. Body of the ischium.
- b. Tendon of the obturator internus with the gemelli.
- c. Quadratus femoris, obturator externus.
- d. The capsule of the hip joint.
- e. The upper, transverse fibres of the adductor magnus.

Medial: Inferior gluteal nerve and vessels.

- 3 *In the thigh:* The sciatic nerve enters the back of the thigh at the lower border of the gluteus maximus. It runs vertically downwards up to the superior angle of the popliteal fossa, at the junction of the upper two-thirds and lower one-third of the thigh, where it terminates by dividing into the tibial and the common peroneal nerves. It has the following relations in the thigh:

Superficial or posterior: The sciatic nerve is crossed by the long head of the biceps femoris (Fig. 7.7).

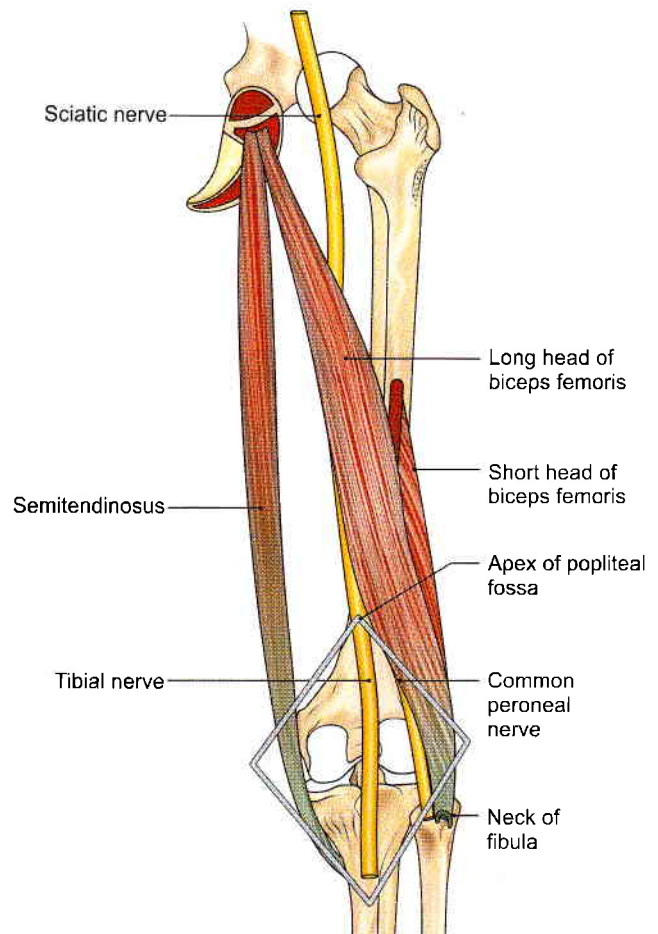


Fig. 7.7: Relations of sciatic nerve in the thigh

Deep or anterior: The nerve lies on the adductor magnus (Fig. 7.3).

Medial: The semimembranosus, and the semitendinosus.

Lateral: Biceps femoris.

The sciatic nerve is accompanied by a small companion artery which is a branch of the inferior gluteal artery. The artery runs along the sciatic nerve for some distance before sinking into its substance.

Branches

- 1 **Articular** branches to the hip joint arise in the gluteal region.
- 2 **Muscular** branches: The *tibial part* of the sciatic nerve supplies the semitendinosus, the semimembranosus, the long head of the biceps femoris, and the ischial head of the adductor magnus from its medial side. The *common peroneal part* supplies only the short head of the biceps femoris.

CLINICAL ANATOMY

- Testing the hamstring muscles hamstring muscles can be tested by requesting the patient to flex the knee against resistance in prone position (Fig. 7.8).
- Sciatic nerve lies on quadratus femoris and adductor magnus. Between the thin borders of these two muscles the nerve lies for a short distance on the femur. When a person sits on the edge of a hard table/chair, the nerve gets compressed between the edge of table and femur. It results in numbness of lower limb. But the sensations come back when foot is hit on the ground a few times and is called *sleeping foot* (Fig. 7.3).
- Shooting pain along the cutaneous distribution of the sciatic nerve and its terminal branches, chiefly the common peroneal, is known as *sciatica*. Pain usually begins in the gluteal region, and radiates along the back of the thigh, and the lateral side of the leg, to the dorsum of the foot. This is usually due to compression of one or more nerve roots forming the sciatic nerve. The cause may be disc prolapse, neuritis, etc. (Fig. 7.9).
- The semimembranosus bursa may get inflamed. The condition is called semimembranosus bursitis (Fig. 7.5).
- The sciatic nerve may be injured by penetrating wounds, dislocation of the hip. This results in loss of all movements below the knee with foot drop; sensory loss on the back of the thigh, the whole of the leg, and the foot except the area innervated by the saphenous nerve (Fig. 7.10).
- Motor loss includes loss of hamstring muscles, loss of dorsiflexors, plantarflexors, evertors and muscles of sole (Fig. 7.11)

ARTERIES OF THE BACK OF THIGH

The arteries on the back of the thigh are terminal parts of the branches of the profunda femoris. The lateral

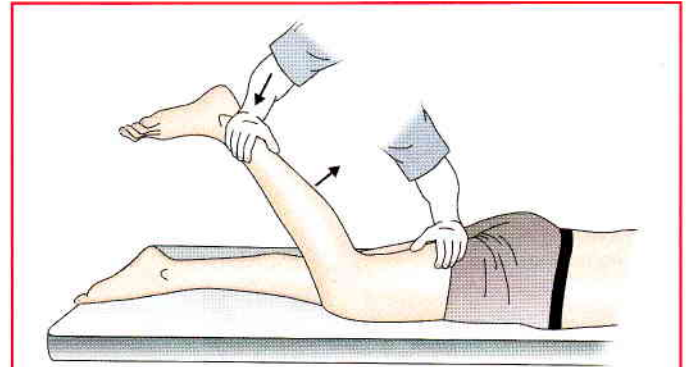


Fig. 7.8: Testing the hamstrings

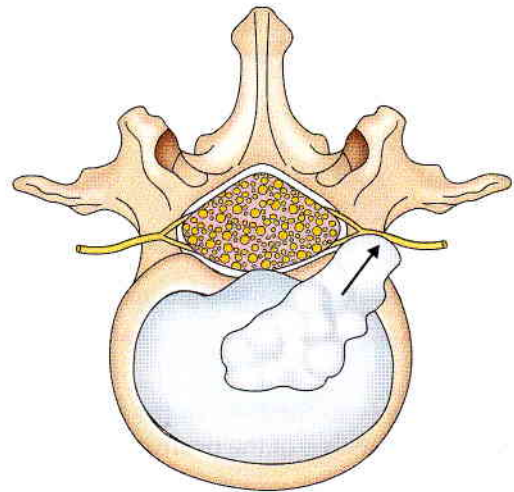


Fig. 7.9: Disc prolapse causing sciatica

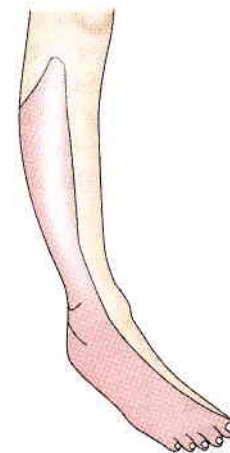


Fig. 7.10: Sensory loss over most of the leg due to injury to sciatic nerve

circumflex femoral branch of the profunda femoris divides into ascending, transverse and descending branches.

The medial circumflex femoral artery gives acetabular branch and then divides into ascending and transverse branches (Figs 7.12a and b).

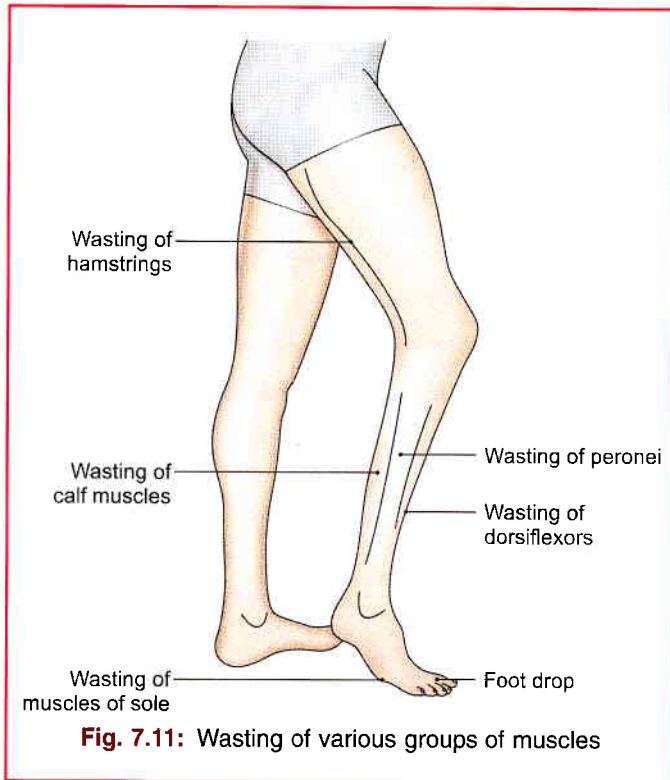


Fig. 7.11: Wasting of various groups of muscles

The main supply to the back of the thigh is through the perforating branches of the profunda femoris. These are described below.

Perforating Branches of the Profunda Femoris Artery

The profunda femoris artery gives off four perforating arteries. They arise on the front of the thigh. They then pass through the adductor magnus and wind round the back of the femur, piercing the aponeurotic origins of other muscles attached to the linea aspera. They ultimately end in the vastus lateralis (Fig. 7.13).

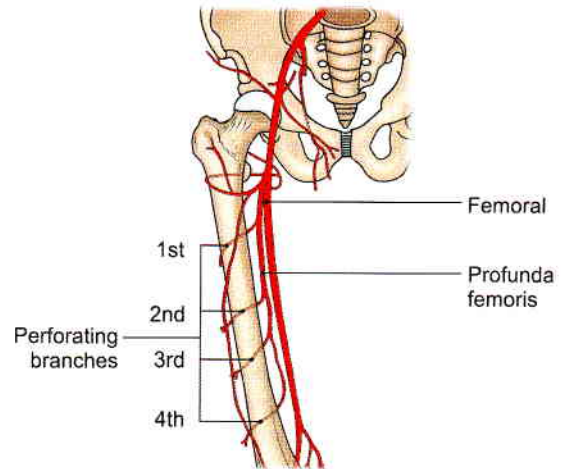


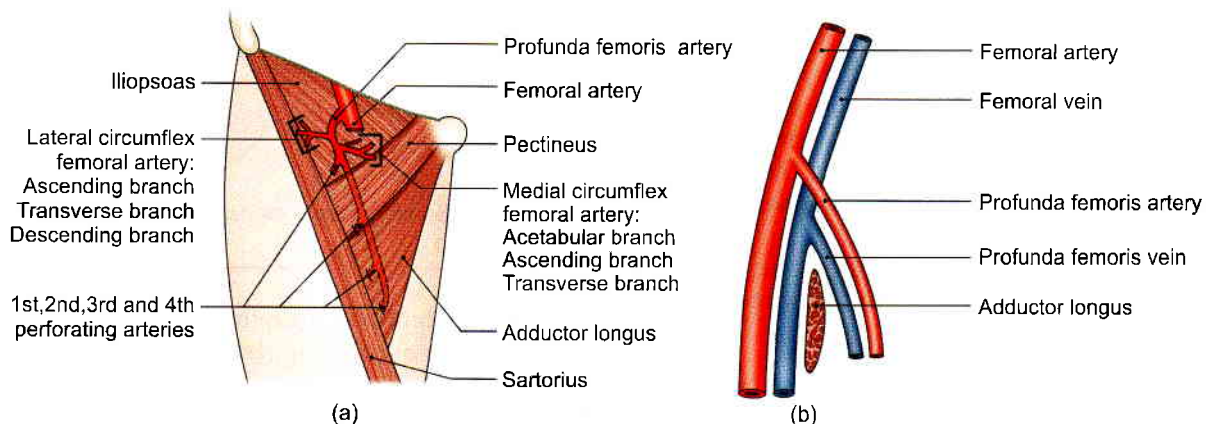
Fig. 7.13: Perforating branches of profunda femoris artery

The *first* perforating artery arises just above, or on the upper border of the adductor brevis, the second in front of the adductor brevis, the third immediately below the adductor brevis, and the fourth is the termination of the profunda femoris artery (Figs 7.12a and b). The perforating arteries give off muscular branches. They also give off cutaneous and anastomotic branches. The second perforating artery, gives off the nutrient artery to the femur.

ANASTOMOSES ON THE BACK OF THIGH

At least two distinct chains of anastomoses can be made out in the back of the thigh. One lies partly on the surface of the adductor magnus and partly in its substance. The other lies close to the linea aspera of femur. These longitudinal anastomotic chains are formed by the branches of internal iliac, the femoral and popliteal arteries. Thus from above downwards:

- 1 The gluteal arteries anastomose with each other and with the circumflex femoral arteries (*see* Flow chart 5.1).



Figs 7.12a and b: Origin and course of the profunda femoris artery: (a) Surface view, and (b) sagittal sectional view. Note that the femoral and profunda vessels straddle the adductor longus

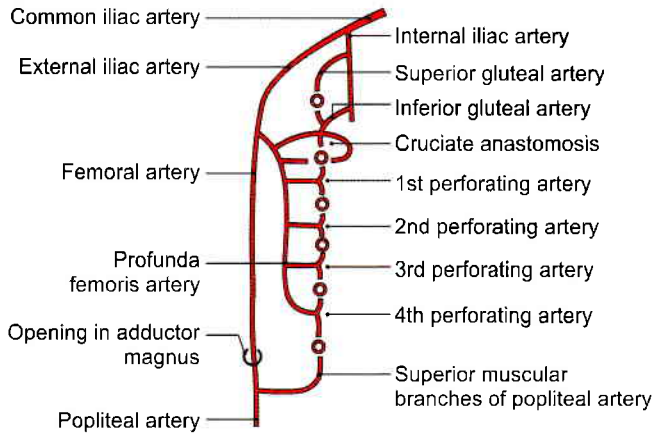


Fig. 7.14: Anastomoses on the back of thigh

- The circumflex femorals anastomose with the first perforating artery (cruciate anastomoses) (Fig. 7.14 and see Flow chart 5.2).
- The perforating arteries anastomose with one another.
- The fourth perforating artery anastomoses with the upper muscular branches of the popliteal artery.

Another anastomosis is found on the sciatic nerve. This is formed by the companion artery of the sciatic nerve and the perforating arteries.

These longitudinal anastomoses provide an alternative route of blood supply to the lower limb, bypassing the external iliac and femoral arteries.

FACTS TO REMEMBER

- Sciatic nerve is the thickest nerve of the body.
- Sleeping foot is a temporary condition.
- Hamstrings are flexors knee and weak extensors of hip.
- Adductor magnus is a hybrid muscle.
- Thin artery accompanying sciatic nerve is part of the axial artery of lower limb.

CLINICOANATOMICAL PROBLEM

A 26-year-old woman complained of severe pain in the back of her right thigh and leg.

- Which nerve is involved and what is its root value?
- What is straight leg raising test? If done on this patient, why does it cause pain?

Ans: The nerve involved is sciatic nerve. Its root value is ventral rami of L4, L5, S1, S2, S3 segments of spinal cord. The pain on the back of thigh indicates compression of the roots of sciatic and radiating pain along cutaneous branches of tibial and common peroneal nerves.

Straight leg raising test:

The patient lies supine on the bed. The affected leg is extended at both hip and knee joints. Then it is raised up from the bed by holding the foot. As the nerve is stretched, it causes severe pain.

MULTIPLE CHOICE QUESTIONS

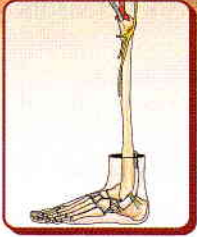
- The posterior compartment is also known as:
 - Flexor compartment
 - Extensor compartment
 - Abductor compartment
 - Adductor compartment
- Biceps femoris is inserted into:
 - Head of fibula
 - Adductor tubercle of femur
 - On styloid process of fibula
 - Medial condyle of tibia
- Compression of which nerve leads to numbness of lower limb

a. Sciatic nerve	b. Tibial nerve
c. Femoral nerve	d. Deep peroneal nerve
- Which is not a character of hamstring muscle?
 - Origin from ischial tuberosity
 - Nerve supply by deep peroneal muscle
 - The muscle act as flexor of knee and extensor of hip
 - Insertion into one of bones of leg
- Semimembranosus is supplied by:
 - Tibial part of sciatic nerve
 - Common peroneal part of sciatic nerve
 - Obturator nerve
 - Femoral nerve
- Sciatic nerve is largest branch of:

a. Sacral plexus	b. Lumbar plexus
c. Cervical plexus	d. Brachial plexus
- Tibial collateral ligament of knee is the morphological continuation of:
 - Adductor magnus muscle
 - Adductor brevis muscle
 - Adductor longus muscle
 - None of above

ANSWERS

1. a 2. a 3. a 4. b 5. a 6. a 7. a



Front, Lateral and Medial Sides of Leg and Dorsum of Foot

Human life is but a series of footnotes to a vast obscure unfinished masterpiece.
—V Nabokov

INTRODUCTION

The great saphenous vein starts on the medial side of the dorsum of the foot and runs up just anterior to the medial malleolus, where it can be “slit open” for transfusion purposes. Dorsalis pedis artery, the distal continuation of the anterior tibial artery, is used for palpation in some clinical conditions. The dorsiflexors of foot supplied by deep peroneal nerve lie in the anterior compartment of leg. Tibialis anterior is an invertor of the foot as well. The two big evertors of the foot with superficial peroneal nerve are placed in the lateral compartment of the leg. The tendons of all these muscles are retained in position by two extensor and two peroneal retinacula. The three muscles inserted on the upper medial surface of tibia stabilise the pelvis on the thigh and leg (see Fig. 4.2b).

SURFACE LANDMARKS

- 1 *Medial and lateral condyles of tibia* are felt better in a flexed knee with the thigh flexed and laterally rotated (Fig. 8.1).
- 2 *Tibial tuberosity* is a bony prominence on the front of the upper part of tibia, 2.5 cm distal to the knee joint line passing through the upper margins of the tibial condyles. The tuberosity provides attachment to ligamentum patellae above, and is continuous with the shin below.
- 3 *Head of the fibula* lies posterolaterally at the level of tibial tuberosity. It serves as a guide to common peroneal nerve which winds around the posterolateral aspect of the neck of fibula.
- 4 *Shin* is the subcutaneous anterior border of tibia. It is sinuously curved and extends from the tibial tuberosity to the anterior margin of the medial malleolus. It is better defined in the upper part than in the lower part.

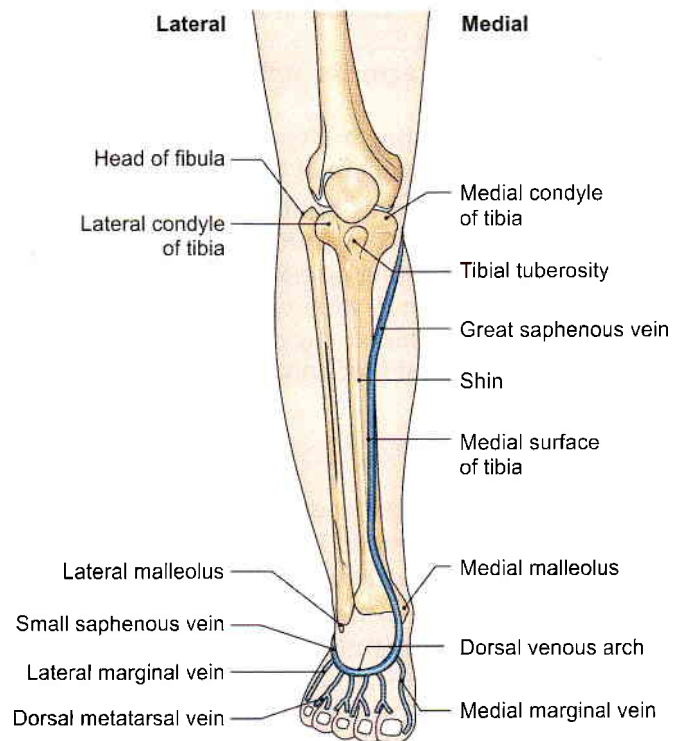


Fig. 8.1: Landmarks on leg and foot with superficial veins on the front

- 5 *Medial surface of tibia* is subcutaneous, except in the uppermost part where it is crossed by the tendons of sartorius, gracilis and semitendinosus. Great saphenous vein crosses lower one-third of the surface, running obliquely upwards and backwards from the anterior border of medial malleolus.
- 6 *Medial border of tibia* is palpable throughout its whole extent. The saphenous nerve and great saphenous vein run partly along it.
- 7 *Gastrocnemius* and the underlying *soleus* form the fleshy prominence of the *calf*. These muscles become



prominent when heel is raised as standing on toes. *Tendocalcaneus* is the strong, thick tendon of these muscles; it is attached below to the posterior surface of calcaneum.

- 8 *Medial malleolus* is the bony prominence on the medial side of ankle. It is formed by a downwards projection from the medial surface of the lower end of tibia.
- 9 *Lateral malleolus* is the bony prominence on the lateral side of ankle. It is formed by the lower end of fibula. It is larger but narrower than the medial malleolus, and its tip is 0.5 cm below that of the medial malleolus. The posterior borders of two malleoli are in the same coronal plane, but the anterior border of lateral malleolus is about 1.5 cm behind that of the medial malleolus.
- 10 *Peroneal trochlea*, when present, is felt as a little prominence about a finger-breadth below the lateral malleolus. *Peroneus brevis* passes above and the *peroneus longus* below the trochlea.
- 11 *Sustentaculum tali* can be felt about a thumb-breadth below the medial malleolus.
- 12 *Tuberosity of navicular bone* is a low bony prominence felt 2.5 to 3.75 cm anteroinferior to the medial malleolus, about midway between the back of the heel and root of the big toe.
- 13 *Head of the talus* lies above the line joining the sustentaculum tali and tuberosity of navicular bone.
- 14 *Tuberosity of the base of fifth metatarsal bone* is the most prominent landmark on the lateral border of the foot. It lies midway between the point of the heel and the root of the little toe.
- 15 *Posterior tibial artery* pulsations can be felt against calcaneum about 2 cm below and behind the medial malleolus (see Fig. 9.9).
- 16 *Dorsalis pedis artery* pulsations can be felt best on the dorsum of foot about 5 cm distal to the malleoli, lateral to the tendon of *extensor hallucis longus*, over the intermediate cuneiform bone (Fig. 8.11).
- 17 *Tendon of tibialis anterior* becomes prominent on active inversion of the foot, passing downwards and medially across the medial part of the anterior surface of ankle.
- 18 *Tendon of extensor hallucis longus* becomes prominent when the foot is dorsiflexed.
- 19 *Extensor digitorum brevis* produces an elevation on the lateral part of the dorsum of foot when the toes are dorsiflexed or extended (Fig. 8.7).
- 20 *First metatarsophalangeal joint* lies a little in front of the centre of the ball of big toe. The *other metatarsophalangeal joints* are placed about 2.5 cm behind the webs of the toes.

SUPERFICIAL FASCIA

DISSECTION

1. Make a horizontal incision across the leg at its junction with foot (see Fig. 3.1).
2. Provide a vertical incision up from the centre of incision (1) to the middle of incision drawn just below the level of tibial tuberosity.
3. Carry this vertical incision on to the dorsum of foot till the middle of the second toe.
Reflect the skin on both the sides. Look for various veins and cutaneous nerves in the leg and foot according to the description given in the text (refer to §).

CONTENTS

The superficial fascia of the front of the leg and the dorsum of the foot contains: The superficial veins, cutaneous nerves, lymphatics, and small unnamed arteries.

Superficial Veins

- 1 The *dorsal venous arch* lies on the dorsum of the foot over the proximal parts of the metatarsal bones. It receives four dorsal metatarsal veins each of which is formed by the union of two dorsal digital veins (Fig. 8.1).
- 2 The *great or long saphenous vein* is formed by the union of the medial end of the dorsal venous arch with the medial marginal vein which drains the medial side of the great toe. It passes upwards in front of the medial malleolus, crosses the lower one-third of the medial surface of tibia obliquely, and runs along its medial border to reach the back of the knee. The saphenous nerve runs in front of the great saphenous vein.
- 3 The *small or short saphenous vein* is formed by the union of the lateral end of the dorsal venous arch with the lateral marginal vein, draining the lateral side of the little toe. It passes upwards behind the lateral malleolus to reach the back of the leg. The sural nerve accompanies the small saphenous vein.
Both saphenous veins are connected to the deep veins through the perforating veins.

Cutaneous Nerves

- 1 The *infrapatellar branch of the saphenous nerve* pierces the sartorius and the deep fascia on the medial side of the knee, curves downwards and forwards, and supplies the skin over the ligamentum patellae (Fig. 8.2).
- 2 The *saphenous nerve* is a branch of the posterior division of the femoral nerve. It pierces the deep fascia on the medial side of the knee between the

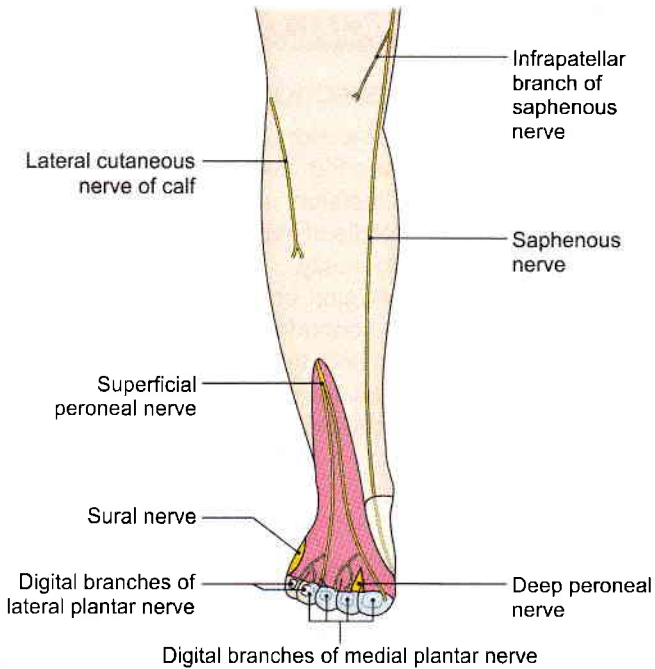


Fig. 8.2: Cutaneous nerves on the front of the leg and dorsum of foot

sartorius and the gracilis, and runs downwards in front of the great saphenous vein. It supplies the skin of the medial side of the leg and the medial border of the foot up to the ball of the great toe.

- 3 The *lateral cutaneous nerve of the calf* is a branch of the common peroneal nerve. It pierces the deep fascia over the lateral head of the gastrocnemius, and descends to supply the skin of the upper two-thirds of the lateral side of the leg (Fig. 8.2).
- 4 The *superficial peroneal nerve* is a branch of the common peroneal nerve. It arises on the lateral side of the neck of the fibula deep to the fibres of the peroneus longus. It descends between the peroneal muscles, pierces the deep fascia at the junction of the upper two-thirds and lower one-third of the lateral side of the leg, and divides into medial and lateral branches. These branches supply the following area:
 - a. The skin over the lower one-third of the lateral side of the leg (Fig. 8.2).
 - b. The skin over the entire dorsum of the foot with the exception of the following areas.
 - i. Lateral border, supplied by sural nerve.
 - ii. Medial border up to the base of the great toe, supplied by the saphenous nerve.
 - iii. Cleft between the first and second toes, supplied by the deep peroneal nerve.
- 5 The *sural nerve* is a branch of the tibial nerve. It arises in the middle of the popliteal fossa. It runs vertically downwards, pierces the deep fascia in the middle of the back of leg, accompanies the small saphenous

vein, and supplies the skin of the lower half of the back of leg and of the whole of the lateral border of the foot up to the tip of the little toe (see Fig. 9.1).

- 6 The *deep peroneal nerve* terminates by supplying the skin adjoining the cleft between the first and second toes.
- 7 The *digital branches of the medial and lateral plantar nerves* curve upwards and supply the distal parts of the dorsum of the toes. Medial plantar nerve supplies medial $3\frac{1}{2}$ toes; lateral plantar nerve supplies lateral $1\frac{1}{2}$ toes.

CLINICAL ANATOMY

Saphenous nerve may be subjected to entrapment neuropathy as it leaves the adductor canal, leading to pain in the area of its supply.

DEEP FASCIA

DISSECTION

Underlying the superficial fascia is the dense deep fascia of leg. Divide this fascia longitudinally as it stretches between tibia and fibula.

Expose the superior extensor retinaculum 5 cm above the ankle joint and the inferior extensor retinaculum in front of the ankle joint.

Features

The following points about the fascia are noteworthy.

- 1 In the leg, tibia and fibula are partly subcutaneous, the most notable being the medial surface of the tibia, and the malleoli. Over these subcutaneous areas, the deep fascia is replaced by periosteum.
- 2 Extensions of deep fascia form intermuscular septa that divide the leg into compartments (Fig. 8.3).

The *anterior* and *posterior* intermuscular septa are attached to the anterior and posterior borders of the fibula. They divide the leg into three compartments: *anterior*, *lateral*, and *posterior*. The posterior compartment is subdivided into superficial, intermediate and deep parts by *superficial* and *deep transverse fascial septa*.

- 3 Around the ankle, the deep fascia is thickened to form bands called *retinacula*. These are so called because they retain tendons in place. On the front of the ankle there are the *superior and inferior extensor retinacula*. Laterally, there are the *superior and inferior peroneal retinacula*. Posteromedially, there is the *flexor retinaculum*. The extensor retinacula are described below. The peroneal retinacula are considered with the lateral compartment of the leg and the flexor retinaculum with the posterior compartment.

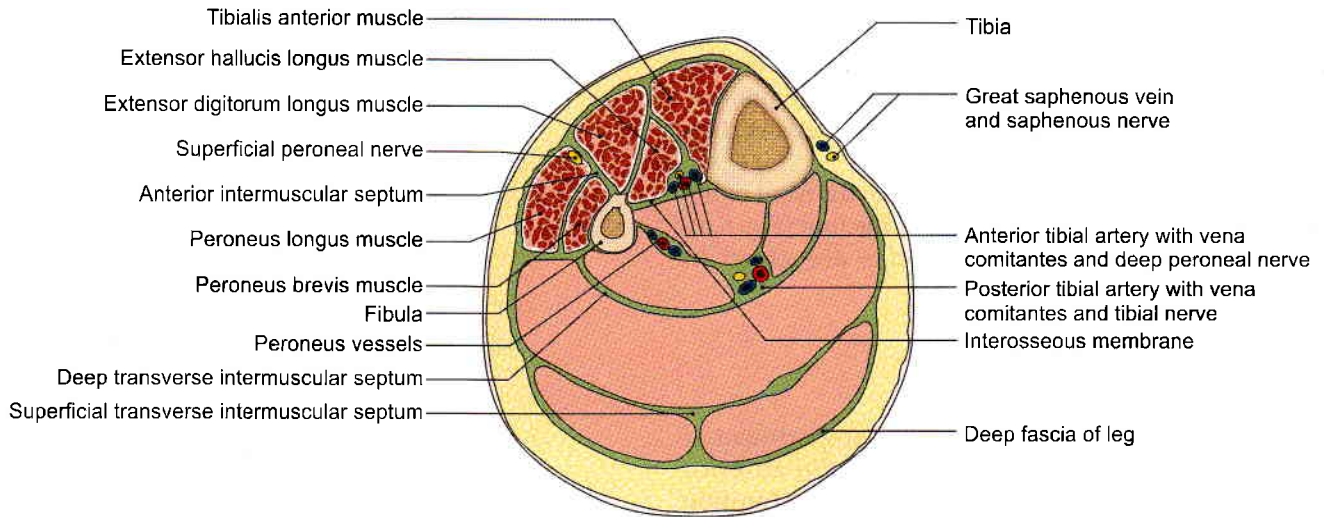


Fig. 8.3: Transverse section through the middle of the leg showing the intermuscular septa and the arrangement of structures in the anterior and lateral compartments

Superior Extensor Retinaculum

Attachments

Medially, it is attached to the lower part of the anterior border of the tibia, and *laterally* to the lower part of the anterior border of the fibula forming the anterior boundary of the elongated triangular area just above the lateral malleolus (Fig. 8.4).

Inferior Extensor Retinaculum

This is a Y-shaped band of deep fascia, situated in front of the ankle joint and over the posterior part of the dorsum of the foot. The stem of the Y lies laterally, and the upper and lower bands, medially (Fig. 8.4).

Attachments

- 1 The *stem* is attached to the anterior non-articular part of the superior surface of the calcaneum, in front of the sulcus calcanei.

- 2 The *upper band* passes upwards and medially, and is attached to the anterior border of the medial malleolus.
- 3 The *lower band* passes downwards and medially and is attached to the plantar aponeurosis.

Structures Passing under

- 1 Tibialis anterior.
- 2 Extensor hallucis longus.
- 3 Anterior tibial vessels.
- 4 Deep peroneal nerve
- 5 Extensor digitorum longus.
- 6 The peroneus tertius.

CLINICAL ANATOMY

Anterior tibial compartment syndrome/fresher's syndrome: The muscles of anterior compartment of leg get pain because of too much sudden exercise. The muscles are tender to touch.

MUSCLES OF FRONT OF LEG

DISSECTION

Identify the muscles of anterior compartment of leg as these are lying close together on the lateral surface of tibia, adjoining interosseous membrane and medial surface of fibula.

Trace their tendons deep to the two retinacula on the dorsum of foot till their insertion. Learn about these muscles given in Tables 8.1 and 8.2.

Look for anterior tibial artery and accompanying deep peroneal nerve as these lie on the upper part of interosseous membrane of leg. Study their course, relations and branches.

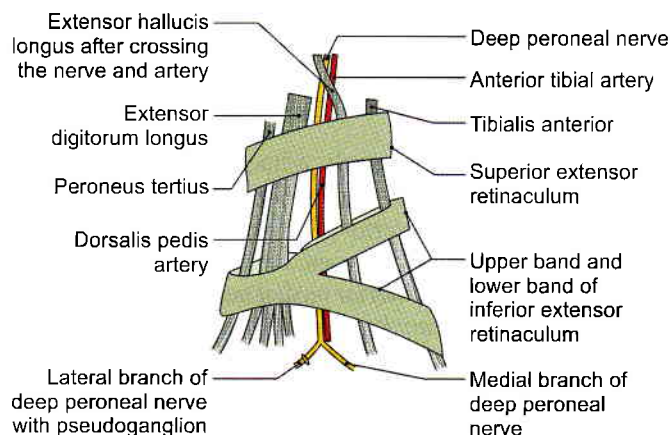


Fig. 8.4: Tendons, vessels and nerves related to the extensor retinacula



MUSCLES OF ANTERIOR COMPARTMENT OF THE LEG

The muscles of the anterior compartment of the leg are the *tibialis anterior*, the *extensor hallucis longus*, the *extensor digitorum longus* and the *peroneus tertius* (Fig. 8.5).

These muscles are tested *by palpation* on the front of leg and requesting the patient to dorsiflex the foot (Fig. 8.6).

The attachments of these muscles are given in Tables 8.1 and 8.2.

ANTERIOR TIBIAL ARTERY

Introduction

This is the main artery of the anterior compartment of the leg (Fig. 8.8). The blood supply to the anterior compartment of the leg is reinforced by the perforating branch of the peroneal artery, the size of which is inversely proportional to that of the anterior tibial artery.

Beginning, Course and Termination

The anterior tibial artery is the smaller terminal branch of the popliteal artery.

It begins on the back of the leg at the lower border of the popliteus, opposite the tibial tuberosity.

It enters the anterior compartment of the leg by passing forwards close to the fibula, through an opening in the upper part of the interosseous membrane.

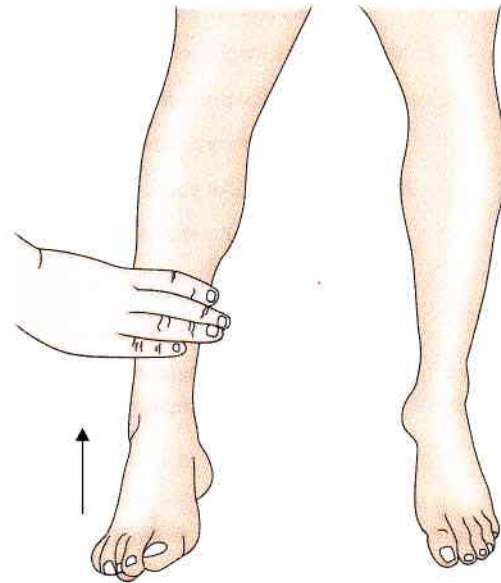


Fig. 8.6: How to test the dorsiflexors of the ankle joint

In the anterior compartment, it runs vertically downwards to a point midway between the two malleoli where it changes its name to become the *dorsalis pedis* artery.

Relations

In the upper one-third of the leg, the artery lies between the *tibialis anterior* and the *extensor digitorum longus* (Fig. 8.5).

In the middle one-third it lies between the *tibialis anterior* and the *extensor hallucis longus* (Fig. 8.3).

In the lower one-third it lies between the *extensor hallucis longus* and the *extensor digitorum longus*. In understanding these relations note that the artery is crossed from lateral to medial side by the tendon of the *extensor hallucis longus* (Fig. 8.4).

The artery is accompanied by the *venae comitantes*.

The deep peroneal nerve is lateral to it in its upper and lower thirds, and anterior to it in its middle one-third (Fig. 8.4).

Branches

- 1 *Muscular* branches supply adjacent muscles.
- 2 *Anastomotic* branches are given to the knee and ankle. The *anterior* and *posterior tibial recurrent branches* take part in the anastomoses round the knee joint (see Fig. 6.10). The *anterior medial malleolar* and *anterior lateral malleolar branches* take part in the anastomoses round the ankle joint or malleolar networks (Fig. 8.8). The *lateral malleolar network* lies just below the lateral malleolus. The *medial malleolar network* lies just below the medial malleolus.

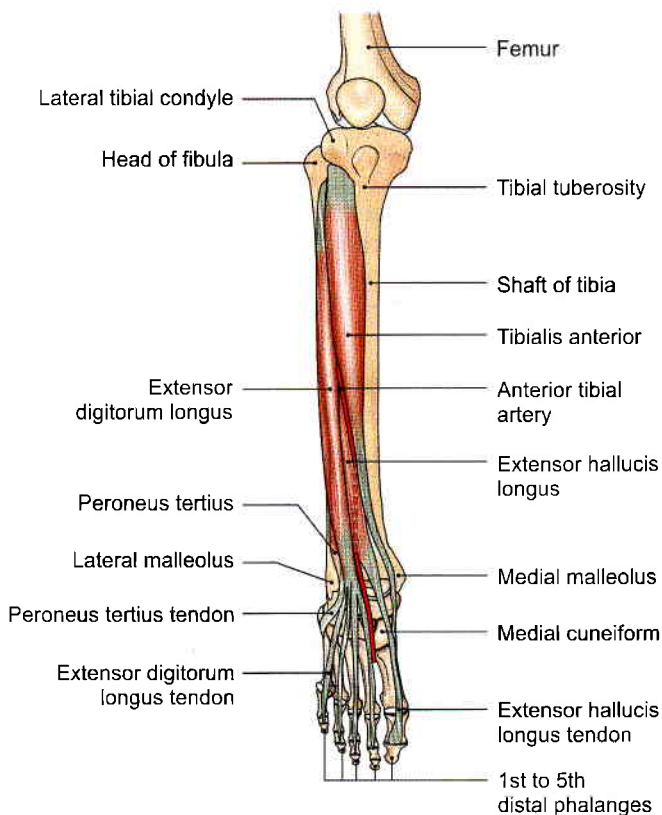


Fig. 8.5: Muscle of front of leg



Table 8.1: Muscles of the anterior compartment of the leg and dorsum of foot

<i>Muscle</i>	<i>Origin from</i>	<i>Insertion into</i>
1. Tibialis anterior It has a spindle-shaped belly with multipennate fibres (see Fig. 2.27)	a. Lateral condyle of tibia b. Upper two-thirds of the lateral surface of the shaft of the tibia c. Adjoining part of interosseous membrane	Inferomedial surface of the medial cuneiform and the adjoining part of the base first metatarsal bone
2. Extensor hallucis longus (see Figs 2.35 and 8.5)	a. Posterior half of the middle 2/4th of the medial surface of the shaft of the fibula, medial to the extensor digitorum longus b. Adjoining part of the interosseous membrane	Dorsal surface of the base of the distal phalanx of the big toe
3. Extensor digitorum longus (see Figs 2.35 and 8.5)	a. Lateral condyle of tibia b. Whole of upper one-fourth and anterior half of middle 2/4th of the medial surface of the shaft of the fibula c. Upper part of interosseous membrane	It divides into four tendons for the lateral four toes. The tendons of 2nd, 3rd and 4th digits are joined on the lateral side by tendon of the extensor digitorum brevis, and forms the dorsal digital expansion. It is inserted on the bases of the middle and distal phalanges (Fig. 8.7)
4. Peroneus tertius It is a separated part of the extensor digitorum longus, and may be regarded as its fifth tendon. It may be absent	a. Lower one-fourth of the medial surface of the shaft of the fibula b. Adjoining part of the interosseous membrane	Medial part of the dorsal surface of the base of the fifth metatarsal bone
5. Extensor digitorum brevis This is a small muscle situated on the lateral part of the dorsum of foot, deep to the tendons of the extensor digitorum longus (Fig. 8.7)	The muscle arises from anterior part of the superior surface of the calcaneum	The muscle divides into four tendons for the medial four toes. The medial most part of the muscle, which is distinct, is known as the extensor hallucis brevis. The extensor hallucis brevis is inserted into the dorsal surface of the base of the proximal phalanx of the great toe. The lateral three tendons join the lateral sides of the tendons of the extensor digitorum longus to form the dorsal digital expansion for the second, third and fourth toes

Note: The above muscles also take origin from the deep surface of the deep fascia, and from adjoining intermuscular septa.

Table 8.2: Nerve supply and actions of muscles

<i>Muscle</i>	<i>Nerve supply</i>	<i>Action</i>
1. Tibialis anterior	Deep peroneal nerve	a. Dorsiflexor of foot b. Invertor of the foot c. Keeps the leg vertical while walking on uneven ground d. Maintains medial longitudinal arch of the foot
2. Extensor hallucis longus	Deep peroneal nerve	Dorsiflexor of foot and extends metatarsophalangeal and interphalangeal joints of big toe
3. Extensor digitorum longus	Deep peroneal nerve	Dorsiflexor of foot. Extends metatarsophalangeal, proximal and distal interphalangeal joints of 2nd–5th toes
4. Peroneus tertius	Deep peroneal nerve	Dorsiflexor of foot and evertor of foot
5. Extensor digitorum brevis	Lateral terminal branch of the deep peroneal nerve	Medial tendon known as extensor hallucis brevis, extends metatarsophalangeal joint of big toe. The other three lateral tendons extend the metatarsophalangeal and interphalangeal joints of 2nd, 3rd and 4th toes particularly in a dorsiflexed foot

DEEP PERONEAL NERVE

Deep peroneal nerve is the nerve of the anterior compartment of the leg and the dorsum of the foot. This

is one of the two terminal branches of common peroneal nerve. It corresponds to the posterior interosseous nerve of the forearm.

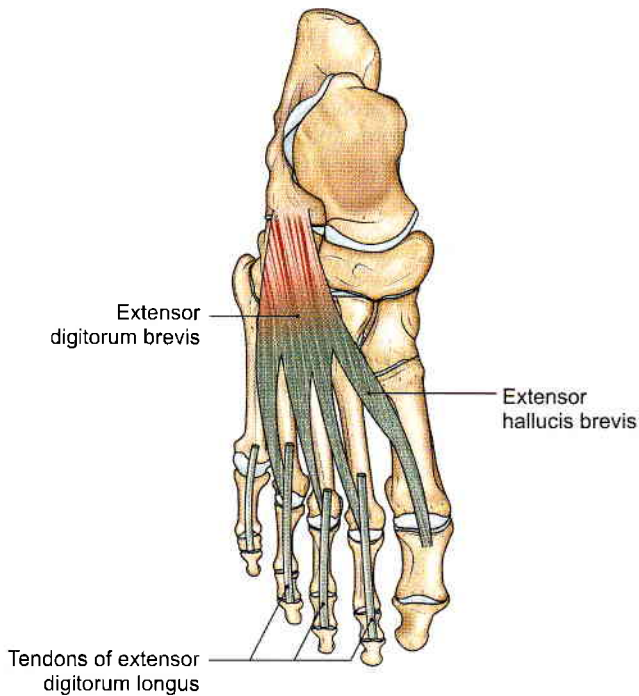


Fig. 8.7: Joint tendons of extensor digitorum brevis and extensor digitorum longus in 2nd, 3rd and 4th toes

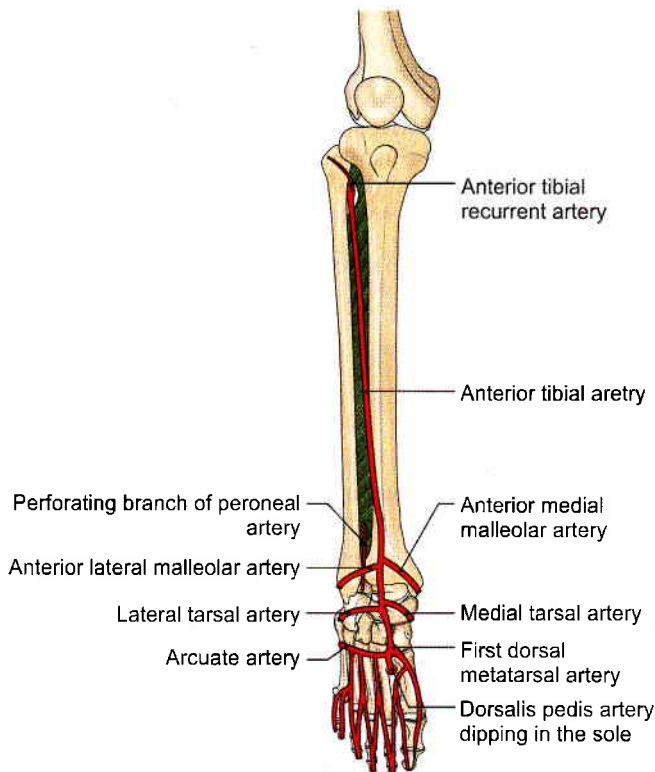


Fig. 8.8: Arteries on the front of the leg and dorsum of the foot

Beginning, Course and Termination

Deep peroneal nerve is one of the terminal branches of common peroneal nerve. It begins on the lateral side of the neck of the fibula (Fig. 8.9).

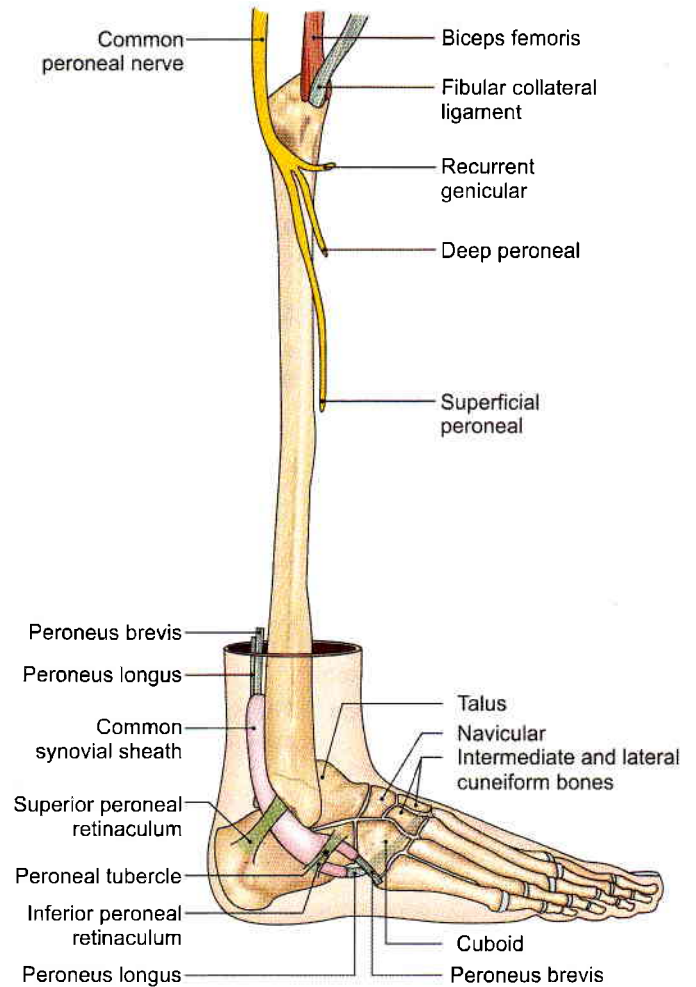


Fig. 8.9: Common peroneal nerve and its terminal branches the peroneal retinacula also seen

It enters the anterior compartment by piercing the anterior intermuscular septum. It then pierces the *extensor digitorum longus* and comes to lie next to the anterior tibial artery (Fig. 8.3).

In the leg, it accompanies the anterior tibial artery and has similar relations.

The nerve ends on the dorsum of the foot, close to the ankle joint, by dividing into the lateral and medial terminal branches (Fig. 8.4).

The lateral terminal branch turns laterally and ends in a *pseudoganglion* deep to the *extensor digitorum brevis*. Branches proceed from the pseudoganglion and supply the *extensor digitorum brevis* and the tarsal joints.

The medial terminal branch ends by supplying the skin adjoining the first interdigital cleft and the proximal joints of the big toe (Fig. 8.2).

Branches

Muscular branches supply:

- 1 Four muscles of the anterior compartment of the leg (Figs 8.3 and 8.5).
- 2 The *extensor digitorum brevis* on the dorsum of the foot.



A *cutaneous branch* supplies adjacent sides of the first and second toes (Fig. 8.2).

Articular branches supply the ankle joint, the tarsal joints, the tarsometatarsal and metatarsophalangeal joints of the big toe.

CLINICAL ANATOMY

Paralysis of the muscles of the anterior compartment of the leg due to injury to deep peroneal nerve results in loss of the power of dorsiflexion of the foot. As a result the foot is plantar flexed. The condition is called *foot drop*. This is usually caused by injury or disease of the common peroneal nerve due to trauma, leprosy or peripheral neuritis (Fig. 8.10). Sensory loss is confined to first interdigital cleft.

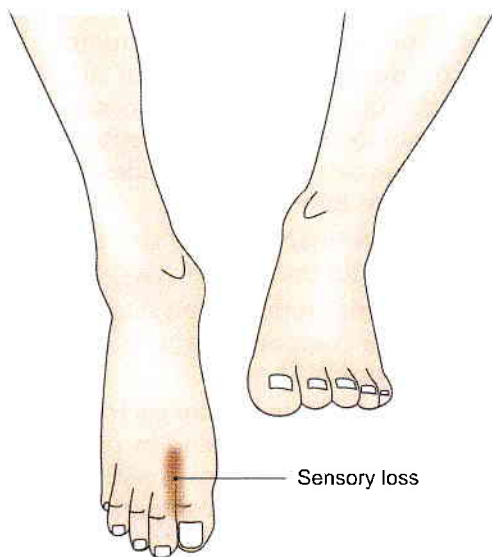


Fig. 8.10: Foot drop on the right side. Sensory loss in the first interdigital cleft

DORSUM OF FOOT

DISSECTION

Identify the small muscle extensor digitorum brevis situated on the lateral side of dorsum of foot. Its tendons are deep to the tendons of extensor digitorum longus. Its most medial tendon is called extensor hallucis brevis (Fig. 8.7). Dissect the dorsalis pedis artery and its branches on the dorsum of the foot.

DORSALIS PEDIS ARTERY (DORSAL ARTERY OF THE FOOT)

This is the chief palpable artery of the dorsum of the foot (Fig. 8.8). It is commonly palpated in patients with

vaso-occlusive diseases of the lower limb. It is a continuation of the anterior tibial artery on to the dorsum of the foot (Figs 8.4 and 8.11).

Beginning, Course and Termination

The artery begins in front of the ankle between the two malleoli. It passes forwards along the medial side of the dorsum of the foot to reach the proximal end of the first intermetatarsal space. Here it dips downwards between the two heads of the first dorsal interosseous muscle, and ends in the sole by completing the plantar arterial arch (Fig. 8.8).

Relations

Superficial

- 1 Skin, fasciae, and inferior extensor retinaculum (Fig. 8.4).
- 2 Extensor hallucis brevis, which crosses the artery from the lateral to medial side.

Deep

- 1 Capsular ligament of the ankle joint.
- 2 The talus, navicular and intermediate cuneiform bones and the ligaments connecting them.

Medial

Extensor hallucis longus.

Lateral

- 1 First tendon of the extensor digitorum longus.
- 2 The medial terminal branch of the deep peroneal nerve.

Branches

- 1 The *lateral tarsal artery* is larger than the medial and arises over the navicular bone. It passes deep to the extensor digitorum brevis, supplies this muscle and neighbouring tarsal joints, and ends in the lateral malleolar network.
- 2 The *medial tarsal branches* are two to three small twigs which join the medial malleolar network.
- 3 The *arcuate artery* is a large branch that arises opposite the medial cuneiform bone. It runs laterally over the bases of the metatarsal bones, deep to the tendons of the extensor digitorum longus and the extensor digitorum brevis, and ends by anastomosing with the lateral tarsal and lateral plantar arteries. It gives off the *second, third and fourth dorsal metatarsal arteries* (Fig. 8.8) each of which divides into dorsal digital branches for adjoining toes. The dorsal metatarsal arteries are joined by proximal and distal perforating arteries from the sole.



- 4 The *first dorsal metatarsal artery* arises just before the *dorsalis pedis artery* dips into the sole. It gives a branch to the medial side of the big toe, and divides into dorsal digital branches for adjacent sides of the first and second toes.

CLINICAL ANATOMY

Pulsations of the *dorsalis pedis artery* are easily felt between the tendons of the *extensor hallucis longus* and the first tendon of the *extensor digitorum longus*. It must be remembered, however, that the *dorsalis pedis artery* is congenitally absent in about 14% of subjects (Fig. 8.11).

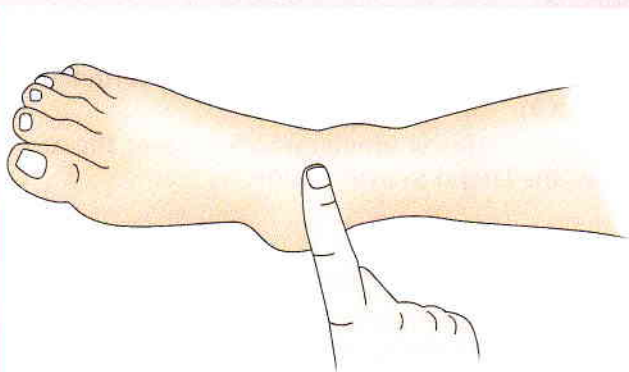



Fig. 8.11: The *dorsalis pedis artery* being palpated

FASCIA AND MUSCLES OF LATERAL SIDE OF THE LEG

DISSECTION

Reflect the lateral skin flap of leg further laterally till peroneal muscles are seen. Divide the deep fascia longitudinally over the peroneal muscles. Clean the superior and inferior peroneal retinacula situated just above and below the lateral malleolus.

Identify the *peroneus longus* and *peroneus brevis* muscles. Trace their tendons through the retinacula towards their insertion. Study the deep fascia and peroneal muscles (*refer to* ).

BOUNDARIES

The lateral or peroneal compartment of the leg is bounded *anteriorly* by the anterior intermuscular septum, *posteriorly* by the posterior intermuscular septum, *medially* by the lateral surface of the fibula, and *laterally* by the deep fascia (Fig. 8.3).

CONTENTS

Muscles: *Peroneus longus* and *peroneus brevis*.

Nerve: Superficial peroneal nerve.

Vessels: The arterial supply is derived from the branches of the *peroneal artery* which reach the lateral compartment by piercing the *flexor hallucis longus* and the posterior intermuscular septum. The veins drain into the small saphenous vein.

PERONEAL RETINACULA

The *superior peroneal retinaculum* is a thickened band of deep fascia situated just behind the lateral malleolus. It holds the peroneal tendons in place against the back of the lateral malleolus. It is attached anteriorly to the posterior margin of the lateral malleolus, and posteriorly to the lateral surface of the calcaneum and to the superficial transverse fascial septum of the leg (Fig. 8.9).

The *inferior peroneal retinaculum* is a thickened band of deep fascia situated anteroinferior to the lateral malleolus. Superiorly, it is attached to the anterior part of the superior surface of the calcaneum, where it becomes continuous with the stem of the inferior extensor retinaculum. Inferiorly, it is attached to the lateral surface of the calcaneum. A septum attached to the peroneal tubercle or trochlea divides the space deep to the retinaculum into two parts.

The peroneal retinacula hold the tendons of the *peroneus longus* and *brevis* in place.

Under the superior retinaculum the two tendons are lodged in a single compartment, and are surrounded by a common synovial sheath.

Under the inferior retinaculum each tendon lies in a separate compartment. The tendon of the *peroneus brevis* lies in the superior compartment and that of the *peroneus longus* in the inferior compartment. Here each tendon is enclosed in a separate extension of the synovial sheath (Fig. 8.9).

CLINICAL ANATOMY

Tenosynovitis of peronei tendon is the inflammation of the tendon sheaths of the peroneal muscles. If superior peroneal retinaculum is torn, the tendons can get dislocated to front of lateral malleolus.

PERONEAL MUSCLES

These are the *peroneus longus* and the *peroneus brevis* (Fig. 8.12). Their attachments are given in Tables 8.3 and 8.4.

CLINICAL ANATOMY

Paralysis of *peroneus brevis* and *peroneus longus* occurs due to injury to superficial peroneal nerve. The foot cannot be everted at subtalar joint.

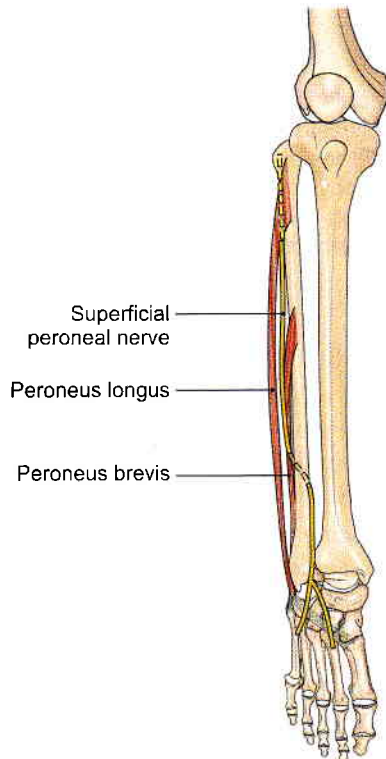


Fig. 8.12: Peronei muscles

SUPERFICIAL PERONEAL NERVE

DISSECTION

Carefully look for common peroneal nerve in relation to the neck of fibula.

Superficial peroneal nerve, one of the terminal branches of common peroneal nerve supplies both the peroneus longus and brevis muscles and in lower one-third of leg becomes cutaneous to supply most of the dorsum of foot.

Introduction

Superficial peroneal nerve (Fig. 8.9) is the main nerve of the lateral compartment of the leg.

Origin

It is a smaller terminal branch of the common peroneal nerve.

Course

The nerve begins on the lateral side of neck of fibula, runs through the peroneal muscles and becomes superficial at the junction of upper two-thirds and lower one-third of leg.

Relations

It begins on the lateral side of the neck of the fibula, under cover of the upper fibres of the *peroneus longus*.

In the upper one-third of the leg, it descends through the substance of the *peroneus longus*. In the middle one-third, it first descends for a short distance between the peroneus longus and *brevis* muscles, reaches the anterior border of the *peroneus brevis*, and then descends in a groove between the *peroneus brevis* and the *extensor digitorum longus* under cover of deep fascia.

At the junction of the upper two-thirds and lower one-third of the leg, it pierces the deep fascia to become superficial. It divides into a medial and a lateral branch which descend into the foot (Fig. 8.2).

BRANCHES AND DISTRIBUTION

Muscular branches: Peroneus longus and the peroneus brevis.

Cutaneous branches: Through its terminal branches, the superficial peroneal nerve supplies the lower one-third of the lateral side of the leg and the greater part of the dorsum of the foot, except for the territories

Table 8.3: The peroneal muscles

Muscle	Origin from	Insertion
1. Peroneus longus It lies superficial to the peroneus brevis (Fig. 8.12)	a. Head of the fibula, b. Upper one-third, and posterior half of the middle one-third of the lateral surface of the shaft of the fibula	The tendon passes deep to the peroneal retinacula, runs through a tunnel in the cuboid, and is inserted into (a) the lateral side of the base of the first metatarsal bone and (b) the adjoining part of the medial cuneiform bone. The tendon changes its direction below the lateral malleolus and again on the cuboid bone. A sesamoid is present in the tendon in the latter situation
2. Peroneus brevis Lies deep to the peroneus longus (Fig. 8.9)	a. Anterior half of the middle one-third and whole of the lower one-third of the lateral surface of the shaft of fibula b. Anterior and posterior inter-muscular septa of the leg	The tendon passes deep to the peroneal retinacula, and is inserted into the lateral side of the base of the fifth metatarsal bone (see Fig. 2.44)



Table 8.4: Nerve supply and actions of the peroneal muscles

Muscle	Nerve supply	Actions
1. Peroneus longus	Superficial peroneal nerve	a. Evertor of foot especially when foot is off the ground b. Maintain lateral longitudinal arch and transverse arch of the foot Peroneus longus and tibialis anterior are inserted into the same two bones, the two together form a 'stirrup' beneath the middle of the sole. The presence of the sling keeps the middle of foot pulled up and prevents flattening of its arches.
2. Peroneus brevis	Superficial peroneal nerve	Evertor of foot

supplied by the saphenous, sural, deep peroneal nerves and plantar nerves (Fig. 8.2).

The *medial branch* crosses the ankle and divides into two dorsal digital nerves—one for the medial side of the big toe, and the other for the adjoining sides of the second and third toes.

The *lateral branch* also divides into two dorsal digital nerves for the adjoining sides of the third and fourth, and fourth and fifth toes.

Communicating branches. The medial branch communicates with the saphenous and deep peroneal nerves and the lateral branch with the sural nerve.

CLINICAL ANATOMY

Superficial peroneal nerve supplies both peronei and then divides into medial and lateral cutaneous branches for supplying dorsum of foot. Superficial peroneal nerve can get entrapped as it penetrates the deep fascia of leg. It may also be involved in lateral compartment syndrome. Its paralysis causes loss of eversion of foot at subtalar joint.

TENDONS ON MEDIAL SIDE OF THE LEG

DISSECTION

Identify the three tendons of a tripod formed by sartorius, gracilis and semitendinosus to their insertion on the upper medial surface of tibia.

Behind these tendons is present the tibial collateral ligament of knee joint.

The great saphenous vein is visualised on the lower one-third of tibia. Study these structures.

Features

Medial side of the leg is formed by the medial surface of the shaft of tibia. The greater part of this surface is subcutaneous and is covered only by the skin and superficial fascia. In the upper part, however, the surface provides attachment to tibial collateral ligament near the medial border, and provides insertion to *sartorius*, *gracilis* and *semitendinosus* in front of the

ligament, all of which are covered by a thin layer of deep fascia. The *great saphenous vein* and the *saphenous nerve* lie in the superficial fascia as they cross the lower one-third of this surface.

- The skin, fasciae and periosteum on this surface are supplied by saphenous nerve.
- The *tibial collateral ligament*, morphologically, represents degenerated part of the tendon of *adductor magnus*. Partly it covers the insertion of *semimembranosus*, and is itself crossed superficially by the tendons of *sartorius*, *gracilis*, *semitendinosus* and with *anserine bursa* around them.
- Guy ropes*: The three muscles inserted into the upper part of the medial surface of tibia represent one muscle from each of the three compartments of thigh, corresponding to the three elements of the hip bone. *Sartorius* belongs to anterior compartment of thigh, and is supplied by the nerve of ilium or femoral nerve.

Gracilis belongs to medial compartment of thigh, and is supplied by the nerve of pubis or obturator nerve.

Semitendinosus belongs to posterior compartment of thigh, and is supplied by the nerve of ischium or sciatic nerve.

These three muscles are anchored below at one point, and spread out above to span the pelvis, like three strings of a tent. From this arrangement it appears that they act as "guy ropes", to stabilize the bony pelvis on the femur (Fig. 8.13).

- Anserine bursa*: This is a large, complicated bursa, with several diverticula. It separates the tendons of *sartorius*, *gracilis* and *semitendinosus* at their insertion from one another, from the bony surface of tibia, and from the tibial collateral ligament (Fig. 8.14).
- The *great saphenous vein* ascends in front of the medial malleolus, and crosses lower one-third of the medial surface of tibia obliquely, with a backward inclination. The saphenous nerve runs downwards just in front of the great saphenous vein. The vein is accompanied by lymphatics from the foot, which



drain into the vertical group of superficial inguinal lymph nodes.

CLINICAL ANATOMY

Bursa anserine between insertion of sartorius, gracilis, semitendinosus and tibial collateral ligament may get inflamed. It is called anserina bursitis.

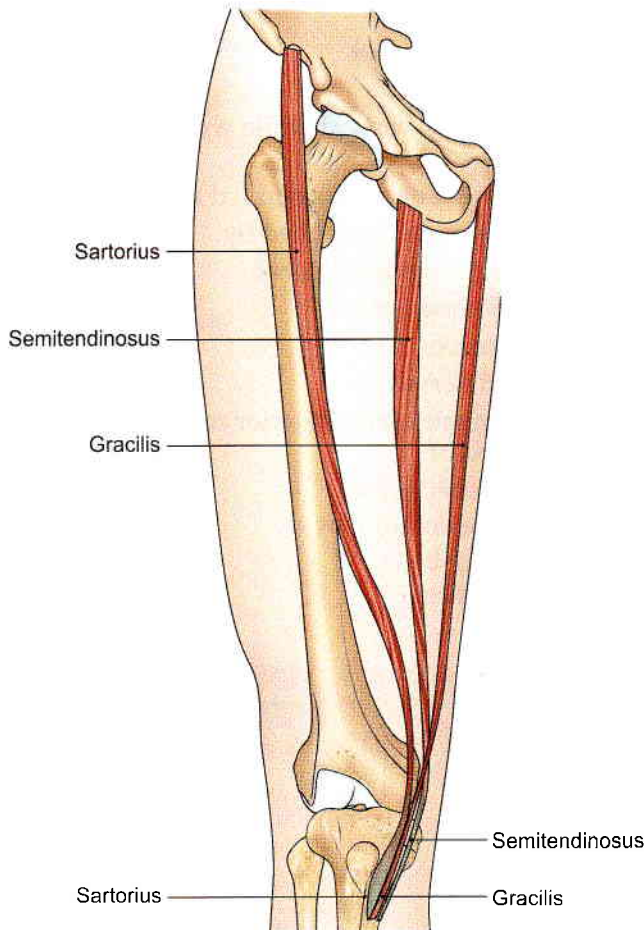


Fig. 8.13: Sartorius, gracilis and semitendinosus form the guy ropes for the tent of pelvis

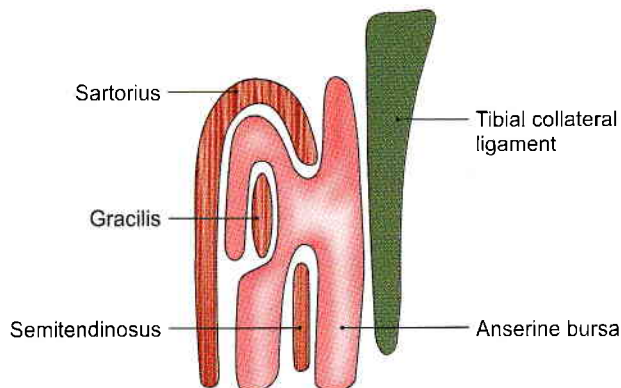


Fig. 8.14: The anserine bursa

Mnemonics

Structures under are extensor retinaculum of ankle

Tall **H**imalayas are never **d**ry places
Tibialis anterior
Extensor **h**allucis longus
Anterior tibial **a**rtery
Deep peroneal **n**erve
Extensor **d**igitorum longus
Peroneus tertius



FACTS TO REMEMBER

- Superior and inferior extensor retinacula and superior and inferior peroneal retinacula retain the tendons in place during movements of various joints.
- Dorsum of foot contains a extensor digitorum brevis, while dorsum of hand has no muscle of its own.
- Long and short saphenous veins start on the dorsum of foot. Long saphenous vein lying anterior to medial malleolus is used for giving intravenous fluids/blood in case of emergency.
- Medial surface of tibia is bare. It is crossed by long saphenous vein and saphenous nerve in the lower one-third of leg.
- Guy ropes, formed by sartorius, gracilis and semitendinosus stabilise the pelvis on the thigh and leg
- Dorsalis pedis is palpated on the dorsum of foot on medial cuneiform between extensor hallucis longus and extensor digitorum longus.

CLINICOANATOMICAL PROBLEM

New medical students were asked by their seniors to run for 3 kilometers everyday. Few of them developed severe pain above their ankles after 4 days and could not continue.

- What is such a syndrome called?
- What tendons are affected in this syndrome?

Ans: When young persons do strenuous work, e.g. running everyday for three kilometers, their extensor tendons in front of the ankle joint got stretched and tired, giving rise to pain above the ankle. In addition there would be inflammation of the tendon sheaths as well, aggravating the pain.

The tendons are from medial to lateral side are

- Tibialis anterior
- Extensor hallucis longus
- Extensor digitorum longus
- Peroneus tertius




MULTIPLE CHOICE QUESTIONS

1. Name the muscle present on the dorsum of foot:
 - a. Soleus
 - b. Extensor digitorum brevis
 - c. Peroneus brevis
 - d. Peroneus tertius
2. Saphenous nerve is a branch of:
 - a. Posterior division of femoral nerve
 - b. Common peroneal nerve
 - c. Tibial nerve
 - d. Deep peroneal nerve
3. Medial plantar nerve supplies:
 - a. Medial 3½ toes
 - b. Medial 2½ toes
 - c. Medial 4 toes
 - d. Medial 3 toes
4. The structure passing under cover of superior extensor retinaculum is:
 - a. Tibialis anterior
 - b. Extensor hallucis longus
 - c. Deep peroneal nerve
 - d. All of above
5. Which is main artery of anterior compartment of leg?
 - a. Anterior tibial artery
 - b. Dorsalis pedis artery
 - c. Peroneal artery
 - d. Popliteal artery
6. Which of the following is not an action of tibialis anterior?
 - a. Dorsiflexor of foot
 - b. Invertor of foot
 - c. Keep the leg vertical while walking on uneven ground
 - d. Maintains lateral longitudinal arch of foot
7. Peroneus longus is supplied by:
 - a. Superficial peroneal nerve
 - b. Deep peroneal nerve
 - c. Tibial nerve
 - d. Femoral nerve
8. Paralysis of muscles of anterior compartment of leg leads to loss of:
 - a. Dorsiflexion of foot
 - b. Plantarflexion of foot
 - c. Both a and b
 - d. None of these

ANSWERS

1. b 2. a 3. a 4. d 5. a 6. d 7. a 8. a



Back of Leg

Thank heaven, the sun has gone in and I don't have to go out and enjoy

—L P Smith

INTRODUCTION

The back or posterior compartment of the leg is also called the calf, corresponds to the front of forearm. This is the bulkiest of the three compartments of leg, because of the powerful antigravity superficial muscles, e.g. gastrocnemius, and soleus, and are quite large in size. They raise the heel during walking. These muscles are inserted into the heel. The deeper muscles cross the ankle medially to enter the sole.

Corresponding to the two bones of the leg, there are two arteries, the posterior tibial and peroneal, but there is only one nerve, the tibial, which represents both the median and ulnar nerves of the forearm.

SUPERFICIAL FASCIA

DISSECTION

The horizontal incision (vi) in the skin is already given (see Fig. 5.2). Carry this incision along the lateral and medial borders of the leg. Reflect whole skin of the back of leg distally till the heel (ix).

Identify the structures, e.g. great and small saphenous veins, medial and lateral calcanean arteries, and nerves in the superficial fascia.

Contents

The superficial fascia of the back of the leg contains: The small and great saphenous veins and their tributaries, several cutaneous nerves, and the medial and lateral calcanean arteries.

Small or Short Saphenous Vein

The vein is formed on the dorsum of the foot by the union of the lateral end of the dorsal venous arch with the lateral marginal vein (see Fig. 8.1). It enters the back of the leg by passing behind the lateral malleolus. In

the leg, it ascends lateral to the tendocalcaneus, and then along the middle line of the calf, to the lower part of the popliteal fossa. Here it pierces the deep fascia and opens into the popliteal vein. It drains the lateral border of the foot, the heel, and the back of the leg. It is connected with the great saphenous and with the deep veins, and is accompanied by the sural nerve.

Great or Long Saphenous Vein

This vein begins on the dorsum of the foot by union of the medial end of the dorsal venous arch with the medial marginal vein (see Fig. 8.1). It ascends in front of the medial malleolus. In the lower one-third of the leg, it passes obliquely across the medial surface of the tibia. In the upper two-thirds of the leg, the vein ascends along the medial border of the tibia, to the postero-medial side of the knee. It is accompanied by the saphenous nerve. In the thigh it inclines forwards to reach saphenous opening and drains into femoral vein.

Cutaneous Nerves

The skin of the calf can be divided into three vertical areas, medial, central and lateral (Fig. 9.1). Roughly there are two nerves for each area, with an additional nerve for the heel. The medial area is supplied by the saphenous nerve and by the posterior branch of the medial cutaneous nerve of the thigh; the central area by the posterior cutaneous nerve of the thigh and by the sural nerve; the lateral area by the lateral cutaneous nerve of the calf and the peroneal communicating nerve. The lower part of the lateral area is supplied by the sural nerve. The heel is supplied by the medial calcanean branches of the tibial nerve.

- 1 The *saphenous nerve* (L3, L4) is a branch of the posterior division of the femoral nerve (see Fig. 8.2). It arises in the femoral triangle. It pierces the deep fascia on the medial side of the knee between the

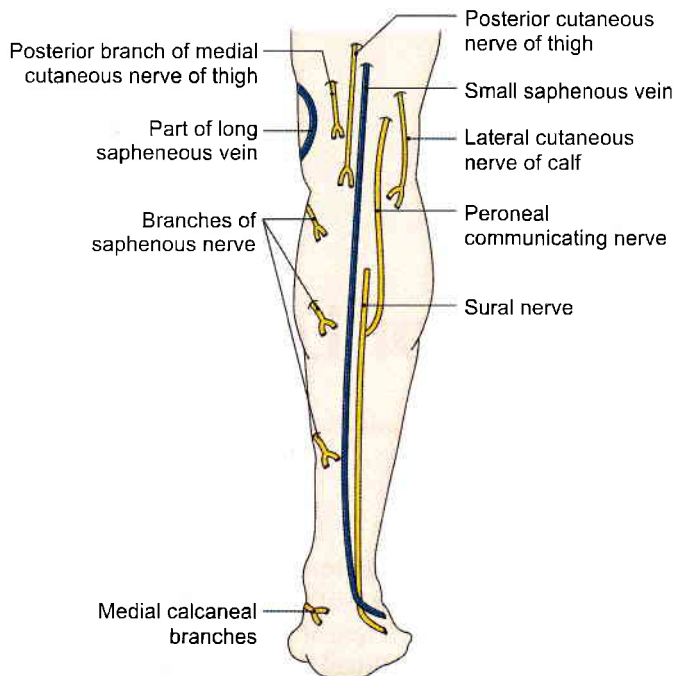


Fig. 9.1: Superficial veins and cutaneous nerves of the back of the leg and the heel

sartorius and the gracilis, and descends close to the great saphenous vein. It supplies the skin of most of the medial area of the leg, and the medial border of the foot up to the ball of the big toe. During venesection this nerve should not be injured.

- 2 The *posterior division of the medial cutaneous nerve of the thigh* (L2, L3) supplies the skin of the upper most part of the medial area of the calf.
- 3 The *posterior cutaneous nerve of the thigh* (S1, S2, S3) is a branch of the sacral plexus and descends along with the small saphenous vein, to supply the skin of the upper half of the central area of the calf.
- 4 The *sural nerve* (L5, S1, S2) is a branch of the tibial nerve in the popliteal fossa. It descends between the two heads of the gastrocnemius. It accompanies the small saphenous vein. It is joined by the peroneal communicating nerve about 5 cm above the heel. After passing behind the lateral malleolus, the nerve runs forwards along the lateral border of the foot, and ends at the lateral side of the little toe. It supplies the skin shown in (Fig. 9.1).
- 5 The *lateral cutaneous nerve of the calf* (L4, L5, S1) is a branch of the common peroneal nerve in the popliteal fossa. It supplies the skin of the upper two-thirds of the lateral area of the leg (both in front and behind).
- 6 The *peroneal or sural communicating nerve* (L5, S1, S2) is a branch of the common peroneal nerve. It descends to join the sural nerve about 5 cm above the heel. Before joining the latter it supplies the skin of the lateral area of calf.

- 7 The *medial calcaneal branches* (S1, S2) of the tibial nerve perforate the flexor retinaculum and supply the skin of the heel and the medial side of the sole of the foot.

CLINICAL ANATOMY

- Sural nerve has a tendency to form painful neuroma.
- Sural nerve can be grafted, as it is only sensory, superficial and is easily identified lying between tendon of tendocalcaneus and lateral malleolus.

DEEP FASCIA

DISSECTION

Incise the deep fascia vertically and reflect it. Define the flexor retinaculum posteroinferior to the medial malleolus and identify the tendons enclosed in synovial sheaths passing deep to it.

Identify the medial and lateral bellies of gastrocnemius muscle. Cut the medial belly 5 cm distal to the origin. Reflect it laterally to locate the popliteal vessels and tibial nerve. Identify plantaris muscle with its longest tendon situated posteromedial to lateral head to gastrocnemius.

Reflect the lateral head of gastrocnemius 5 cm distal to its origin. Both the bellies now can be turned distally. Deep to gastrocnemius, expose the strong soleus muscle.

The popliteal vessels and tibial nerve pass deep or anterior to the fibrous arch between the upper parts of the two leg bones.

BOUNDARIES AND SUBDIVISIONS

The posterior compartment of leg is bounded and subdivided by the deep fascia. It is thin above but thick near the ankle, where it forms the flexor and superior peroneal retinacula.

The boundaries of the posterior compartment of the leg are as follows.

Anteriorly: Posterior surfaces of:

- 1 Tibia,
- 2 The interosseous membrane (*see* Fig. 8.3)
- 3 The fibula, and
- 4 The posterior intermuscular septum.

Posteriorly: Deep fascia of the leg.

The posterior compartment is subdivided into three parts—superficial, middle and deep, by two strong fascial septa.

The *superficial transverse fascial septum* (Fig. 9.8) separates the superficial and deep muscles of the back of the leg, and encloses the posterior tibial vessels and tibial nerve. It is attached:



- a. *Above*, to the soleal line of the tibia and the back of the fibula, below the origin of the soleus.
- b. *Below*, it becomes continuous with the flexor and superior peroneal retinacula.
- c. *Medially*, it is attached to the medial border of the tibia.
- d. *Laterally*, to the posterior border of the fibula.

The *deep transverse fascial septum* separates the tibialis posterior from the long flexors of the toes. Attachments:

- a. *Above*, it blends with the interosseous membrane.
- b. *Below*, it blends with the superficial fascial septum.
- c. *Medially*, it is attached to the vertical ridge on the posterior surface of the tibia.
- d. *Laterally*, to the medial crest of the fibula.

Flexor Retinaculum

Some important facts about the retinaculum are as follows.

- 1 **Attachments:** The flexor retinaculum is attached *anteriorly* to the posterior border and tip of the medial malleolus and *posteriorly* and *laterally* to the medial tubercle of the calcaneum (Fig. 9.2). Septa pass from the retinaculum to the underlying bone and divide the space deep to the retinaculum into four compartments.
- 2 **Structures passing deep to the retinaculum:** These are from medial to lateral side.
 - a. The tendon of the tibialis posterior.
 - b. The tendon of the flexor digitorum longus.
 - c. The posterior tibial artery and its terminal branches, along with the accompanying veins.
 - d. The tibial nerve and its terminal branches.
 - e. The tendon of the flexor hallucis longus. Each tendon occupies a separate compartment which is lined by a synovial sheath. The nerve and artery share a common compartment.

These structures (a) to (e) lie in a *tarsal tunnel*. If the nerve gets pressed, it leads to *tarsal tunnel syndrome*.

- 3 The lower part of the deep surface of the flexor retinaculum gives origin to the greater part of the abductor hallucis muscle.
- 4 Near the calcaneum, the retinaculum is pierced by the medial calcanean vessels and nerves.

CLINICAL ANATOMY

Tibial nerve can be injured at:

- a. In upper part of calf from fracture of tibia.
- b. In middle of calf from tight plasters.
- c. Under flexor retinaculum. This is called *tarsal tunnel syndrome*.

Sensory loss: Distal and middle phalanges including nail beds of all toes (see Fig. 8.2). The sensory loss is in the skin over sole of foot.

Motor loss if injured at upper part of calf:

- a. Superficial muscles of calf
- b. Deep muscles of calf
- c. Intrinsic muscles of sole

SUPERFICIAL MUSCLES

The muscles of the back of leg are classified into two groups—superficial and deep. The superficial muscles

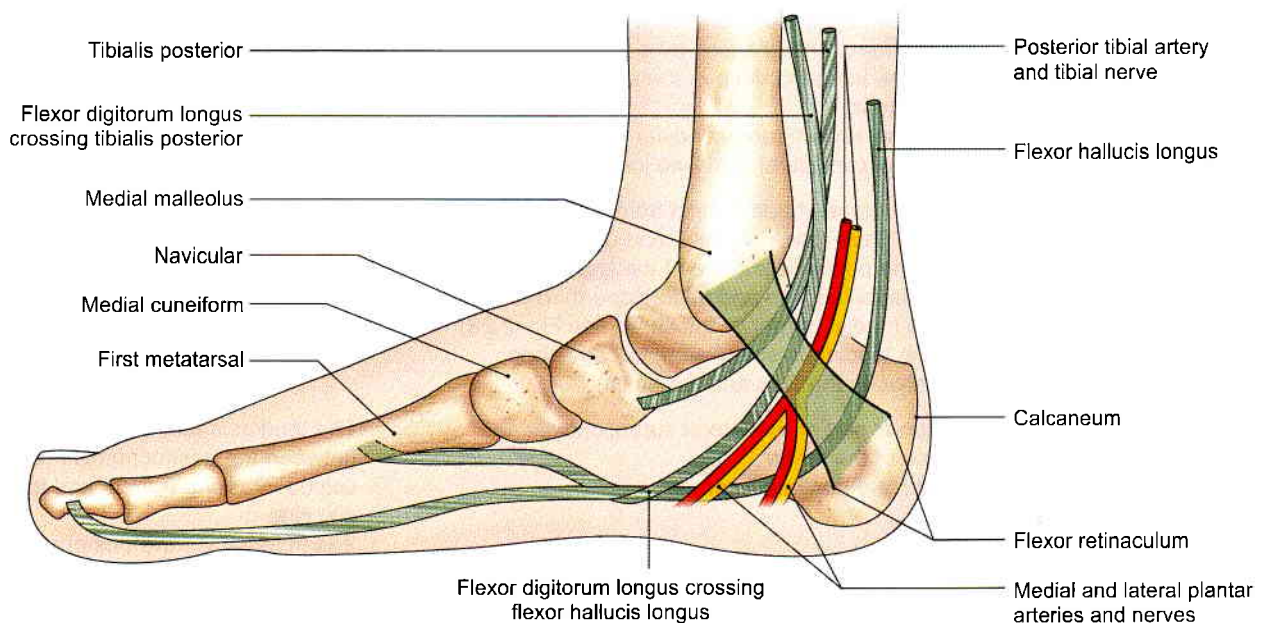


Fig. 9.2: Flexor retinaculum of the ankle, and the structures passing deep to it



are the gastrocnemius, the soleus, and the plantaris. The attachments of these muscles are described in Tables 9.1 and 9.2.

Additional Points of Interest

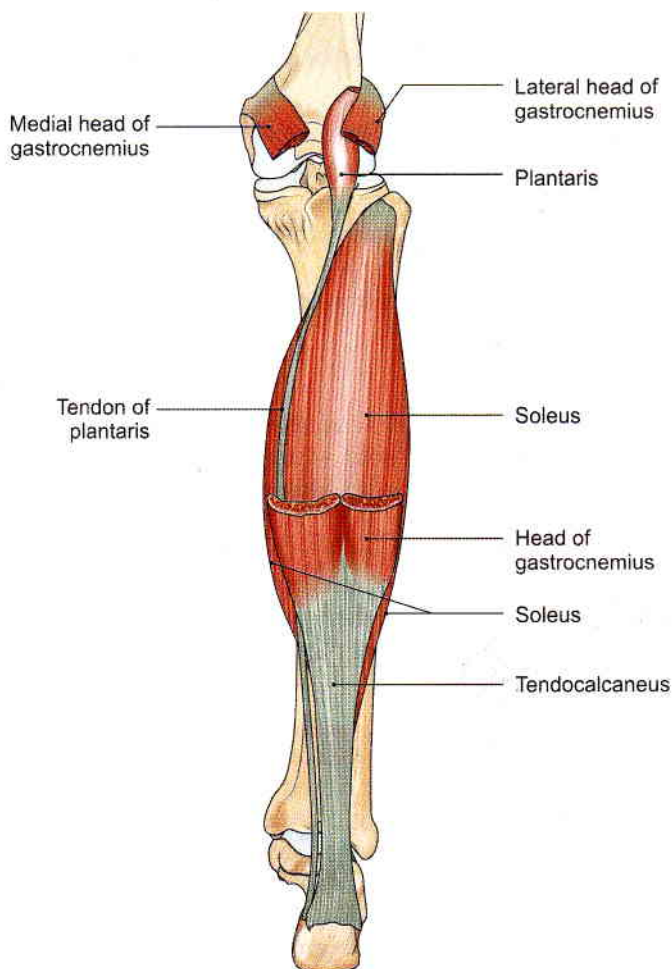
- 1 The large size of the gastrosoleus is a human character, and is directly related to the adoption of an erect posture, and to the bipedal gait of man. Soleus is homologous with flexor digitorum superficialis of the front of forearm.
- 2 From an evolutionary point of view the long plantar ligament is the divorced tendon of the gastrocnemius; and the flexor digitorum brevis is the divorced distal part of the soleus.
- 3 A small sesamoid bone called the fabella is present in the tendon of origin of the lateral head of the gastrocnemius.
- 4 A bursa Brodie's bursa lies deep to the medial head of the gastrocnemius. The bursa is also deep to the semimembranosus and may communicate with the cavity of the knee joint.
- 5 The muscles of the calf play an important role in circulation. Contractions of these muscles help in the venous return from the lower limb. The soleus is particularly important in this respect. There are large, valveless, venous sinuses in its substance. When the muscle contracts the blood in these sinuses is pumped out. When it relaxes, it sucks the blood from the superficial veins through the perforators. The soleus is, therefore, called the *peripheral heart* (Fig. 9.8).
- 6 The *tendocalcaneus* is the thickest and strongest tendon of the body. It is about 15 cm long. It begins near the middle of the leg, but its anterior surface receives fleshy fibres of the soleus almost up to its lower end. It is narrow and thick in the middle, and expanded at both end and is attached to posterior surface of calcaneum (Fig. 9.3).
- 7 Tendocalcaneus is also known as tendo-Achilles. According to a Greek legend, Achilles was an irresistible and invincible warrior. His mother, the sea Goddess, had dipped him in the underground river, Styx. No weapon could harm the body which had been covered by the waters of Styx. But the warrior was ultimately killed in the war of Trojans, by the arrows hitting his vulnerable heel which was

Table 9.1: Superficial muscles of the back of the leg

Muscle	Origin	Insertion
1. Gastrocnemius This is a large powerful muscle. It has two heads, medial and lateral. It lies superficial to the soleus. The two heads of the gastrocnemius, and the soleus, are together referred to as the gastrosoleus or the triceps surae (see Figs 2.12 and 9.3)	a. The <i>medial head</i> is larger than the lateral. It arises by a broad flat tendon from: <ul style="list-style-type: none"> • The posterosuperior depression on the medial condyle of the femur, behind the adductor tubercle • The adjoining raised area on the popliteal surface of the femur • The capsule of the knee joint b. The <i>lateral head</i> arises by a broad flat tendon from: <ul style="list-style-type: none"> • The lateral surface of the lateral condyle of the femur • The lateral supracondylar line • The capsule of the knee joint 	The tendon of this muscle fuses with the tendon of the soleus to form the tendocalcaneus or tendoachilles, which is inserted into the middle one-third of the posterior surface of the calcaneum
2. Soleus It is a sole-shaped multipennate muscle, which lies deep to the gastrocnemius (Fig. 9.3)	It has a dome-shaped origin from: <ol style="list-style-type: none"> a. The fibula: back of head, and upper one-fourth of the posterior surface of the shaft (see Fig. 2.34) b. Tibia: soleal line and middle one-third of the medial border of the shaft (see Fig. 2.28) c. The tendinous soleal arch that stretches between the tibia and the fibula 	See gastrocnemius
3. Plantaris It is vestigial in human beings. It has a short belly and a long tendon (Fig. 9.3)	<ol style="list-style-type: none"> a. Lower part of the lateral supracondylar line of the femur b. Oblique popliteal ligament 	The tendon is thin and long. It lies between the gastrocnemius and the soleus, crossing from lateral to medial side It is inserted on the posterior surface of the calcaneum, medial to the tendocalcaneus. Plantar aponeurosis is the estranged part of the plantaris

**Table 9.2: Nerve supply and actions of superficial muscles**

Muscle	Nerve supply	Actions
1. Gastrocnemius	Tibial nerve (S1, S2)	The gastrocnemius and soleus are strong plantar flexors of the foot, at the ankle joint. The gastrocnemius is also a flexor of the knee. Plantar flexion, produced by the gastrocnemius and the soleus, is very important in walking and running
2. Soleus	Tibial nerve (S1, S2)	The soleus is more powerful than the gastrocnemius, but the latter is faster acting. In walking, the soleus overcomes the inertia of the body weight, like the bottom gear of a car. When movement is under way, the quicker acting gastrocnemius increases the speed like the top gear of a car. Soleus is chiefly a postural muscle, to steady the leg on the foot
3. Plantaris	Tibial nerve (S1, S2)	The plantaris is a rudimentary muscle, and is accessory to the gastrocnemius. Its functional importance is of transplantation

**Fig. 9.3:** Superficial muscles of the back of the leg

the only unprotected part of his body. His mother had held him by one heel, and the water over this heel had not flowed.

DEEP MUSCLES, ARTERIES AND NERVE

DISSECTION

Once the soleus has been studied, separate it from its attachment on tibia and reflect it laterally. Look for a number of deep veins which emerge from this muscle.

Identify popliteus, situated above the soleus muscle. Deep to soleus is the first intermuscular septum. Incise this septum vertically to reach the long flexors of the toes, e.g. flexor hallucis longus laterally and flexor digitorum longus medially. Trace these tendons till the flexor retinaculum. Turn the flexor hallucis longus laterally and expose the second intermuscular septum.

Divide this septum to reveal the deepest muscle of the posterior compartment of leg, e.g. tibialis posterior. Trace its tendon also till flexor retinaculum. Study these deep muscles.

Clean the lowest part of popliteal vessels and trace its two terminal branches, anterior tibial into anterior compartment and posterior tibial into the posterior compartment of leg. Identify posterior tibial vessels and tibial nerve in fibrofatty tissue between the two long flexors of the leg deep to the first intermuscular septum.

Peroneal vessels are identified in the connective tissue of the second intermuscular septum. Study their origin, course and branches from the following text.

The nerve to popliteus deserves special mention. Being a branch of tibial nerve it descends over the popliteus to reach its distal border. There it supplies the muscle after winding around its distal border. It also supplies a branch to tibialis posterior muscle, both tibiofibular joints and interosseous membrane.


Table 9.3: Deep muscles of the posterior compartment of the leg

Name	Origin	Insertion
Popliteus (Fig. 9.4)	Lateral surface of lateral condyle of femur; origin is intracapsular Outer margin of lateral meniscus of the knee joint	Posterior surface of shaft of tibia above soleal line
Flexor digitorum longus (Fig. 9.4)	Upper two-thirds of medial part of posterior surface of tibia below the soleal line	Bases of distal phalanges of shaft of lateral four toes. Muscle ends in a tendon which divides into four slips, one for each of the lateral four toes. Each slip is attached to the plantar surface of the distal phalanx of the digit concerned
Flexor hallucis longus (Fig. 9.4)	Lower three-fourths of the posterior surface of the fibula (except the lowest 2.5 cm) and interosseous membrane (<i>see</i> Fig. 2.34)	Plantar surface of base of distal phalanx of big toe
Tibialis posterior (Fig. 9.4)	Upper two-thirds of lateral part of posterior surface of tibia below the soleal line (<i>see</i> Fig. 2.28). Posterior surface of fibula in front of the medial crest and posterior surface of interosseous membrane	Tuberosity of navicular bone and other tarsal bones except talus. Insertion is extended into 2nd, 3rd and 4th metatarsal bones at their bases

Table 9.4: Nerve supply and actions of deep muscles of the posterior compartment of the leg

Name	Nerve supply	Actions
Popliteus	Tibial nerve	Unlocks knee joint by lateral rotation of femur on tibia prior to flexion
Flexor digitorum longus	Tibial nerve	Flexes distal phalanges, plantar flexor of ankle joint; supports medial and lateral longitudinal arches of foot
Flexor hallucis longus	Tibial nerve	Flexes distal phalanx of big toe; plantar flexor of ankle joint; supports medial longitudinal arch of foot
Tibialis posterior	Tibial nerve	Plantar flexor of ankle joint; inverts foot at subtalar joint, supports medial longitudinal arch of foot (Fig. 9.4)

DEEP MUSCLES

The deep muscles of the back of the leg are the popliteus, the flexor digitorum longus, the flexor hallucis longus, and the tibialis posterior. They are described in Tables 9.3 and 9.4.

Important Relations of Flexor Digitorum Longus

- 1 The tendon crosses the tibialis posterior in lower part of the leg. It passes deep to the flexor retinaculum to enter the sole of foot. Here it crosses the tendon of flexor hallucis longus (Fig. 9.4).
- 2 The tendon receives the insertion of the flexor digitorum accessorius.
- 3 The slips for the digits give origin to the four lumbrical muscles.

Important Relations of Flexor Hallucis Longus

The tendon runs across the lower part of the posterior surface of the tibia. Reaching the calcaneus it turns forwards below the sustentaculum tali which serves as a pulley for it. As the tendon lies on the medial side of calcaneum, it runs deep to the flexor retinaculum and

is surrounded by a synovial sheath. The tendon then runs forwards in the sole when it is crossed by the tendon of flexor digitorum longus.

Important Relations of Tibialis Posterior

The tendon passes behind the medial malleolus, grooving it. The tendon then passes deep to the flexor retinaculum. The terminal part of the tendon supports the spring ligament.

CLINICAL ANATOMY

- The deep muscles are tested by palpating the calf while the foot is being plantarflexed (Fig. 9.5).
- Tendo-Achilles reflex or ankle jerk (S1, S2): The foot gets plantar flexed on tapping the tendocalcaneus (Fig. 9.6).
- For thromboangiitis obliterans or occlusive disease of lower limb arteries, sympathetic fibres to the arteries are removed, so as to denervate the arteries. Lumbar 2 and 3 ganglia with intervening sympathetic trunk is removed, as these supply the arteries of lower limb.



- In long distance air travel, sitting immobile can lead to thrombosis of soleal venous sinuses. The thrombus may get dislodged to block any other artery. One must stretch the legs frequently.
- Dislocation or subluxation of ankle is common during plantarflexion. Lower end of the leg bones, i.e. medial malleolus, tibia, thin fibula and lateral malleolus form tibiofibular mortice. This is wider anteriorly and narrow posteriorly. The trochlear surface of talus forming ankle joint is also wider anteriorly and narrow posteriorly. During dorsiflexion, wider trochlear surface fits into narrow posterior part of the mortice. The joint is stable and close packed. During plantarflexion the narrow posterior trochlear surface lies loosely in wider anterior part of the mortice. The joint is unstable and can easily get subluxated or dislocated. This occurs while walking in high heels (Fig. 9.10).

POSTERIOR TIBIAL ARTERY

Beginning, Course and Termination

It begins at the lower border of the popliteus, between the tibia and the fibula, deep to the gastrocnemius (Fig. 9.7).

It enters the back of leg by passing deep to the tendinous arch of the soleus.

In the leg, it runs downwards and slightly medially, to reach the posteromedial side of the ankle, midway between the medial malleolus and the medial tubercle of the calcaneum.

It terminates deep to flexor retinaculum (and the origin of the abductor hallucis) by dividing, into the lateral and medial plantar arteries (Fig. 9.2).

Relations

Superficial

- 1 In the upper two-thirds of the leg, it lies deep to the gastrocnemius, the soleus and the superficial transverse fascial septum (Fig. 9.8).
- 2 In the lower one-third of the leg, it runs parallel to, and 2.5 cm in front of, the medial border of the tendocalcaneus. It is covered by skin and fasciae.
- 3 At the ankle, it lies deep to the flexor retinaculum and the abductor hallucis (Fig. 9.2).

Deep

- 1 In the upper two-thirds of the leg, it lies on the tibialis posterior (Fig. 9.8).
- 2 In the lower one-third of the leg, it lies on the flexor digitorum longus and on the tibia.
- 3 At the ankle, it lies directly on the capsule of the ankle joint between the flexor digitorum longus and the flexor hallucis longus (Fig. 9.2).

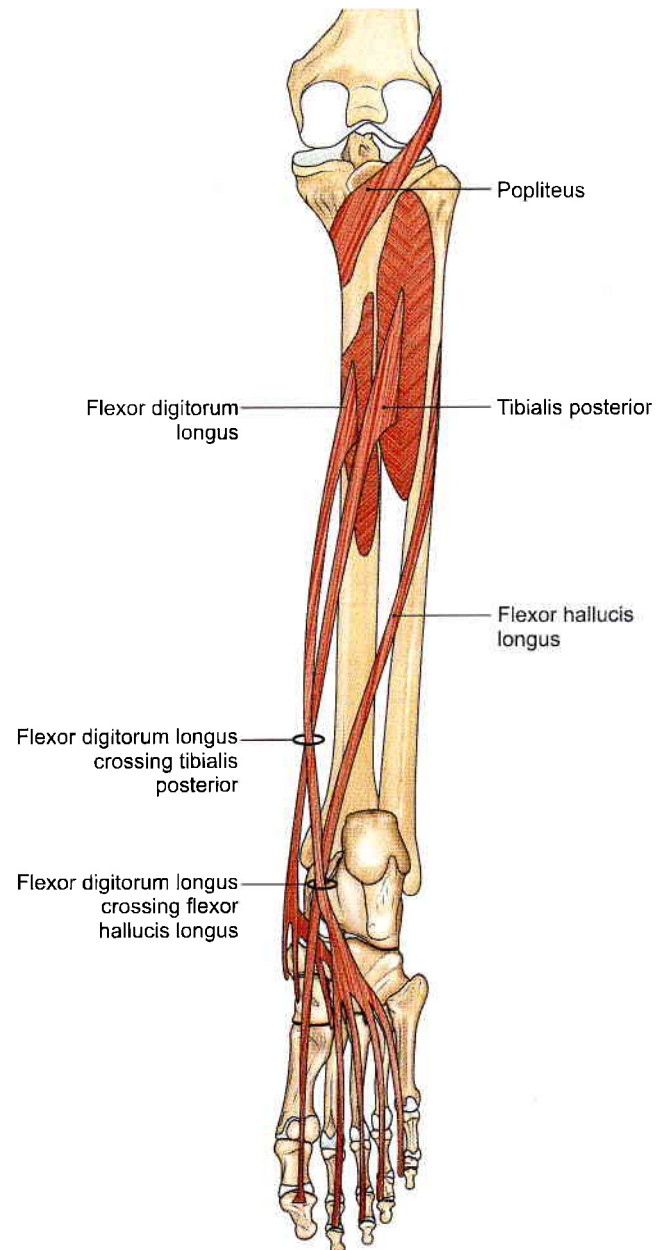


Fig. 9.4: Deep muscles of the back of the leg

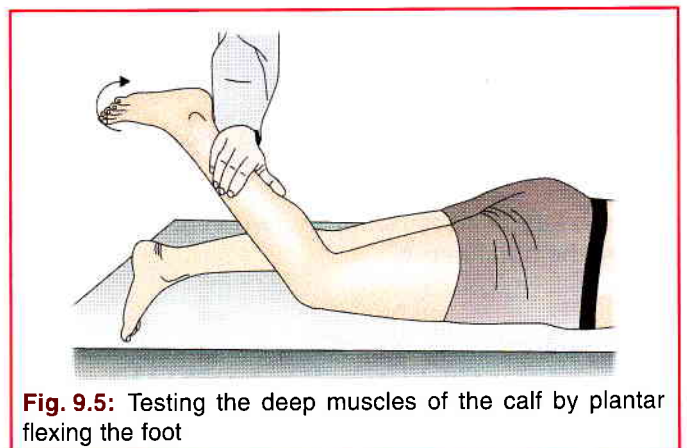


Fig. 9.5: Testing the deep muscles of the calf by plantar flexing the foot

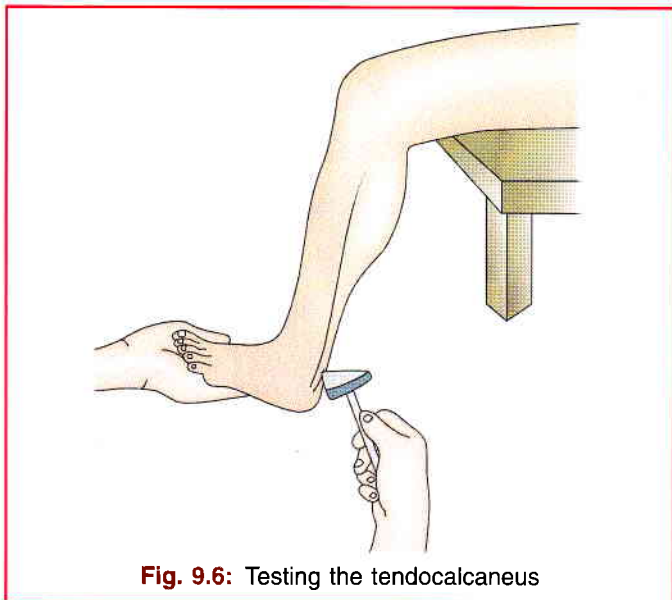


Fig. 9.6: Testing the tendocalcaneus

- 3 A *nutrient artery* is given off to the tibia.
- 4 The *anastomotic branches* of the posterior tibial artery are as follows.
 - a. The circumflex fibular branch winds round the lateral side of the neck of the fibula to reach the front of the knee where it takes part in the anastomoses around the knee joint.
 - b. A communicating branch forms an arch with a similar branch from the peroneal artery about 5 cm above the ankle.
 - c. A malleolar branch anastomoses with other arteries over the medial malleolus.
 - d. Calcaneal branches anastomose with other arteries in the region.
- 5 *Terminal branches*: These are the medial and lateral plantar arteries. They will be studied in the sole (Fig. 9.7).

PERONEAL ARTERY

Beginning, Course and Termination

This is the largest branch of the posterior tibial artery. It supplies the posterior and lateral compartments of the leg (Fig. 9.7).

It begins 2.5 cm below the lower border of the popliteus.

It runs obliquely towards the fibula, and descends along the medial crest of the fibula, accompanied by the nerve to the flexor hallucis longus. It passes behind the inferior tibiofibular and ankle joints, medial to peroneal tendons. It terminates by dividing into a number of lateral calcaneal branches (Fig. 9.7).

Branches

- 1 *Muscular branches*, to the posterior and lateral compartments.
- 2 *Nutrient artery*, to the fibula.
- 3 *Anastomotic branches*:
 - a. The large perforating branch pierces the interosseous membrane 5 cm above the ankle, and joins the lateral malleolar network.
 - b. The communicating branch anastomoses with a similar branch from the posterior tibial artery, about 5 cm above the lower end of the tibia.
 - c. The calcaneal branches join the lateral malleolar network.

The perforating branch of the peroneal artery may reinforce, or even replace the dorsalis pedis artery.

TIBIAL NERVE

Course

The course and relations of the tibial nerve in the leg are similar to those of the posterior tibial artery. Like the artery, the tibial nerve also terminates by dividing into the medial plantar and lateral plantar nerves (Fig. 9.2).

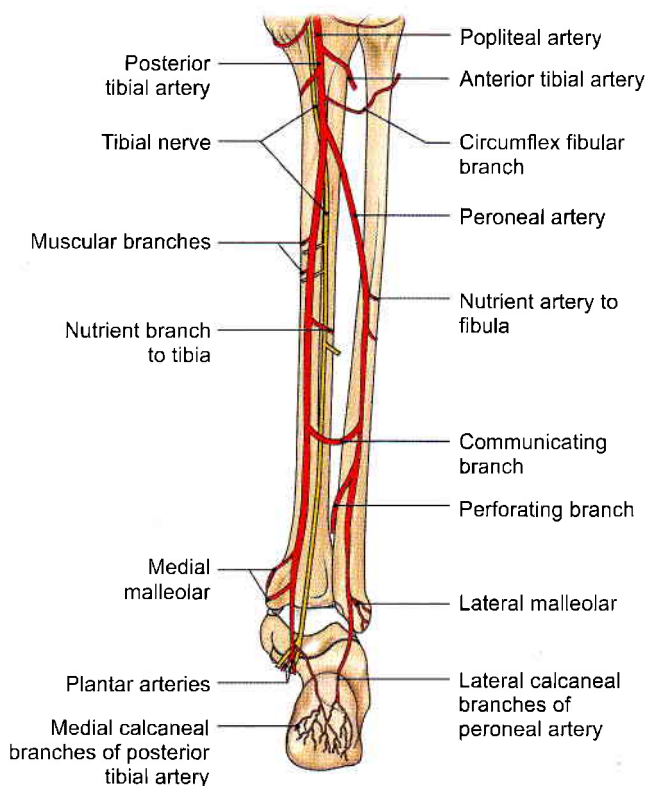


Fig. 9.7: Course of the posterior tibial and peroneal arteries and the tibial nerve

The artery is *accompanied* by two *venae comitantes* and by the tibial nerve.

Branches

- 1 The *peroneal artery* (Fig. 9.7) is the largest branch of the posterior tibial artery. It is described later.
- 2 Several *muscular branches* are given off to muscles of the back of the leg.

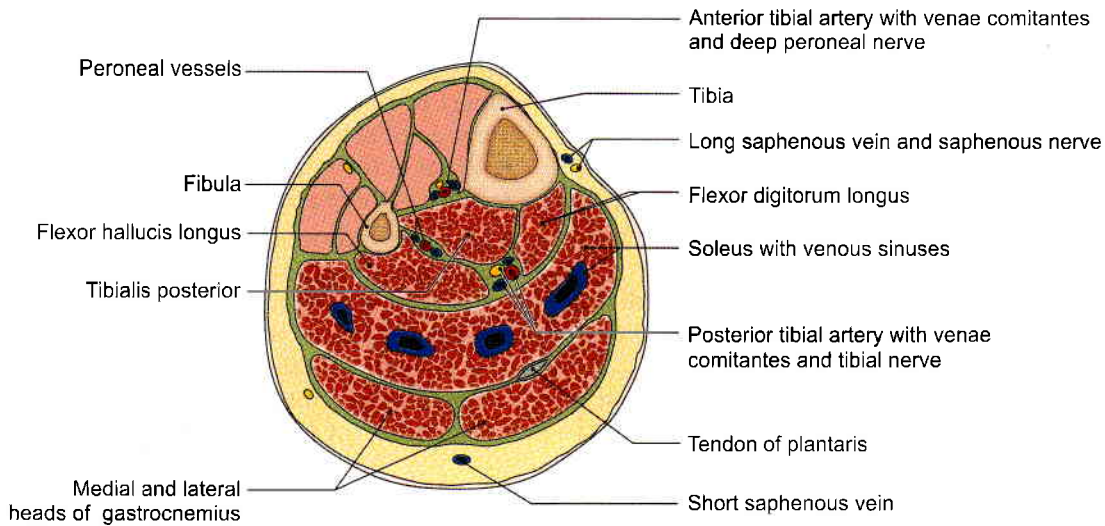


Fig. 9.8: Transverse section through the middle of the leg, showing the arrangement of structures in the posterior compartment

Branches

Muscular

To the tibialis posterior, the flexor digitorum longus; the flexor hallucis longus, and the deep part of the soleus (Figs 9.7 and 9.8).

Cutaneous

Medial calcanean branches pierce the flexor retinaculum, and supply the skin on the back and lower surface of the heel.

Articular

To the ankle joint.

Terminal

Medial plantar and lateral plantar nerves (Fig. 9.2).

CLINICAL ANATOMY

- The posterior tibial pulse is palpated in doubtful cases of intermittent claudication where a person gets cramps and severe pain in calf muscles due to lack of blood supply.
- The posterior tibial pulse can be felt against the calcaneum about 2 cm below and behind the medial malleolus (Fig. 9.9).
- The long tendon of plantaris is used for tendon transplantation in the body.
- Tendocalcaneus can rupture in tennis players 5 cm above its insertion. Plantar flexion is not possible. The two ends must be stitched.
- High heels for long periods causes change in posture. Knees are excessively bent, with lumbar vertebrae pushed forwards. There is a lot of stress on the muscles of back and those of the calf. So many fashionable ladies wear high heels for short time and change to flat ones soon (Fig. 9.10).

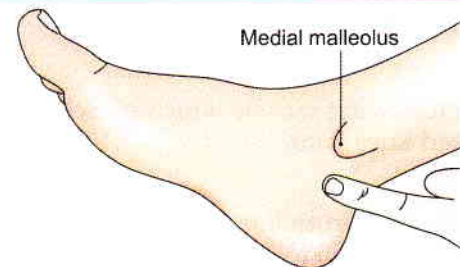


Fig. 9.9: Site of palpation of the posterior tibial artery



Fig. 9.10: Smart high heels

Mnemonics

Structures under flexor retinaculum

Talented **d**octors are **n**ever hungry
Tibialis posterior
Flexor **d**igitorum longus
Posterior tibial **a**rtery
Tibial **n**erve
Flexor **h**allucis longus





FACTS TO REMEMBER

- Soleus acts as the peripheral heart, as it pushes the venous blood upwards.
- Soleus acts like first gear while gastrocnemius act like second and third gears during walking.
- Tendocalcaneus is the strongest tendon in the body
- All the muscles of back of leg/calf are supplied by the tibial nerve
- Posterior tibial artery is palpated between medial malleolus and calcaneus under the flexor retinaculum.
- Posterior tibial artery ends by dividing into medial and lateral plantar arteries.

CLINICOANATOMICAL PROBLEM

An elderly man complained of pain on the inner aspect of right ankle joint. The pain was also felt in the area of sole.

- What is the syndrome called?
- Why is there pain in the sole?

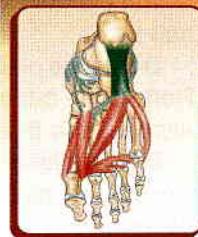Ans: The syndrome is called *tarsal tunnel syndrome* if tibial nerve gets entrapped under the flexor retinaculum of the ankle. Since the tibial nerve gets constricted, there is pain in the sole as the medial and lateral plantar nerves are affected. There may be paralysis of intrinsic muscles of the sole due to compression of medial and lateral plantar nerves.

MULTIPLE CHOICE QUESTIONS

- Which muscle is called peripheral heart?
 - Soleus
 - Gastrocnemius
 - Plantaris
 - Sartorius
- Out of following muscle which muscle acts as key of locked knee joint?
 - Popliteus
 - Flexor digitorum longus
 - Tibialis posterior
 - Flexor hallucis longus
- Plantaris is inserted in:
 - Posterior surface of calcaneum
 - Medial to tendocalcaneus
 - Both a and b
 - None of above
- What relation of flexor digitorum longus is wrong (not correct)?
 - The tendon crosses the tibialis posterior in lower part of leg
 - The tendon receives insertion of flexor digitorum accessorius
 - The 4 slips of the tendon give origin to 3 lumbrical muscles
 - The tendon crosses the tendon of flexor hallucis longus
- If tibial nerve is injured under flexor retinaculum, the condition is called:
 - Tarsal tunnel syndrome
 - Foot drop
 - Morton's neuroma
 - Pes calcaneus
- Tibialis posterior is chiefly inserted into:
 - Base of distal phalanges of shaft of lateral 4 toes
 - Base of distal phalanges of big toe
 - Posterior surface of shaft of tibia
 - Tuberosity of navicular bone
- Deep muscles of posterior compartment of leg are supplied by:
 - Tibial nerve
 - Deep peroneal nerve
 - Obturator nerve
 - Femoral nerve

ANSWERS

1. a 2. a 3. c 4. c 5. a 6. d 7. a



Sole of Foot

English is funny. Just before disaster, a message was received, "Save our sole."

INTRODUCTION

The structure of the sole is similar to that of the palm. The skin, superficial fascia, deep fascia, muscles, vessels and nerves, are all comparable in these two homologous parts. However, unlike the hand, the foot is an organ of support and locomotion. Accordingly, the structures of the foot get modified. The great toe has lost its mobility and its power of prehension; the lesser four toes are markedly reduced in size; and the tarsal bones and the first metatarsal are enlarged to form a broad base for better support. The arches of the foot serve as elastic springs for efficient walking, running, jumping and supporting the body weight.

SKIN

DISSECTION

Skin of the sole usually becomes very hard. To remove it, the incision is given from heel through the root to the tip of the middle toe. Reflect the skin and fatty superficial fascia to each side of the sole. Look for cutaneous nerves and vessels.

Features

The skin of the sole, like that of the palm, is:

- 1 Thick for protection;
- 2 Firmly adherent to the underlying plantar aponeurosis; and
- 3 Creased. These features increase the efficiency of the grip of the sole on the ground.

The skin is mainly supplied by three cutaneous nerves (Fig. 10.1). The nerves are:

- a. Medial calcanean branches of the tibial nerve, to the posterior and medial portions;
- b. Branches from the medial plantar nerve to the larger, anteromedial portion including the medial three and a half digits; and

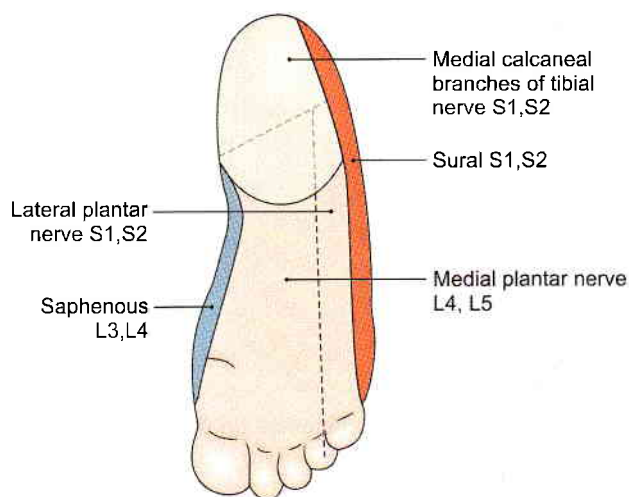


Fig. 10.1: Cutaneous nerves supplying the sole

- c. Branches from the lateral plantar nerve to the smaller anterolateral portion including the lateral one and a half digits.
- d. Small areas on medial and lateral sides are innervated by saphenous and sural nerves.

These nerves are derived from spinal nerves L4, L5 and S1. The segmental distribution is shown in Fig. 10.2. In eliciting the plantar reflex, the area supplied by segment S1 is stimulated.

FASCIAE

DISSECTION

The deep fascia on the plantar aspect of toes is thickened to form fibrous flexor sheaths; proximally it is continuous with the plantar aponeurosis.

Identify the cutaneous branches from medial and lateral plantar arteries and nerves on the respective sides of plantar aponeurosis.



Between the five distal slips of the aponeurosis trace the digital nerves and vessels from medial plantar nerve and vessels for three and a half medial toes and from lateral plantar nerve and vessels for lateral one and a half toes.

Divide the plantar aponeurosis 4 cm distal to the heel. Reflect the cut ends both proximally and distally. This exposes the three muscles of the first layer of sole.

Medial plantar nerve and vessels are easily visualised close to the medial border of sole. Stems of lateral plantar nerve and vessels including its superficial division are also seen.

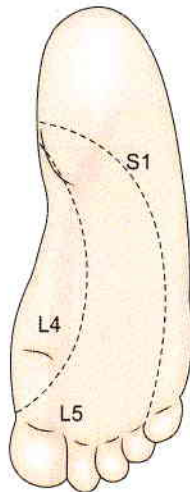


Fig. 10.2: Dermatomes on the sole

Superficial Fascia

The superficial fascia of the sole is fibrous and dense. Fibrous bands bind the skin to the deep fascia or plantar aponeurosis, and divide the subcutaneous fat into small tight compartments which serve as water-cushions and reinforce the spring-effect of the arches of the foot during walking, running and jumping. The fascia is very thick and dense over the weight-bearing points. It contains cutaneous nerves and vessels. Thickened bands of superficial fascia stretch across the roots of the toes forming the *superficial transverse metatarsal ligaments*.

DEEP FASCIA

The deep fascia of the sole is specialized to form:

- 1 The plantar aponeurosis in the sole.
- 2 The deep transverse metatarsal ligaments between the metatarsophalangeal joints.
- 3 The fibrous flexor sheaths in the toes.

Plantar Aponeurosis

The deep fascia covering the sole is thick in the centre and thin at the sides. The thickened central part is known as the *plantar aponeurosis* (Fig. 10.3).

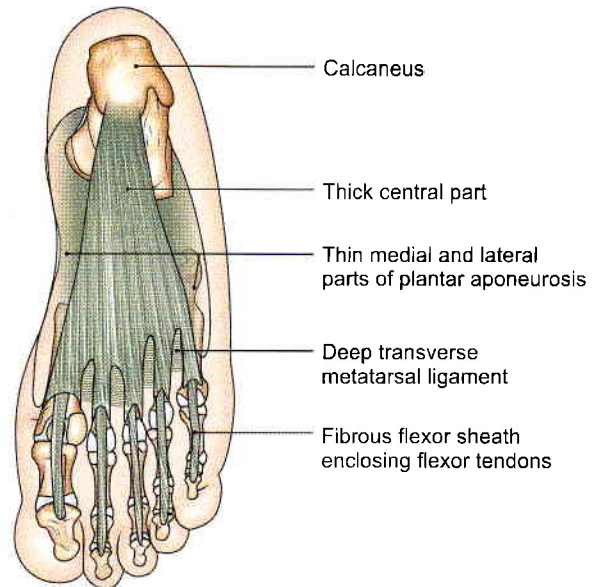


Fig. 10.3: Plantar aponeurosis and fibrous flexor sheaths

Plantar aponeurosis represents the distal part of the plantaris which has become separated from the rest of the muscle during evolution because of the enlargement of the heel.

The aponeurosis is triangular in shape. The *apex* is proximal. It is attached to the medial tubercle of the calcaneum, proximal to the attachment of the flexor digitorum brevis. The *base* is distal. It divides into five processes near the heads of the metatarsal bones. The digital nerves and vessels pass through the intervals between the processes.

Each process splits, opposite the metatarsophalangeal joints, into a *superficial* and a *deep slip*. The superficial slip is attached to dermis of skin. The deep slip divides into two parts which embrace the flexor tendons, and blend with the fibrous flexor sheaths and with the deep transverse metatarsal ligaments.

From the margins of the aponeurosis, lateral and medial *vertical intermuscular septa* pass deeply, and divide the sole into three compartments. Thinner *transverse septa* arise from the vertical septa and divide the muscles of the sole into four layers.

Functions

- 1 It fixes the skin of the sole.
- 2 It protects deeper structures.
- 3 It helps in maintaining the longitudinal arches of the foot.
- 4 It gives origin to muscles of the first layer of the sole.

The plantar aponeurosis differs from the palmar aponeurosis in giving off an additional process to the great toe, which restricts the movements of the latter.



Deep Transverse Metatarsal Ligaments

These are four short, flat bands which connect the plantar ligaments of the adjoining metatarsophalangeal joints. They are related dorsally to the interossei, and ventrally to the lumbricals and the digital vessels and nerves.

Fibrous Flexor Sheaths

These are made up of the deep fascia of the toes. Their structure is similar to that of the fibrous flexor sheaths of the fingers. They retain the flexor tendons in position during flexion of the toes (Fig. 10.3).

CLINICAL ANATOMY

Plantar fasciitis occurs in policemen due to stretching of the plantar aponeurosis. This results in pain in the heel region, especially during standing.

MUSCLES OF SOLE

The muscles of the sole are arranged in four layers, which will be considered one by one.

MUSCLES AND TENDONS OF THE FIRST AND SECOND LAYERS

DISSECTION

Cut through the flexor digitorum brevis near its middle taking care to preserve the underlying lateral plantar nerve and vessels. Reflect the distal part distally till the toes.

Detach the abductor digiti minimi and identify the lateral head of the flexor digitorum accessorius till its insertion into the tendon of flexor digitorum longus.

Trace the long flexor tendons through the fibrous flexor sheath into the base of distal phalanges of toes.

Follow the lumbricals to their insertion into the base of the proximal phalanx and into the extensor expansion of the dorsum of toes. Study the muscles of second layer comprising the long flexor tendons and associated muscles.

Cut through both the long flexor tendons (flexor hallucis longus and flexor digitorum longus) and flexor digitorum accessorius where all the three are united to each other. Reflect the ends proximally and distally to reveal the muscles of third layer of sole.

Muscles of First Layer

The muscles of the first layer are the *flexor digitorum brevis*, the *abductor hallucis*, and the *abductor digiti minimi*.

These muscles are described in Tables 10.1 and 10.2 and shown in Figs 10.4a and b.

Muscles of Second Layer

The contents of second layer are the tendons of the flexor digitorum longus, and of the flexor hallucis longus; and the flexor digitorum accessorius and lumbrical muscles. The muscles are described in Tables 10.3 and 10.4.

MUSCLES AND TENDONS OF THE THIRD AND FOURTH LAYERS

DISSECTION

Separate flexor hallucis brevis and oblique head of adductor hallucis from their origin and reflect them distally.

Preserve the plantar arch and deep plantar nerve. Look for sesamoid bones at the insertion of flexor hallucis brevis.

Reflect the transverse head of adductor hallucis medially. On cutting the deep transverse metatarsal ligament on both sides of second toe, tendons of interossei muscles are recognised.

Detach the flexor digiti minimi brevis from its origin and reflect it forwards. This will show the laterally situated interossei muscles.

Identify and examine the attachment of tendon of tibialis posterior on the medial side of foot.

Trace the course of tendon of peroneus longus through the groove in the cuboid bone across the sole to its insertions into lateral sides of base of first metatarsal and medial cuneiform bone.

After studying the muscles of the third layer, detach them from their origins towards their insertions. The muscles of the fourth layer are visualised.

Muscles of the Third Layer

The third layer of the sole contains three muscles. These are the *flexor hallucis brevis*, the *flexor digiti minimi brevis*, and the *adductor hallucis* (Figs 10.6a and b). They are described in Tables 10.5 and 10.6.

Muscles of the Fourth Layer

The structures present in the fourth layer of the sole are the *interosseous muscles*, and the *tendons* of the *tibialis posterior* and of the *peroneus longus*.

Interosseous Muscles of the Foot

These are small muscles placed between the metatarsal bones. There are three plantar and four dorsal interossei (Figs 10.7 and 10.8).



Table 10.1: Muscles of the first layer of the sole

Muscle	Origin from	Insertion
1. Flexor digitorum brevis This muscle lies deep to the plantar aponeurosis (Fig. 10.4a)	a. Medial tubercle of calcaneum b. Plantar aponeurosis c. Medial and lateral intermuscular septa	The muscle ends in four tendons for the lateral four toes. Opposite the base of the proximal phalanx each tendon divides into two slips that are inserted into the margins of the middle phalanx. The tendon of the flexor digitorum longus (for that digit) passes through the gap between the two slips. Note that the insertion is similar to that of the flexor digitorum superficialis of the hand
2. Abductor hallucis This muscle lies along the medial border of foot, and covers the origin of the plantar vessels and nerves	a. Medial tubercle of calcaneum b. Flexor retinaculum c. Deep fascia covering it d. Medial intermuscular septum	The tendon fuses with the medial portion of the tendon of the flexor hallucis brevis. It is inserted into the medial side of the base of the proximal phalanx of the great toe
3. Abductor digiti minimi This muscle lies along the lateral border of foot (Fig. 10.4a)	a. Medial and lateral tubercles of calcaneum b. Lateral intermuscular septum c. Deep fascia covering it	The tendon fuses with the tendon of the flexor digiti minimi brevis. It is inserted into the lateral side of the base of the proximal phalanx of the little toe

Table 10.2: Nerve supply and actions of muscles of the first layer of the sole

Muscle	Nerve supply	Actions
1. Flexor digitorum brevis	Medial plantar nerve	Flexion of the toes at the proximal interphalangeal joints and metatarsophalangeal joints
2. Abductor hallucis	Medial plantar nerve	Abduction of the great toe away from the second toe
3. Abductor digiti minimi	Main trunk of lateral plantar nerve	Abduction of the little toe

PLANTAR VESSELS AND NERVES

DISSECTION

Dissect the medial plantar nerve and vessels on the medial side of sole. Lateral plantar nerve and vessels also enter the sole from the medial side. These cross the sole to reach the lateral side. Here lateral plantar artery forms a plantar arch across the sole which gives numerous branches. The lateral plantar nerve divides into a superficial and deep branch. The latter runs in the concavity of the plantar arch. The course branches of nerves and vessels are given in the text.

Features

- 1 The chief arteries of the sole are the medial and lateral plantar arteries. They are terminal branches of the posterior tibial artery (Fig. 10.9).
- 2 The chief nerves of the sole are the medial and lateral plantar nerves. They are terminal branches of the tibial nerve.
- 3 These arteries and nerves begin deep to the flexor retinaculum. The posterior tibial artery divides into the medial and lateral plantar arteries a little higher than the division of tibial nerve. As a result the arteries are closer to the margins of the sole than the corresponding nerves.

- 4 The medial plantar vessels and nerve lie between the abductor hallucis and the flexor digitorum brevis (Fig. 10.4b).
- 5 The lateral plantar vessels and nerve run obliquely towards the base of the 5th metatarsal bone, between the first and second layers of the sole. Here the artery turns medially and becomes continuous with the plantar arch. This arch lies between the third and fourth layers of the sole (Fig. 10.9). The plantar arch is accompanied by the deep branch of the lateral plantar nerve.

MEDIAL PLANTAR NERVE

Origin and Course

Medial plantar nerve is the larger terminal branch of the tibial nerve. It passes forwards between *abductor hallucis* and *flexor digitorum brevis* and divides into its branches. In its distribution, it resembles the median nerve of the hand (Fig. 10.4b).

Branches

Its *muscular branches* supply four muscles as follows.

- 1 The abductor hallucis.
- 2 The flexor digitorum brevis.
- 3 The flexor hallucis brevis receives a branch from the first digital nerve.



Table 10.3: Muscles and tendons of the second layer of the sole (Fig. 10.5)

<i>Muscle</i>	<i>Origin from</i>	<i>Insertion</i>
1. Flexor digitorum longus (Fig. 10.5) (muscle of calf) (see Fig. 2.28 and 9.4)	From upper two-thirds of the medial part of the posterior surface of tibia below the soleal line	The muscle divides into four tendons. Each is inserted to the plantar surface of distal phalanx of second to fifth digit
2. Flexor digitorum accessorius It is so called because it is accessory to the flexor digitorum longus	It arises by two heads a. <i>Medial head</i> is large and fleshy; it arises from the medial concave surface of the calcaneum b. Lateral head is smaller and tendinous; it arises from the calcaneum in front of the lateral tubercle, The two heads unite at an acute angle	The muscle fibres are inserted into the lateral side of the tendon of the flexor digitorum longus
3. Lumbricals There are four of them, numbered from medial to lateral side (Fig. 10.5)	They arise from the tendons of the flexor digitorum longus. The first lumbrical is unipennate, and the others are bipennate First lumbrical arises from medial side of 1st tendon of flexor digitorum longus Second lumbrical arises from adjacent sides of 1st and 2nd tendons of flexor digitorum longus Third lumbrical arises from adjacent sides of 2nd and 3rd tendons of flexor digitorum longus Fourth lumbrical arises from adjacent sides of 3rd and 4th tendons of flexor digitorum longus	Their tendons pass forwards on the medial sides of the metatarsophalangeal joints of the lateral four toes, and then dorsally for insertion into the extensor expansion
4. Flexor hallucis longus (muscle of calf) (see Fig. 2.34 and 9.4)	Lower three-fourths of the posterior surface of fibula except lowest 2.5 cm and adjoining interosseous membrane	Plantar surface of the base of the distal phalanx of the great toe

Table 10.4: Nerve supply and actions of muscles and tendons of the second layer of the sole

<i>Muscle</i>	<i>Nerve supply</i>	<i>Actions</i>
1. Flexor digitorum longus	Tibial nerve	Plantar flexion of lateral four toes Plantar flexion of ankle Maintains medial longitudinal arch
2. Flexor digitorum accessorius	Main trunk of lateral plantar nerve	1. Straightens the pull of the long flexor tendons 2. Flexes the toes through the long tendons
3. Lumbricals	The first muscle by the medial plantar nerve; and the other three by the deep branch of lateral plantar nerve	They maintain extension of the digits at the interphalangeal joints so that in walking and running the toes do not buckle under
4. Flexor hallucis longus	Tibial nerve	Plantar flexor of the big toe, plantar flexor of ankle joint, maintains medial longitudinal arch

4 The first lumbrical muscle receives a branch from the second digital nerve.

Cutaneous branches supply the skin of the medial part of the sole, and of the medial three and a half toes through four digital branches.

The first digital nerve supplies the medial side of the great toe.

The second nerve supplies the adjacent sides of the first and second toes.

The third nerve supplies the adjacent sides of the second and third toes;

The fourth nerve supplies the adjacent sides of the third and fourth toes.

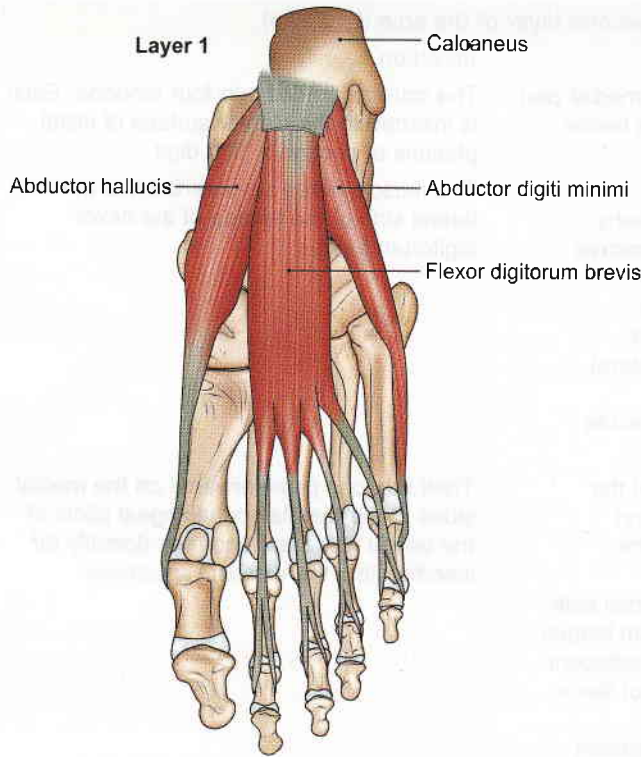


Fig. 10.4a: Muscles of the first layer of the sole

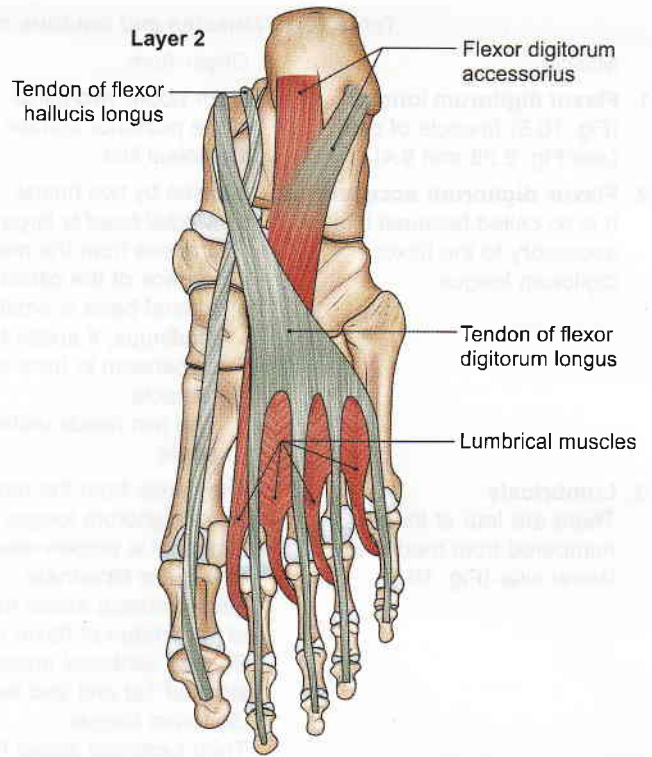


Fig. 10.5: Muscles and tendons of the second layer of the sole

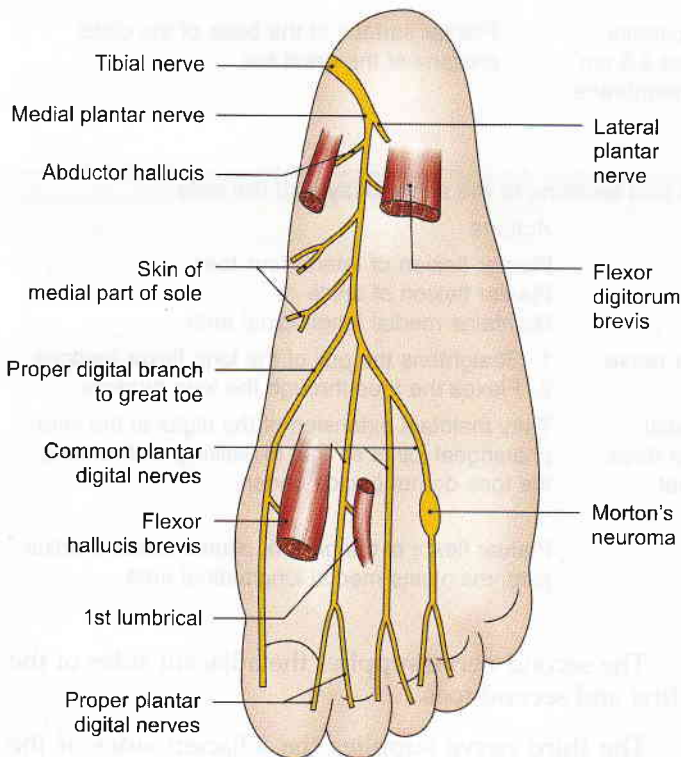


Fig. 10.4b: Scheme to show the distribution of the medial plantar nerve with Morton's neuroma on one branch of the nerve

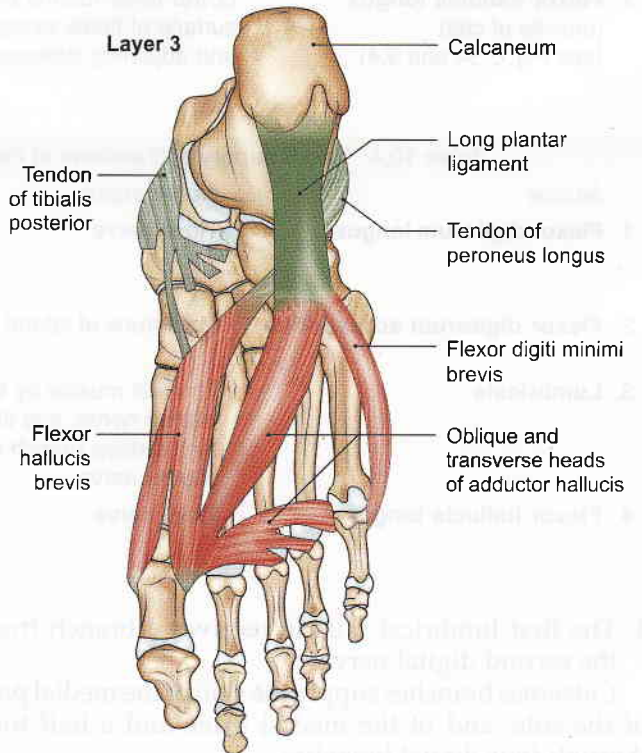


Fig. 10.6a: Muscles of third layer of the sole. The tendons of tibialis posterior and peroneus longus belong to the fourth layer

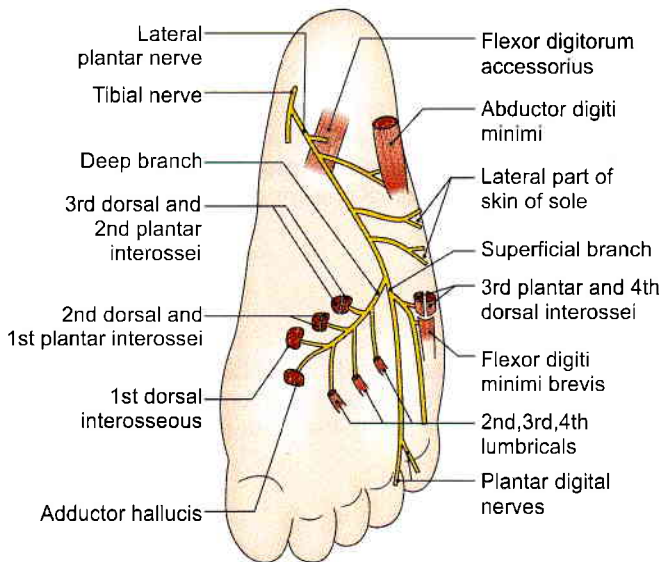


Fig. 10.6b: Scheme to show the distribution of the lateral plantar nerve

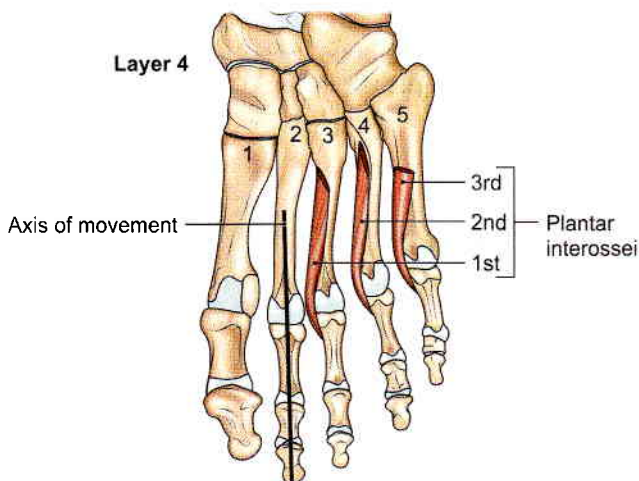


Fig. 10.7: The plantar interossei

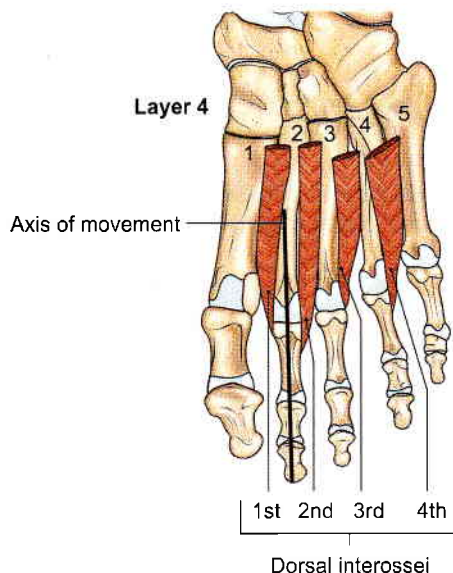


Fig. 10.8: The dorsal interossei

Each digital nerve gives off a dorsal branch which supplies structures around the nail of the digit concerned.

Articular branches supply joints of the tarsus and metatarsus.

LATERAL PLANTAR NERVE

Origin

Lateral plantar nerve (Fig. 10.6b) is the smaller terminal branch of the tibial nerve. It passes laterally and forwards till base of fifth metatarsal, where it divides into superficial and deep branches. In its distribution, it resembles the ulnar nerve in the hand.

Branches

The *main trunk* supplies two muscles, the *flexor digitorum accessorius* and the *abductor digiti minimi*, and the skin of the sole. The main trunk ends by dividing into superficial and deep branches.

The *superficial branch* divides into two branches, lateral and medial. The *lateral branch* supplies three muscles—*flexor digiti minimi brevis*, the *third plantar* and *fourth dorsal interossei*, and the skin on the lateral side of the little toe. The *medial branch* communicates with the medial plantar nerve, and supplies the skin lining the fourth interdigital cleft.

The *deep branch* supplies *nine* muscles, including the second, third and fourth lumbricals; first, second and third dorsal interossei; first and second plantar interossei and adductor hallucis.

CLINICAL ANATOMY

- A neuroma may be formed on the branch of medial plantar nerve between 3rd and 4th metatarsal bones. It is called *Morton's neuroma* (Fig. 10.4b). This causes pain between third and fourth metatarsals. It may be also due to pressure on digital nerve between 3rd and 4th metatarsals.
- Any of the digital nerves, especially the one in the third interdigital cleft may develop neuroma. This is a painful condition.

MEDIAL PLANTAR ARTERY

Beginning, Course and Termination

Medial plantar artery is a smaller terminal branch of the posterior tibial artery. It lies along the medial border of foot and divides into branches.

Branches

It gives off cutaneous, muscular branches to the overlying skin and to the adjoining muscles, and three small superficial digital branches that end by joining the first, second and third plantar metatarsal arteries which are branches of the plantar arch (Fig. 10.9).



Table 10.5: Muscles of the third layer of the sole

Muscle	Origin from	Insertion
1. Flexor hallucis brevis It covers the plantar surface of the first metatarsal bone (Fig. 10.6b)	It arises by a Y-shaped tendon: a. The <i>lateral limb</i> , from the medial part of the plantar surface of the cuboid bone, behind the groove for the peroneus longus and from the adjacent side of the lateral cuneiform bone b. The <i>medial limb</i> is a direct continuation of the tendon of tibialis posterior into the foot	The muscle splits into medial and lateral parts, each of which ends in a tendon. Each tendon is inserted into the corresponding side of the base of the proximal phalanx of the great toe
2. Adductor hallucis	It arises by two heads: a. The <i>oblique head</i> is large, and arises from the bases of the second, third, and fourth metatarsals, from the sheath of the tendon of the peroneus longus b. The <i>transverse head</i> is small, and arises from the deep metatarsal ligament, and the plantar ligaments of the metatarsophalangeal joints of the third, fourth and fifth toes (transverse head has no bony origin)	On the lateral side of the base of the proximal phalanx of the big toe, in common with the lateral tendon of the flexor hallucis brevis
3. Flexor digiti minimi brevis : It lies along the fifth metatarsal bone	a. Base of the fifth metatarsal bone b. Sheath of the tendon of the peroneus longus	Into the lateral side of the base of the proximal phalanx of the little toe

Table 10.6: Nerve supply and actions of muscles of the third layer of the sole

Muscle	Nerve supply	Actions
1. Flexor hallucis brevis	Medial plantar nerve	Flexes the proximal phalanx at the metatarsophalangeal joint of the great toe
2. Adductor hallucis	Deep branch of lateral plantar nerve, which terminates in this muscle	1. Adductor of great toe towards the second toe 2. Maintains transverse arches of the foot
3. Flexor digiti minimi brevis	Superficial branch of lateral plantar nerve	Flexes the proximal phalanx at the metatarsophalangeal joint of the little toe

Table 10.7: Muscles of the fourth layer of the sole

Muscle	Origin from	Insertion
1. Plantar interossei (three bellies), unipennate, slender muscle bellies. Tendons pass on medial sides of third, fourth and fifth toes (Fig. 10.7)	Bases and medial sides of third, fourth and fifth metatarsals	Medial sides of bases of proximal phalanges and dorsal digital expansions of 3rd, 4th and 5th toes
2. Dorsal interossei (Fig. 10.8) (four bellies), bipennate, muscle bellies, fills up gaps between metatarsals	Adjacent sides of metatarsal bones	Bases of proximal phalanges and dorsal digital expansion of toes; first on medial side of 2nd toe; second on lateral side of 2nd toe; third on lateral side of 3rd toe and fourth on lateral side of 4th toe
3. Tibialis posterior	Posterior surfaces of leg bones	Tuberosity of navicular (see Table 9.3)
4. Peroneus longus	Upper part of lateral surface of fibula	Base of 1st metatarsal (see Table 8.3)



Table 10.8: Nerve supply and actions of muscles of the fourth layer of the sole

Muscle	Nerve supply	Actions
1. Plantar interossei (Fig. 10.7)	First and second by lateral plantar (deep branch). Third by lateral plantar (superficial branch)	Adductors of third, fourth and fifth toes toward the axis. Flexor of metatarsophalangeal and extensor of interphalangeal joints of third, fourth and fifth toes
2. Dorsal interossei (Fig. 10.8)	First, second, third by lateral plantar (deep branch), fourth dorsal interosseous by superficial branch of lateral plantar	Abductors of toes from axis of second toe. First and second cause medial and lateral abduction of second toe. Third and fourth for abduction of 3rd and 4th toes
3. Tibialis posterior	Tibial nerve	Plantar flexor of ankle (see Table 9.4)
4. Peroneus longus	Superficial peroneal nerve	Evertor of foot (see Table 8.4)

LATERAL PLANTAR ARTERY

Beginning, Course and Termination

Lateral plantar artery is the larger terminal branch of the posterior tibial artery. At the base of the fifth metatarsal bone it gives a superficial branch and then continues as the plantar arch (Figs 10.9 and 10.10).

Branches

Muscular branches supply the adjoining muscles.
Cutaneous branches supply the skin and fasciae of the lateral part of the sole.
Anastomotic branches reach the lateral border of the foot and anastomose with arteries on the dorsum of the foot.
A calcanean branch is occasionally given off to the skin of the heel.

PLANTAR ARCH

Beginning, Course and Termination

Plantar arch is formed by the direct continuation of the lateral plantar artery after it has given off the superficial

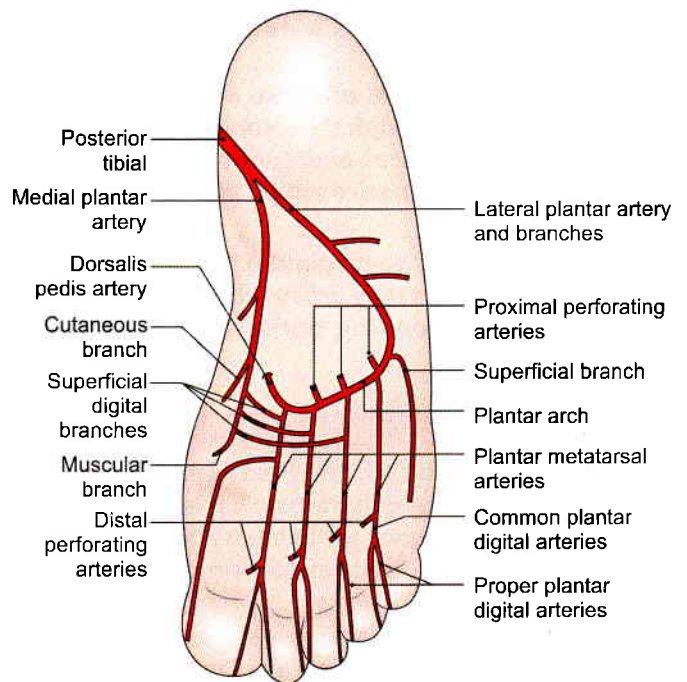


Fig. 10.9: Medial and lateral plantar arteries and their branches

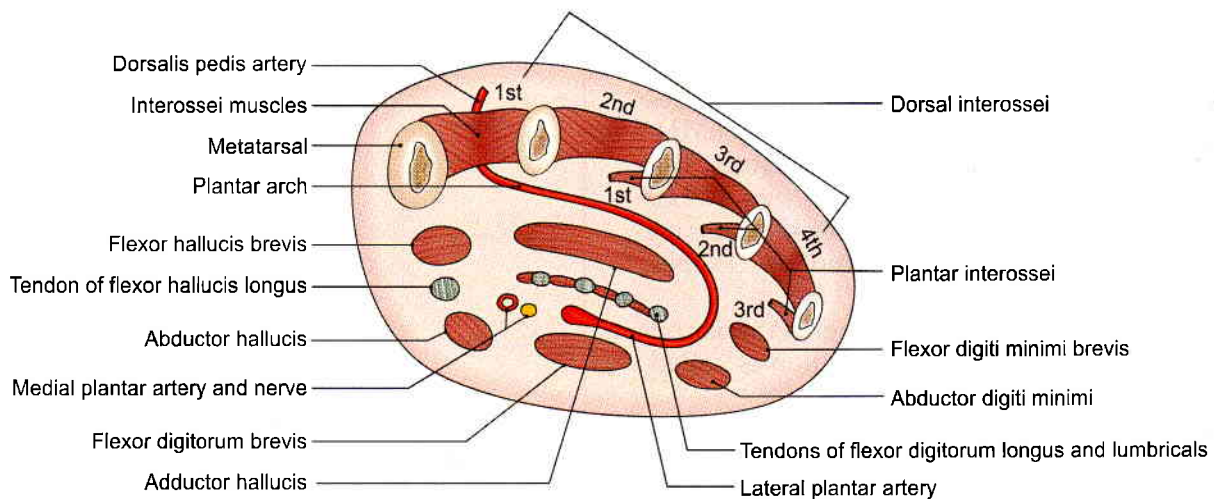


Fig. 10.10: Transverse section of the foot through the metatarsals showing the arrangement of structures in the sole



branch and is completed medially by the dorsalis pedis artery. It extends from the base of the fifth metatarsal bone to the proximal part of the first intermetatarsal space, and lies between the third and fourth layers of the sole. It is accompanied by venae comitantes. The deep branch of the lateral plantar nerve lies in the concavity of the plantar arch (Fig. 10.9 and 10.10).

Branches of the Plantar Arch

- 1 Four *plantar metatarsal* arteries run distally, one in each intermetatarsal space. Each artery ends by dividing into two *plantar digital* branches for adjacent sides of two digits. The first artery also gives off a branch to the medial side of the great toe. The lateral side of the little toe gets a direct branch from the lateral plantar artery.
- 2 The plantar arch gives off three *proximal perforating arteries* that pass through the second, third and fourth intermetatarsal spaces and communicate with the dorsal metatarsal arteries which are the branches of the arcuate artery.

The distal end of each plantar metatarsal artery gives off a *distal perforating artery* which joins the distal part of the corresponding dorsal metatarsal artery (Fig. 10.9).

CLINICAL ANATOMY

- Fracture of shaft of 2nd/3rd/4th/metatarsal bones is called "march fracture". It is seen in army personnel, policemen as they have to march a lot. It occurs due to decalcification and vascular necrosis.
- Normal architecture of foot is subjected to insults due to "high heels". Females apparently look taller, smarter but may suffer from sprains and dislocations of the ankle joint (see Fig. 9.14).
- Toes may be spread out or splayed.
- Longitudinal arches are exaggerated leading to pes cavus.
- If foot is dorsiflexed, person walks on the heel condition is called "Talipes calcaneus" (Fig. 10.11).
- If foot is plantar flexed, person walks on toes. The condition is called "Talipes equinus" (Fig. 10.12).
- If medial border of foot is raised, person walks on lateral border of foot. The condition is "Talipes varus" (Fig. 10.13).
- If lateral border of foot is raised, person walks on medial border of foot. The condition is called "Talipes valgus" (Fig. 10.14).

Most common is talipes equinovarus in which the heel is medial, the foot is plantarflexed and inverted with high medial longitudinal arch.

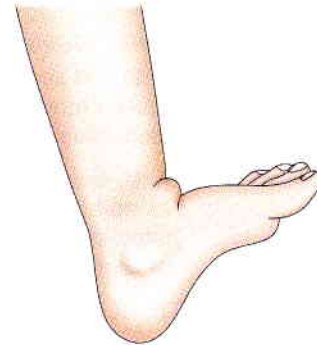

Fig. 10.11: Talipes calcaneus

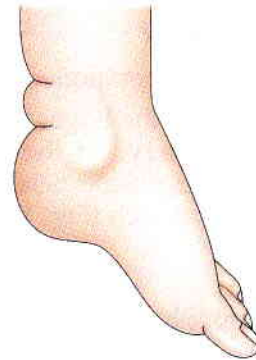


Fig. 10.12: Talipes equinus

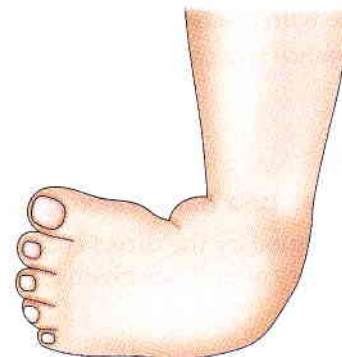

Fig. 10.13: Talipes varus

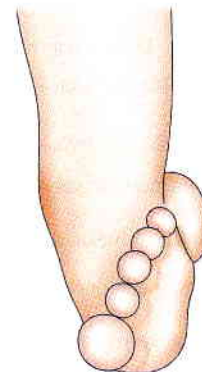

Fig. 10.14: Talipes valgus

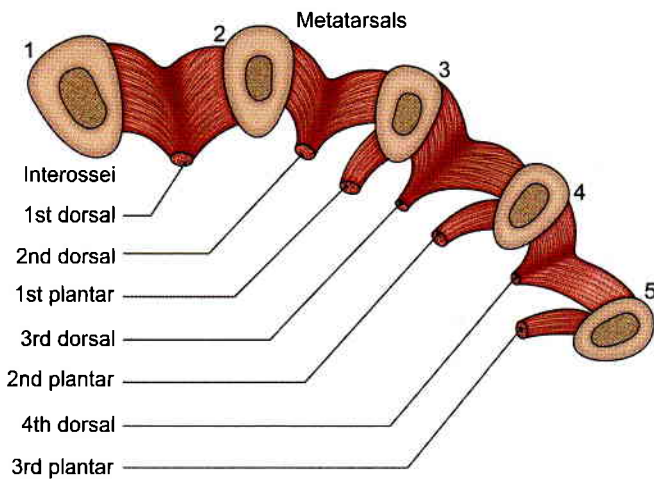


Fig. 10.15: Schematic transverse section through the metatarsal bones (1–5) to show the origins of the interossei

FACTS TO REMEMBER

- Muscles of the sole are disposed in four layers.
- Medial plantar nerve supplies 4 intrinsic muscles.
- Lateral plantar nerve supplies 14 intrinsic muscles.
- Extrinsic muscles are supplied by the nerve of the respective compartments of the leg.
- Only one arterial arch, the plantar arch is present.
- The muscles of the sole maintain the arches of the foot.

- Between 1st and 2nd layers of muscles are the trunks of medial plantar and lateral plantar nerves and vessels.
- Between the 3rd and 4th layers are the plantar arch and deep branch of lateral plantar nerve.

CLINICOANATOMICAL PROBLEM

A young female complains of severe pain along the middle of her right sole.

- What is the condition called?
- Name the branches of medial plantar nerve?

Ans: This may due to a “neuroma” in the common digital nerve between third and fourth metatarsal bones. This is a benign proliferation of the nerve fibres.

The condition is painful. The treatment is surgery.

Medial plantar nerve gives:

- Muscular branches to abductor hallucis, flexor digitorum brevis, both of 1st layer of sole; first lumbrical of 2nd layer of sole and flexor hallucis brevis of 3rd layer of sole
- The nerve gives 7 digital branches to adjacent sides of medial 3½ toes, including their nail beds and distal phalanges on the dorsum of foot
- It also gives articular branches to the joints in its territory of distribution.

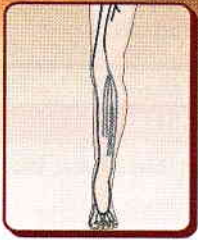
MULTIPLE CHOICE QUESTIONS

- Muscles of first layer of sole are all *except*:
 - Abductor hallucis
 - Flexor digitorum brevis
 - Abductor digiti minimi
 - Extensor digitorum brevis
- Which is not inserted into plantar aspect of foot?
 - Flexor hallucis longus
 - Peroneus longus
 - Peroneus tertius
 - Flexor digitorum longus
- In the movement of eversion of foot, all of the following muscles are involved *except*:
 - Peroneus longus
 - Peroneus brevis
 - Tibialis anterior
 - Peroneus tertius
- The bone devoid of muscular attachment:
 - Cuboid
 - Talus
 - Navicular
 - Medial cuneiform
- All muscles form second layer of sole *except*:
 - Flexor digitorum accessorius
 - Lumbricals
 - Flexor hallucis longus
 - Flexor digitorum brevis
- All of following structures pass behind medial malleolus beneath flexor retinaculum of ankle region *except*:
 - Tibialis posterior
 - Flexor digitorum longus
 - Deep peroneal nerve
 - Tibial nerve
- How many plantar interossei are present in the sole?
 - Four
 - Three
 - Two
 - Five
- Medial plantar nerve supplies all muscles *except*:
 - Abductor hallucis
 - Adductor hallucis
 - Flexor digitorum brevis
 - Flexor hallucis brevis

ANSWERS

1. d 2. c 3. c 4. b 5. d 6. c 7. b 8. b

11



Venous and Lymphatic Drainage, Segmental Innervation, and Comparison of Lower and Upper Limbs

Doctors are lucky. The sun sees their success—the earth covers their mistake

—Bushnell

INTRODUCTION

Venous drainage acquires importance as blood has to flow up against the gravity.

The saphenous veins can be “easily seen” in the leg. The varicose veins, if occur, look quite ugly under the skin. Effort should be made not to develop the varicose veins. The lymph travels mostly to the inguinal group of lymph nodes.

The sensory nerves are derived only from ventral rami of L1 to L5 and S1 to S3 segments of spinal cord.

Lower limb bud rotates medially, so that extensor compartment lies on front, while flexor compartment is present on the back of thigh. Tibia and big toe lie along the pre-axial border while fibula and little toe are along the post-axial border of the limb.

VENOUS DRAINAGE

Consideration of the venous drainage is of great importance because in the lower limb venous blood has to ascend against gravity. This is aided by a number of local factors, the failure of which gives rise to varicose veins.

Factors Helping Venous Return

General Factors

- 1 Negative intrathoracic pressure, which is made more negative during inspiration;
- 2 Arterial pressure and overflow from the capillary bed;
- 3 Compression of veins accompanying arteries by arterial pulsation; and
- 4 The presence of valves, which support and divide the long column of blood into shorter columns. These also maintain a unidirectional flow.

Local Factors

These are venous, muscular and fascial.

- 1 **Venous:** The veins of the lower limb are more muscular than the veins of any other part of the body. They have greater number of valves. Superficial veins are connected to deep veins by perforators.
- 2 **Muscular:** When the limb is active, muscular contraction compresses the deep veins and drives the blood in them upwards. It is helped by the suction action of the diaphragm
- 3 **Fascial:** The tight sleeve of deep fascia makes muscular compression of the veins much more effective by limiting outward bulging of the muscles.

VEINS OF LOWER LIMB

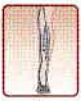The veins may be classified into three groups: superficial, deep and perforating.

Superficial Veins

They include the great and small saphenous veins, and their tributaries. They lie in the superficial fascia, on the surface of deep fascia (see Figs 3.4 and 8.1). They are thick-walled because of the presence of smooth muscle and some fibrous and elastic tissues in their walls. Valves are more numerous in the distal parts of these veins than in their proximal parts. A large proportion of their blood is drained into the deep veins through the perforating veins.

Deep Veins

These are the medial plantar, lateral plantar, dorsalis pedis, anterior and posterior tibial, peroneal, popliteal, and femoral veins, and their tributaries. They accompany the arteries, and are supported by powerful surrounding muscles. The valves are more numerous in



deep veins than in superficial veins. They are more efficient channels than the superficial veins because of the driving force of muscular contraction.

Perforating Veins

They connect the superficial with the deep veins. Their valves permit only one way flow of blood, from the superficial to the deep veins. There are about five perforators along the great saphenous vein, and one perforator along the small saphenous vein.

The relevant details of these veins are given below.

LONG SAPHENOUS VEINS

- 1 The dorsal venous arch lies on the dorsum of the foot over the proximal parts of the metatarsal bones. It receives four dorsal metatarsal veins each of which is formed by the union of two dorsal digital veins (see Fig. 8.1).
- 2 The great or long saphenous vein is formed by the union of the medial end of dorsal venous arch with the medial marginal vein which drains the medial side of great toe. It passes upwards in front of the medial malleolus, crosses the lower one-third of the medial surface of tibia obliquely, and runs along its medial border to reach the back of the knee. The saphenous nerve runs in front of the great saphenous vein.
- 3 In the thigh, it inclines forwards to reach the saphenous opening where it pierces the cribriform fascia and opens into the femoral vein. Before piercing the cribriform fascia, it receives three named tributaries corresponding to the three cutaneous arteries, and also many unnamed tributaries (Fig. 11.1).

It contains about 10 to 15 valves which prevent back flow of the venous blood, which tends to occur because of gravity. One valve is always present at the saphenofemoral junction. Incompetence of these valves makes the vein dilated and tortuous leading to varicose veins.

The vein is also connected to the deep veins of the limb by perforating veins. There are three medial perforators just above the ankle, one perforator just below the knee, and another one in the region of the adductor canal (Fig. 11.2). The perforating veins are also provided with valves which permit flow of blood only from the superficial to the deep veins. Failure of the valves also gives rise to varicose veins.

Tributaries

At the commencement: Medial marginal vein from the sole.

In the leg: It communicates freely with the small saphenous vein and with deep veins.

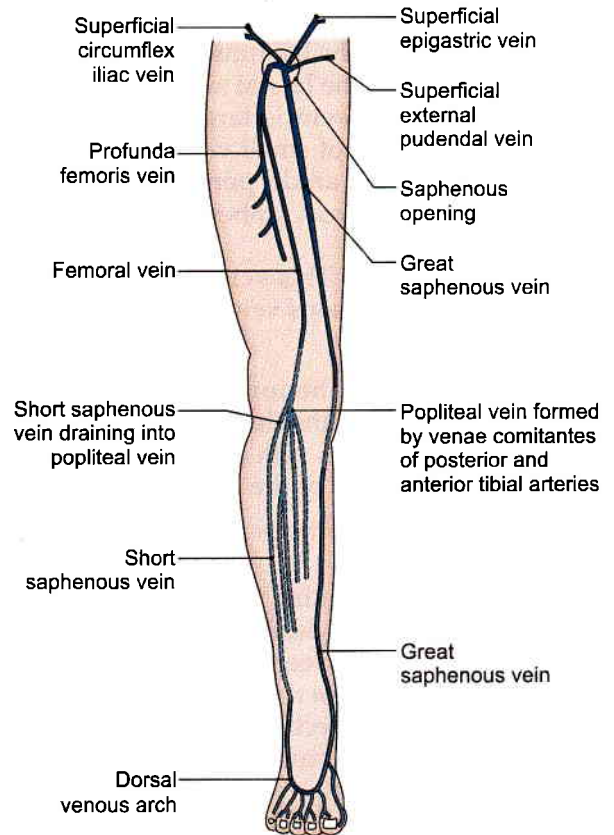


Fig. 11.1: Scheme to show the arrangement of the veins of lower limb. Popliteal, short saphenous and venae comitantes of posterior tibial artery are on posterior aspect

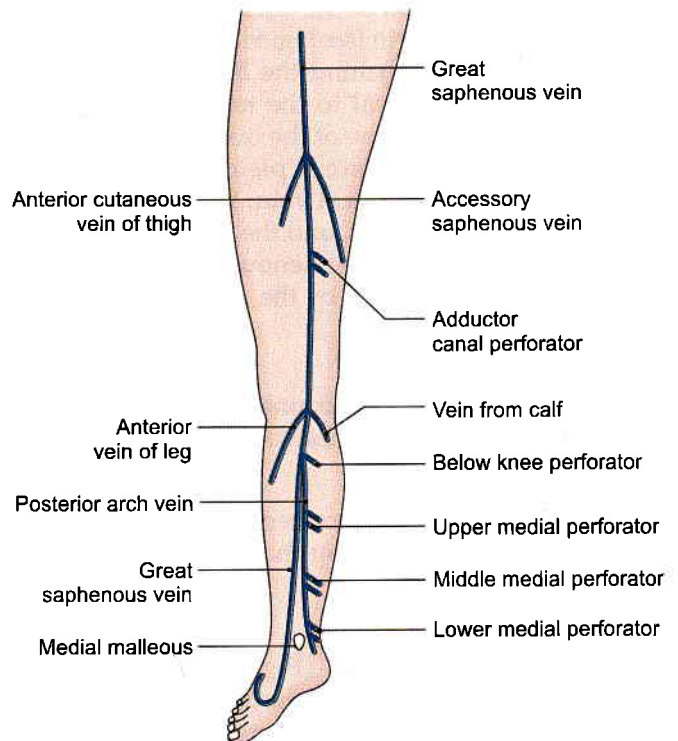


Fig. 11.2: Tributaries and perforating veins of the great saphenous vein



Just below the knee:

- 1 The anterior vein of the leg runs upwards, forwards and medially, from the lateral side of the ankle.
- 2 The posterior arch vein is large and constant. It begins from a series of small venous arches which connect the medial ankle perforators, and runs upwards to join the great saphenous vein just below the knee.
- 3 A vein from the calf: This vein also communicates with the small saphenous vein.

In the thigh:

- 1 The accessory saphenous vein drains the posteromedial side of the thigh.
- 2 The anterior cutaneous vein of the thigh drains the lower part of the front of the thigh.

Just before piercing the cribriform fascia:

- 1 Superficial epigastric,
- 2 Superficial circumflex iliac, and
- 3 Superficial external pudendal.

Just before termination: Deep external pudendal vein.

The *thoracoepigastric vein* runs along the anterolateral wall of the trunk. It connects the superficial epigastric vein with the lateral thoracic vein. Thus it is an important connection between the veins of the upper and lower limbs.

SMALL OR SHORT SAPHENOUS VEIN

The vein is formed on the dorsum of the foot by the union of the lateral end of the dorsal venous arch with the lateral marginal vein (see Fig. 9.1). It enters the back of the leg by passing behind the lateral malleolus. In the leg, it ascends lateral to the tendocalcaneus, and then along the middle line of the calf, to the lower part of the popliteal fossa. Here it pierces the deep fascia and opens into the popliteal vein. It drains the lateral border of the foot, the heel, and the back of the leg. It is connected with the great saphenous and with the deep veins, and is accompanied by the sural nerve.

PERFORATING VEINS

As already mentioned, they connect the superficial with the deep veins (Fig. 11.2). These are classified as follows.

Indirect perforating veins

Indirect perforating veins connect the superficial veins with the deep veins through the muscular veins (Fig. 11.3).

Direct perforating veins

Direct perforating veins (Fig. 11.4) connect the superficial veins directly with the deep veins. The great and small saphenous veins are the large direct perforators. The small direct perforating veins (Fig. 11.5) are follows:

- 1 *In the thigh:* The *adductor canal perforator* connects the great saphenous vein with the femoral vein in the lower part of the adductor canal.

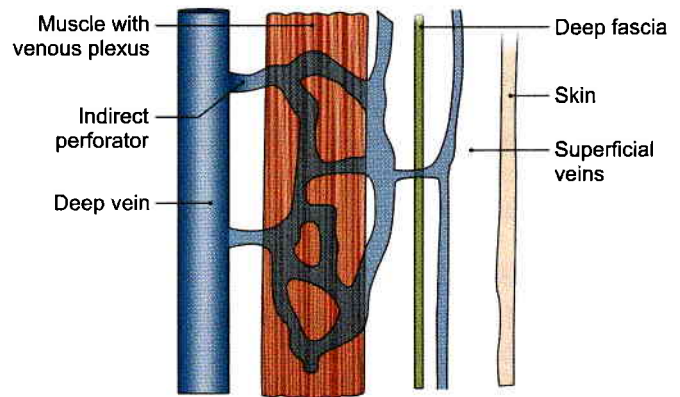


Fig. 11.3: Indirect perforating vein

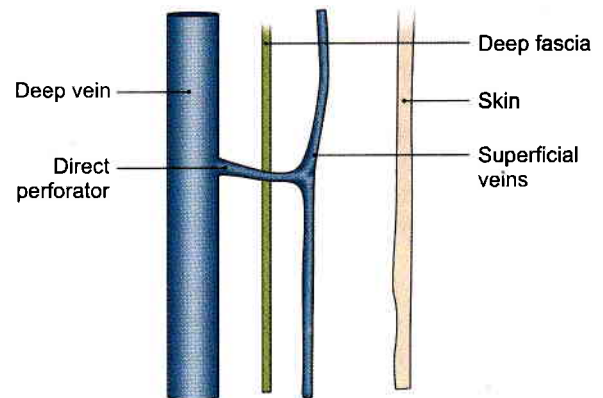


Fig. 11.4: Direct perforating vein

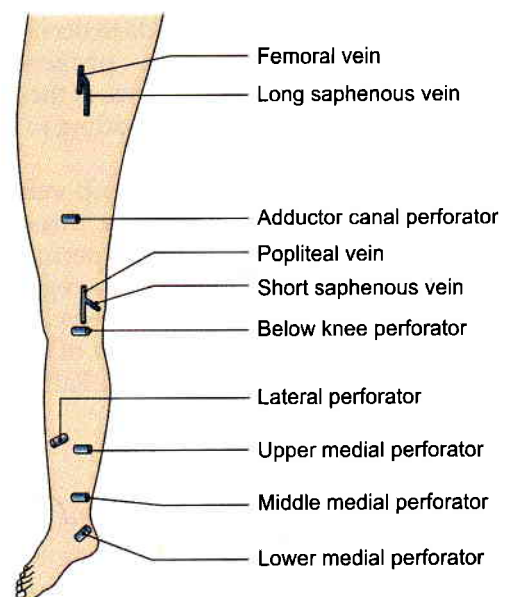


Fig. 11.5: Perforating veins of the lower limb



2 *Below the knee:*

One perforator connects the great saphenous vein or the posterior arch vein with the posterior tibial vein.

3 *In the leg:*

A *lateral perforator* is present at the junction of the middle and lower thirds of the leg. It connects the small saphenous vein, or one of its tributaries with the peroneal vein.

Medially there are three perforators which connect the posterior arch vein with the posterior tibial vein.

- The *upper medial perforator* lies at the junction of the middle and lower thirds of the leg.
- The *middle medial perforator* lies above the medial malleolus.
- The *lower medial perforator* lies posteroinferior to the medial malleolus.

CLINICAL ANATOMY

• *Calf pump and peripheral heart.* In the upright position of the body, the venous return from the lower limb depends largely on the contraction of calf muscles. These muscles are, therefore, known as the “calf pump”.

For the same reason the soleus is called the *peripheral heart* (see Fig. 9.3). When this muscle contracts, blood contained in large sinuses within it is pumped into the deep veins; and when the muscle relaxes, blood flows into the sinuses from the superficial veins. Unidirectional blood flow is maintained by the valves in the perforating veins (Fig. 11.6).

- “Cut open procedure”/venesection is done on the great saphenous vein as it lies in front of medial malleolus. This vein is used for transfusion of blood/fluids in case of non-availability or collapse of other veins. Saphenous nerve is identified and not injured as it lies anterior to the great saphenous vein (Fig. 11.7).
- Great saphenous vein is used for bypassing the blocked coronary arteries. The vein is reversed so that valves do not block the passage of blood.
- *Varicose veins and ulcers:* If the valves in perforating veins or at the termination of superficial veins become incompetent, the defective veins become “high pressure leaks” through which the high pressure of the deep veins produced by muscular contraction is transmitted to the superficial veins. This results in dilatation of the superficial veins and to gradual degeneration of their walls producing varicose veins and varicose ulcers (Fig. 11.8).

- Varicose veins often occur during third trimester of pregnancy, as the iliac vein get pressed due to enlarged uterus. These mostly subside after delivery.
- *Trendelenburg’s test:* This is done to find out the site of leak or defect in a patient with varicose veins. Only the superficial veins and the perforating veins can be tested, not the deep veins.
- The patient is made to lie down, and the veins are emptied by raising the limb and stroking the varicose veins in a proximal direction. Now pressure is applied with the thumb at the saphenofemoral junction and the patient is asked to stand up quickly. To test the superficial veins, the pressure is released. Quick filling of the varicose veins from above indicates incompetency of the superficial veins.

To test the perforating veins, the pressure at the saphenofemoral junction is not released, but maintained for about a minute. Gradual filling of the varices indicates incompetency of the perforating veins, allowing the blood to pass from deep to superficial veins.

- After a deep vein thrombosis affecting the perforators, they recanalise without valves. So the muscle pump will force blood from deep to superficial veins, causing varicosity of the veins.
- Varicose veins are treated with sclerosing injections or laser treatment.

Comparison between long saphenous and short saphenous veins is as follows.

Features	Long saphenous vein	Short saphenous vein
Beginning	Medial end of dorsal venous plexus	Lateral end of dorsal venous plexus
Position	Anterior to medial malleolus	Posterior to lateral malleolus
Number of valves	15–20 valves	8–10 valves
Relation of a sensory nerve	Saphenous nerve	Sural nerve
Termination	Femoral vein	Popliteal vein

LYMPHATIC DRAINAGE

Most of the lymph from the lower limb drains into the inguinal lymph nodes, either mostly directly or partly indirectly through the popliteal and anterior tibial nodes. The deep structures of the gluteal region and the upper part of the back of the thigh drain into the internal iliac nodes along the gluteal vessels.

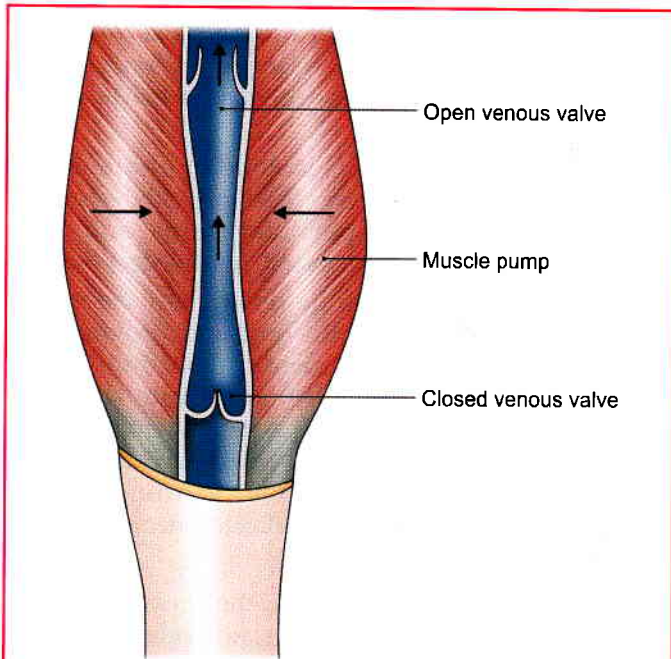


Fig. 11.6: Venous valves for unidirectional flow of blood

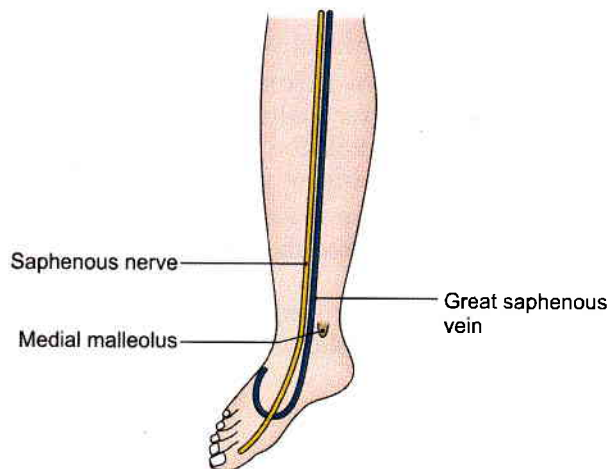


Fig. 11.7: Cut open vein section procedure on great saphenous vein

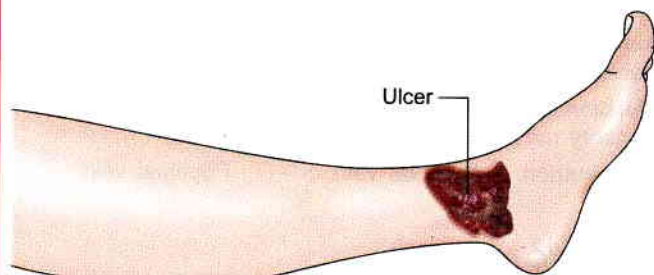

Fig. 11.8: Varicose ulcer

Classification

- I. Lymph nodes
 - a. Superficial inguinal lymph nodes.

- b. Deep:
 - Deep inguinal lymph nodes
 - Popliteal lymph nodes
 - Anterior tibial lymph nodes.

- II. Lymphatics:
 - a. Superficial, and
 - b. Deep.

Superficial Inguinal Lymph Nodes

These are very important because they drain the skin and fasciae of the lower limb; the perineum and the trunk below the umbilical plane (see Fig. 3.5). They are divided into three sets.

- 1 The *lower vertical group* is placed along both sides of the terminal part of the great saphenous vein, and contains about four or five nodes. They drain the skin and fasciae of the lower limb (great saphenous territory), except the buttock and the short saphenous territory. A few lymphatics, accompanying the short saphenous vein, cross the leg, accompany the great saphenous vein, and drain into this group of nodes.
- 2 The *upper lateral group* is placed below the lateral part of the inguinal ligament, and contains about two or three nodes. They drain the skin and fasciae of the upper part of the lateral side of the thigh, the buttock, the flank and the back below the umbilical plane.
- 3 The *upper medial group* is placed below the medial end of the inguinal ligament. One or two nodes may lie above the inguinal ligament along the course of the superficial epigastric vessels. The group contains two to three nodes. They drain:
 - a. The anterior abdominal wall below the level of the umbilicus.
 - b. The perineum, including external genitalia, except the glans, the anal canal below the pectinate line, the vagina below hymen and the penile part of the male urethra.
 - c. The superolateral angle of the uterus, via the round ligament.

Efferents from all superficial inguinal nodes pierce the cribriform fascia, and terminate in the deep inguinal nodes. A few may pass directly to the external iliac nodes.

Deep Inguinal Lymph Nodes

These are about four to five in number, and lie medial to the upper part of the femoral vein. The most proximal node of this group; gland of Cloquet or of Rosenmüller, lies in the femoral canal. These nodes receive afferents from:

- 1 The superficial inguinal nodes.
- 2 The popliteal nodes.
- 3 Glans penis or clitoris.
- 4 The deep lymphatics of the lower limb accompanying the femoral vessels.

Their efferents pass to the external iliac nodes.



Popliteal Lymph Nodes

These nodes lie near the termination of the small saphenous vein, deep to the deep fascia. One node lies between the popliteal artery and the oblique popliteal ligament. They receive afferents from:

- 1 The territory of the small saphenous vein.
- 2 The deep parts of the leg (through vessels running along the anterior and posterior tibial vessels).
- 3 The knee joint.

Their efferents run along the popliteal and femoral vessels, and terminate in the deep inguinal nodes.

Anterior Tibial Lymph Node

One inconstant node may lie along the upper part of the anterior tibial artery. When present, it collects lymph from the anterior compartment of the leg, and passes it on to the popliteal nodes.

Superficial Lymphatics

These lymph vessels are larger and are more numerous than the deep lymphatics. They run in the superficial fascia and ultimately form two streams. The main stream follows the great saphenous vein, and ends in the lower vertical group of superficial inguinal lymph

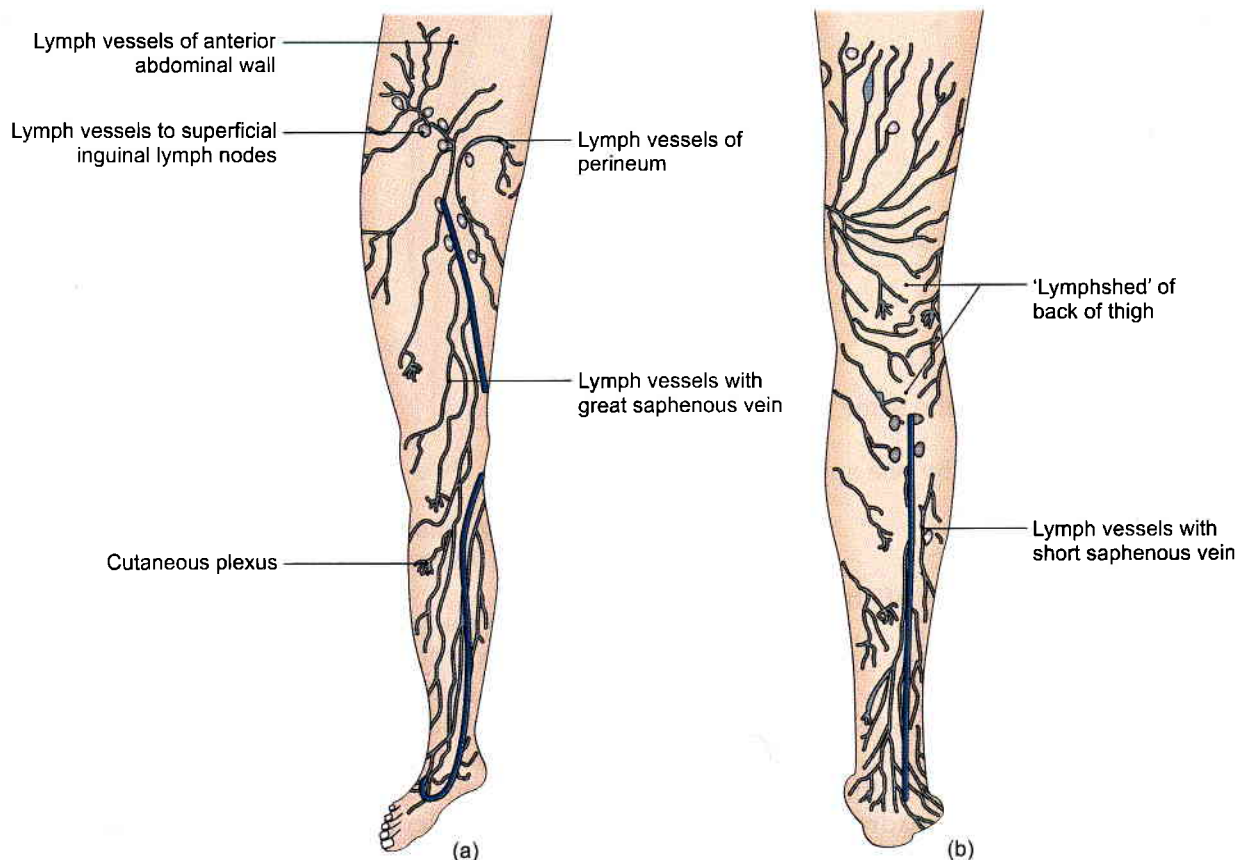
nodes shown in (Fig. 11.9a). The accessory stream follows the small saphenous vein and ends in the popliteal lymph nodes (Fig. 11.9b).

Deep Lymphatics

These are smaller and fewer than the superficial lymphatics, although they drain all structures lying deep to the deep fascia. They run along the principal blood vessels, and terminate mostly into the deep inguinal nodes, either directly or indirectly through the popliteal nodes. The deep lymphatics from the gluteal region and from the upper part of the back of the thigh accompany the gluteal vessels and end in the internal iliac nodes.

CLINICAL ANATOMY

- *Elephantiasis*: Lymphatic obstruction caused by the parasite filaria is very common in the lower limb. This results in great hypertrophy of the skin and of subcutaneous tissue (elephantiasis) (Fig. 11.10).
- The commonest cause of a swelling in the inguinal area is enlargement of the inguinal lymph nodes. This can be caused by infection, or carcinoma, anywhere in the area drained by these nodes (Fig. 11.11).



Figs 11.9a and b: Superficial lymphatics of the lower limb: (a) Anterior aspect, and (b) posterior aspect

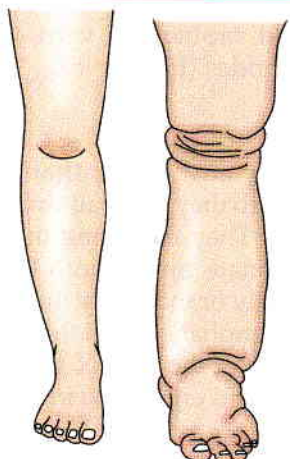


Fig. 11.10: Elephantiasis due to filariasis

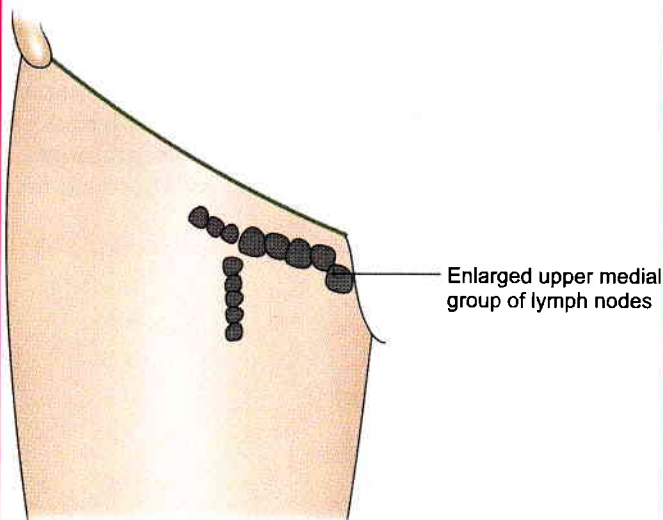


Fig. 11.11: Lymphadenitis due to infection in the perineum

SEGMENTAL INNERVATION

Dermatomes

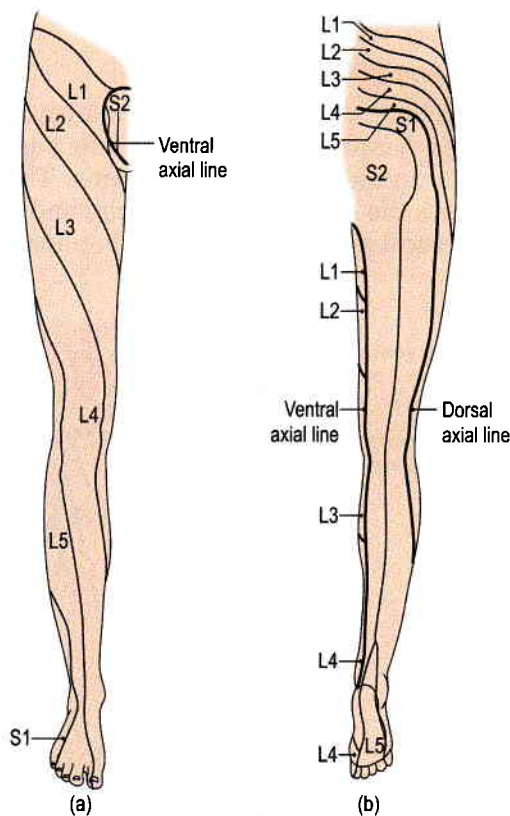
The principles involved are the same as described in the upper limb.

The area of skin supplied by one spinal segment is called a dermatome.

Important Features

- The cutaneous innervation of the lower limb is derived:
 - Mainly from segments L1 to L5 and S1 to S3 of the spinal cord; and
 - Partly from segments T12 and S4.
- As a rule, the limb is supplied only by anterior primary rami. The exception to this rule is that the skin of the superomedial quadrant of the gluteal region is supplied by the posterior primary rami of nerves L1 to L3 and S1 to S3.

- There is varying degree of overlap of adjoining dermatomes, so that the area of sensory loss following damage to the spinal cord or nerve roots is always less than the actual area of the dermatome.
- Initially, each limb bud has a cephalic border, and a caudal border. These are known as the *preaxial* and the *postaxial* borders, respectively. In the embryo, the great toe and tibia lie along the preaxial border, and the little toe and fibula along the postaxial border. Later, the limb bud rotates medially through 90°, so that the great toe and tibia are carried medially, and the little toe and fibula laterally. Thus, the tibial border is the original preaxial border, and the fibular border, the postaxial border, of the lower limb.
- The dermatomes of the lower limb are distributed in an orderly numerical sequence (Figs 11.12a and b).



Figs 11.12a and b: Dermatomes of the lower limb: (a) Anterior view, and (b) posterior view

Along the preaxial border from above downwards, there are dermatomes T12, L1 to L4.

The middle three toes, the adjoining area of the dorsum of the foot and the lateral side of the leg are supplied by segment L5.

Along the postaxial border from below upwards, there are dermatomes S1, S2, S3.

- As the limb elongates, the central dermatomes (L4, L5, S1) get pulled in such a way that these are



represented only in the distal part of the limb, and are buried proximally. The line along which the central dermatomes are buried is known as the *axial line*. In fact, an axial line is defined as a line along which certain dermatomes are buried (missing) so that distant dermatomes adjoin each other. Overlapping of the dermatomes is minimal across the axial line. There are *two axial lines*, one ventral and one dorsal, both of which extend largely on the back of the limb. On the posterior surface of the limb, the *ventral axial line* extends up to the heel, whereas the *dorsal axial line* ends at a higher level, at the junction of the upper two-thirds and lower one-third of the leg. On the anterior surface of the limb, the ventral axial line crosses the scrotum, and the dorsal axial line encroaches on the lateral side of the knee. Some workers deny the existence of the dorsal axial line.

Myotomes

A spinal nerve supplies muscles that are derived from one myotome. Most of the muscles are supplied by more than one segment of the spinal cord, the supply by some segments being predominant. Damage of the predominant segments results in maximum paralysis of the muscle. The chart given below is accurate enough for use in clinical examination.

- L1 Psoas major.
- L2 Psoas major, iliacus, sartorius, gracilis, pectineus, adductor longus, adductor brevis.
- L3 Quadriceps, adductors (longus, brevis, magnus).
- L4 Quadriceps, tensor fasciae latae, adductor magnus, obturator externus, tibialis anterior, tibialis posterior.
- L5 Gluteus medius, gluteus minimus, obturator internus, semimembranosus, semitendinosus, extensor hallucis longus, extensor digitorum longus, peroneus tertius, popliteus.
- S1 Gluteus maximus, obturator internus, piriformis, biceps femoris, semitendinosus, popliteus, gastrocnemius, soleus, peronei, extensor digitorum brevis.
- S2 Piriformis, biceps femoris, gastrocnemius, soleus, flexor digitorum longus, flexor hallucis longus, intrinsic muscles of foot.
- S3 Intrinsic muscles of foot (except abductor hallucis, flexor hallucis brevis, flexor digitorum brevis, extensor digitorum brevis).

Joint Movements

The segmental innervation of muscles can also be expressed in terms of movements of joints (Fig. 11.13).

Hip	Flexors, adductors and medial rotators	... L1, L2, L3
	Extensors, abductors and lateral rotators	... L5, S1

Knee	Extensors	... L3, L4
	Flexors	... L5, S1
Ankle	Dorsiflexors	... L4, L5
	Plantar flexors	... S1, S2
Foot	Invertors	... L4, L5
	Evertors	... L5, S1

CLINICAL ANATOMY

Like dermatomes, the myotomes are also helpful in determination of the level of a lesion in the spinal cord.

SYMPATHETIC INNERVATION

- 1 Sympathetic innervation of the lower limb is derived from the lower three thoracic and upper two lumbar (T10 to L2) segments of the spinal cord. The fibres arise from the lateral horn cells, and pass out with the ventral roots as preganglionic (white rami) fibres. These pass down the sympathetic chain to relay in the lumbar and upper two or three sacral ganglia.
- 2 The postganglionic fibres emerge from the lumbar sympathetic ganglia and pass through grey rami to reach the lumbar nerves. From these nerves they pass into the femoral nerve. They supply the femoral artery and its branches in the thigh. Some postganglionic sympathetic fibres emerge from the upper two or three sacral ganglia. They travel through the tibial nerve to supply the popliteal artery and its branches in the leg and foot.
- 3 The blood vessels to skeletal muscles are dilated by sympathetic activity. These nerves are vasomotor, sudomotor and pilomotor to the skin.
- 4 Sympathetic denervation of the lower limb can be produced by removing the second, third and fourth lumbar ganglia with the intermediate chain. This divides all preganglionic fibres to the lower limb. The first lumbar ganglion is preserved because it controls the proximal urethral sphincter mechanism. Its removal is followed by dry coitus. Bilateral lumbar sympathectomy is done in patients with Buerger's disease.

Mnemonics

Great saphenous vein

M, m, m, m, m, m

M—Medial end of dorsal venous arch

m—medial marginal vein ends into it

m—lies anterior to the medial malleolus

m—crosses medial surface of tibia obliquely

m—runs behind medial border of tibia to reach behind the knee

m—runs along medial side of thigh to end in the saphenous opening



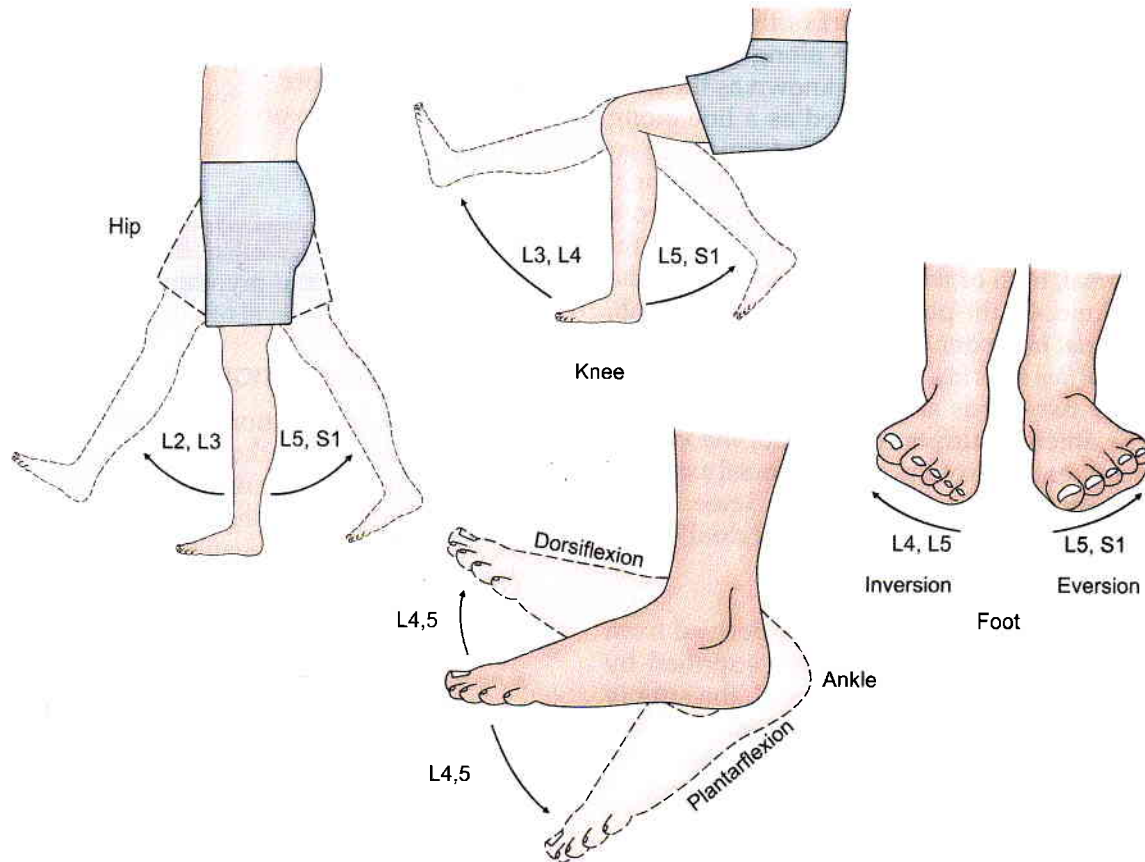


Fig. 11.13: Segmental innervation of the joints

COMPARISON OF LOWER AND UPPER LIMBS

	Lower limb	Upper limb
General	<p>Lower limb with long and heavy bones supports and stabilises the body</p> <p>Lower limb bud rotates medially, so that big toe points medially. Nerve supply: Ventral rami of lumbar 2–5 and sacral 1–3 segments of spinal cord. Sciatic and one of its terminal branch the tibial nerve supplies the flexor aspect of the limb. The other terminal branch of sciatic nerve, i.e. common peroneal, supplies the extensors of ankle joint (dorsiflexors) through its deep peroneal branch. Its superficial branch supplies the peroneal muscles of the leg. Femoral supplies the quadriceps femoris (extensor of knee) while obturator nerve supplies the adductors</p>	<p>The upper limb is for range and variety of movements. Thumb assisted by palm and fingers has the power of holding articles</p> <p>Upper limb bud rotates laterally, so that the thumb points laterally. Nerve supply: Ventral rami of cervical 5–8 and thoracic 1 segments of spinal cord. Musculocutaneous, median and ulnar nerves supply the flexor aspects of the limb, while the radial nerve supplies the triceps brachii (extensor of elbow) and its branch the posterior interosseous supplies the extensors of wrist</p>
	<i>Thigh</i>	<i>Arm</i>
Bones	Femur is the longest bone of lower limb and of the body	Humerus is the longest bone of upper limb
Joints	Hip joint is a multiaxial joint	Shoulder joint is also multiaxial joint
Muscles	<p>Posteriorly: Hamstrings supplied by sciatic</p> <p>Anteriorly: Quadriceps by femoral</p> <p>Medially: Adductors by obturator nerve</p>	<p>Anteriorly: Biceps, brachialis and coracobrachialis supplied by musculocutaneous nerve</p> <p>Posteriorly: Triceps brachii supplied by radial nerve</p>

(Contd...)



(Contd...)

Nerves	Sciatic for posterior compartment of thigh, femoral for anterior compartment of thigh, obturator for adductor muscles of medial compartment of thigh	Musculocutaneous	for anterior compartment of arm Radial for posterior compartment. Coracobrachialis equivalent to medial compartment of arm also supplied by musculocutaneous nerve
Branches	Muscular, cutaneous, articular/genicular, vascular and terminal branches	Muscular, cutaneous, articular/genicular, vascular and terminal branches	
Arteries	Femoral, popliteal and profunda femoris (deep)	Axillary, brachial, profunda (deep) brachii	

Leg

Forearm

Bones	Tibia: Preaxial bone Fibula: Postaxial bone	Radius: Preaxial bone Ulna: Postaxial bone
Joints	Knee joint formed by femur, tibia and patella. Fibula does not participate in knee joint. An additional bone (sesamoid) patella makes its appearance. This is an important weight-bearing joint	Elbow joint formed by humerus, radius and ulna, communicates with superior radioulnar joint. Forearm is characterised by superior and inferior radioulnar joints. These are both pivot variety of synovial joints permitting rotatory movements of pronation and supination, e.g. meant for picking up food and putting it in the mouth
Muscles	Plantaris Flexor digitorum longus Flexor hallucis longus Soleus and flexor digitorum brevis Gastrocnemius (medial head) Gastrocnemius (lateral head) Tibialis anterior Extensor digitorum longus Extensor hallucis longus	Palmaris longus Flexor digitorum profundus Flexor pollicis longus Flexor digitorum superficialis Flexor carpi ulnaris Flexor carpi radialis Abductor pollicis longus Extensor digitorum Extensor pollicis longus

Lower limb

Upper limb

Compartment-ments	Anterior aspect: Dorsiflexors of ankle joint Posterior aspect: Plantar flexors (flexors) of ankle joint Lateral aspect: Evertors of subtalar joint	Anterior aspect: Flexors of wrist and pronators of forearm Posterior aspect: Extensors of wrist, and supinator
Nerves	Tibial nerve for all the plantar flexors of the ankle joint. Common peroneal winds around neck of fibula (postaxial bone) and divides into superficial and deep branches. The deep peroneal supplies dorsiflexors (extensors) of the ankle joint. The superficial peroneal nerve supplies a separate lateral compartment of leg	Median nerve for 6½ muscles and ulnar nerve for 1½ muscles of anterior aspect of forearm. These are flexors of wrist and pronators of forearm. Posterior interosseous nerve or deep branch of radial supplies the extensors of the wrist and the supinator muscle of forearm. It winds around radius (preaxial bone) and corresponds to deep peroneal nerve. The superficial branch of radial nerve corresponds to the superficial peroneal nerve
Arteries	Popliteal divides into anterior tibial and posterior tibial in the popliteal fossa. Posterior tibial corresponds to ulnar artery	Brachial divides into radial and ulnar branches in the cubital fossa. Radial corresponds to anterior tibial artery

Foot

Hand

Bones and joints	7 big tarsal bones occupying half of the foot. There are special joints between talus, calcaneus and navicular, i.e. subtalar and talocalcaneonavicular joints. They permit the movements of inversion and eversion (raising the medial border/lateral border of the foot) for walking on the uneven surfaces. This movement of inversion is similar to supination and of eversion to pronation of forearm. Flexor digitorum accessorius is a distinct muscle	There are 8 small carpal bones occupying very small area of the hand. First carpometacarpal joint, i.e. joint between trapezium and base of 1st metacarpal is a unique joint. It is of saddle variety and permits a versatile movement of opposition in addition to other movements. This permits the hand to hold things, e.g. doll, pencil, food, bat, etc. Opponens pollicis is specially for opposition
-------------------------	---	--

(Contd...)



(Contd...)

to straighten the action of flexor digitorum longus tendons in line with the toes on which these act. Tibialis anterior, tibialis posterior and peroneus longus reach the foot and sole for the movements of inversion (first two) and eversion (last one) respectively

Nerves Medial plantar supplies four muscles of the sole including 1st lumbrical (abductor hallucis, flexor hallucis brevis, flexor digitorum brevis, 1st lumbrical)

Lateral plantar corresponds to ulnar nerve and supplies 14 intrinsic muscles of the sole

Muscles Muscles which enter the sole from the leg, e.g. flexor digitorum longus, flexor hallucis longus, tibialis posterior, peroneus longus are supplied by the nerves of the leg. 1st lumbrical is unipennate and is supplied by medial plantar, 2nd–4th are bipennate being supplied by deep branch of lateral plantar nerve

Extensor digitorum brevis present on dorsum of foot

Blood vessels Posterior tibial artery divides into medial plantar and lateral plantar branches. There is only one arch, the plantar arch formed by lateral plantar and dorsalis pedis (continuation of anterior tibial) arteries

The great sphenous vein with perforators lies along the preaxial border. The short saphenous vein, lies along the postaxial border but it terminates in the popliteal fossa

Axis The axis of movement of adduction and abduction passes through the 2nd digit. So 2nd toe possesses two dorsal interossei muscles

Median nerve supplies 5 muscles of hand including 1st and 2nd lumbricals (abductor pollicis brevis, flexor pollicis brevis, opponens pollicis, 1st and 2nd lumbricals)

Ulnar nerve corresponds to lateral plantar nerve and supplies 15 intrinsic muscles of the hand

Muscles which enter the palm from forearm, e.g. flexor digitorum superficialis, flexor digitorum profundus, flexor pollicis longus are supplied by the nerves of the forearm. 1st and 2nd lumbricals are unipennate and are supplied by median nerve. 3rd and 4th are bipennate being supplied by deep branch of ulnar nerve

No muscle on dorsum of hand

Radial artery corresponds to anterior tibial while ulnar artery corresponds to posterior tibial artery. Ulnar artery divides into superficial and deep branches. There are two palmar arches, superficial and deep. The superficial arch mainly is formed by ulnar artery and deep arch is formed mainly by the radial artery. Cephalic vein is along the preaxial border. Basilic vein runs along the postaxial border of the limb and terminates in the middle of the arm

The axis of movement of adduction and abduction is through the third digit or middle finger. So the middle finger has two dorsal interossei muscles

	Sole	Palm
<i>I Layer</i>	Abductor hallucis brevis Flexor digitorum brevis Abductor digiti minimi	Abductor pollicis brevis Flexor pollicis brevis Flexor digiti minimi Abductor digiti minimi
<i>Between I and II layers</i>	Superficial plantar arch is not present Branches of medial plantar nerve and artery Branches of superficial branch of lateral plantar nerve	Superficial palmar arch Branches of median nerve Branches of superficial branch of ulnar nerve
<i>II Layer</i>	Tendon of flexor digitorum longus, lumbricals and flexor digitorum accessorius Tendon of flexor hallucis longus	Tendons of flexor digitorum superficialis Tendons of flexor digitorum profundus and lumbricals Tendon of flexor pollicis longus
<i>III Layer</i>	Flexor hallucis brevis Adductor hallucis Flexor digiti minimi brevis	Opponens pollicis Adductor pollicis Opponens digiti minimi
<i>Between III and IV layers</i>	Plantar arch with deep branch of lateral plantar nerve	Deep palmar arch and deep branch of ulnar nerve
<i>IV Layer</i>	1–3 plantar interossei 1–4 dorsal interossei Tendons of tibialis posterior and peroneus longus	1–4 palmar interossei 1–4 dorsal interossei



(Contd...)

Nerves Sciatic for posterior compartment of thigh, femoral for anterior compartment of thigh, obturator for adductor muscles of medial compartment of thigh

Branches Muscular, cutaneous, articular/genicular, vascular and terminal branches

Arteries Femoral, popliteal and profunda femoris (deep)

Musculocutaneous for anterior compartment of arm
 Radial for posterior compartment. Coracobrachialis equivalent to medial compartment of arm also supplied by musculocutaneous nerve

Muscular, cutaneous, articular/genicular, vascular and terminal branches

Axillary, brachial, profunda (deep) brachii

Leg

Bones Tibia: Preaxial bone
 Fibula: Postaxial bone

Joints Knee joint formed by femur, tibia and patella. Fibula does not participate in knee joint. An additional bone (sesamoid) patella makes its appearance. This is an important weight-bearing joint

Muscles Plantaris
 Flexor digitorum longus
 Flexor hallucis longus
 Soleus and flexor digitorum brevis
 Gastrocnemius (medial head)
 Gastrocnemius (lateral head)
 Tibialis anterior
 Extensor digitorum longus
 Extensor hallucis longus

Forearm

Radius: Preaxial bone
 Ulna: Postaxial bone

Elbow joint formed by humerus, radius and ulna, communicates with superior radioulnar joint. Forearm is characterised by superior and inferior radioulnar joints. These are both pivot variety of synovial joints permitting rotatory movements of pronation and supination, e.g. meant for picking up food and putting it in the mouth

Palmaris longus
 Flexor digitorum profundus
 Flexor pollicis longus
 Flexor digitorum superficialis
 Flexor carpi ulnaris
 Flexor carpi radialis
 Abductor pollicis longus
 Extensor digitorum
 Extensor pollicis longus

Lower limb

Compartment-ments Anterior aspect: Dorsiflexors of ankle joint
 Posterior aspect: Plantar flexors (flexors) of ankle joint
 Lateral aspect: Evertors of subtalar joint

Nerves Tibial nerve for all the plantar flexors of the ankle joint. Common peroneal winds around neck of fibula (postaxial bone) and divides into superficial and deep branches. The deep peroneal supplies dorsiflexors (extensors) of the ankle joint. The superficial peroneal nerve supplies a separate lateral compartment of leg

Arteries Popliteal divides into anterior tibial and posterior tibial in the popliteal fossa. Posterior tibial corresponds to ulnar artery

Upper limb

Anterior aspect: Flexors of wrist and pronators of forearm
 Posterior aspect: Extensors of wrist, and supinator

Median nerve for 6½ muscles and ulnar nerve for 1½ muscles of anterior aspect of forearm. These are flexors of wrist and pronators of forearm. Posterior interosseous nerve or deep branch of radial supplies the extensors of the wrist and the supinator muscle of forearm. It winds around radius (preaxial bone) and corresponds to deep peroneal nerve. The superficial branch of radial nerve corresponds to the superficial peroneal nerve

Brachial divides into radial and ulnar branches in the cubital fossa. Radial corresponds to anterior tibial artery

Foot

Bones and joints 7 big tarsal bones occupying half of the foot. There are special joints between talus, calcaneus and navicular, i.e. subtalar and talocalcaneonavicular joints. They permit the movements of inversion and eversion (raising the medial border/lateral border of the foot) for walking on the uneven surfaces. This movement of inversion is similar to supination and of eversion to pronation of forearm. Flexor digitorum accessorius is a distinct muscle

Hand

There are 8 small carpal bones occupying very small area of the hand. First carpometacarpal joint, i.e. joint between trapezium and base of 1st metacarpal is a unique joint. It is of saddle variety and permits a versatile movement of opposition in addition to other movements. This permits the hand to hold things, e.g. doll, pencil, food, bat, etc. Opponens pollicis is specially for opposition

(Contd...)



(Contd...)

to straighten the action of flexor digitorum longus tendons in line with the toes on which these act. Tibialis anterior, tibialis posterior and peroneus longus reach the foot and sole for the movements of inversion (first two) and eversion (last one) respectively

Nerves Medial plantar supplies four muscles of the sole including 1st lumbrical (abductor hallucis, flexor hallucis brevis, flexor digitorum brevis, 1st lumbrical)
Lateral plantar corresponds to ulnar nerve and supplies 14 intrinsic muscles of the sole

Muscles Muscles which enter the sole from the leg, e.g. flexor digitorum longus, flexor hallucis longus, tibialis posterior, peroneus longus are supplied by the nerves of the leg. 1st lumbrical is unipennate and is supplied by medial plantar, 2nd–4th are bipennate being supplied by deep branch of lateral plantar nerve
Extensor digitorum brevis present on dorsum of foot

Blood vessels Posterior tibial artery divides into medial plantar and lateral plantar branches. There is only one arch, the plantar arch formed by lateral plantar and dorsalis pedis (continuation of anterior tibial) arteries
The great sphenous vein with perforators lies along the preaxial border. The short saphenous vein, lies along the postaxial border but it terminates in the popliteal fossa

Axis The axis of movement of adduction and abduction passes through the 2nd digit. So 2nd toe possesses two dorsal interossei muscles

Median nerve supplies 5 muscles of hand including 1st and 2nd lumbricals (abductor pollicis brevis, flexor pollicis brevis, opponens pollicis, 1st and 2nd lumbricals)
Ulnar nerve corresponds to lateral plantar nerve and supplies 15 intrinsic muscles of the hand

Muscles which enter the palm from forearm, e.g. flexor digitorum superficialis, flexor digitorum profundus, flexor pollicis longus are supplied by the nerves of the forearm. 1st and 2nd lumbricals are unipennate and are supplied by median nerve. 3rd and 4th are bipennate being supplied by deep branch of ulnar nerve

No muscle on dorsum of hand

Radial artery corresponds to anterior tibial while ulnar artery corresponds to posterior tibial artery. Ulnar artery divides into superficial and deep branches. There are two palmar arches, superficial and deep. The superficial arch mainly is formed by ulnar artery and deep arch is formed mainly by the radial artery. Cephalic vein is along the preaxial border. Basilic vein runs along the postaxial border of the limb and terminates in the middle of the arm

The axis of movement of adduction and abduction is through the third digit or middle finger. So the middle finger has two dorsal interossei muscles

*Sole**Palm*

I Layer Abductor hallucis brevis
Flexor digitorum brevis
Abductor digiti minimi

Abductor pollicis brevis
Flexor pollicis brevis
Flexor digiti minimi
Abductor digiti minimi

Between I and II layers Superficial plantar arch is not present
Branches of medial plantar nerve and artery
Branches of superficial branch of lateral plantar nerve

Superficial palmar arch
Branches of median nerve
Branches of superficial branch of ulnar nerve

II Layer Tendon of flexor digitorum longus, lumbricals and flexor digitorum accessorius
Tendon of flexor hallucis longus

Tendons of flexor digitorum superficialis
Tendons of flexor digitorum profundus and lumbricals
Tendon of flexor pollicis longus

III Layer Flexor hallucis brevis
Adductor hallucis
Flexor digiti minimi brevis

Opponens pollicis
Adductor pollicis
Opponens digiti minimi

Between III and IV layers Plantar arch with deep branch of lateral plantar nerve

Deep palmar arch and deep branch of ulnar nerve

IV Layer 1–3 plantar interossei
1–4 dorsal interossei
Tendons of tibialis posterior and peroneus longus

1–4 palmar interossei
1–4 dorsal interossei

**FACTS TO REMEMBER**

- Long saphenous vein with saphenous nerve lie anterior to medial malleolus
- Short saphenous vein lies behind lateral malleolus
- Varicose veins are due to tortuosity of the long saphenous vein and occur mostly due to prolonged standing.
- Long saphenous vein is used to bypass the coronary artery after inverting the vein.

CLINICOANATOMICAL PROBLEM

A 30-year-old female during her pregnancy noted blue tubular structures over her calf and thigh. These get prominent after standing for a long time.

- What are these blue tubular structures?
- Why do these develop in lower limbs only?

Ans: These blue tubular structures are the varicose veins in the lower limbs. These develop due to pressure of the foetal head on the veins in the pelvis, preventing the return of venous blood back into the circulation. These develop only in lower limbs as venous blood has to flow against gravity. Though there are valves inside the vein to permit unidirectional flow of blood, still varicose veins develop due to some incompetency of the valves and the pressure of the foetal head. On prolonged standing the veins got more prominent, as venous blood has to travel vertically upwards for long distance. Varicose veins usually disappear after pregnancy.

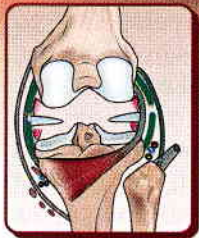MULTIPLE CHOICE QUESTIONS

1. Which one of the following factors does not help in venous return from lower limb?
 - a. Positive intrathoracic pressure
 - b. Arterial pressure and overflow from the capillary bed
 - c. Compression of vena comitantes accompanying the arteries by arterial pulsation
 - d. Presence of valves which supports the long column of blood and divides the long column into shorter parts.
2. Number of valves in long saphenous vein are:
 - a. 1–8
 - b. 10–20
 - c. 20–25
 - d. 25–30
3. Upper medial group of inguinal lymph nodes drains all the following regions *except*:
 - a. Infraumbilical part of anterior abdominal wall
 - b. Perineum including most of the external genitalia
 - c. Superolateral angle of the uterus
 - d. Most of the lower limb
4. Posterior primary rami of L1–L3 and S1–S3 supply skin of which quadrant of the gluteal region?
 - a. Superolateral quadrant
 - b. Superomedial quadrant
 - c. Inferomedial quadrant
 - d. Inferolateral quadrant
5. Quadriceps femoris muscle is supplied by:
 - a. L3, L4 segments
 - b. L2, L3, L4 segments
 - c. L2, L3, L4 segments
 - d. L3, L4, L5 segments
6. Which muscle is called the “peripheral heart”?
 - a. Popliteus
 - b. Soleus
 - c. Gastrocnemius
 - d. Tibialis posterior

ANSWERS

1. a 2. b 3. d 4. b 5. a 6. b

12



Joints of Lower Limb

High heels make her look "sexy" and confident not withstanding foot injury and back pain

INTRODUCTION

The weight-bearing joints of the lower limb are more stable. Hip joint allows the same movement as the mobile shoulder joint, but the range of movement is restricted.

Knee joint allows similar movements as the elbow besides the very important locking of the joint for long time standing. The leg bones do not permit the movements of supination and pronation for reasons of stability.

The ankle joint also allows limited movements for the same reason. The additional movements of inversion and eversion provided at the subtalar joints are to adjust the foot to the uneven ground.

HIP JOINT

DISSECTION

Ligate the femoral vessels and nerve with thick thread 2 cm below the inguinal ligament. Cut them above the ligature.

Cut sartorius muscle 5 cm below its origin and rectus femoris 3 cm below its origin and reflect these downwards. Detach the iliopsoas muscle from its insertion into lesser trochanter and separate the two parts.

The capsule of the joint and the thickened iliofemoral ligament are now exposed. Supplement the study of the ligaments and movements on the dried bones.

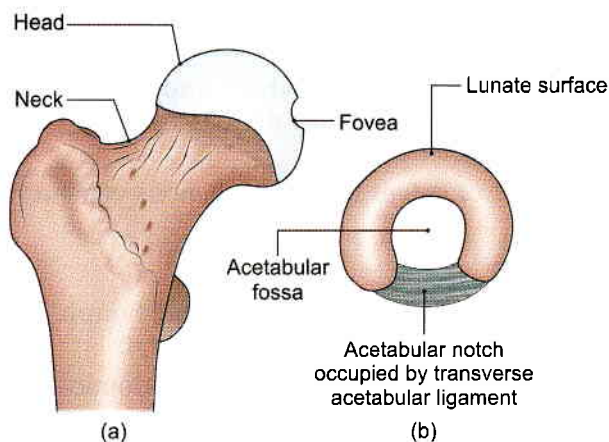
Type

Ball and socket variety of synovial joint (multiaxial).

Articular Surfaces

The head of the femur articulates with the acetabulum of the hip bone to form the hip joint. The *head of the*

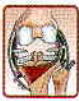femur forms more than half a sphere, and is covered with hyaline cartilage except at the fovea capitis. The *acetabulum* presents a horseshoe-shaped, lunate articular surface, an acetabular notch and an acetabular fossa (Figs 12.1a and b). The lunate surface is covered with cartilage. Though the articular surfaces on the head of the femur and on the acetabulum are reciprocally curved, they are not co-extensive.



Figs 12.1a and b: Articular surfaces of the hip joint

The hip joint is unique in having a high degree of stability as well as mobility. The *stability* or *strength* depends upon:

- Depth of the acetabulum and the narrowing of its mouth by the acetabular labrum.
- Tension and strength of ligaments.
- Strength of the surrounding muscles.
- Length and obliquity of the neck of the femur.
- Atmospheric pressure: A fairly wide range of mobility is possible because of the fact that the femur has a long neck which is narrower than the equatorial diameter of the head.



Ligaments

The ligaments include:

- The fibrous capsule,
- The iliofemoral ligament,
- The pubofemoral ligament,
- The ischiofemoral ligament,
- The ligament of the head of the femur,
- The acetabular labrum, and
- The transverse acetabular ligament.

- 1 The *fibrous capsule* is attached on the hip bone to the acetabular labrum including the transverse acetabular ligament, and to bone above and behind the acetabulum; and on the femur to the intertrochanteric line in front, and 1 cm medial to the intertrochanteric crest behind (Fig. 12.2).

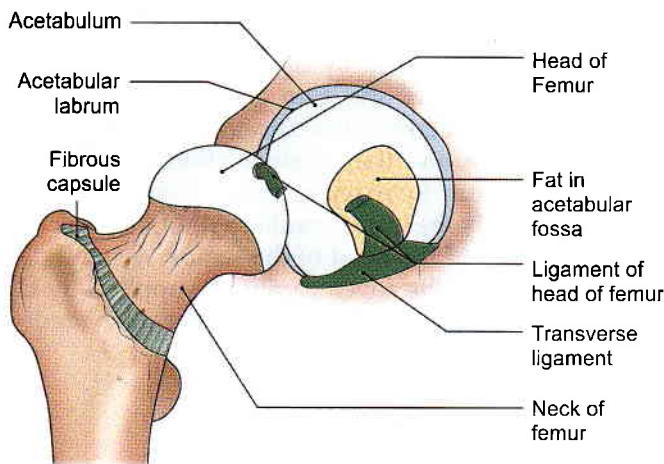


Fig. 12.2: Fibrous capsule of the hip joint

Anterosuperiorly, the capsule is thick and firmly attached. This part is subjected to maximum tension in the standing posture. Posteroinferiorly, the capsule is thin and loosely attached to bone.

The capsule is made up of two types of fibres. The outer fibres are longitudinal and the inner circular ones are called as *zona orbicularis*. The longitudinal fibres are best developed anterosuperiorly, where many of them are reflected along the neck of the femur to form the *retinacula*. Blood vessels supplying the head and neck of the femur, travel along these retinacula. The synovial membrane lines the fibrous capsule, the intracapsular portion of the neck of the femur, both surfaces of the acetabular labrum, the transverse ligament, and fat in the acetabular fossa. It also invests the round ligament of the head of the femur (Fig. 12.2).

The joint cavity communicates with a bursa lying deep to the tendon of *psoas major*, through a circular opening in the capsule located between the

pubofemoral ligament and vertical band of the iliofemoral ligament (Fig.12.3).

- 2 The *iliofemoral ligament*, or inverted Y-shaped ligament of *Bigelow*, lies anteriorly. It is one of the strongest ligaments in the body. It prevents the trunk from falling backwards in the standing posture. The ligament is triangular in shape. Its apex is attached to the lower half of the anterior inferior iliac spine; and the base to the intertrochanteric line. The upper oblique and lower vertical fibres form thick and strong bands, while the middle fibres are thin and weak (Fig. 12.3).

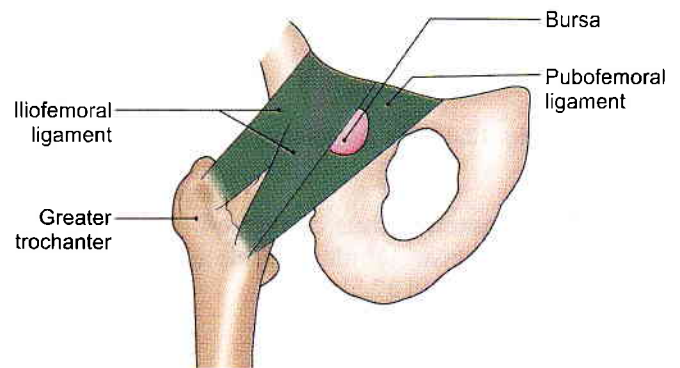


Fig. 12.3: The iliofemoral and pubofemoral ligaments

- 3 The *pubofemoral ligament* supports the joint inferomedially. It is also triangular in shape. Superiorly, it is attached to the iliopubic eminence, the obturator crest and the obturator membrane. Inferiorly, it merges with the anteroinferior part of the capsule and with the lower band of the iliofemoral ligament.
- 4 The *ischiofemoral ligament* is comparatively weak. It covers the joint posteriorly. Its fibres are twisted and extend from the ischium to the acetabulum. The fibres of the ligament form the *zona orbicularis*. Some of them are attached to the greater trochanter (Fig. 12.4).
- 5 The *ligament of the head of the femur*, round ligament or *ligamentum teres* is a flat and triangular ligament. The apex is attached to the fovea capitis, and the base to the transverse ligament and the margins of the acetabular notch. It may be very thin, or even absent. It transmits arteries to the head of the femur, from the acetabular branches of the obturator and medial circumflex femoral arteries (see Fig. 4.7).
- 6 The *acetabular labrum* is a fibrocartilaginous rim attached to the margins of the acetabulum. It narrows the mouth of the acetabulum. This helps in holding the head of the femur in position (Fig. 12.5).
- 7 The *transverse ligament of the acetabulum* is a part of the acetabular labrum which bridges the acetabular

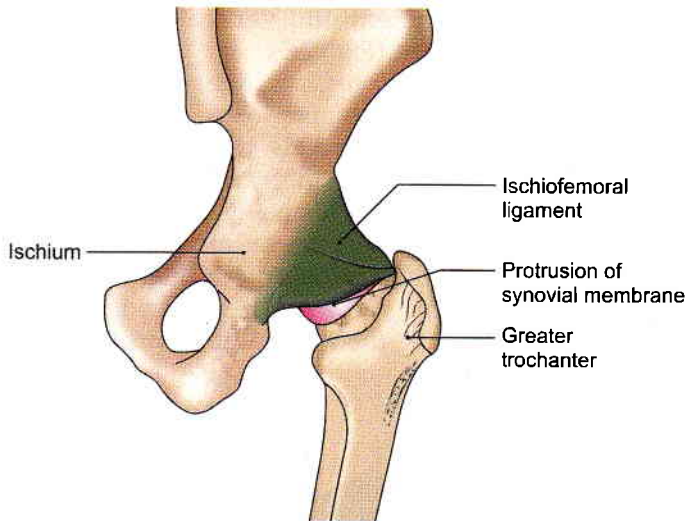


Fig. 12.4: The ischiofemoral ligament

notch. The notch is thus converted into a foramen which transmits acetabular vessels and nerves to the joint (Figs 12.1 and 12.5).

Relations of the Hip Joint

Anterior Relations

Tendon of the iliopsoas separated from the joint by a bursa and femoral vein, femoral artery and femoral nerve (Fig. 12.5).

Posterior Relations

The joint, from below upwards, is related to the following muscles: Tendon of obturator externus covered by the quadratus femoris, obturator internus and gemelli, piriformis, sciatic nerve and the gluteus maximus muscle.

Superior Relations

Reflected head of the rectus femoris covered by the gluteus minimus, gluteus medius and partly by gluteus maximus.

Inferior Relations

Lateral fibres of the pectineus and the obturator externus. In addition there are gracilis, adductors longus, brevis, magnus and hamstring muscles.

Blood Supply

The hip joint is supplied by the obturator artery, two circumflex femorals and two gluteal arteries. The medial and lateral circumflex femoral arteries form an arterial circle around the capsular attachment on the neck of the femur. Retinacular arteries arise from this circle and supply the intracapsular part of the neck and the greater part of the head of the femur. A small part of the head, near the fovea capitis is supplied by the acetabular branches of the obturator and medial circumflex femoral arteries (see Fig. 4.7).

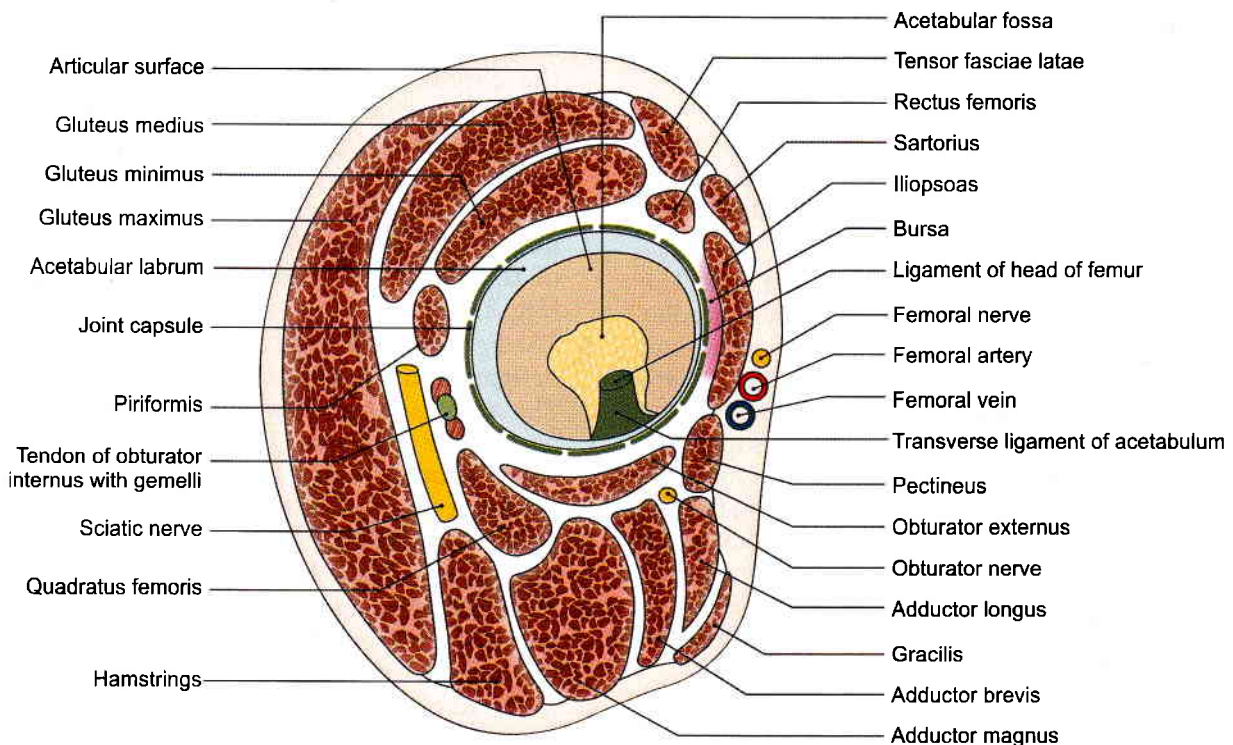


Fig. 12.5: Relations of the hip joint



Nerve Supply

The hip joint is supplied by the femoral nerve, through the nerve to the rectus femoris; the anterior division of the obturator nerve; the nerve to the quadratus femoris; and the superior gluteal nerve.

Movements

- 1 Flexion and extension occur around a transverse axis.
- 2 Adduction and abduction occur around an anteroposterior axis.
- 3 Medial and lateral rotation occur around a vertical axis.
- 4 Circumduction is a combination of the foregoing movements.

Hip joint extension and slight abduction and medial rotation is the close packed position for the hip joint which means the ligaments and the capsules are most taut in this position. But the surfaces are most congruent in slightly flexed, abducted and laterally rotated position of the hip.

In general, all axes pass through the centre of the head of the femur, but none of them is fixed because the head is not quite spherical.

Flexion is limited by contact of the thigh with the anterior abdominal wall. Similarly, adduction is limited by contact with the opposite limb. The range of the other movements is different from one another: Extension 15°, abduction 50°, medial rotation 25°, and lateral rotation 60°.

The movement of the hip is closely related to the position of the knee because of the presence of two muscles which act on both hip and knee. In the extended position of the knee, the stretch on the hamstring muscles does not allow the hip to move into its complete flexion range. Similarly with knee completely flexed, the hip joint may not attain complete extension due to tension in the Rectus femoris which gets stretched at the hip and the knee.

When the hip joints are bearing weight, the femur is fixed. But like any other joint, here also the proximal

bone, i.e. pelvis is capable of moving on the fixed distal femur. The pelvis can either move into anterior tilting (equivalent to flexion of hip) or posterior tilting (equivalent to extension of the hip).

The muscles producing these movements are given in Table 12.1.

CLINICAL ANATOMY

- *Congenital dislocation* is more common in the hip than in any other joint of the body. The head of the femur slips upwards on to the gluteal surface of the ilium because the upper margin of the acetabulum is developmentally deficient (Fig. 12.6). This causes lurching gait, and Trendelenburg's test is positive (see Fig. 5.12).
- *Perthes' disease* or pseudocoxalgia is characterized by destruction and flattening of the head of the femur, with an increased joint space in X-ray pictures.
Coxa vara is a condition in which the neck-shaft angle is reduced from the normal angle of about 150° in a child, and 127° in an adult (Fig. 12.7).
- *Dislocation of the hip* may be posterior (more common), anterior (less common), or central (rare). The sciatic nerve may be injured in posterior dislocations.
- Injuries in the region of hip joint may produce shortening of the lower limb. The length of lower limb is measured from the anterior superior iliac spine to the medial malleolus.
- Disease of the hip like tuberculosis, may cause *referred pain* in the knee because of the common nerve supply of the two joints.
- *Aspiration of the hip joint* can be done by passing a needle from a point 5 cm below the anterior superior iliac spine, upwards, backwards and medially. It can also be done from the side by passing the needle from the posterior edge of the greater trochanter, upwards and medially, parallel with the neck of the femur.

Table 12.1: Muscles producing movements at the hip joint

Movement	Chief muscles	Accessory muscles
1. Flexion	Psoas major and iliacus	Pectineus, rectus femoris, and sartorius; adductors (mainly adductor longus) participate in early stages
2. Extension	Gluteus maximus and hamstrings	—
3. Adduction	Adductors longus, brevis and magnus	Pectineus and gracilis
4. Abduction	Glutei medius and minimus	Tensor fasciae latae and sartorius
5. Medial rotation	Tensor fasciae latae and the anterior fibres of the glutei medius and minimus	—
6. Lateral rotation	Two obturators, two gemelli and the quadratus femoris	Piriformis, gluteus maximus and sartorius



- Hip diseases show an interesting age pattern:
 - Below 5 years : Congenital dislocation and tuberculosis (Fig. 12.6)
 - 5 to 10 years : Perthes' disease
 - 10 to 20 years : Coxa vara (Fig. 12.7)
 - Above 40 years: Osteoarthritis
- In arthritis of hip joint, the position of joint is partially flexed, abducted and laterally rotated.
- Fracture of the neck of the femur may be subcapital, near the head (Fig. 12.8), cervical in the middle, or basal near the trochanters. Damage to retinacular arteries causes avascular necrosis of the head. Such a damage is maximal in subcapital fractures and least in basal fractures. These fractures are common in old age, between the age of 40 and 60 years. Femur neck fracture is usually produced by trivial injuries. Trochanteric fracture may be intertrochanteric, i.e. between the trochanters or subtrochanteric, i.e. below the trochanters. These fractures occur in strong, adult subjects, and are produced by severe, violent injuries (Fig. 12.8).
- Shenton's line, in an X-ray picture, is a continuous curve formed by the upper border of the obturator foramen and the lower border of the neck of the femur. In fracture neck femur, line becomes abnormal (Fig. 12.9).

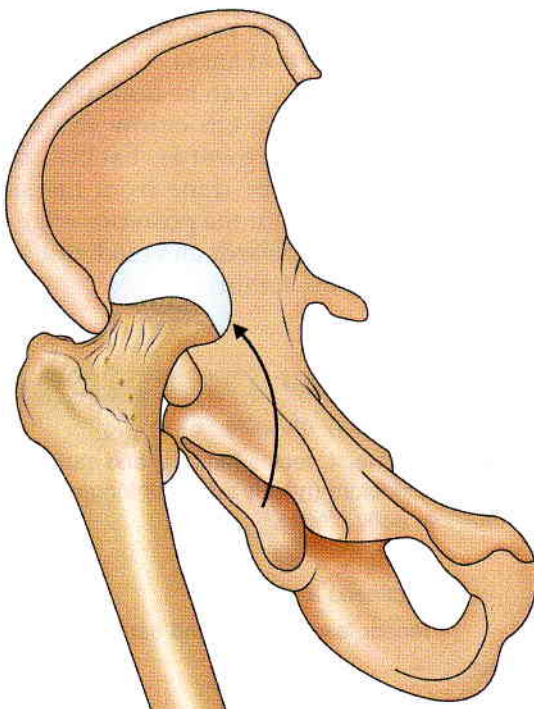


Fig. 12.6: Congenital dislocation of hip joint

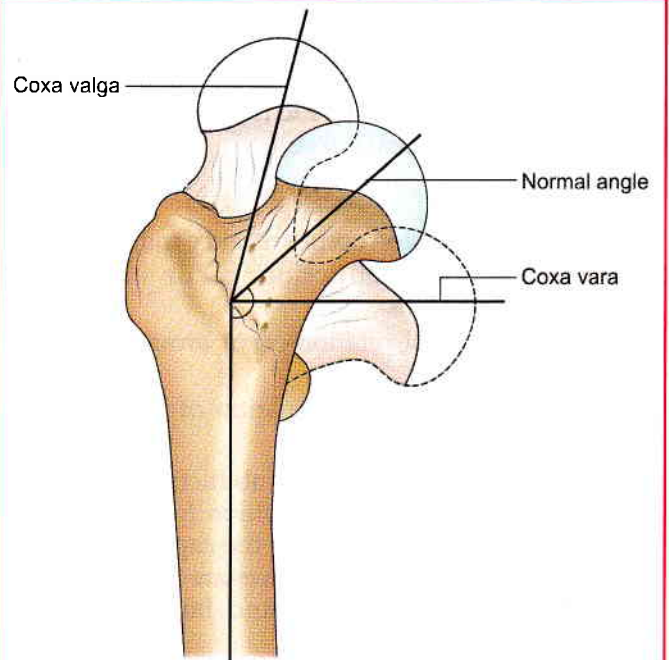


Fig. 12.7: Coxa vara and coxa valga

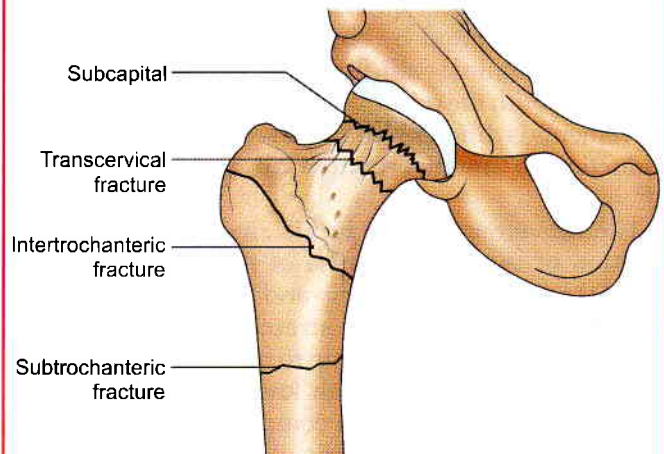


Fig. 12.8: Fracture of neck and trochanteric fracture

KNEE JOINT

DISSECTION

Strip the extra structures around the knee joint, leaving behind the fibrous capsule, ligaments and parts of muscles/tendons attached to the bones/ligaments.

Study the articular surfaces, articular capsule, medial and lateral collateral ligaments, oblique popliteal ligament and arcuate popliteal ligament.

Features

The knee is the largest and most complex joint of the body. The complexity is the result of fusion of three joints in one. It is formed by fusion of the lateral

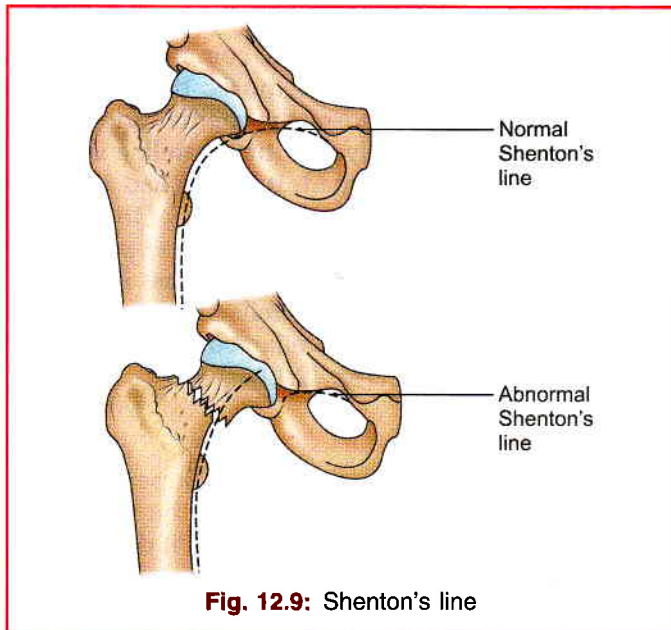


Fig. 12.9: Shenton's line

femorotibial, medial femorotibial, and femoropatellar joints.

Type

It is condylar synovial joint, incorporating two condylar joints between the condyles of the femur and tibia, and one saddle joint between the femur and the patella. It is also a complex joint as the cavity is divided by the menisci.

Articular Surfaces

The knee joint is formed by:

- 1 The condyles of the femur.
- 2 The patella (Figs 12.10 to 12.12).
- 3 The condyles of the tibia. The femoral condyles articulate with the tibial condyles below and behind, and with the patella in front.

Ligaments

The knee joint is supported by the following ligaments.

- 1 Fibrous capsule (Fig. 12.11).
- 2 Ligamentum patellae (Fig. 12.12).
- 3 Tibial collateral or medial ligament (Fig. 12.11).
- 4 Fibular collateral or lateral ligament (Fig. 12.11).

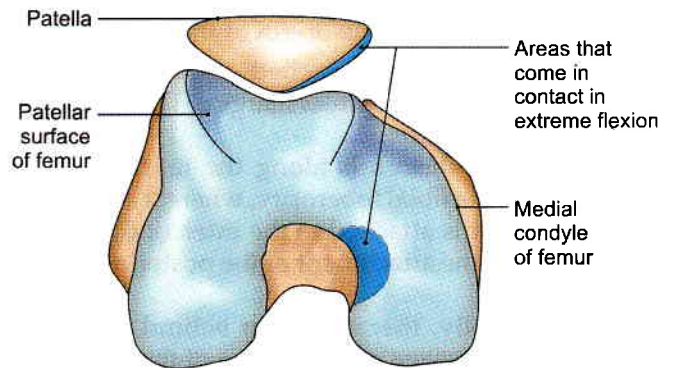


Fig. 12.10: Lower end of the femur and patella

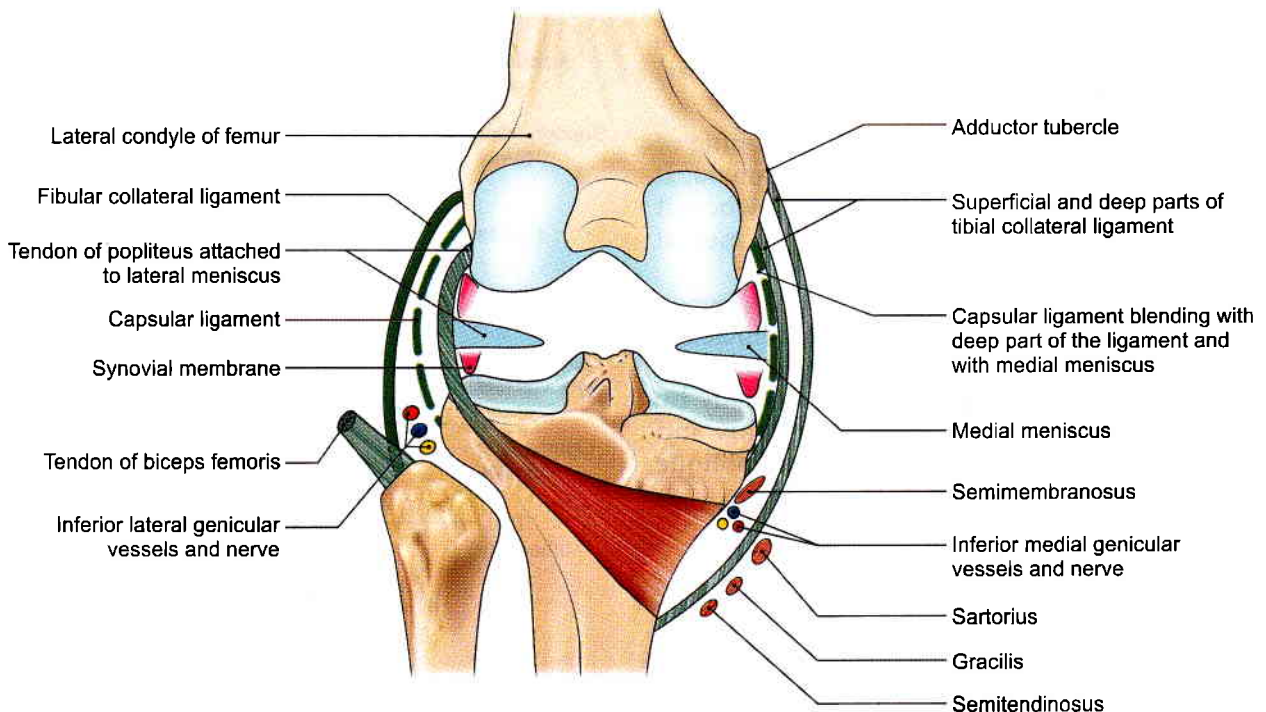


Fig. 12.11: Tibial and fibular collateral ligaments



- 5 Oblique popliteal ligament (Fig. 12.11).
- 6 Arcuate popliteal ligament.
- 7 Anterior cruciate ligament (Fig. 12.12).
- 8 Posterior cruciate ligament (Fig. 12.12).
- 9 Medial meniscus (Fig. 12.11).
- 10 Lateral meniscus (Fig. 12.11).
- 11 Transverse ligament.

Fibrous (Articular) Capsule

The fibrous capsule is very thin, and is deficient anteriorly, where it is replaced by the quadriceps femoris, the patella and the ligamentum patellae.

Femoral attachment: It is attached about half to one centimeter beyond the articular margins. The attachment has three special features.

- 1 Anteriorly, it is deficient.
- 2 Posteriorly, it is attached to the intercondylar line.
- 3 Laterally, it encloses the origin of the popliteus.

Tibial attachment: It is attached about half to one centimeter beyond the articular margins. The attachment has three special features.

- 1 Anteriorly, it descends along the margins of the condyles to the tibial tuberosity, where it is deficient.
- 2 Posteriorly, it is attached to the intercondylar ridge which limits the attachment of the posterior cruciate ligament.
- 3 Posterolaterally, there is a gap behind the lateral condyle for passage of the tendon of the popliteus.

Some terms applied to parts of the capsule are as follows.

Coronary ligament: The fibrous capsule is attached to the periphery of the menisci. The part of the capsule between the menisci and the tibia is sometimes called the coronary ligament.

Short lateral ligament: This is a cord-like thickening of the capsule deep to the fibular collateral ligament. It extends from the lateral epicondyle of femur, where it blends with the tendon of popliteus, to the medial border of the apex of the fibula.

The capsular ligament is weak. It is strengthened anteriorly by the medial and lateral patellar retinacula, which are extensions from the vastus medialis and lateralis; laterally by the iliotibial tract; medially by expansions from the tendons of the sartorius and semimembranosus; and posteriorly, by the oblique popliteal ligament.

Openings

The capsule has two constant gaps.

- 1 One leading into the suprapatellar bursa.
- 2 Another for the exit of the tendon of the popliteus.

Sometimes there are gaps that communicate with the bursae deep to the medial head of the gastrocnemius, and deep to the semimembranosus.

Ligamentum Patellae

This is the central portion of the common tendon of insertion of the quadriceps femoris; the remaining portions of the tendon form the medial and lateral patellar retinacula. The ligamentum patellae is about 7.5 cm long and 2.5 cm broad. It is attached above to the margins and rough posterior surface of the apex of the patella, and below to the smooth, upper part of the tibial tuberosity. The superficial fibres pass in front of the patella. The ligamentum patellae is related to the superficial and deep infrapatellar bursae, and to the infrapatellar pad of fat (Fig. 12.12).

Tibial Collateral or Medial Ligament

This is a long band of great strength. Superiorly, it is attached to the medial epicondyle of the femur just below the adductor tubercle. Inferiorly, it divides into anterior and posterior parts.

The anterior or superficial part is about 10 cm long and 1.25 cm broad, and is separated from the capsule by one or two bursae. It is attached below to the medial border and posterior part of the medial surface of the shaft of the tibia. It covers the inferior medial genicular vessels and nerve, and the anterior part of the tendon of the semimembranosus, and is crossed below by the tendons of the sartorius, gracilis and the semitendinosus (Fig. 12.11).

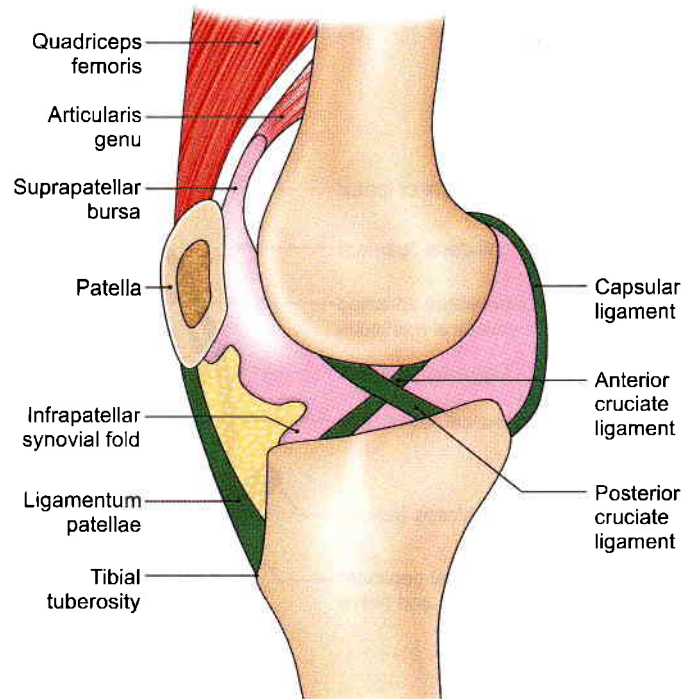


Fig. 12.12: Sagittal section through the knee joint of right side seen from the medial aspect to show the reflection of the synovial membrane (note the cruciate ligaments)



The *posterior (deep)* part of the ligament is short and blends with the capsule and with the medial meniscus. It is attached to the medial condyle of the tibia above the groove for the semimembranosus.

Morphologically, the tibial collateral ligament represents the degenerated tendon of the adductor magnus muscle.

Fibular Collateral or Lateral Ligament

This ligament is strong and cord-like. It is about 5 cm long. Superiorly, it is attached to the lateral epicondyle of the femur just above the popliteal groove. Inferiorly, it is embraced by the tendon of the biceps femoris, and is attached to the head of the fibula in front of its apex. It is separated from the lateral meniscus by the tendon of the popliteus. It is free from the capsule. The inferior lateral genicular vessels and nerve separate it from the capsule (Fig. 12.11).

Morphologically, it represents the femoral attachment of the peroneus longus.

Oblique Popliteal Ligament

This is an expansion from the tendon of the semimembranosus. It runs upwards and laterally, blends with the posterior surface of the capsule, and is attached to the intercondylar line and lateral condyle of the femur. It is closely related to the popliteal artery, and is pierced by the middle genicular vessels and nerve, and the terminal part of the posterior division of the obturator nerve (Fig 12.13).

Arcuate Popliteal Ligament

This is a posterior expansion from the short lateral ligament. It extends backwards from the head of the fibula, arches over the tendon of the popliteus, and is attached to the posterior border of the intercondylar area of the tibia.

Cruciate Ligaments

These are very thick and strong fibrous bands, which act as direct bonds of union between tibia and femur, to maintain anteroposterior stability of knee joint. They are named according to the attachment on tibia.

Anterior cruciate ligament begins from anterior part of intercondylar area of tibia, runs upwards, backwards and laterally and is attached to the posterior part of medial surface of lateral condyle of femur. It is taut during extension of knee (Fig. 2.12).

Posterior cruciate ligament begins from the posterior part of intercondylar area of tibia, runs upwards, forwards and medially and is attached to the anterior part of the lateral surface of medial condyle of femur. It is taut during flexion of the knee.

These are supplied by middle genicular vessels and nerves (see Figs 2.26 and 12.13).

Menisci or Semilunar Cartilages

The menisci are two fibrocartilaginous discs. They are shaped like crescents. They deepen the articular surfaces of the condyles of the tibia, and partially divide the joint cavity into upper and lower compartments. Flexion and extension of the knee take place in the *upper* compartment, whereas rotation takes place in the *lower* compartment (Fig. 12.11).

Each meniscus has the following.

- a. **Two ends:** The anterior and posterior ends of menisci are attached to the tibia and are referred to as anterior and posterior horns.
- b. **Two borders:** The 'outer' border is thick, convex and close to the fibrous capsule; while the 'inner' border is thin, concave and free.
- c. **Two surfaces:** The upper surface is concave for articulation with the femur. The lower surface is flat and rests on the peripheral two-thirds of the tibial condyle. The peripheral thick part is vascular. The inner part is avascular and is nourished by synovial fluid.

The *medial meniscus* is nearly semicircular, being wider behind than in front. The posterior fibres of the anterior end are continuous with the transverse ligament. Its peripheral margin is adherent to the deep part of the tibial collateral ligament (Fig. 12.11).

The *lateral meniscus* is nearly circular (see Fig. 2.26). The posterior end of the meniscus is attached to the medial condyle of femur through two menisiofemoral ligaments. The tendon of the popliteus and the capsule separate this meniscus from the fibular collateral ligament. The more medial part of the tendon of the popliteus is attached to the lateral meniscus. The mobility of the posterior end of this meniscus is controlled by the popliteus and by the two menisiofemoral ligaments.

Because of the attachments of the menisci to multiple structures, the motion of the menisci is limited to a great extent. Out of the two menisci the medial meniscus has more firm attachments to the tibia.

In a young person the peripheral 25–33% of the meniscus is vascularised and is innervated. The remaining part of the meniscus receives its nutrition from the synovial fluid. Therefore, movement is important for cartilage nutrition since movement causes diffusion of nutrients from synovial fluid to the cartilage.

Functions of menisci

- 1 They help in making the articular surfaces more congruent. Because of their flexibility they can adapt



their contour to the varying curvature of the different parts of the femoral condyles, as the latter glide over the tibia.

- 2 The menisci serve as shock absorbers.
- 3 They help in lubricating the joint cavity.
- 4 Because of their nerve supply, they also have a sensory function. They give rise to proprioceptive impulses.

Transverse Ligament

It connects the anterior ends of the medial and lateral menisci (Fig. 12.13).

SYNOVIAL MEMBRANE

DISSECTION

Cut through the tendon of quadriceps femoris muscle just above the knee joint. Extend this incision on either side of patella and ligamentum patellae anchored to the tibial tuberosity. Reflect patella downwards to peep into the cavity of knee joint.

Note the huge infrapatellar synovial fold and pad of fat in it. Remove the fat and posterior part of fibrous capsule so that the cruciate ligaments and menisci are visualised.

Features

The synovial membrane of the knee joint lines the capsule, except posteriorly where it is reflected forwards by the cruciate ligaments, forming a common covering for both the ligaments (Figs 12.11 and 12.12).

In front, it is absent from the patella. Above the patella, it is prolonged upwards for 5 cm or more as the suprapatellar bursa. Below the patella, it covers the deep surface of the infrapatellar pad of fat, which separates it from the ligamentum patellae. A median fold, the *infrapatellar synovial fold*, extends backwards from the pad of fat to the intercondylar fossa of the femur. An alar fold diverges on each side from the median fold to reach the lateral edges of the patella (Fig. 12.12).

Bursae around the Knee

As many as 12 bursae have been described around the knee—four anterior, four lateral, and four medial. These bursae are as follows.

Anterior

- 1 Subcutaneous prepatellar bursa (*see* Fig. 3.6).
- 2 Subcutaneous infrapatellar bursa.
- 3 Deep infrapatellar bursa.
- 4 Suprapatellar bursa.

Lateral

- 1 A bursa deep to the lateral head of the gastrocnemius.
- 2 A bursa between the fibular collateral ligament and the biceps femoris.
- 3 A bursa between the fibular collateral ligament and the tendon of the popliteus.
- 4 A bursa between the tendon of the popliteus and the lateral condyle of the tibia.

Medial

- 1 A bursa deep to the medial head of the gastrocnemius.
- 2 The *anserine bursa* is a complicated bursa which separates the tendons of the sartorius, the gracilis and the semitendinosus from one another, from the tibia, and from the tibial collateral ligament (*see* Fig. 8.14).
- 3 A bursa deep to the tibial collateral ligament.
- 4 A bursa deep to the semimembranosus.

Relations of Knee Joint

Anteriorly

Anterior bursae (*see* Fig. 3.6), ligamentum patellae (Fig. 12.12), and patellar plexus of nerves.

Posteriorly

- 1 *At the middle*: Popliteal vessels, tibial nerve.
- 2 *Posterolaterally*: Lateral head of gastrocnemius, plantaris, and common peroneal nerve.
- 3 *Posteromedially*: Medial head of gastrocnemius, semitendinosus, semimembranosus, gracilis, and popliteus at its insertion (Fig. 12.13).

Medially

- 1 Sartorius, gracilis and semitendinosus (*see* Fig. 8.14).
- 2 Great saphenous vein with saphenous nerve.
- 3 Semimembranosus (Fig. 12.13).

Laterally

Biceps femoris, and tendon of origin of popliteus.

Blood Supply

The knee joint is supplied by the anastomoses around it. The chief sources of blood supply are:

- 1 Five genicular branches of the popliteal artery.
- 2 The descending genicular branch of the femoral artery.
- 3 The descending branch of the lateral circumflex femoral artery.
- 4 Two recurrent branches of the anterior tibial artery.
- 5 The circumflex fibular branch of the posterior tibial artery (*see* Fig. 6.10).

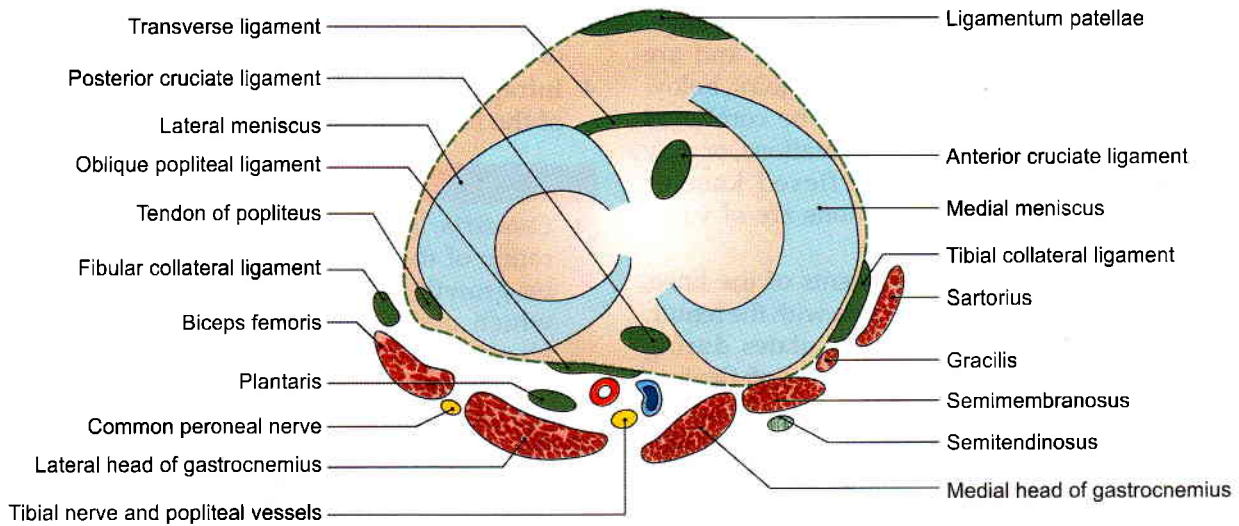


Fig. 12.13: Transverse section through the left knee joint showing the synovial relations

Nerve Supply

- 1 Femoral nerve, through its branches to the vasti, especially the vastus medialis.
- 2 Sciatic nerve, through the genicular branches of the tibial and common peroneal nerves.
- 3 Obturator nerve, through its posterior division.

MOVEMENTS AT THE KNEE JOINT

DISSECTION

Clean the articular surfaces of femur, tibia and patella on the soft specimen and on dried bones. Analyse the movements on them. Try all these movements on yourself and on your friends as well.

Features

Active movements at the knee are flexion, extension, medial rotation and lateral rotation (Table 12.2).

Flexion and *extension* are the chief movements. These take place in the upper compartment of the joint, above

the menisci. They differ from the ordinary hinge movements in two ways.

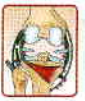- 1 The transverse axis around which these movements take place is not fixed. During extension, the axis moves forwards and upwards, and in the reverse direction during flexion.
- 2 These movements are invariably accompanied by rotations or conjunct rotation. When the foot is on the ground, while standing erect, medial rotation of femur occurs during last 30 degrees of extension as in position of "attention" by the vastus medialis. It is called conjunct rotation. During the position of "stand at ease", there is lateral rotation of femur, during initial stages of flexion, by popliteus muscle.

Medial rotation of the femur occurs during the last 30 degrees of extension, and lateral rotation of the femur occurs during the initial stages of flexion.

When the foot is off the ground as while sitting on a chair the tibia rotates instead of the femur, in the opposite direction.

Table 12.2: Muscles producing movements at the knee joint

Movement	Principal muscles
A. Extension (from sitting on a chair to standing)	Quadriceps femoris (four heads)
B. Locking (standing in "attention")	Vastus medialis
C. Unlocking (standing "at ease")	Popliteus
D. Flexion	1. Biceps femoris 2. Semitendinosus 3. Semimembranosus
E. Medial rotation of flexed leg	1. Popliteus 2. Semimembranosus 3. Semitendinosus
F. Lateral rotation of flexed leg	Biceps femoris



Rotatory movements at the knee are of a small range. Rotations take place around a vertical axis, and are permitted in the lower compartment of the joint, below the menisci. Rotatory movements may be combined with flexion and extension or conjunct rotations, or may occur independently in a partially flexed knee or adjunct rotations. The conjunct rotations are of value in locking and unlocking of the knee.

During different phases of movements of the knee, different portions of the patella articulate with the femur. The lower pair of articular facets articulates during extension; middle pair during beginning of flexion; upper pair during midflexion; and the medial strip during full flexion of the knee (see Figs 2.21 and 12.10).

Locking and Unlocking of the Knee Joint

Locking is a mechanism that allows the knee to remain in the position of full extension as in standing without much muscular effort.

Locking occurs as a result of medial rotation of the femur during the last stage of extension. The anteroposterior diameter of the lateral femoral condyle is less than that of the medial condyle. As a result, when the lateral condylar articular surface is fully 'used up' by extension, part of the medial condylar surface remains unused. At this stage the lateral condyle serves as an axis around which the medial condyle rotates backwards, i.e. medial rotation of the femur occurs, so that the remaining part of the medial condylar surface is also 'taken up'. This movement locks the knee joint. Locking is aided by the oblique pull of ligaments during the last stages of extension. When the knee is locked, it is completely rigid and all ligaments of the joint are taut. Locking is produced by continued action of the same muscles that produce extension, i.e. the quadriceps femoris, especially the vastus medialis part.

The locked knee joint can be flexed only after it is unlocked by a reversal of the medial rotation, i.e. by lateral rotation of the femur. Unlocking is brought about by the action of the popliteus muscle.

Accessory or passive movements can be performed in a partially flexed knee. These movements include:

- a. A wider range of rotation.
- b. Anteroposterior gliding of the tibia on the femur.
- c. Some adduction and abduction.
- d. Some separation of the tibia from the femur.

Morphology of Knee Joint

- 1 The tibial collateral ligament is the degenerated tendon of the adductor magnus.
- 2 The fibular collateral ligament is the degenerated tendon of the peroneus longus.

- 3 Cruciate ligaments represent the collateral ligaments of the originally separate femorotibial joints.
- 4 Infrapatellar synovial fold indicates the lower limit of the femoropatellar joint.

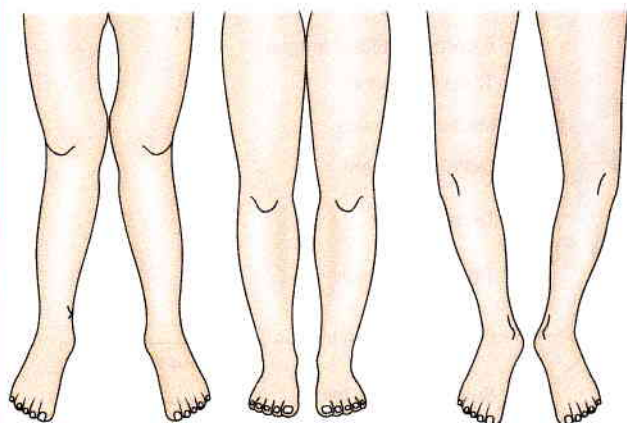
CLINICAL ANATOMY

- *Osteoarthritis* is an age related cartilage degeneration of the articular surfaces. It is characterized by growth of osteophytes at the articular ends, which make movements limited and painful. However, osteoarthritis may set in at an early age also due to underlying congenital deformities or fractures around the knee joint.
- Structurally, the knee is a weak joint because the articular surfaces are not congruent. The tibial condyles are too small and shallow to hold the large, convex, femoral condyles in place. The femoropatellar articulation is also quite insecure because of the shallow articular surfaces, and because of the outward angulation between the long axis of the thigh and of the leg. The stability of the joint is maintained by a number of factors.
 - a. The cruciate ligaments maintain anteroposterior stability.
 - b. The collateral ligaments maintain side to side stability.
 - c. The factors strengthening the capsule have been enumerated earlier.
 - d. The iliotibial tract plays an important role in stabilizing the knee (see Fig. 3.8).
- *Deformities of the knee:* The angle between the long axis of the thigh and that of the leg may be abnormal and the leg may be abnormally abducted (genu valgum or knock knee) or abnormally adducted (genu varum or bow knee). This may occur due to rickets, and posture, or as a congenital abnormality (Fig. 12.14).
- *Diseases of the knee:* The knee joint may be affected by various diseases. These include osteoarthritis and various infections. Infections may be associated with collections of the fluid in the joint cavity. This gives rise to swelling above, and at the sides of the patella. The patella appears to float in the fluid. Aspiration of fluid can be done by passing a needle into the joint on either side of the patella. Bursae around the joint may get filled with fluid resulting in swellings.
- *Injuries to the knee:*
 - a. *Injuries to menisci* strains in a slightly flexed knee, as in kicking a football, the meniscus may get separated from the capsule, or may be torn longitudinally (bucket-handle tear) or transversely (see Fig. 2.18).



The medial meniscus is more vulnerable to injury than the lateral because of its fixity to the tibial collateral ligament, and because of greater excursion during rotatory movements. The lateral meniscus is protected by the popliteus which pulls it backwards so that it is not crushed between the articular surfaces.

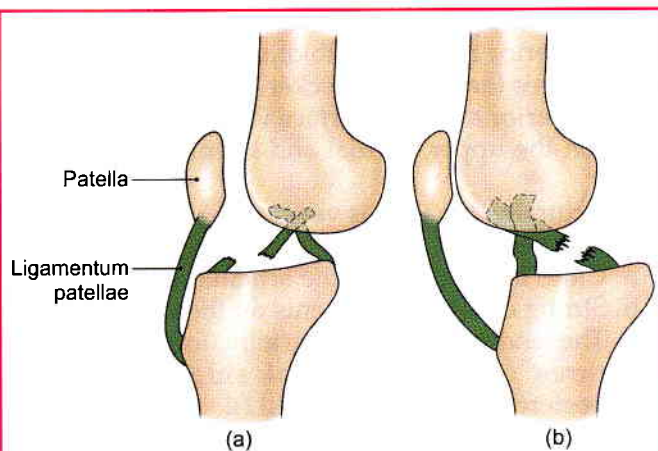
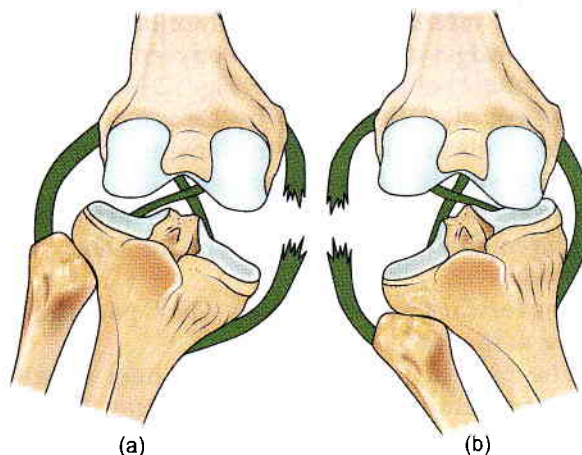
- b. *Injuries to cruciate ligaments* are also common. The anterior cruciate ligament is more commonly damaged than the posterior. It may be injured in violent hyperextension of the knee or in anterior dislocation of the tibia. The posterior ligament is injured in posterior dislocation of the tibia. The injury may vary from simple sprain to complete tear. Tear of the ligaments leads to abnormal anteroposterior mobility (Figs 12.15a and b).
- c. *Injuries to collateral ligaments* are less common, and may be produced by severe abduction and adduction strains (Figs 12.16a and b).
- *Mal-alignment of patella*: Ideally the patella is resting in the centre of the width of the femur in a relaxed standing position. However, the patella position may be altered congenitally or due to tightness of surrounding structures which may lead to painful conditions of the patello-femoral joint.
 - Semimembranosus bursitis is quite common. It causes a swelling in the popliteal fossa region on the posteromedial aspect (see Fig. 7.5).
 - Baker's cyst is a central swelling, occurs due to osteoarthritis of knee joint. The synovial membrane protrudes through a hole in the posterior part of capsule of knee joint.
 - Hip joint and knee joint may need to be replaced if beyond repair.
 - In knee joint disease vastus medialis is first to atrophy and last to recover (see Fig. 3.27).



Genu valgum

Normal

Genu varum

Fig. 12.14: Deformities of the knee**Figs 12.15a and b:** Rupture of: (a) Anterior, and (b) posterior cruciate ligaments**Figs 12.16a and b:** Injury of: (a) Medial, and (b) lateral collateral ligaments

ANKLE JOINT

DISSECTION

Define the margins of both extensor retinacula, one flexor retinaculum and both peroneal retinacula. Identify the tendons enclosed in synovial sheaths, nerves and blood vessels passing under them. Displace these structures without removing them.

Clean and define the strong medial and lateral ligaments of ankle joint. Also demarcate the thin anterior and posterior parts of the capsule of the joint.

Type

This is a synovial joint of the hinge variety.

Articular Surfaces

The upper articular surface is formed by:

- 1 The lower end of the tibia including the medial malleolus.



- 2 The lateral malleolus of the fibula, and
- 3 The inferior transverse tibiofibular ligament. These structures form a deep socket (Fig. 12.18).

The inferior articular surface is formed by articular areas on the upper, medial and lateral aspects of the talus.

Structurally, the joint is very strong. The stability of the joint is ensured by:

- a. Close interlocking of the articular surfaces.
- b. Strong collateral ligaments on the sides.
- c. The tendons that cross the joint, four in front, and three on posteromedial side and two on posterolateral side (Fig. 12.17).

The depth of the superior articular socket is contributed by:

- a. The downward projection of medial and lateral malleoli, on the corresponding sides of talus.
- b. By the inferior transverse tibiofibular ligament that bridges across the gap between the tibia and the fibula behind the talus (Fig. 12.18). The socket is provided flexibility by strong tibiofibular ligaments and by slight movements of the fibula at the superior tibiofibular joint.

There are two factors, however, that tend to displace the tibia and fibula forwards over the talus. These factors are:

- a. The forward pull of tendons which pass from the leg to the foot.
- b. The pull of gravity when the heel is raised. Displacement is prevented by the following factors.
 - i. The talus is wedge-shaped, being wider anteriorly. The malleoli are oriented to fit this wedge.

- ii. The posterior border of the lower end of the tibia is prolonged downwards.
- iii. The presence of the inferior transverse tibiofibular ligament.
- iv. The tibiocalcanean, posterior tibiotalar, calcaneofibular and posterior talofibular ligaments pass backwards and resist forward movement of the tibia and fibula.

Ligaments

The joint is supported by:

- a. Fibrous capsule.
- b. The deltoid or medial ligament.
- c. A lateral ligament.

Fibrous Capsule

It surrounds the joint but is weak anteriorly and posteriorly. It is attached all around the articular margins with two exceptions.

- 1 Posterosuperiorly, it is attached to the inferior transverse tibiofibular ligament.
- 2 Anteroinferiorly, it is attached to the dorsum of the neck of the talus at some distance from the trochlear surface.

The anterior and posterior parts of the capsule are loose and thin to allow hinge movements. On each side, however, it is supported by strong collateral ligaments.

The synovial membrane lines the capsule. The joint cavity ascends for some distance between the tibia and the fibula.

Deltoid or Medial Ligament

This is a very strong triangular ligament present on the medial side of the ankle. The ligament is divided

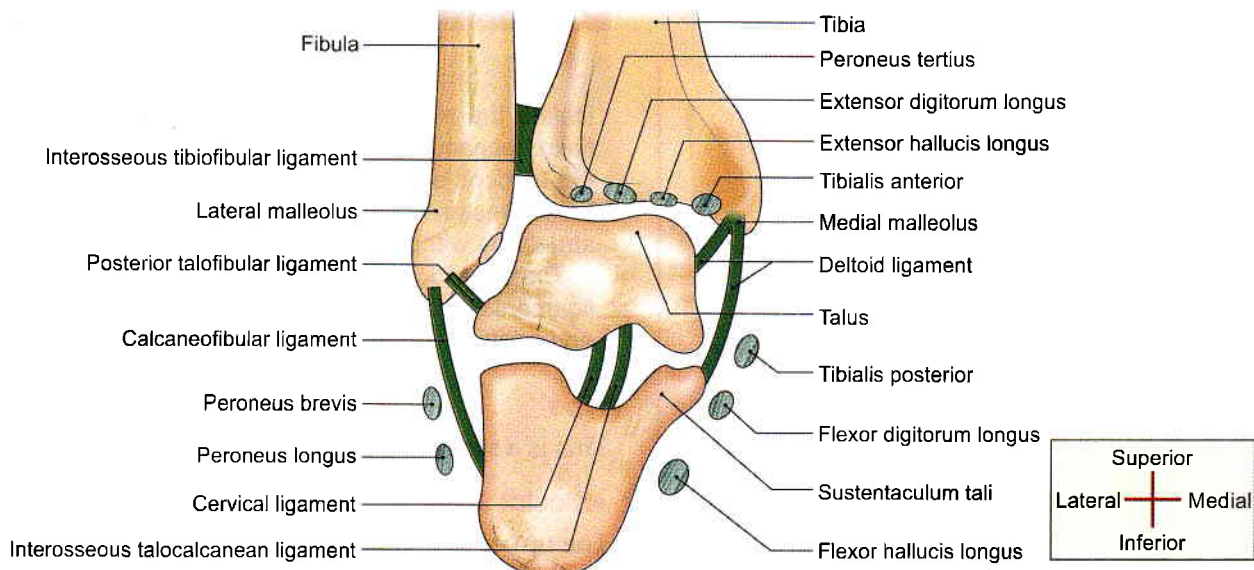
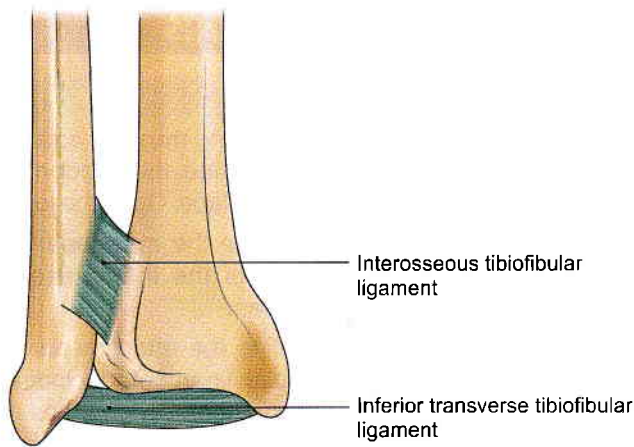
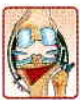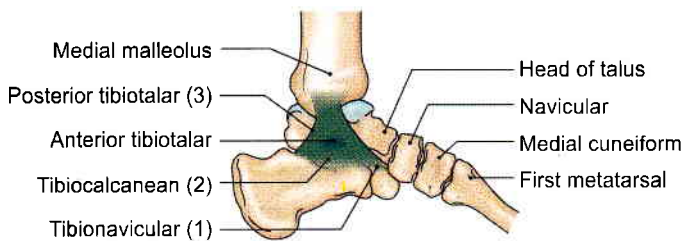


Fig. 12.17: Anterior view of coronal section through the right ankle joint to show its relations

**Fig. 12.18:** Inferior tibiofibular joint**Fig. 12.19:** Medial side of the ankle joint showing the parts of deltoid ligament

into a superficial and a deep part. Both parts have a common attachment above to the apex and margins of the medial malleolus. The lower attachment is indicated by the name of the fibres (Fig. 12.19).

Superficial part

- 1 Anterior fibres or *tibionavicular* are attached to the tuberosity of the navicular bone and to the medial margin of the spring ligament.
- 2 The middle fibres or *tibiocalcanean* are attached to the whole length of the sustentaculum tali.
- 3 The posterior fibres or *posterior tibiotalar* are attached to the medial tubercle and to the adjoining part of the medial surface of the talus.

Deep part or *anterior tibiotalar* is attached to the anterior part of the medial surface of the talus.

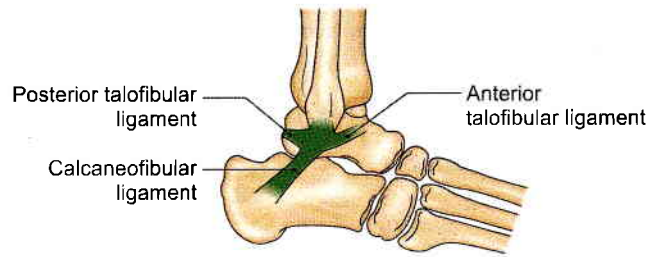
The deltoid ligament is crossed by the tendons of the tibialis posterior and flexor digitorum longus.

The deltoid ligament is a very strong ligament and excessive tensile forces on the ligament result in an avulsion fracture rather than a tear of the ligament. The ligament is prone to injuries in inversion.

Lateral Ligament

This ligament consists of three bands as follows.

- 1 The *anterior talofibular ligament* is a flat band which passes from the anterior margin of the lateral malleolus to the neck of the talus, just in front of the fibular facet (Fig. 12.20).

**Fig. 12.20:** Lateral side of the ankle joint showing the lateral ligament

- 2 The *posterior talofibular ligament* passes from the lower part of the malleolar fossa of the fibula to the lateral tubercle of the talus.
- 3 The *calcaneofibular ligament* is a long rounded cord which passes from the notch on the lower border of the lateral malleolus to the tubercle on the lateral surface of the calcaneum. It is crossed by the tendons of the peroneus longus and brevis.
- 4 The interosseous tibiofibular ligament, inferior extensor retinaculum and inferior and superior peroneal retinacula also contribute to the stability of the ankle joint (see Figs 8.4 and 8.9).

Relations of the Ankle Joint

Anteriorly, from medial to lateral side, there are the tibialis anterior, the extensor hallucis longus, the anterior tibial vessels, the deep peroneal nerve, the extensor digitorum longus, and the peroneus tertius (Fig. 12.17).

Posteromedially, from medial to lateral side, there are the tibialis posterior, the flexor digitorum longus, the posterior tibial vessels, the tibial nerve, the flexor hallucis longus.

Posterolaterally the peroneus longus, and the peroneus brevis (Fig. 12.17).

Movements

Active movements are dorsiflexion and plantar flexion (Table 12.3).

- 1 In *dorsiflexion* the forefoot is raised, and the angle between the front of the leg and the dorsum of the foot is diminished. It is a close-pack position with maximum congruence of the joint surfaces. The wider anterior trochlear surface of the talus fits into lower end of narrow posterior part of the lower end of tibia. There are no chances of dislocation in dorsiflexion (see Fig. 11.13).
- 2 In *plantar flexion*, the forefoot is depressed, and the angle between the leg and the foot is increased. The narrow posterior part of trochlear surface of talus loosely fits into the wide anterior part of the lower end of tibia. High heels cause plantar flexion of ankle joint and its dislocations (see Fig. 9.10).


Table 12.3: Muscles producing movements

Movement	Principal muscles	Accessory muscles
A. Dorsiflexion	Tibialis anterior	<ol style="list-style-type: none"> 1. Extensor digitorum longus 2. Extensor hallucis longus 3. Peroneus tertius
B. Plantar flexion	<ol style="list-style-type: none"> 1. Gastrocnemius 2. Soleus 	<ol style="list-style-type: none"> 1. Plantaris 2. Tibialis posterior 3. Flexor hallucis longus 4. Flexor digitorum longus

Blood Supply

From anterior tibial, posterior tibial, and peroneal arteries.

Nerve Supply

From deep peroneal and tibial nerves.

CLINICAL ANATOMY

- The *sprains of the ankle* are almost always abduction sprains of the subtalar joints, although a few fibres of the deltoid ligament are also torn. True sprains of the ankle joint are caused by forced plantar flexion, which leads to tearing of the anterior fibres of the capsule. The joint is unstable during plantar flexion.
- *Dislocations of the ankle* are rare because joint is very stable due to the presence of deep tibiofibular socket. Whenever dislocation occurs, it is accompanied by fracture of one of the malleoli.
- Acute sprains of lateral ankle occur when the foot is plantar flexed and excessively inverted. The lateral ligaments of ankle joint are torn giving rise to pain and swelling.
- Acute sprains of medial ankle occur in excessive eversion, leading to tear of strong deltoid ligament. These cases are less common.
- The *optimal position* of the ankle to avoid ankylosis is one of slight plantar flexion.
- For injections into the ankle joint, the needle is introduced between tendons of extensor hallucis longus and tibialis anterior with the ankle partially plantar flexed.
- During walking, the plantar flexors raise the heel from the ground. When the limb is moved forwards the dorsiflexors help the foot in clearing the ground. The value of the ankle joint resides in this hinge action, in this to and fro movement of the joint during walking.

TIBIOFIBULAR JOINTS

DISSECTION

Superior tibiofibular joint: Remove the muscles around the superior tibiofibular joint. Define the tendon of popliteus muscle on its posterior surface. Open the joint.

Middle tibiofibular joint: Remove the muscles from anterior and posterior surface of the interosseous membrane and define its surfaces.

Inferior tibiofibular joint: Define the attachments of anterior and posterior tibiofibular ligaments including inferior transverse tibiofibular ligament. Divide these to expose the strong interosseous tibiofibular ligament. Use dry bones and articulated foot to understand the attachments of the ligaments.

The tibia and fibula articulate at three joints, the superior, middle and inferior tibiofibular joints.

Superior Tibiofibular Joint

This is a small synovial joint of the plane variety. It is formed by articulation of small, rounded, flat facets present on the head of the fibula, and on the lateral condyle of the tibia. The joint permits slight gliding or rotatory movements that help in adjustment of the lateral malleolus during movements at the ankle joint.

The bones are united by a fibrous capsule which is strengthened by anterior and posterior ligaments. These ligaments are directed forwards and laterally. The cavity of the joint may communicate with the knee joint through the popliteal bursa. The joint is supplied by the nerve to the popliteus, and by the recurrent genicular nerve (*see* Fig. 6.7).

Middle Tibiofibular Joint

This is a fibrous joint formed by the interosseous membrane connecting the shafts of the tibia and the fibula. The interosseous membrane is attached to the interosseous borders of the two bones. Its fibres are directed downwards and laterally. It is wide above and narrow below where it is continuous with the interosseous ligament of the inferior tibiofibular joint. It presents a large opening at the upper end for the passage of the anterior tibial vessels, and a much smaller opening near its lower end for the passage of the perforating branch of the peroneal artery (*see* Fig. 2.24).

Relations

Anteriorly

Tibialis anterior, extensor digitorum longus, anterior tibial vessels, deep peroneal nerve extensor hallucis longus and peroneus tertius (*see* Fig. 8.5).

**Posterorly**

Tibialis posterior and flexor hallucis longus (see Fig. 9.4).

Nerve Supply

Nerve to popliteus.

Functions

- 1 The membrane provides additional surface for attachment of muscles.
- 2 Binds the tibia and the fibula.
- 3 Resists the downward pull exerted on the fibula by the powerful muscles attached to the bone. Note that the biceps femoris is the only muscle that pulls the fibula upwards.

Inferior Tibiofibular Joint

This is a syndesmosis uniting the lower ends of the tibia and the fibula (Fig. 12.18). The bony surfaces are connected by a very strong *interosseous ligament*, which forms the chief bond of union between the lower ends of these bones.

The interosseous ligament is concealed both in front and behind by the *anterior* and *posterior tibiofibular ligaments*, whose fibres are directed downwards and laterally.

The posterior tibiofibular ligament is stronger than the anterior. Its lower and deep portion forms the *inferior transverse tibiofibular ligament*, which is a strong thick band of yellowish fibres passing transversely from the upper part of the malleolar fossa of the fibula to the posterior border of the articular surface of the tibia, reaching up to the medial malleolus (Fig. 12.18).

Blood Supply

Perforating branch of the peroneal artery; and the malleolar branches of the anterior and posterior tibial arteries (see Fig. 9.7).

Nerve Supply

Deep peroneal, tibial and saphenous nerves.

The joint permits slight movements, so that the lateral malleolus can rotate laterally during dorsiflexion of the ankle.

CLINICAL ANATOMY

- The inferior tibiofibular joint is strong. The strength of the ligaments uniting the lower ends of the tibia and fibula is an important factor in maintaining the integrity of the ankle joint.
- The slight movements of the lateral malleolus taking place at this joint provide suppleness to the ankle joint.

JOINTS OF THE FOOT**DISSECTION**

Remove all the tendons, muscles from both dorsal and plantar aspects of the tarsal, metatarsal and phalanges. Define, identify the ligaments joining the various bones. Ligaments are stronger on the plantar aspect than the dorsal aspect.

Subtalar joint

Divide the ligaments which unite the talus and calcaneus together at the talocalcanean, talocalcaneonavicular joints. Study these joints carefully to understand the movements of inversion and eversion.

On the lateral side of foot, define the attachments of long plantar ligament. Reflect this ligament from its proximal attachment to see the deeper plantar calcaneocuboid ligament.

Classification

The joints of the foot are numerous. They can be classified as:

- 1 Intertarsal (Fig. 12.21),
- 2 Tarsometatarsal,
- 3 Intermetatarsal,
- 4 Metatarsophalangeal, (see Fig. 2.44)
- 5 Interphalangeal.

The main intertarsal joints are the subtalar or talocalcanean joint, the talocalcaneonavicular joint and the calcaneocuboid joint. Smaller intertarsal joints include the cuneonavicular, cuboidonavicular, intercuneiform and cuneocuboid joints.

The movements permitted at these joints are as follows.

- a. The intertarsal, tarsometatarsal and intermetatarsal joints permit gliding and rotatory movements,

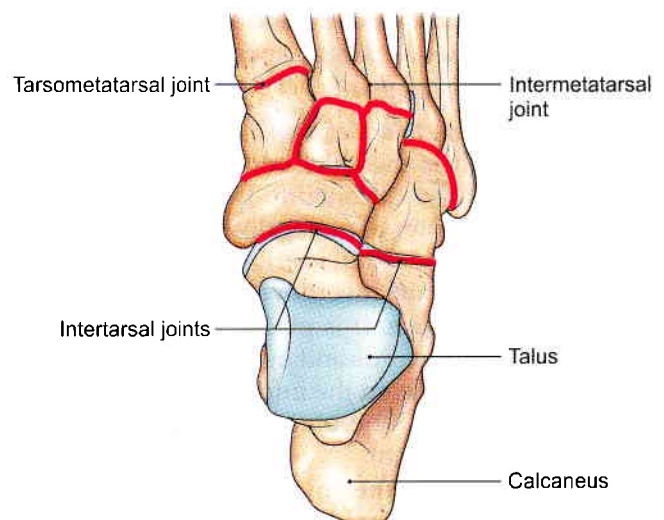


Fig. 12.21: Some joints of the foot



which jointly bring about inversion, eversion, of the foot. Pronation is a component of eversion, while supination is a component of inversion.

- b. The metatarsophalangeal joints permit flexion, extension, adduction and abduction of the toes.
- c. The interphalangeal joints of hinge variety permit flexion and extension of the distal phalanges.

A brief description of the relevant joints is given below.

SUBTALAR OR TALOCALCANEAN JOINT

There are three joints, posterior, anterior and medial between the talus and the calcaneum. The posterior joint is named the talocalcanean or subtalar joint where concave undersurface of body of talus articulates with convex posterior facet of the calcaneum.

The anterior joints are parts of the talocalcaneonavicular joint. On the anterior and medial side of undersurface of head of talus, the surfaces are convex and articulate with concave articulating surfaces of calcaneum.

Since the three joints form a single functional unit, clinicians often include these joints under the term subtalar joint. However, the sinus tarsi separates the posterior articulations from the anterior and medial articulations. The greater part of the talocalcaneonavicular joint lies in front of the head of the talus and not below it (Figs 12.22a and b).

Talocalcanean Joint

The *talocalcanean joint* is a plane synovial joint between the concave facet on the inferior surface of the body of the talus and the convex facet on the middle one-third of the superior surface of the calcaneum.

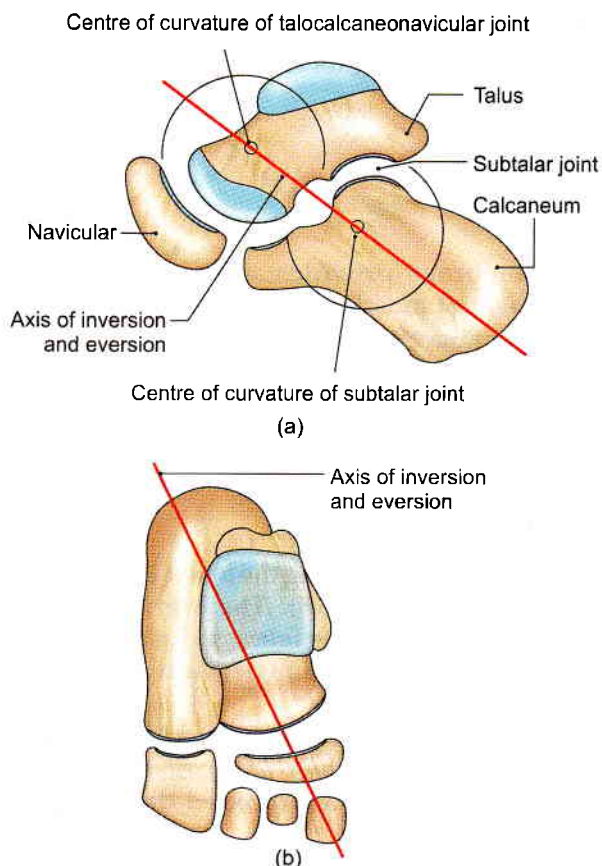
The bones are connected by:

- a. A fibrous capsule,
- b. The lateral and medial talocalcanean ligaments,
- c. The interosseous talocalcanean ligament, and
- d. The cervical ligament:

The *interosseous talocalcanean ligament* is thick and very strong. It is the chief bond of union between the talus and the calcaneum. It occupies the sinus tarsi, and separates the talocalcanean joint from the talocalcaneonavicular joint. It becomes taut in eversion, and limits this movement.

The *cervical ligament* is placed lateral to the sinus tarsi. It passes upwards and medially, and is attached above to a tubercle on the inferolateral aspect of the neck of the talus. It becomes taut in inversion, and limits this movement.

In addition to the interosseous and cervical ligament, the collateral ligaments of the ankle joint also provide stability to the talocalcanean joint.



Figs 12.22a and b: Axis of movements of inversion and eversion at subtalar joint: (a) Side view, and (b) superior view

Movements

The joint participates in the movements of inversion and eversion of the foot described at the end of chapter.

Talocalcaneonavicular Joint

The joint has some of the features of a ball and socket joint. The head of the talus fits into a socket formed partly by the navicular bone, and partly by the calcaneum. Two ligaments also take part in forming the socket: these are the spring ligament medially, and the medial limb of the bifurcate ligament laterally (Figs 12.22a and b).

The bones taking part in forming the joint are connected by a fibrous capsule. The capsule is supported posteriorly by the interosseous talocalcanean ligament; dorsally by the dorsal talonavicular ligament; ventromedially by the spring ligament; and laterally by the medial limb of the bifurcate ligament. The spring ligament is described below. The bifurcate ligament is described with the calcaneocuboid joint.

Movements

The movements permitted at this joint are those of inversion and eversion. They are described below.



The *spring ligament* or *plantar calcaneonavicular ligament* is powerful. It is attached posteriorly to the anterior margin of the sustentaculum tali, and anteriorly to the plantar surface of the navicular bone between its tuberosity and articular margin. The head of the talus rests directly on the upper surface of the ligament, which is covered by fibrocartilage. The plantar surface of the ligament is supported by the tendon of tibialis posterior medially, and by the tendons of flexor hallucis longus and flexor digitorum longus, laterally.

The spring ligament is the most important ligament for maintaining the medial longitudinal arch of the foot.

CALCANEOCUBOID JOINT

This is a saddle joint. The opposed articular surfaces of the calcaneum and the cuboid are concavoconvex. On account of the shape of articular surfaces, medial movement of the forefoot is accompanied by its lateral rotation and adduction or inversion. Lateral movement of the forefoot is accompanied by medial rotation and abduction or eversion. The bones are connected by:

- 1 A fibrous capsule,
- 2 The lateral limb of the bifurcate ligament,
- 3 The long plantar ligament (Fig. 12.23) and
- 4 The short plantar ligament.

The *bifurcate ligament* is Y-shaped. Its stem is attached to the anterolateral part of the sulcus calcanei; the medial limb or calcaneonavicular ligament, to the dorsolateral surface of the navicular bone; and the lateral limb or calcaneocuboid ligament, to the dorsomedial surface of the cuboid bone. Thus each limb of the ligament strengthens a separate joint.

The *long plantar ligament* (Fig. 12.23) is a long and strong ligament whose importance in maintaining the arches of foot is surpassed only by the spring ligament.

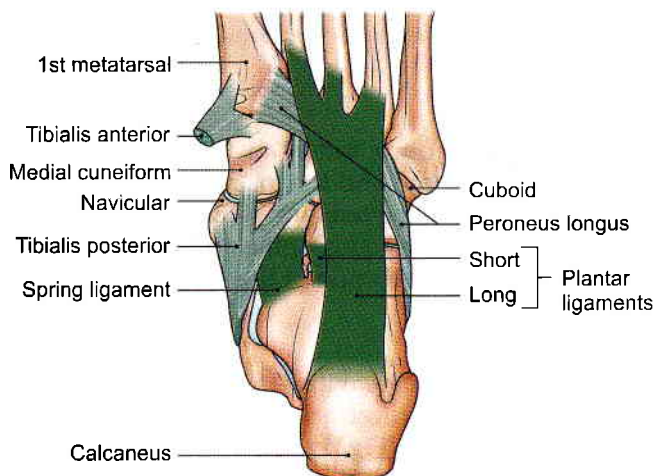


Fig. 12.23: Some ligaments of the foot with the tendons of peroneus longus

It is attached posteriorly to the plantar surface of the calcaneum, and anteriorly to the lips of the groove on the cuboid bone, and to the bases of the middle three metatarsals. It converts the groove on the plantar surface of the cuboid into a tunnel for the tendon of the peroneus longus. Morphologically, it represents the divorced tendon of the gastrocnemius.

The *short plantar ligament* or *plantar calcaneocuboid ligament* lies deep to the long plantar ligament. It is broad and strong ligament extending from the anterior tubercle of the calcaneum to the plantar surface of the cuboid, behind its ridge.

TRANSVERSE TARSAL OR MIDTARSAL JOINT

This includes the calcaneocuboid and the talonavicular joints (Fig. 12.21). The talonavicular joint is a part of the talocalcaneonavicular joint, and hence the transverse tarsal joint may be said to be made up of only one and a half joints. These joints are grouped together only by virtue of being placed in nearly the same transverse plane. In any case, the two joints do not form a functional unit. They have different axes of movements. It demarcates the forefoot from the hindfoot. Its movements help in inversion and eversion of the foot.

Inversion and Eversion of the Foot

Inversion is a movement in which the medial border of the foot is elevated, so that the sole faces medially.

Eversion is a movement in which the lateral border of the foot is elevated, so that the sole faces laterally. These movements can be performed voluntarily only when the foot is off the ground. When the foot is on the ground these movements help to adjust the foot to uneven ground.

In inversion and eversion, the entire part of the foot below the talus moves together. The movement takes place mainly at the subtalar and talocalcaneonavicular joints and partly at the transverse tarsal joint. The calcaneum and the navicular bone, move medially or laterally round the talus carrying the forefoot with them. Inversion is accompanied by plantar flexion of the foot and adduction of the forefoot. Eversion is accompanied by dorsiflexion of the foot and abduction of the forefoot.

Joints Taking Part

Main

- 1 Subtalar (talocalcanean).
- 2 Talocalcaneonavicular.

Accessory

Transverse tarsal which includes calcaneocuboid and talonavicular joints.



Axis of Movements

Inversion and eversion take place around an oblique axis which runs forwards, upwards and medially, passing from the back of the calcaneum, through the sinus tarsi, to emerge at the superomedial aspect of the neck of the talus. The obliquity of the axis partly accounts for adduction, abduction, plantar flexion and dorsiflexion which are associated with these movements (Fig. 12.22).

Range of Movements

- 1 Inversion is much more free than eversion.
- 2 The range of movements is appreciably increased in plantar flexion of the foot because, in this position, the narrow posterior part of the trochlear surface of the talus occupies the tibiofibular socket. In this position slight side to side movements of the talus are permitted.

Muscles Producing Movements

Inversion is produced by the actions of the tibialis anterior and the tibialis posterior, helped by the flexor hallucis longus and the flexor digitorum longus (Table 12.4).

Table 12.4: Muscles producing movements of inversion and eversion

Movement	Principal muscles
A. Inversion	Tibialis anterior Tibialis posterior
B. Eversion	Peroneus longus Peroneus brevis

Mechanism: During inversion the forepart of foot is adducted at mid tarsal joint followed by lateral rotation of foot at subtalar joint. During eversion the reverse of this occurs.

Pronation and Supination of the Foot

These are really components of the movements of inversion and eversion. In pronation and supination, the forefoot (i.e. the distal part of the tarsus and metatarsus) moves on the calcaneum and talus. The medial border of the forefoot is elevated in supination (which is thus a part of inversion), while the reverse occurs in pronation (and the eversion). These movements take place chiefly at the transverse tarsal joint and partly at smaller intertarsal, tarsometatarsal and intermetatarsal joints.

There are differences when supination and pronation occur in weight bearing and nonweight bearing situations. In weight bearing supination and pronation, the calcaneum is not free to move in all directions and

the motions are thus completed by compensatory movements of the talus.

Limiting Factors

Inversion is limited by:

- 1 Tension of peronei
- 2 Tension of cervical ligament.

Eversion is limited by:

- 1 Tension of tibialis anterior
- 2 Tension of tibialis posterior
- 3 Tension of deltoid ligament.

Functional Significance

Inversion and eversion greatly help the foot in adjusting to uneven and slippery ground. When feet are supporting the body weight, these movements occur in a modified form called supination and pronation, which are forced on the foot by the body weight.

SMALLER JOINTS OF FOREFOOT

DISSECTION

Cut across the cuneocuboid, cuneonavicular and intercuneiform joints to expose the articulating surfaces.

With a strong knife cut through tarsometatarsal and intermetatarsal joints. Try to separate the bones to see interosseous ligaments.

Detach abductor hallucis, flexor hallucis brevis, adductor hallucis from the sesamoid bones of the big toe.

Cut the deep transverse metatarsal ligaments on each side of the third toe. Now the tendons of dorsal and plantar interossei can be seen till their insertion. Identify the distal attachments of the lumbrical muscles as well.

Identify the extensor expansion on the dorsum of digits and see its continuity with the collateral ligaments. Study these joints from the text provided.

Features

These are plane joints between the navicular, the cuneiform, the cuboid and the metatarsal bones. They permit small gliding movements, which allow elevation and depression of the heads of the metatarsals, as well as pronation and supination of the foot.

Joint Cavities of Foot

There are only six joint cavities in the proximal part of the foot. These are intertarsal, tarsometatarsal and intermetatarsal joints (Fig. 12.24). The cavities are:

- 1 Talocalcanean
- 2 Talocalcaneonavicular
- 3 Calcaneocuboid

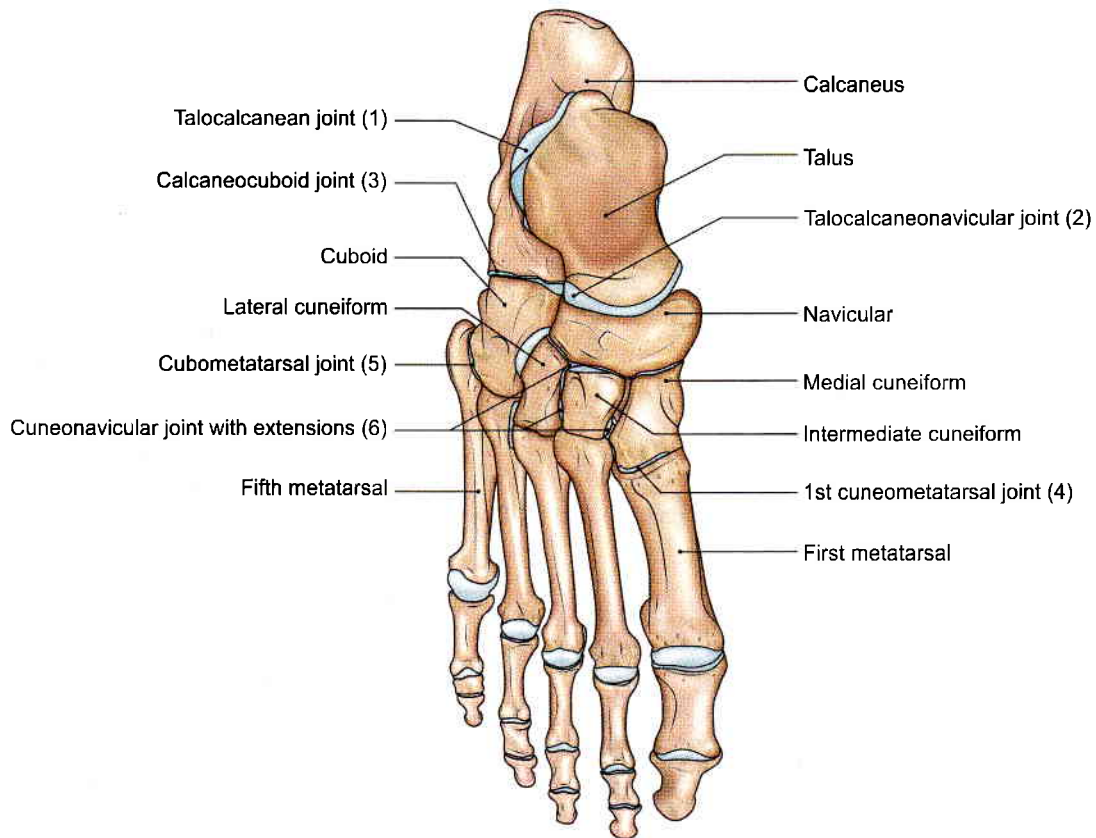


Fig. 12.24: Joint cavities in the proximal part of the foot

- 4 First cuneometatarsal
- 5 Cubometatarsal
- 6 Cuneonavicular with extensions (Fig. 12.21), i.e. navicular with three cuneiforms and second and third cuneometatarsal joints.

Metatarsophalangeal and Interphalangeal Joints

The structure of these joints is similar to the corresponding joints of the hand, with two exceptions.

- 1 The deep transverse ligaments of the foot connect all the five toes instead of only four fingers in the hand.
- 2 The toes are adducted and abducted with reference to the second toe and not the third finger as in the hand.

GAIT WALKING

Gait is a motion which carries the body forwards. There are two phases: Swing and stance (Figs 12.25a to d).

Swing Phase

- 1 Flexion of hip, flexion of knee and plantar flexion of ankle.
- 2 Flexion of hip, extension of knee and dorsiflexion of ankle.

Stance Phase

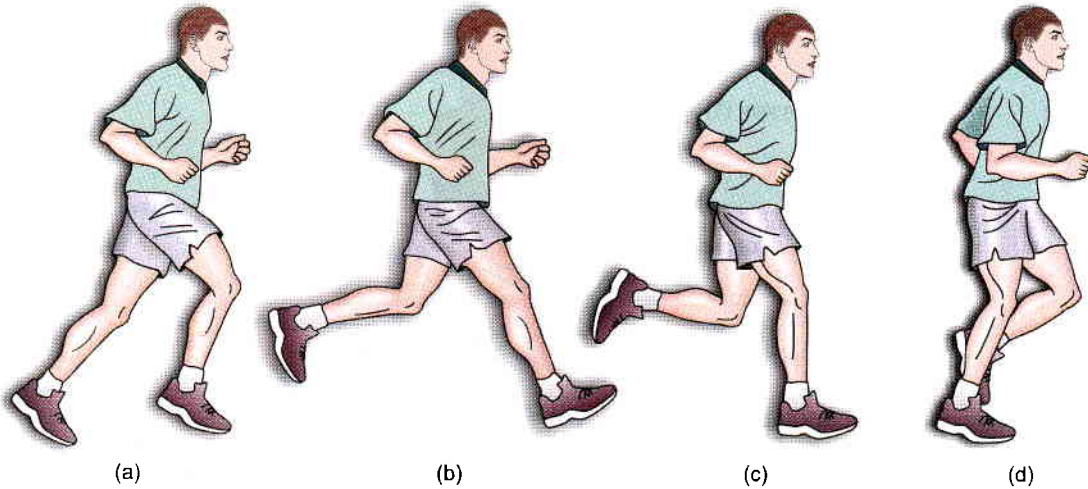
- 1 Flexion of hip, extension of knee and foot on the ground.
- 2 Extension of hip, extension of knee and foot on the ground.

CLINICAL ANATOMY

- Females wearing high heels (more than 5 cm), put stress on their back and lower limbs. The spine is pushed forwards, knees are excessively bent, resulting in too much pull on some muscles and ligaments. High heels result in shift in position of centre of gravity. The problems caused by high heels are "fashionable diseases". The sprains of the medial and lateral ligaments of ankle joint are almost always due to high heels (see Fig. 9.10).
- Joints of the foot lead to various deformities like mallet toe, hammer toe and claw toe (Fig. 12.26).
- *Arthroscopy*: One can look into the joints by special instruments called the arthroscopes.

For hip joint, the instrument is introduced 4 cm lateral to the femoral pulse and 4 cm below inguinal ligament.

For knee joint, the arthroscope is introduced from the front of the semiflexed knee joint.



Figs 12.25a to d: Phases of gait: (a) and (b) Swing phase, (c) and (d) stance phase

For ankle joint, the instrument is introduced medial to the tendon of tibialis anterior muscle. One needs to be careful of the great saphenous vein.

- *Hallux valgus*: Due to ill-fitting shoes great toe gets pushed laterally, even dislocating the sesamoid bone. Head of 1st metatarsal points medially and adventitious bursa develops there. Toes may be deformed at their joints resulting in claw toe.
- Fractured toe is bandaged with the adjacent toe, this is called buddy splint (Fig. 12.27).

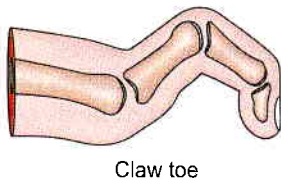
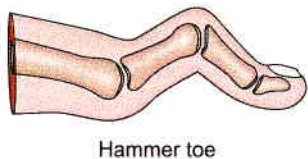
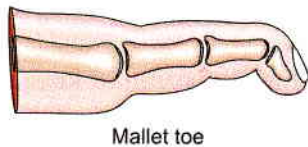
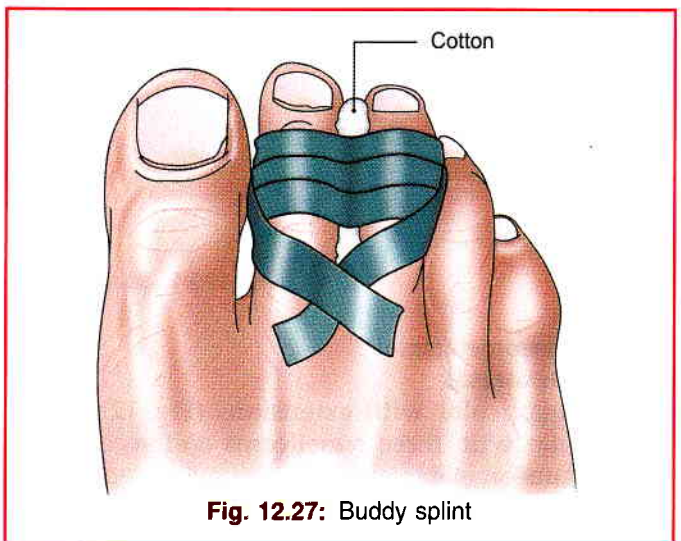


Fig. 12.26: Deformities of toes

Morphologic Significance

In intrauterine life and early infancy, the soles of the feet are turned inwards, so that they face each others. As growth proceeds, the feet are gradually everted to allow a plantigrade posture. Such eversion does not occur in apes.



Mnemonics of Locking and Unlocking

L M F T T E

Locking is medial rotation of femur on tibia at terminal stages of extension when foot is on the ground.

U L F T I F

Unlocking is lateral rotation of femur on tibia at initial stages of flexion when foot in on the ground.

L L T F T E

Locking is lateral rotation of tibia on femur at terminal stages of extension when foot in off the ground.

U M T F I F

Unlocking is medial rotation of tibia on femur at initial stages of flexion when foot is off the ground.

**FACTS TO REMEMBER**

- Knee joint is the most complicated joint
- Flexion and extension are allowed in the upper compartment of knee joint while rotation is permitted in the lower or meniscotibial compartment.
- Inversion and eversion occur at talocalcaneo-navicular joint, assisted by movements at transverse tarsal joints, i.e. talonavicular and calcaneocuboid joints.
- Locking muscle is vastus medialis part of quadriceps femoris.
- Unlocking muscle is popliteus.
- Tendon of peroneus longus crosses the sole from lateral to medial side
- Inferior tibiofibular joint is a syndesmosis type of joint, i.e. joint formed by ligaments only.
- Fibula does not take part in knee joint, but participates in the formation of ankle joint.
- Talus has no muscular attachment. Tendon of flexor hallucis longus courses between the two tubercles of its posterior process
- The big toe carries double the weight to the ground than any of other four toes.

CLINICOANATOMICAL PROBLEMS**Case 1**

The knee of a football player was flexed at right angle. At this time, his knee was so injured that his tibia got driven forwards.

- What ligament is injured?
- What are its attachments? What other ligaments can be injured?

Ans: The injured ligament is anterior cruciate ligament. It is attached below to anterior part of intercondylar area of tibia. It is attached above to the medial surface of a lateral condyle of femur. This ligament binds the two bones together. With this injury, the menisci and fibular collateral ligaments may also be torn.

Case 2

A sportsman, while playing basketball sprained his ankle. He complained of severe pain on the lateral side of his right ankle.

- What ligament is injured?
- What other ligament could be injured?
- What bone can be fractured?

Ans: The sportsman's anterior talofibular ligament is torn. The posterior talofibular and calcaneofibular ligaments could also be torn. The lower end of fibula could also be fractured.

MULTIPLE CHOICE QUESTIONS

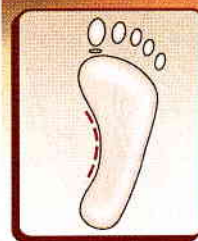1. All of the following muscles extend thigh at hip joints *except*:
 - a. Semitendinosus
 - b. Semimembranosus
 - c. Hamstring portion of adductor magnus
 - d. Gluteus medius
2. Strongest ligament around hip joint which prevents overextension during standing?
 - a. Ischiofemoral ligament
 - b. Pubofemoral ligament
 - c. Iliofemoral ligament
 - d. Transverse acetabular ligament
3. At beginning of flexion of locked knee, the joint is unlocked by which of following muscle?
 - a. Biceps femoris
 - b. Popliteus
 - c. Gastrocnemius
 - d. Articularis genu
4. Concerning knee joint which of the following statement is correct?
 - a. It is a hinge joint made up of articulations between femur, tibia and fibula
 - b. The tendon of popliteus perforates capsule posteriorly and attached to medial meniscus
 - c. It contains two semilunar cartilages, medial one being longer and more liable to injury
 - d. The anterior cruciate ligament arises from anterior intercondylar area in front of anterior end of medial semilunar cartilage
5. Regarding stability of knee joint, which of following factors is most important
 - a. The shape of articulating surfaces
 - b. The semilunar cartilages
 - c. The cruciate ligaments
 - d. The tone of muscle acting on joint, especially quadriceps femoris
6. Which is not true about ankle joint?
 - a. It is synovial joint of hinge variety
 - b. Deltoid ligament contribute to its stability
 - c. It is formed by distal ends of tibia and fibula articulating with body of talus
 - d. It is most stable in fully plantar flexed position
7. Which muscle is concerned in dorsiflexion of foot at ankle joint?
 - a. Extensor digitorum brevis
 - b. Extensor hallucis brevis



- c. Tibialis anterior
d. Tibialis posterior
8. All of following muscles are concerned with dorsiflexion of foot at ankle joint *except*:
- a. Peroneus longus
b. Tibialis anterior
c. Extensor digitorum longus
d. Extensor hallucis longus
9. All muscles are invertors of foot at talocalcaneonavicular joint *except*:
- a. Tibialis posterior b. Peroneus tertius
c. Tibialis anterior d. Flexor digitorum longus
10. Abduction and adduction of forefoot takes place at which of following joints?
- a. Ankle joint b. Tarsometatarsal joints
c. Subtalar joint d. Inferior tibiofibular

ANSWERS

1. d 2. c 3. b 4. c 5. c 6. d 7. c 8. a 9. b 10. c



Arches of Foot

The happiest moments we ever know are when we entirely forget ourselves
—Swami Vivekanand

INTRODUCTION

Arches of the foot help in fast walking, running and jumping. In addition, these help in weight-bearing and in providing upright posture. The foot is really unique to human being. Arches are supported by intrinsic and extrinsic muscles of the sole in addition to ligaments, aponeurosis and shape of the bones. Foot prints are not complete due to the arches. The foot has to suffer from many disorders because of tight shoes or high heels which one wears for various reasons.

The foot has to act:

- 1 As a pliable platform to support the body weight in the upright posture, and
- 2 As a lever to propel the body forwards in walking, running or jumping.

To meet these requirements, the human foot is designed in the form of elastic arches or springs. These arches are segmented, so that they can best sustain the stresses of weight and of thrusts. The presence of the arches makes the sole concave. This is best appreciated by examining foot prints which show the weight-bearing parts of the sole (Fig. 13.1).

An arched foot is a distinctive feature of man. It distinguishes him from other primates. The arches are present right from birth, although they are masked in infants by the excessive amount of fat in their soles.

CLASSIFICATION OF ARCHES

- 1 Longitudinal
 - Medial
 - Lateral
- 2 Transverse
 - Anterior
 - Posterior

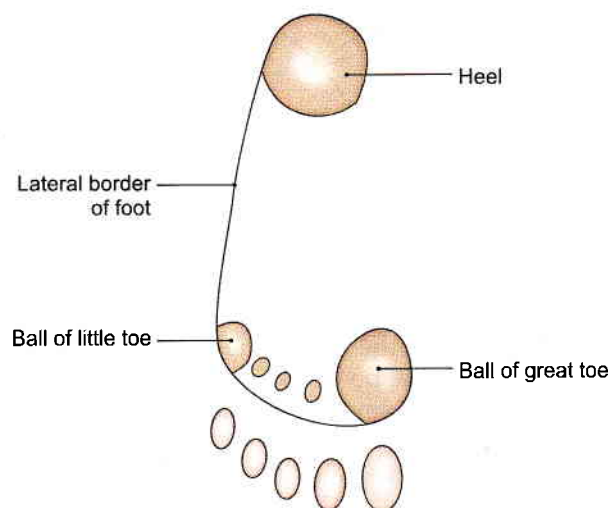


Fig. 13.1: Foot print showing the weight-bearing points of the sole

FORMATION OR STRUCTURE OF ARCHES

Medial Longitudinal Arch

This arch is considerably higher, more mobile and resilient than the lateral. It is considered as a big arc of a small circle. Its constitution is as follows:

Ends

The *anterior end* is formed by the heads of the first, second and third metatarsals. The phalanges do not take part in forming the arches. The *posterior end* of this arch is formed by the medial tubercle of the calcaneum (Fig. 13.2).

Summit

The summit of the arch is formed by the superior articular surface of the body of the talus.

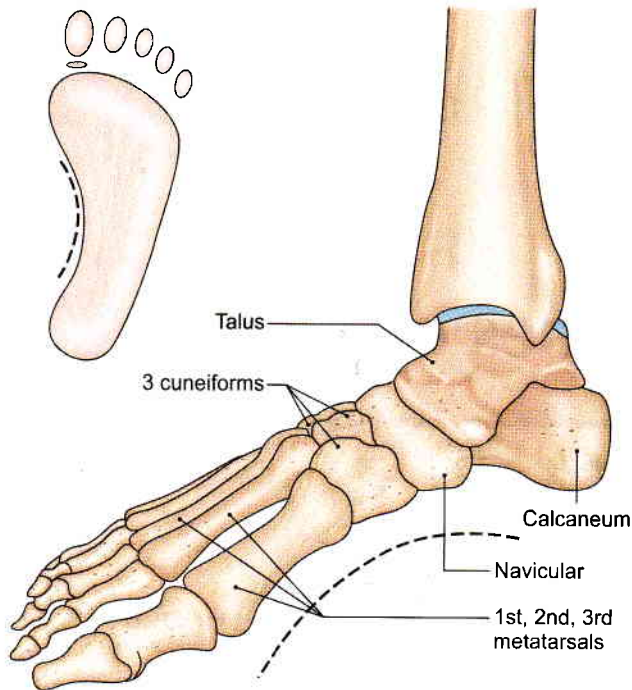


Fig. 13.2: Bones forming the medial longitudinal arch of foot: Superior view

Pillars

The *anterior pillar* is long and weak. It is formed by the talus, the navicular, the three cuneiform bones, and the first three metatarsal bones. The *posterior pillar* is short and strong. It is formed by the medial part of the calcaneum (Fig. 13.3).

The *main joint* of the arch is the talocalcaneonavicular joint.

Lateral Longitudinal Arch

This arch is characteristically low, has limited mobility, and is built to transmit weight and thrust to the ground. It is considered as a small arc of a big circle. This is in contrast to the medial longitudinal arch which acts as

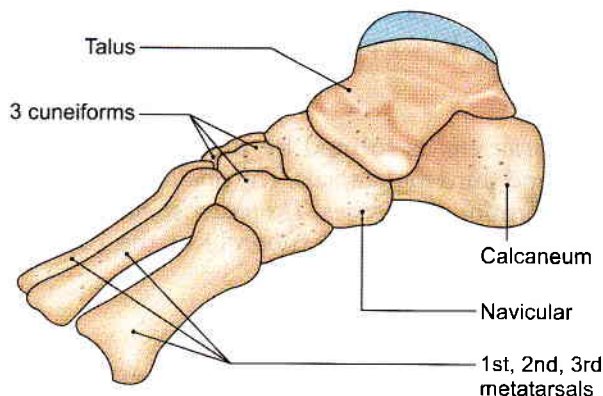


Fig. 13.3: Bones forming the medial longitudinal arch of foot: Medial view

a shock absorber. The constitution of the lateral longitudinal arch is as follows.

Ends

The *anterior end* of the arch is formed by the heads of the 4th and 5th metatarsal bones. The *posterior end* is formed by the lateral tubercle of the calcaneum (Fig. 13.4).

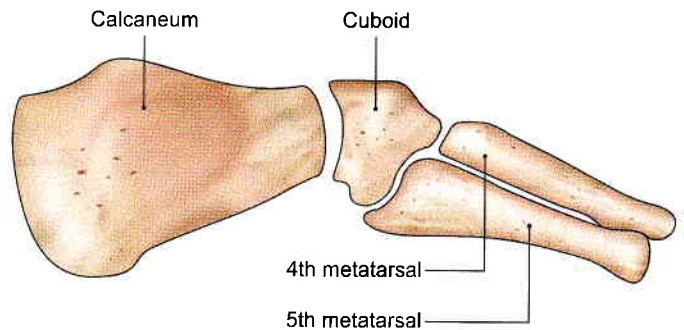


Fig. 13.4: Bones forming the lateral longitudinal arch of foot: Lateral view

Summit

The *summit* lies at the level of the articular facets on the superior surface of the calcaneum at the level of the subtalar joint.

Pillars

The *anterior pillar* is long and weak. It is formed by the cuboid bone and by the 4th and 5th metatarsals. The *posterior pillar* is short and strong. It is formed by the lateral half of the calcaneum.

Main Joint

The *main joint* of the arch is the calcaneocuboid joint.

Anterior Transverse Arch

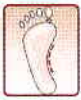The *anterior transverse arch* is formed by the heads of the five metatarsal bones. It is complete because the heads of the first and fifth metatarsals both come in contact with the ground, and form the two ends of the arch.

Posterior Transverse Arch

The *posterior transverse arch* is formed by the greater parts of the tarsus and metatarsus. It is incomplete because only the lateral end comes in contact with the ground, the arch forming a 'half dome' which is completed by a similar half dome of the opposite foot.

FACTORS RESPONSIBLE FOR MAINTENANCE OF ARCHES

In general, the factors helping in maintaining the various arches are as follows:



- 1 Shape of the bones concerned.
- 2 *Intersegmental ties/staples* or ligaments (and muscles) that hold the different segments of the arch together.
- 3 *Tie beams* or *bowstrings* that connect the two ends of the arch.
- 4 *Slings* that keep the summit of the arch pulled up. Each of these factors is considered below.
- 5 Suspension

Bony Factor

The posterior transverse arch is formed, and maintained mainly because of the fact that many of the tarsal bones involved (e.g. the cuneiform bones), and the heads of the metatarsal bones, are wedge-shaped, the apex of the wedge pointing downwards.

The bony factor is not very important in the case of the other arches.

Intersegmental Ties

All arches are supported by the ligaments uniting the bones concerned. The most important of these are as follows:

- 1 The spring ligament for the medial longitudinal arch (Fig. 13.5).
- 2 The long and short plantar ligaments for the lateral longitudinal arch (see Fig. 12.23).
- 3 In the case of the transverse arch, the metatarsal bones are held together by the interosseous muscles also.

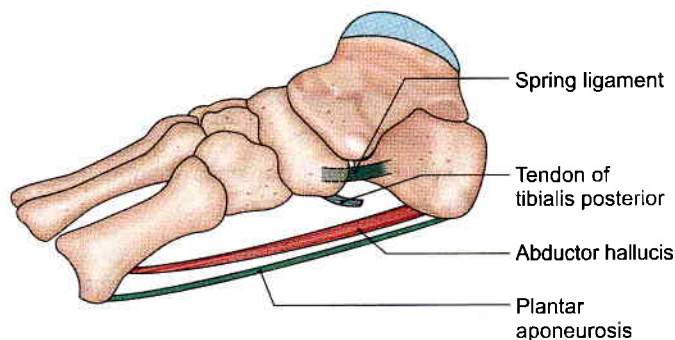


Fig. 13.5: Scheme showing some factors maintaining the medial longitudinal arch of the foot

Tie Beams

The longitudinal arches are prevented from flattening by the plantar aponeurosis, and by the muscles of the first layer of the sole. These structures keep the anterior and posterior ends of these arches pulled together. In the case of the transverse arch, the adductor hallucis acts as a tie beam (see Figs 10.4a and 10.6a).

Slings

- 1 The summit of the medial longitudinal arch is pulled upwards by tendons passing from the posterior

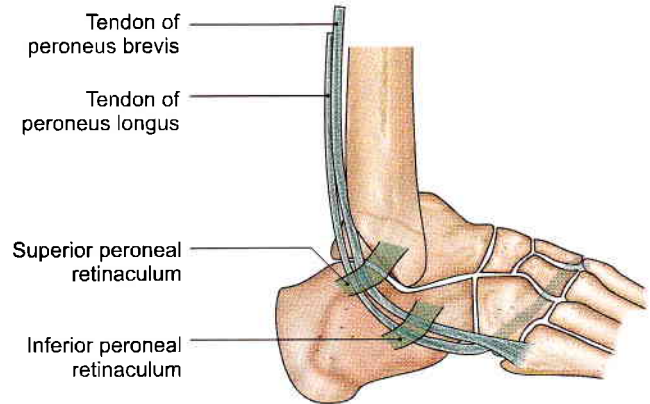


Fig. 13.6: Peroneal tendons helping to support the lateral longitudinal arch of the foot

compartment of the leg into the sole, i.e. tibialis posterior, flexor hallucis longus, flexor digitorum longus (Fig. 13.7).

- 2 The summit of the lateral longitudinal arch is pulled upwards by the peroneus longus and peroneus brevis (Fig. 13.6).
- 3 The tendons of tibialis anterior and peroneus longus together form a sling (stirrup) which keeps the middle of the foot pulled upwards, thus supporting the longitudinal arches.
- 4 As the tendon of the peroneus longus runs transversely across the sole, it pulls the medial and lateral margins of the sole closer together, thus maintaining the transverse arches. The transverse arch is also supported by tibialis posterior which grips many of the bones of the sole through its slips (Fig. 13.7).

Suspension

- 1 Medial longitudinal arch — Tibialis anterior
- 2 Lateral longitudinal arch — Peroneus longus.

FUNCTIONS OF ARCHES

- 1 The arches of the foot distribute body weight to the weight-bearing areas of the sole, mainly the heel and the toes. Out of the latter, weight is borne mainly on the first and fifth toes. The lateral border of the foot bears some weight, but this is reduced due to the presence of the lateral longitudinal arch.
- 2 The arches act as springs (chiefly the medial longitudinal arch) which are of great help in walking and running.
- 3 They also act as shock absorbers in stepping and particularly in jumping.
- 4 The concavity of the arches protects the soft tissues of the sole against pressure.
- 5 The character of medial longitudinal arch is resiliency and that of lateral longitudinal arch is rigidity.

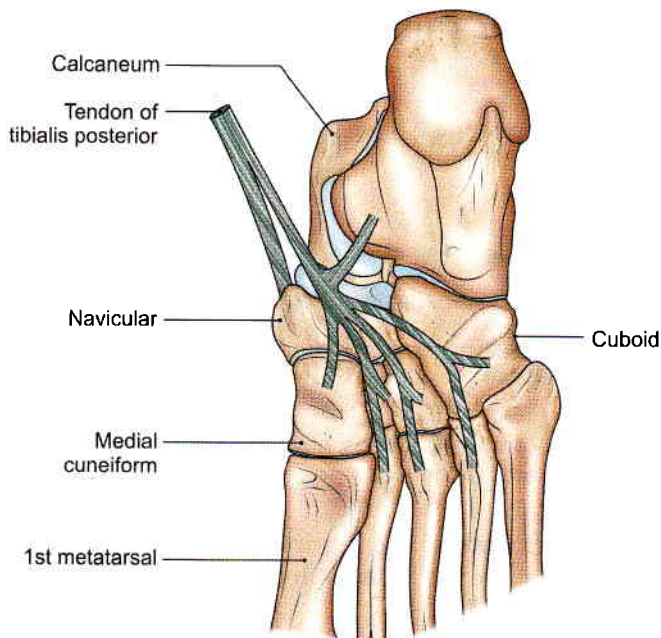


Fig. 13.7: Insertion of the tibialis posterior. Note the slips passing to all tarsal bones (except the talus) and to the middle three metatarsals

SUMMARY

The arches of the foot are well known features of the foot. There are two longitudinal arches, i.e. medial longitudinal arch and lateral longitudinal arch (Table 13.1).

In addition there are two transverse arches, i.e. posterior transverse arch and an anterior transverse arch (Table 13.2).

The *medial longitudinal arch* is the most important and is primarily affected in pes planus and pes cavus.

This arch is formed by the calcaneus, navicular, three cuneiforms and medial three metatarsals.

Flattening of the arch is common and is assessed clinically.

The medial arch is supported by:

- Spring ligament which supports the head of the talus.
- Plantar aponeurosis: Acts as a tie beam.
- Abductor hallucis and flexor digitorum brevis which act as spring ties.
- Tibialis anterior which lifts the centre of the arch. This muscle also forms a stirrup like support with the help of peroneus longus muscle.
- Tibialis posterior adducts the mid-tarsal joint and supports the spring ligament.
- Flexor hallucis longus extending between the anterior and posterior ends also supports the head of talus.

The *lateral longitudinal arch* is formed by calcaneum, cuboid, 4th and 5th metatarsals. It is rather shallow and gets flattened on weight bearing.

- This arch is supported by long plantar ligament, short plantar ligament. Plantar aponeurosis acts as a tie beam.
- Flexor digitorum brevis, flexor digiti minimi and abductor digiti minimi act as tie beams.
- Peroneus longus, peroneus brevis and peroneus tertius support this arch.

Table 13.1: Comparison of medial longitudinal arch and lateral longitudinal arch

	<i>Medial longitudinal arch</i>	<i>Lateral longitudinal arch</i>
Features	Higher, more mobile, resilient and shock absorber	Lower, limited mobility transmits weight, rigid
Anterior end	Heads of 1st, 2nd, 3rd metatarsal bones	Heads of 4th, 5th metatarsals
Posterior end	Medial tubercle of calcaneum	Lateral tubercle of calcaneum
Summit	Superior articular surface of talus	Articular facet on superior surface of calcaneum at level of subtalar joint
Anterior pillar	Talus, navicular, 3 cuneiforms and 1–3 metatarsals	Cuboid and 4th, 5th metatarsals
Posterior pillar	Medial half of calcaneum	Lateral half of calcaneum
Main joint	Talocalcaneonavicular joint	Calcaneocuboid joint
Bony factor	Wedge-shaped	Wedge-shaped
Intersegmental ties	Spring ligament	Long plantar ligament Short plantar ligament
Tie beams	Plantar aponeurosis (medial part) Abductor hallucis Medial part of flexor digitorum brevis	Plantar aponeurosis (lateral part) Abductor digiti minimi Lateral part of flexor digitorum brevis
Slings	Tibialis posterior Flexor hallucis longus Flexor digitorum longus	Peroneus longus Peroneus brevis
Suspension	Sling formed by tibialis anterior and peroneus longus	Sling formed by tibialis anterior and peroneus longus



Table 13.2: Comparison of anterior transverse arch and posterior transverse arch

	<i>Anterior transverse arch</i>	<i>Posterior transverse arch</i>
Formation	Heads of 1st to 5th metatarsals	Navicular, 3 cuneiforms, bases and shafts of metatarsals
Features	Complete arch	Incomplete. Arch is half dome raised medially
Bony factor	Round-shaped	Wedge-shaped
Intersegmental ties	Dorsal interosseous muscles	Dorsal interosseous muscles
Tie beams	Adductor hallucis Deep transverse metatarsal ligaments	Flexor hallucis brevis Intertarsal and tarsometatarsal ligaments
Slings	Peroneus longus Tibialis posterior	Peroneus longus Tibialis posterior

Posterior transverse arch is formed by three cuneiforms and cuboid. This arch extends across the sole in a coronal plane. It is only a half arch, the other half gets completed by the other foot. This arch is supported by the ligaments binding the bones. It gets specific support from the tendon of peroneus longus as it extends from the lateral side to the medial side of the sole

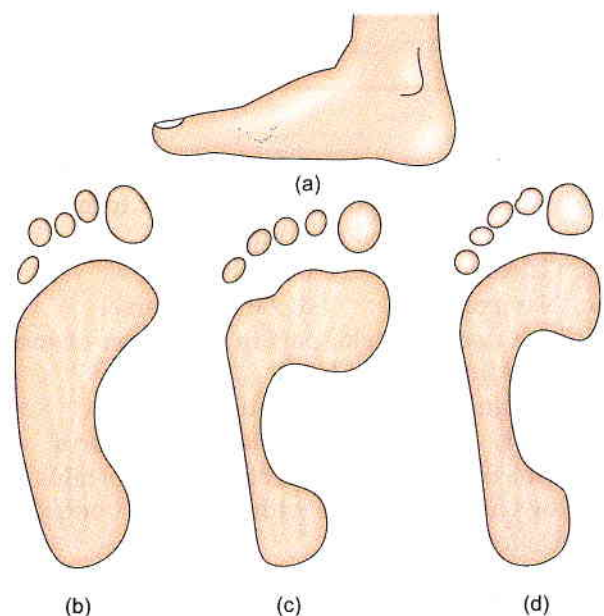
Anterior transverse arch also lies in coronal plane. It is formed by the heads of five metatarsals. During weight bearing, the metatarsal heads flatten out.

This arch is supported by intermetatarsal ligaments and the intrinsic muscles of the sole. The transverse head of adductor hallucis holds the heads of metatarsals together (see Fig. 10.6a).

CLINICAL ANATOMY

- Absence or collapse of the arches leads to flat foot (*pes planus*), which may be congenital or acquired. The effects of a flat foot are as follows.
 - a. Loss of spring in the foot leads to a clumsy, shuffling gait.
 - b. Loss of shock absorbing function makes the foot more liable to trauma and osteoarthritis.
 - c. Loss of the concavity of the sole leads to compression of the nerves and vessels of the sole. Compression of the communication between the lateral and medial plantar nerves causes neuralgic pain in the forefoot (*metatarsalgia*). Compression of blood vessels may cause vascular disturbances in the toes.
- Exaggeration of the longitudinal arches of the foot is known as *pes cavus*. This is usually a result of contracture (*plantar flexion*) at the transverse tarsal joint. When dorsiflexion of the metatarsophalangeal joints, and plantar flexion of the interphalangeal joints (due to atrophy of lumbricals and interossei) are superadded, the condition is known as *claw-foot*. The common causes of *pes cavus* and *claw-foot* are spina bifida and poliomyelitis (Figs 13.8a to d and 13.9).

- Other deformities of the foot are as follows.
 - a. *Talipes equinus* in which the patient walks on toes, with the heel raised.
 - b. *Talipes calcaneus* in which the patient walks on heel, with the forefoot raised.
 - c. *Talipes varus* in which the patient walks on the outer border of foot which is inverted and adducted (see Fig. 10.13).
 - d. *Talipes valgus* in which the patient walks on inner border of foot which is everted and abducted.
 - e. Commonest deformity of the foot is *talipes equinovarus (club foot)*. In this condition the foot is inverted, adducted and plantar flexed. The condition may be associated with spina bifida.
- *Talipes (club foot)* may be of two types: *Talipes calcaneovalgus*—foot is dorsiflexed at ankle joint, everted at midtarsal joints.
- *Talipes equinovarus*—foot is plantar flexed at ankle joint and inverted at midtarsal joints (Fig. 13.10).



Figs 13.8a to d: (a), (b) Flat feet, (c) pes cavus, and (d) normal

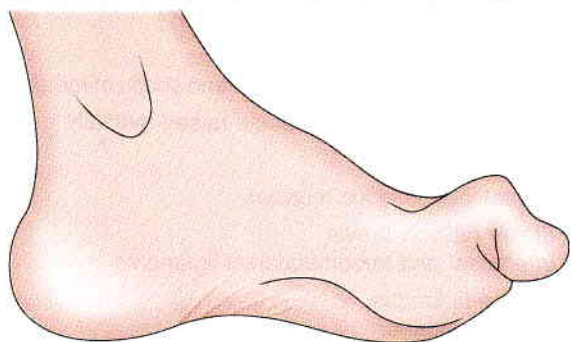


Fig. 13.9: Claw-foot/pes cavus

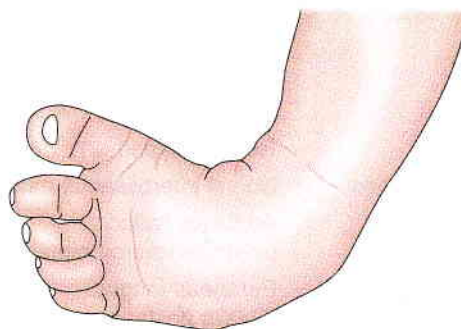

Fig. 13.10: Club foot/talipes equinovarus

FACTS TO REMEMBER

- Talus is the summit of medial longitudinal arch of the foot.
- Important joint of medial longitudinal arch is talocalcaneonavicular joint
- Main supports of this arch are tibialis posterior, tibialis anterior and peroneus longus muscles
- Important ligaments of the arch are spring or plantar calcaneonavicular, interosseous talocalcanean
- Arches distribute the weight evenly to the ground
- Great toe through its two sesamoid bones transfers double the weight of the other toes.
- Important joint of lateral longitudinal arch is calcaneocuboid joint. Its main supports are tendon of peroneus longus, long plantar and short plantar ligaments.
- Posterior transverse arch is supported by tendon of peroneus longus muscle.
- Anterior transverse arch is supported by deep metatarsal ligaments and dorsal interossei muscles.

CLINICOANATOMICAL PROBLEM

A young adult was disqualified in his medical examination of the army due to his flat feet

- What are flat feet?
- Name the factors maintaining the medial longitudinal arch of the foot

Ans: When the feet do not show the upward concavity along the medial border of foot, the foot is called "flat foot". If such a person puts his wet feet on the ground, there will be impression of the whole foot. Flat foot persons cannot run as fast as arched foot persons. The in army persons are required to run fast, so a flat foot person may be disqualified.

Factors maintaining medial longitudinal arch of the foot are:

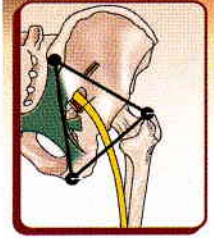
1. Proper shape of the bones, e.g. talus, calcaneum.
2. Ligaments like spring ligament, deltoid ligaments
3. Short muscles like abductor hallucis, flexor hallucis brevis, dorsal interossei
4. Long tendons like flexor hallucis longus, tibialis posterior, peroneus longus, tibialis anterior.

MULTIPLE CHOICE QUESTIONS

1. All of following bones takes part is formation of lateral longitudinal arch *except*:
 - a. Calcaneum
 - b. Cuboid
 - c. Navicular
 - d. 4th metatarsal
2. Which does not take part in formation of medial longitudinal arch of foot?
 - a. Calcaneum
 - b. Cuboid
 - c. Talus
 - d. Medial cuneiform
3. The major ligament that supports head of talus from below, as it articulates with navicular bone is:
 - a. Deltoid ligament
 - b. Plantar calcaneonavicular ligament.
 - c. Anterior talofibular ligament
 - d. Posterior talofibular ligament
4. Main muscular support of medial longitudinal arch is the following *except*:
 - a. Tibialis posterior
 - b. Flexor hallucis longus
 - c. Peroneus brevis
 - d. Flexor digitorum longus
5. Main muscular support of lateral longitudinal arch is following *except*:
 - a. Peroneus longus
 - b. Peroneus brevis
 - c. Peroneus tertius
 - d. Extensor digitorum brevis

ANSWERS

1. c 2. b 3. b 4. c 5. d



Surface and Radiological Anatomy

God gave you a gift of 86,400 seconds today. Have you used one to say, Thank You?

—WA Ward

SURFACE MARKING OF ARTERIES

Femoral Artery

It corresponds to the upper two-thirds of a line joining the following two points.

- **Midinguinal point:** A point midway between the anterior superior iliac spine and the pubic symphysis (Fig. 14.1).
- **Adductor tubercle:** It lies at the lower end of the cord-like tendon of the adductor magnus. The tendon can be felt in a shallow groove just behind the prominence of the vastus medialis *when the thigh is semiflexed, abducted and laterally rotated.*

The upper one-third of the line represents the upper half of the artery lying in the femoral triangle. The middle one-third of the line represents the lower half

of the artery lying in the adductor canal. The lower one-third of the line represents the descending genicular and saphenous branches of the artery.

Profunda Femoris Artery

First mark the femoral artery. The profunda artery is then marked by joining the following two points on the femoral artery (Fig. 14.1).

- **First point:** 3.5 cm below the midinguinal point.
 - **Second point:** 10 cm below the midinguinal point.
- The artery is slightly convex laterally in its upper part.

Popliteal Artery

It is marked by joining the following points.

- **First point:** At the junction of the middle and lower thirds of the thigh, 2.5 cm medial to the midline on the back of the limb (Fig. 14.2).
- **Second point:** On the midline of the back of the knee.
- **Third point:** On the midline of the back of leg at the level of the tibial tuberosity.

Superior Gluteal Artery

Mark the following points.

- **First point:** At the posterior superior iliac spine.
- **Second point:** At the apex of the greater trochanter (Fig. 14.3).

The superior gluteal artery enters the gluteal region at the junction of the upper and middle thirds of the line joining points (1st) and (2nd).

Inferior Gluteal Artery

Mark the following points.

- **First point:** Posterior superior iliac spine.
- **Second point:** Ischial tuberosity.

Then mark a third point 2.5 cm lateral to the midpoint of the line joining 1st and 2nd points. The sciatic nerve

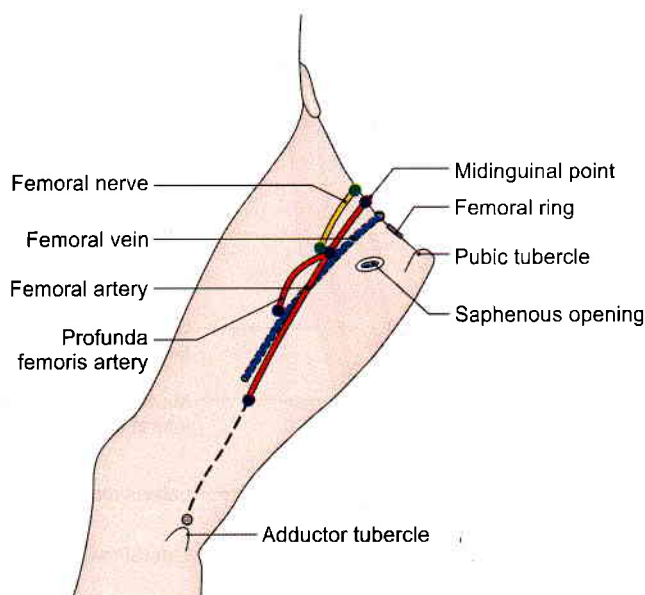


Fig. 14.1: Femoral vessels, profunda femoris artery, femoral nerve, femoral ring and saphenous opening in the thigh

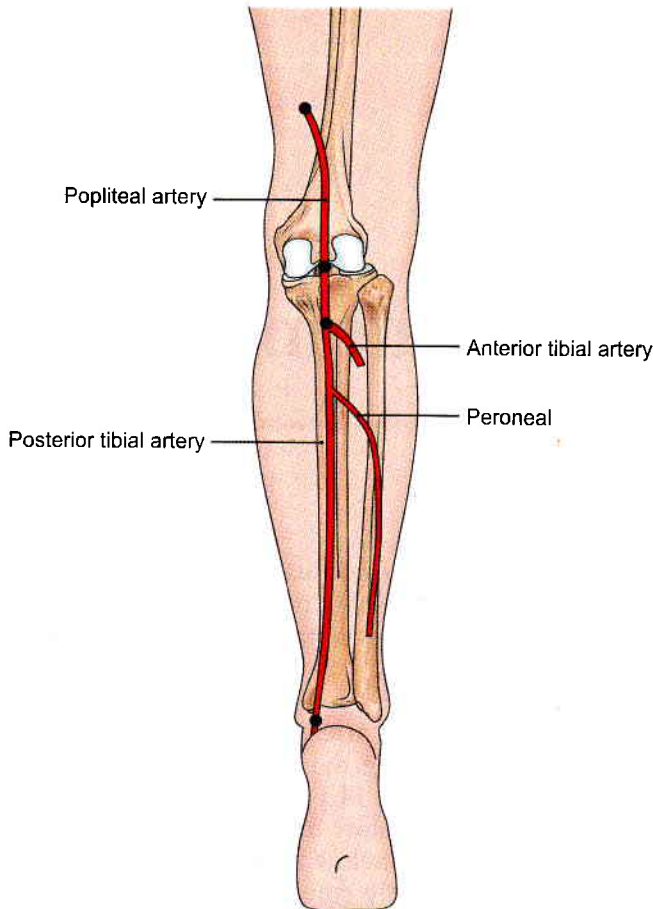


Fig. 14.2: Surface marking of popliteal, posterior tibial

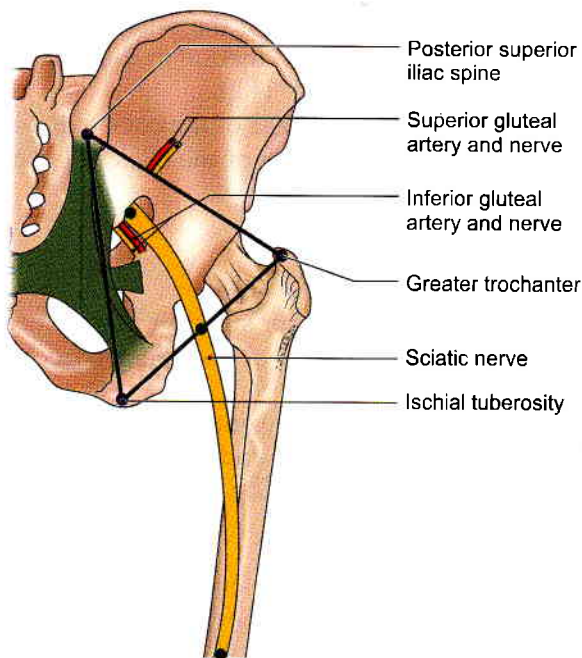


Fig. 14.3: Surface marking of sciatic nerve gluteal arteries and nerves

enters the gluteal region at this point. The inferior gluteal artery appears just medial to the entry of the sciatic nerve (Fig. 14.3).

Anterior Tibial Artery

It is marked by joining the following two points.

- *First point:* 2.5 cm below the medial side of the head of the fibula (Fig. 14.4).
- *Second point:* Midway between the two malleoli. The artery passes downwards and slightly medially.

Posterior Tibial Artery

It is marked by joining the following two points.

- *First point:* On the midline of the back of the leg at the level of the tibial tuberosity.
- *Second point:* Midway between the medial malleolus and the tendocalcaneus (Fig. 14.2).

Dorsalis Pedis Artery

It is marked by joining the following two points.

- *First point:* Midway between the two malleoli.
- *Second point:* At the proximal end of the first intermetatarsal space (Fig. 14.4).

Medial Plantar Artery

It is marked by joining the following two points.

- *First point:* Midway between the medial malleolus and the prominence of the heel.
- *Second point:* On the navicular bone which lies midway between the back of the heel and the root of

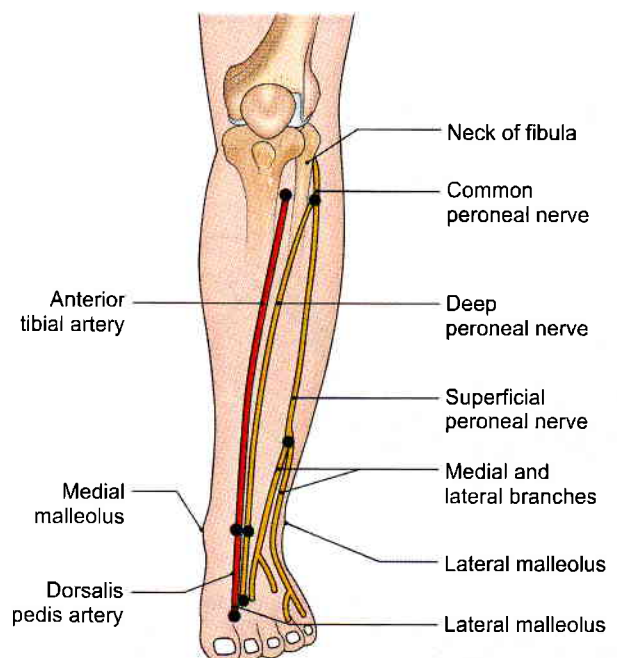


Fig. 14.4: Surface marking of anterior tibial, dorsalis pedis arteries; deep and superficial peroneal nerves

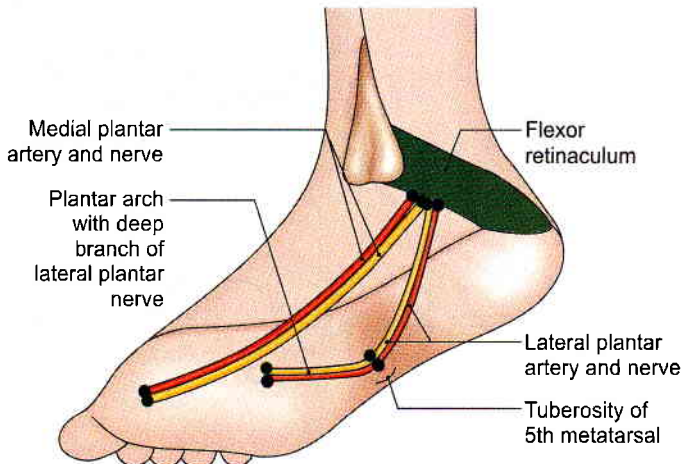


Fig. 14.5: Surface marking of medial and lateral plantar nerves and vessels, including the plantar arch

the big toe. The artery runs in the direction of the first interdigital cleft (Fig. 14.5).

Lateral Plantar Artery

It is marked by joining the following two points.

- *First point:* Midway between the medial malleolus and the prominence of the heel.
- *Second point:* 2.5 cm medial to the tuberosity of the fifth metatarsal bone (Fig. 14.5).

Plantar Arch

It is marked by joining the following two points.

- *First point:* 2.5 cm medial to the tuberosity of the fifth metatarsal bone.
- *Second point:* At the proximal end of the first intermetatarsal space, 2.5 cm distal to the tuberosity of the navicular bone (Fig. 14.5).

The arch is slightly curved with its convexity directed forwards.

VEINS

Femoral Vein

Its marking is same as that of the femoral artery, except that the upper point is taken 1 cm medial to the midinguinal point, and the lower point 1 cm lateral to the adductor tubercle. The vein is medial to the artery at the upper end, posterior to it in the middle, and lateral to it at the lower end (Fig. 14.1).

Great Saphenous Vein

It can be marked by joining the following points, although it is easily visible in living subjects.

- 1 *First point:* On the dorsum of the foot at the medial end of the dorsal venous arch.

- 2 *Second point:* On the anterior surface of the medial malleolus.
- 3 *Third point:* On the medial border of the tibia at the junction of the upper two-thirds and lower one-third of the leg.
- 4 *Fourth point:* At the adductor tubercle.
- 5 *Fifth point:* Just below the centre of the saphenous opening (Fig. 14.6).

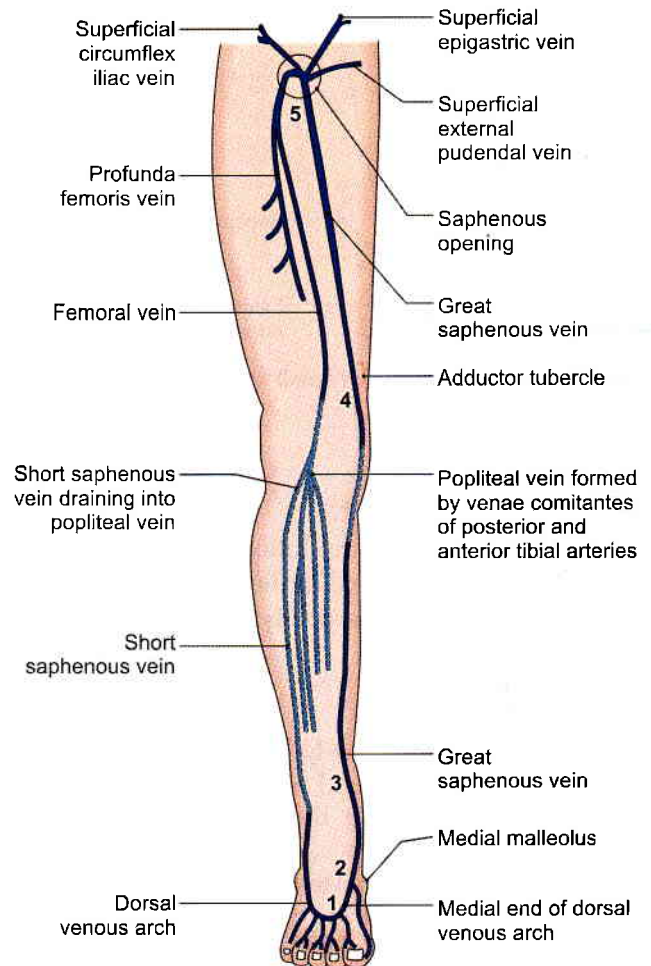


Fig. 14.6: Scheme to show the arrangement of the veins of the lower limb (see text)

Small Saphenous Vein

It can be marked by joining the following points, although this vein is also easily visible in its lower part (Fig. 14.7).

- 1 *First point:* On the dorsum of the foot at the lateral end of the dorsal venous arch.
- 2 *Second point:* Behind the lateral malleolus.
- 3 *Third point:* Just lateral to the tendocalcaneus above the lateral malleolus.
- 4 *Fourth point:* At the centre of the popliteal fossa.

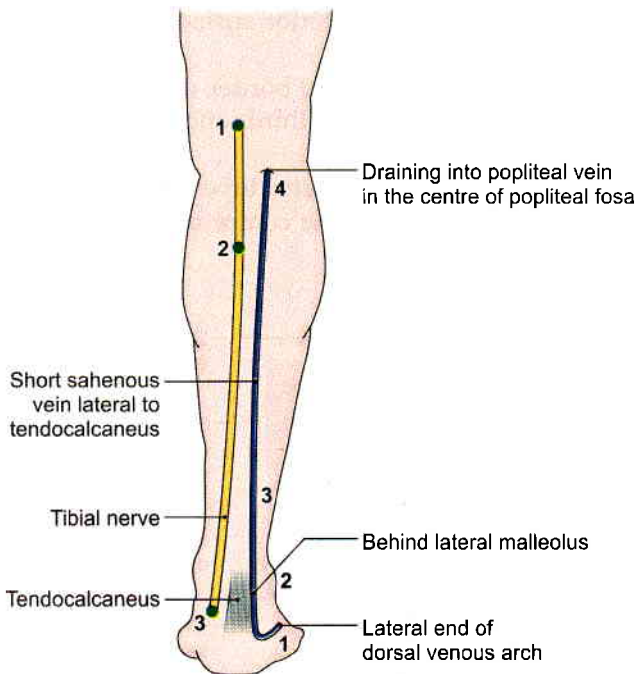


Fig. 14.7: Surface marking of small saphenous vein (see text)

NERVES

Femoral Nerve

It is marked by joining the following two points.

- **First point:** 1.2 cm lateral to the midinguinal point.
- **Second point:** 2.5 cm vertically below the first point (Fig. 14.1).

Sciatic Nerve

It is marked by joining the following points.

- **First point:** 2.5 cm lateral to the midpoint between the posterior superior iliac spine and the ischial tuberosity (Fig. 14.3).
- **Second point:** Just medial to the midpoint between the ischial tuberosity and the greater trochanter.
- **The third point:** In the midline of the back of the thigh at the junction of its upper two-thirds and lower one-third, i.e. at the apex of the popliteal fossa.

Tibial Nerve

Mark the following points.

- **First point:** In the midline of back of the thigh at the junction of its upper two-thirds and lower one-third, i.e. at the apex of the popliteal fossa.
- **Second point:** In the midline of back of the leg at the level of tibial tuberosity (Fig. 14.7).
- **Third point:** Midway between the medial malleolus and tendocalcaneus.

The line joining (1) and (2) represents the tibial nerve in the popliteal fossa, and the line joining (2) and (3) represents it in the back of the leg.

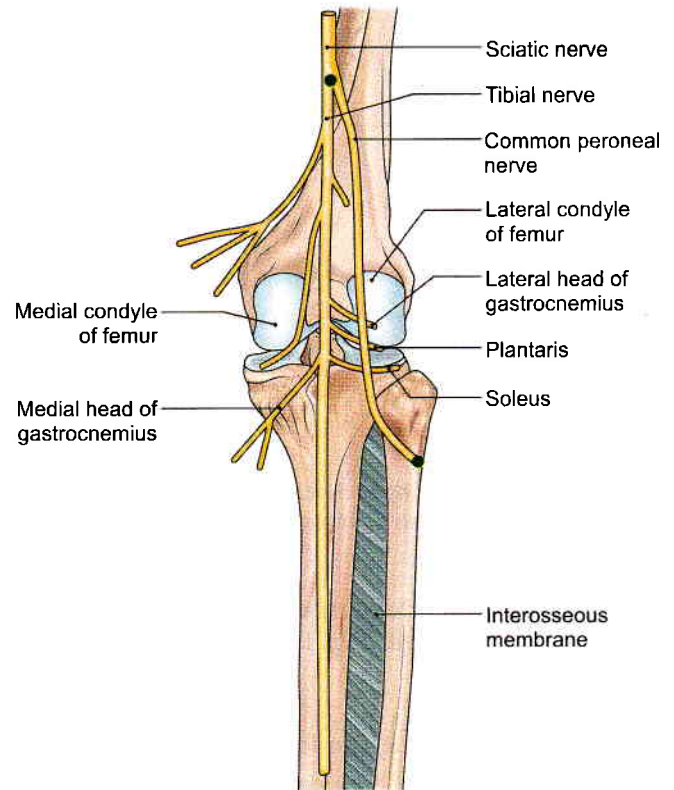


Fig. 14.8: Tibial and common peroneal nerves

Common Peroneal Nerve

It is marked by joining the following two points.

- **First point:** At the apex of the popliteal fossa (Fig. 14.8).
- **Second point:** On the back of the neck of the fibula (see Fig. 7.7).

At the lower end the nerve turns forwards and ends deep to the upper fibres of the peroneus longus.

Deep Peroneal Nerve

It is marked by joining the following two points.

- **First point:** On the lateral aspect of the neck of the fibula (Fig. 14.4).
- **Second point:** In front of the ankle, midway between the two malleoli.
- **Third point:** First interosseous space

The nerve lies lateral to the anterior tibial artery in its upper and lower thirds, but anterior to the artery in its middle-third.

Superficial Peroneal Nerve

It is marked by joining the following two points.

- **First point:** On the lateral aspect of the neck of the fibula (Fig. 14.4).
- **Second point:** On the anterior border of the peroneus longus at the junction of the upper two-thirds and lower one-third of the leg.



At the lower point the nerve pierces the deep fascia and divides into medial and lateral branches.

Medial Plantar Nerve

It is marked in a manner similar to the medial plantar artery (Fig. 14.5). Lies lateral to the artery.

Lateral Plantar Nerve

It is marked in a manner similar to that for the lateral plantar artery (Fig. 14.5). Lies medial to the artery.

MISCELLANEOUS STRUCTURES

Saphenous Opening

Its centre lies 4 cm below and 4 cm lateral to the pubic tubercle. It is about 2.5 cm long and 2 cm broad, with its long axis directed downwards and laterally (Fig. 14.1).

Femoral Ring

It is represented by a horizontal line 1.25 cm long over the inguinal ligament, 1.25 cm medial to the midinguinal point (Fig. 14.1).

Superior Extensor Retinaculum

The retinaculum is about 3 cm broad vertically. It is drawn from:

- 1 The anterior border of the triangular subcutaneous area of the fibula.
- 2 The lower part of the anterior border of the tibia, running medially and slightly upwards (Fig. 14.9).

Inferior Extensor Retinaculum

- 1 The *stem* is about 1.5 cm broad. It extends from the anterior part of the upper surface of the calcaneum to a point medial to the tendon of the extensor digitorum longus on the dorsum of the foot.
- 2 The *upper band* is about 1 cm wide, and extends from the medial end of the stem to the anterior border of the medial malleolus (Fig. 14.9).
- 3 The *lower band* is also about 1 cm wide. It extends from the medial end of the stem to the medial side of the foot, extending into the sole.

Flexor Retinaculum

It is about 2.5 cm broad, and extends from:

- 1 The medial malleolus
- 2 The medial side of the heel, running downwards and backwards (Fig. 14.10).

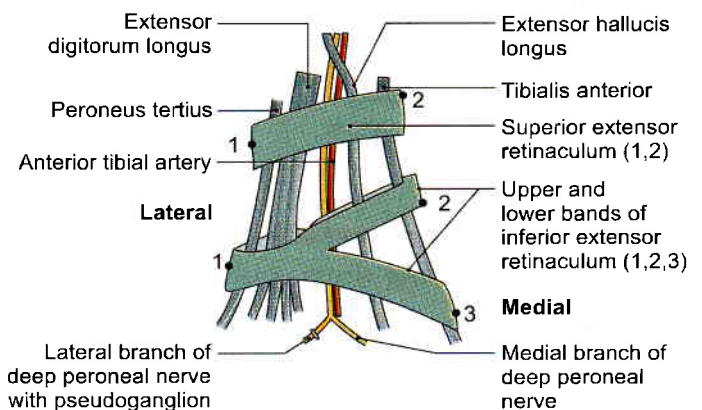


Fig. 14.9: Superior and inferior extensor retinacula of the ankle, surface view

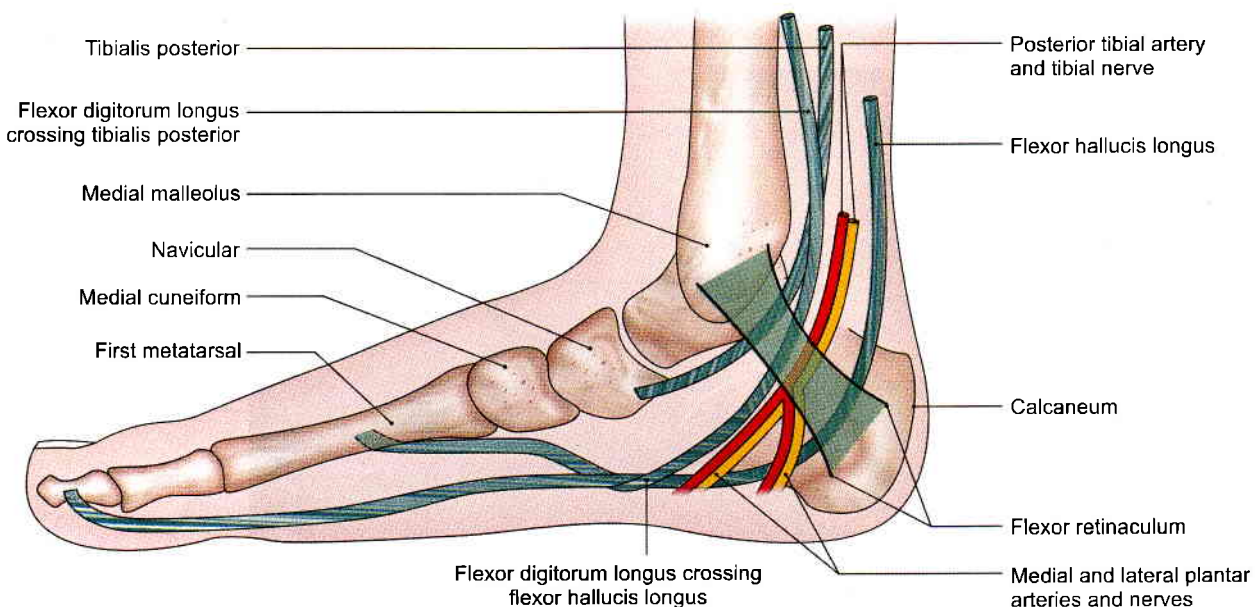


Fig. 14.10: Flexor retinaculum of the ankle, and the structures passing deep to it



RADIOLOGICAL ANATOMY

In the study of plain skiagrams of the limbs, the following points should be noted.

- 1 View of the radiograph.
- 2 Identification of all bones visible.
- 3 Normal relations of the bones forming joints and the radiological 'joint space'.
- 4 The presence of epiphyses in the young bones.

Briefly, such skiagrams are helpful in the diagnosis of the following.

- a. Fractures.
- b. Dislocations.
- c. Diseases.
 - i. Infective (osteomyelitis),
 - ii. Degenerative (osteoarthritis),
 - iii. Neoplastic (benign and malignant),
 - iv. Deficiency (rickets and scurvy).
- d. Developmental defects.
- e. The age below 25 years.

HIP

Identify the Following Bones in AP View

- 1 *Hip bone*, including ilium, pubis, ischium and acetabulum.
- 2 *Upper end of femur*, including the head, neck, greater trochanter, lesser trochanter, and upper part of shaft. The *neck-shaft angle* is about 125 degrees in adults, being more in children (140°) and less in females. In the head, a dense wedge or triangle of cancellous bone is known as *Ward's triangle*. It represents the epiphyseal scar.

Give X-ray photo

Calcar femorale is a dense plate of compact bone forming a buttress to strengthen the concavity of the neck-shaft angle in front of the lesser trochanter. It transmits weight from the head of femur to the *linea aspera*.

Cervical torus is a thickened band or ridge of compact bone on the upper part of the neck between the head and the greater trochanter.

- 3 The *lumbosacral spine* may have been included.

Study the Normal Appearance of the Following Joints

- 1 *Hip joint*: Normal relation of the head of femur with the acetabulum is indicated by the *Shenton's line*, which is a continuous curve formed by the upper border of obturator foramen and the lower border of the neck of femur (Fig. 14.11).

- 2 *Pubic symphysis*

- 3 *Sacroiliac joint*.

Note the epiphyses and other incomplete ossifications if any, and determine the age.

The ischiopubic rami fuse by 7–8 years, and the acetabulum is ossified by 17 years.

KNEE

Identify the Following Bones

- 1 *Lower end of femur*, including the two condyles (Figs 14.12 and 14.13).

- 2 *Patella* is clearly seen only in the lateral views; in AP views it overlaps the lower end of femur. It lies about 1 cm above the knee joint.

Bilateral separation of the superolateral angles of the patellae is known as *bipartite patella*. The small fragment may be further subdivided to form the multipartite

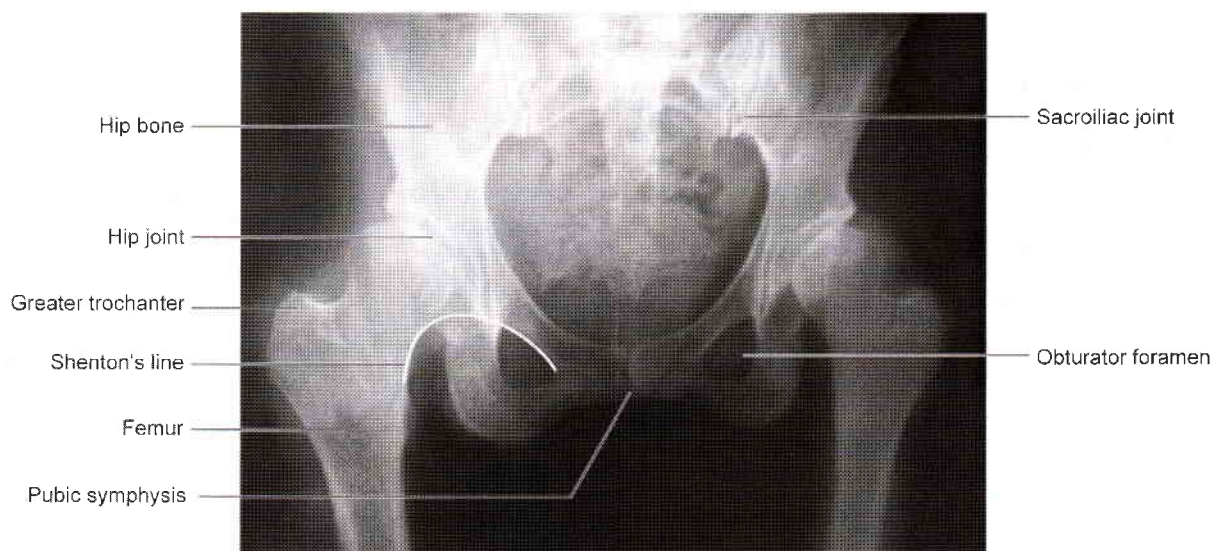

Fig. 14.11: Anteroposterior view of the female pelvis

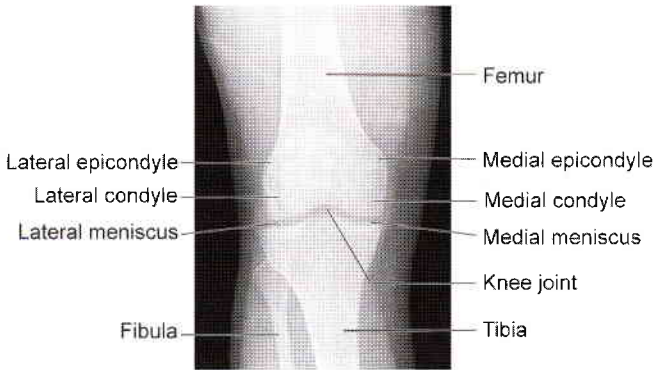


Fig. 14.12: Anteroposterior view of the knee joint

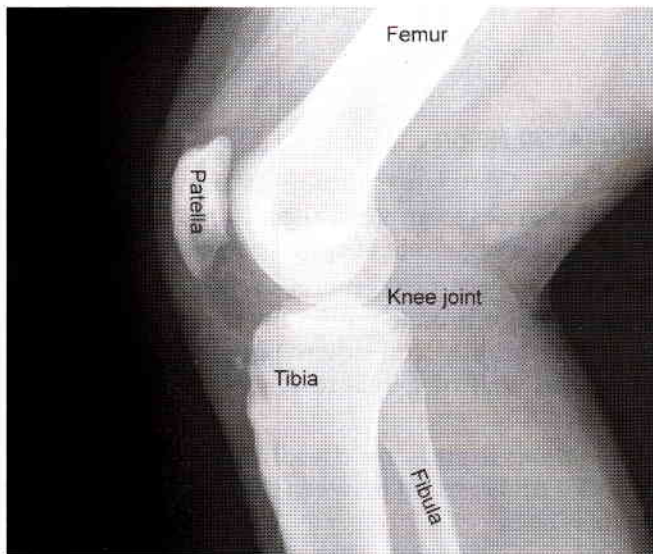


Fig. 14.13: Lateral view of the knee joint

patella. This is due to failure of the ossific centers to fuse.

In *emargination of patella*, its outer margin is concave. The concavity is bounded by a tubercle above and a spine below. This reflects the mode of attachment of the vastus lateralis.

- 3 *Upper end of tibia*, including the two condyles, intercondylar eminence and tibial tuberosity.
- 4 *Upper end of fibula*, including the head, neck and upper part of shaft.
- 5 *Fabella*: It is a small, rounded sesamoid bone in the lateral head of gastrocnemius. It articulates with the posterior surface of the lateral condyle of femur. It measures 1–1.5 cm in diameter, and is present in about 15% individuals. As a rule it is bilateral, and appears at 12–15 years of age.

Study the Normal Appearance of the Following Joints

- 1 *Knee joint*: The joint space varies inversely with the age. In young adults, it is about 5 mm. It is entirely due to articular cartilage and not due to menisci.
- 2 *Superior tibiofibular joint*.

Note the epiphyses if any, and determine the age with the help of ossification studied

FOOT

Identify the Following Bones

- 1 *Talus* and *calcaneum* are better seen in lateral view.
- 2 *Navicular* and *cuboid* are seen clearly in almost all the views (Fig. 14.14).
- 3 *Cuneiform bones* are seen separately in dorsoplantar views; they overlap each other in a lateral view.
- 4 *Metatarsals* and *phalanges* are seen separately in dorsoplantar views, but overlap each other in lateral views.
- 5 Sesamoid and accessory bones should be distinguished from fractures.

The common *sesamoids* are found on the plantar surface of the head of first metatarsal bone. They may also be present in the tendons of tibialis anterior, tibialis posterior and peroneus longus.

Accessory bones are separate small pieces of bone which have not fused with the main bone. For example, os trigonum (lateral tubercle of talus) and os vesalianum (tuberosity of fifth metatarsal bone).

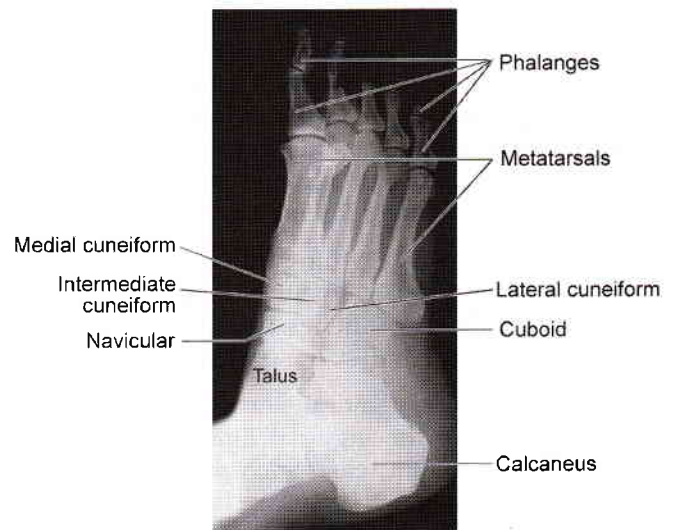
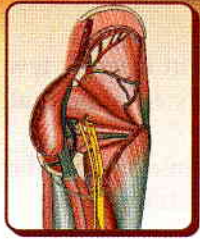


Fig. 14.14: Dorsoplantar view of the ankle and foot

Study the Normal Appearance of the Following Joints

- 1 Ankle joint.
- 2 Subtalar, talocalcaneonavicular and transverse tarsal joints.
- 3 Tarsometatarsal, intermetatarsal, metatarsophalangeal, and interphalangeal joints.

Note the epiphyses and other incomplete ossification if any, and determine the age.



Appendix 1

The chief function of your body is to carry your brain around
—Thomas Alva Edison

NERVES OF LOWER LIMB

FEMORAL NERVE

Femoral nerve is the nerve of anterior compartment of thigh. Its cutaneous branch, the saphenous nerve extends to the medial side of leg and medial border of foot till the ball of the big toe.

Root value: Dorsal division of ventral rami of L2, L3, L4 segments of spinal cord (see Figs 3.3 and 3.11).

Beginning and course: It emerges at the lateral border of psoas major muscle in abdomen. It passes downwards between psoas major and iliacus muscles. The nerve enters the thigh behind the inguinal ligament, lateral to femoral sheath. It is not a content of femoral sheath as its formation is behind fascia iliaca.

Termination: It ends by dividing into two divisions 2.5 cm below the inguinal ligament. Both these divisions end in a number of branches. In between the two divisions, lateral circumflex femoral artery is present.

Branches: In *abdomen*, femoral nerve supplies iliacus muscle. Just above the inguinal ligament, it gives a branch to pectineus muscle, which passes behind the femoral sheath to reach the muscle. Its branches in the thigh are shown in Table A1.1.

OBTURATOR NERVE

Root value: Obturator nerve is a branch of lumbar plexus. It arises from ventral division of ventral rami of L2, L3, L4 segments of spinal cord (see Fig. 4.4).

Beginning and course: It emerges on the medial border of psoas major muscle within the abdomen. It crosses the pelvic brim to run downwards and forwards on the lateral wall of pelvis to reach the upper part of obturator foramen.

Termination: It ends by dividing into anterior and posterior divisions. In between the divisions, adductor brevis is seen.

Anterior division: It passes downwards in front of obturator externus. Then it lies between pectineus and adductor longus anteriorly and adductor brevis posteriorly. It gives muscular, articular and vascular branches.

Posterior division: It pierces the obturator externus and passes behind adductor brevis and in front of adductor magnus. It also ends by giving muscular, articular and vascular branches.

The branches are shown in Table A1.2.

ACCESSORY OBTURATOR NERVE

It is present in 30% subjects (see Fig. 4.6).

Table A1.1: Branches of femoral nerve in thigh

	<i>Anterior/ Superficial division</i>	<i>Posterior / Deep division</i>
Muscular	Sartorius	Vastus medialis Vastus intermedius Vastus lateralis Rectus femoris
Cutaneous	Medial cutaneous nerve of thigh Intermediate cutaneous nerve of thigh	Saphenous (for medial side of leg and medial border of foot till ball of big toe)
Articular and vascular	Sympathetic fibres to femoral artery	Knee joint from branches to vasti Hip joint from branch to rectus femoris



Table A1.2: Branches of obturator nerve

	<i>Anterior division</i>	<i>Posterior division</i>
Muscular	Pectineus, adductor longus, adductor brevis, gracilis	Obturator externus, adductor magnus (adductor part)
Articular	Hip joint	Knee joint
Vascular and cutaneous	Femoral artery—Medial side of thigh	Popliteal artery

Root value: Ventral division of ventral rami of L3, L4 nerves.

Course: Runs along medial border of psoas major, crosses superior ramus of pubis behind pectineus muscle.

Branches: Deep surface of pectineus, hip joint and communicating branch to anterior division of obturator nerve (see Fig. 4.6).

SUPERIOR GLUTEAL NERVE

Root value: L4, L5, S1.

Course: Enters the gluteal region through greater sciatic notch above piriformis muscle. Runs between gluteus medius and gluteus minimus to end in tensor fasciae latae (see Fig. 5.14).

Branches: It supplies gluteus medius, gluteus minimus and tensor fasciae latae.

INFERIOR GLUTEAL NERVE

Root value: L5, S1, S2.

Course: Enters the gluteal region through greater sciatic notch below piriformis muscle (see Fig. 5.14).

Branches: It gives a number of branches to the gluteus maximus muscle only. It is the sole supply to the large antigravity, postural muscle with red fibres, responsible for extending the hip joint.

NERVE TO QUADRATUS FEMORIS

Root value: L4, L5, S1.

Branches: It supplies quadratus femoris, inferior gemellus and hip joint.

NERVE TO OBTURATOR INTERNUS

Root value: L5, S1, S2.

Branches: It supplies obturator internus and superior gemellus.

SCIATIC NERVE

Sciatic nerve is the thickest nerve of the body. It is the terminal branch of the lumbosacral plexus.

Root value: Ventral rami of L4, L5, S1, S2, S3. It consists of two parts (see Figs 5.6 and 5.14).

Tibial part: Its root value is ventral division of ventral rami of L4, L5, S1, S2, S3, segments of spinal cord (see Fig. 7.6).

Common peroneal part: Its root value is dorsal division of ventral rami of L4, L5, S1, S2 segments of spinal cord.

Course: Sciatic nerve arises in the pelvis. Leaves the pelvis by passing through greater sciatic foramen below the piriformis to enter the gluteal region (see Fig. 7.7).

In the gluteal region, it lies deep to the gluteus maximus muscle, and crosses superior gemellus, obturator internus, inferior gemellus, quadratus femoris to enter the back of thigh. During its short course, it lies between ischial tuberosity and greater trochanter with a convexity to the lateral side. It gives no branches in the gluteal region.

In the back of thigh, it lies deep to long head of biceps femoris and superficial to adductor magnus (see Fig. 7.7).

Termination: It ends by dividing into its two terminal branches in the back of thigh.

Branches: The branches of sciatic nerve are shown in Table A1.3.

TIBIAL NERVE

Root value: Ventral division of ventral rami of L4, L5, S1, S2, S3, segments of spinal cord.

Beginning: It begins as the larger subdivision of sciatic nerve in the back of thigh (see Fig. 6.7).

Course: It has a long course first in the popliteal fossa and then in the back of leg.

Popliteal fossa: The nerve descends vertically in the popliteal fossa from its upper angle to the lower angle.

Table A1.3: Branches of sciatic nerve

	<i>Gluteal region</i>	<i>Back of thigh; from tibial part</i>	<i>From common peroneal part</i>
Muscular	Nil	Long head of biceps femoris, semitendinosus, semimembranosus, ischial part of adductor magnus	Short head of biceps femoris
Articular	Nil	Hip joint	—
Terminal	Nil	Tibial and common peroneal nerves	—



It lies superficial to the popliteal vessels. It continues in the back of leg beyond the distal border of popliteus muscle (see Fig. 6.7).

In back of leg: The nerve descends as the neurovascular bundle with posterior tibial vessels. It lies superficial to tibialis posterior and deep to flexor digitorum longus. Lastly it passes deep to the flexor retinaculum of ankle (see Figs 9.2 and 9.7).

Branches: Its branches are shown in Table A1.4.

Termination: The tibial nerve terminates by dividing into medial plantar and lateral plantar nerves as it lies deep to the flexor retinaculum.

COMMON PERONEAL NERVE

This is the smaller terminal branch of sciatic nerve. Its root value is dorsal division of ventral rami of L4, L5, S1, S2 segments of spinal cord.

Beginning: It begins in the back of thigh as a smaller subdivision of the sciatic nerve.

Course: It lies in the upper lateral part of popliteal fossa, along the medial border of biceps femoris muscle. It turns around the lateral surface of fibula. Then it lies in the substance of peroneus longus muscle (see Fig. 6.4).

Branches: Its branches are shown in Table A1.5.

Termination: Ends by dividing into two terminal branches, i.e. superficial peroneal and deep peroneal nerves (see Fig. 8.9).

DEEP PERONEAL NERVE

The deep peroneal nerve is the nerve of the anterior compartment of the leg and the dorsum of the foot. It corresponds to the posterior interosseous nerve of the forearm. This is one of the two terminal branches of the common peroneal nerve given off between the neck of the fibula and the peroneus longus muscle.

Course and relations: The deep peroneal nerve begins on the lateral side of the neck of fibula under cover of

Table A1.5: Branches of common peroneal nerve in popliteal fossa

Muscular	— Short head of biceps femoris
Cutaneous and vascular	— Lateral cutaneous nerve of calf — Sural communicating
Articular	— Superior lateral genicular — Inferior lateral genicular — Recurrent genicular
Terminal	— Deep peroneal — Superficial peroneal

the upper fibres of peroneus longus. It enters the anterior compartment of leg by piercing the anterior intermuscular septum. It then pierces the extensor digitorum longus and comes to lie next to the anterior tibial vessels (see Fig. 14.4).

In the leg, it accompanies the anterior tibial artery and has similar relations. The nerve lies lateral to the artery in the upper and lower third of the leg, and anterior to the artery in the middle one-third.

The nerve ends on the dorsum of the foot, close to the ankle joint, by dividing into the lateral and medial terminal branches (see Fig. 8.4).

The lateral terminal branch turns laterally and ends in a pseudoganglion deep to the extensor digitorum brevis. Branches arise from the pseudoganglion and supply the extensor digitorum brevis and the tarsal joints.

The medial terminal branch ends by supplying the skin adjoining the first interdigital cleft and the proximal joints of the big toe.

Branches and distribution of the deep peroneal nerve:

Muscular branches: The muscular branches supply the following muscles.

1. Muscles of the anterior compartment of the leg. These include:
 - a. Tibialis anterior
 - b. Extensor hallucis longus

Table A1.4: Branches of tibial nerve

	Popliteal fossa	Back of leg
Muscular	— Medial head of gastrocnemius — Lateral head of gastrocnemius — Plantaris — Soleus — Popliteus. These are given in lower part of fossa	Soleus Flexor digitorum longus Flexor hallucis longus Tibialis posterior
Cutaneous and vascular	Sural nerve. This is given in middle of fossa	Medial calcaneal branches and branch to posterior tibial artery
Articular	— Superior medial genicular — Middle genicular — Inferior medial genicular. These are given in upper part of fossa	Ankle joint
Terminal	—	Medial plantar and lateral plantar nerves



- c. Extensor digitorum longus
d. Peroneus tertius.
- 2 The extensor digitorum brevis (on the dorsum of foot) is supplied by the lateral terminal branch of the deep peroneal nerve.

Cutaneous branches: The lateral terminal branch of the deep peroneal nerve ends by forming the dorsal digital nerves for the adjacent sides of the big toe and second toe (see Fig. 8.2).

Articular branches: These are given to the:

- 1 Ankle joint
- 2 Tarsal joints
- 3 Tarsometatarsal joint
- 4 Metatarsophalangeal joint of big toe.

SUPERFICIAL PERONEAL NERVE

It is the smaller terminal branch of the common peroneal nerve (see Fig. 8.9).

Origin: It arises in the substance of peroneus longus muscle, lateral to the neck of fibula.

Course: It descends in the lateral compartment of leg deep to peroneus longus. Then it lies between peroneus longus and peroneus brevis muscles and lastly between the peronei and extensor digitorum longus.

It pierces the deep fascia in distal one-third of leg and descends to the dorsum of foot.

Branches: It supplies both peroneus longus and peroneus brevis muscles.

It gives cutaneous branches (see Fig. 8.2) to most of the dorsum of foot including the digital branches to medial side of big toe, adjacent sides of 2nd and 3rd; 3rd and 4th and 4th and 5th toes. The nail beds are not supplied as these are supplied by medial plantar for medial 3½ and by lateral plantar for lateral 1½ toes. Adjacent sides of big and second toes are supplied by deep peroneal nerve. The medial border of foot is supplied by saphenous and lateral border by sural nerves.

PLANTAR NERVES

The medial and lateral plantar nerves are the terminal branches of the tibial nerve. These nerves begin deep to the flexor retinaculum.

Medial plantar nerve: It is the larger terminal branch of tibial nerve. Its distribution is similar to median nerve of the hand. It lies between abductor hallucis and flexor digitorum brevis and ends by giving muscular, cutaneous and articular branches (see Fig. 10.4b).

Branches: The branches of medial plantar nerve are shown in Table A1.6.

Lateral plantar nerve: It is the smaller terminal branch of tibial nerve, resembling the ulnar nerve of the hand in its distribution. It runs obliquely between the first and second layers of sole till the tuberosity of fifth metatarsal bone, where it divides into its superficial and deep branches (see Fig. 10.6b).

Branches: The structures supplied by the trunk, and its two branches are given in Table A1.7.

Table A1.6: Branches of medial plantar nerve

Medial plantar nerve (S2, S3)	
Muscular	— Abductor hallucis : 1st layer — Flexor digitorum brevis : 1st layer — First lumbrical : 2nd layer — Flexor hallucis brevis : 3rd layer
Cutaneous and vascular	— Nail beds of medial 3½ toes — Sympathetic branches to medial plantar artery
Articular	— Tarsometatarsal, metatarsophalangeal and interphalangeal joints of medial 2/3rd of foot

CLINICAL ANATOMY

- Femoral nerve supplying the quadriceps femoris through L2, L3, L4 segments of spinal cord is tested by doing the 'patellar jerk'. The ligamentum patellae is hit by the hammer and the contraction of the quadriceps is felt with extension of knee (see Fig. 3.30).
- Since obturator nerve supplies both the hip and knee joints, pain of one joint may be referred to the other joint.
- The paralysis of left superior gluteal nerve leads to paralysis of left gluteus medius and minimus

Table A1.7: Branches of lateral plantar nerve

	Trunk (S2, S3)	Superficial branch	Deep branch
Muscular	• Abductor digiti minimi: 1st layer • Flexor digitorum accessorius: 2nd layer	• Flexor digiti minimi brevis: 3rd layer • 3rd plantar interosseous: 4th layer • 4th dorsal interosseous: 4th layer	1st and 2nd plantar interossei: 4th layer 1st, 2nd, 3rd, dorsal interossei: 4th layer 2nd, 3rd, 4th lumbricals: 2nd layer Adductor hallucis: 3rd layer
Cutaneous and vascular	—	Nail beds of lateral 1½ toes Sympathetic branches to lateral plantar artery	—
Articular	Tarsometatarsal	Interphalangeal	Metatarsophalangeal



muscle. During walking when the body is supported on left foot, the right unsupported side of the pelvis droops, causing inability to walk with right foot. This is called *positive Trendelenburg's test* (see Fig. 5.12)

- *Sleeping foot*: Sometimes it happens that one is awake but the foot sleeps. Sciatic nerve lies on quadratus femoris and adductor magnus. Between the two muscles, the nerve lies on the hard femur. So the nerve gets pressed between the femur and the hard edge of table, chair or bed. There is numbness of the lower limb till the foot is hit against the ground a few times. The sensations come back (see Fig. 7.3).
- *Injury*: Injury to sciatic nerve leads to paralysis of hamstrings and all muscles of the leg and foot leading to "foot drop" (see Fig. 7.11).
- *Sciatica*: Is the name given when there is radiating pain in the back of lower limb. It may be due to slip disc.
- Common peroneal nerve is the commonest nerve to be paralysed. This is injured due to fracture of neck of fibula, 'lathi injury' on the lateral side of knee joint or due to plaster on the leg. In the last case, the nerve gets compressed between hard plaster and neck of fibula. To prevent this cotton must be placed on the upper lateral side of the leg (see Fig. 8.9).

The effects of injury are:

Motor loss: To dorsiflexors and evertors of foot. The typical position of the foot is "foot drop"; sensory loss is to the back of leg; lateral side of leg and most of dorsum of foot.

Articular loss to the lateral side of knee joint.

- Paralysis of muscles of the anterior compartment of the leg results in loss of the power of dorsiflexion of the foot. As a result the foot is plantar flexed. The condition is called as "foot drop" (see Fig. 8.10).

- The motor and sensory loss in case of injury to the various nerves is shown in Table A1.8.
- Thus most of the muscles of the lower limb are supplied by sciatic nerve except the adductors of thigh and extensors of knee joint.
- Arterial occlusive disease of the lower limb: Occlusive disease causes ischaemia of the muscles of lower limb leading to cramp-like pain. The pain disappears with rest but comes back with activity. The condition is called 'intermittent claudication'.
- Palpation of dorsalis pedis artery and posterior tibial artery gives information about peripheral arterial diseases (see Fig. 8.11).
- Sympathetic innervation of the arteries: Thoracic 10–12 and L1–L3 segments provide sympathetic innervation to arteries of lower limb. Preganglionic fibres relay in the ganglia associated with these segments. Postganglionic fibres reach blood vessels via branches of lumbar and sacral plexuses.
- Femoral artery receives postganglionic fibres from femoral and obturator nerves.
- Arteries of the leg receive postganglionic fibres via the tibial and common peroneal nerves.
- Lumbar sympathectomy for occlusive arterial disease: Sympathectomy, i.e. removal of L2 and L3 ganglia with intervening sympathetic trunk is advised for this condition. This increases the collateral circulation. L1 ganglion is not removed as it is responsible for ejaculation.
- Blood supply to muscles of back of thigh reaches through a rich anastomosis (see Fig. 7.14) formed by:
 - a. Superior gluteal artery
 - b. Inferior gluteal artery
 - c. Branches of femoral circumflex arteries
 - d. Perforating arteries
 - e. Branches of popliteal artery.
- Excessive fluid from knee joint can be aspirated by putting in a needle in the joint cavity from its lateral side.

Table A1.8: Injury to nerves and their effects

	<i>Motor loss</i>	<i>Sensory loss</i>
Femoral nerve	Quadriceps femoris	Anterior side of thigh, medial side of leg till ball of big toe
Sciatic nerve	Hamstring muscles; dorsiflexors and plantar flexors of ankle joint and evertors of foot Foot drop occurs	Back of leg, lateral side of leg, most of dorsum of foot, sole of foot
Common peroneal	Dorsiflexors of ankle, evertors of foot and foot drop occurs	Lateral and anterior sides of leg, most of dorsum of foot, most of digits
Tibial	Plantar flexors of ankle, intrinsic muscles of sole	Skin of sole. Later trophic ulcers develop
Obturator	Adductors of thigh except hamstring part of adductor magnus	Small area on the medial side of thigh

(Contd...)

**Table A1.8: Injury to nerves and their effects (Contd...)**

	Motor loss	Sensory loss
Superior gluteal	Gluteal medius, gluteus minimus and tensor fascia latae	Nil
Inferior gluteal	Gluteus maximus	Nil
Pudendal nerve	Muscles of perineum	Skin of perineum
Deep peroneal	Muscles of anterior compartment of leg	1st interdigital cleft
Superficial peroneal	Peroneus longus and peroneus brevis	Lateral aspect of leg most of dorsum of foot
Medial plantar	Four intrinsic muscles of sole (Table A1.6)	Medial 2/3rd of sole and digital nerves to medial 3½ toes, including nail beds
Lateral plantar	Most of intrinsic muscles of sole (Table A1.7)	Lateral 1/3rd of sole and digital nerves to lateral 1½ toes, including nail beds

CLINICAL TERMS

Policeman's heel: Plantar aponeurosis is attached to posterior tubercle of calcaneus and to all five digits. In plantar fasciitis, there is pain in the heel. Since policeman has to stand for long hours, they often suffer from it.

Dipping gait: Gluteus medius and gluteus minimus support the opposite side of the pelvis, when the foot is raised during walking. If these two muscles get paralysed on right side, walking with left limb becomes difficult, as that limb dips down, while attempting to lift it. Walking with right leg is normal as this leg is supported by the normal left muscles (see Fig. 5.12).

Weaver's bottom: Inflammation of the bursa over the ischial tuberosity. Since weavers have to sit for a long time, they suffer from it more often.

Meralgia parasthetica: Lateral cutaneous nerve of thigh may pierce the inguinal ligament and it may get pressed and cause irritation over lateral side of upper thigh (see Fig. 3.20).

Housemaid knee: Inflammation of prepatellar bursa (see Fig. 3.6). It used to be common in housemaids as they had to sweep the floor with their knees bent acutely.

Clergyman's knee: Inflammation of subcutaneous infrapatellar bursa as he would sit for prayers with bent knees

Close-pack position of ankle joint: Dorsiflexed ankle joint when anterior wide trochlear area of talus fits tightly into posterior narrow articular area of lower end of tibia.

Inversion injuries more common than eversion injuries: Inversion is accompanied by plantar flexion. During plantar flexion the narrow posterior trochlear area of talus lies loosely in the anterior wide articular area of lower end of tibia. So inversion injuries are common.

Fresher's syndrome: Overexertion of the muscles of anterior compartment of leg causes oedema of leg as these are enclosed in tight compartment of deep fascia. This results in pain in the leg. Fresher's are students who are just admitted in the colleges. They are compelled to run by the senior students. So it occurs in them.

Sites of intramuscular injections: In upper lateral quadrant of gluteal region into the gluteus medius. Also into the vastus lateralis (see Fig. 5.9).

Sites of pulse palpation in lower limb: Femoral artery, popliteal artery, posterior tibial and dorsalis pedis arteries. Popliteal artery is used for auscultation to measure blood pressure in lower limb.

Cut open/venesection: A small cut given in great/long saphenous vein to insert a cannula for giving intravenous transfusions. Since position of this vein is constant, anterior to medial malleolus, the great saphenous vein is used for cut-open.

Tarsal tunnel syndrome: The syndrome occurs due to compression of tibial nerve within the fibro-osseous tunnel under the flexor retinaculum of ankle joint. This is associated with pain and parasthesia in the sole of the foot often worse at night.

Injury to medial meniscus: The medial meniscus is more vulnerable to injury than the lateral meniscus, because of its fixity to the capsule and tibial collateral ligament. The lateral meniscus is protected by the popliteus which pulls it backwards so that it is not crushed between the articular surfaces (see Fig. 2.18).

Cruciate ligaments: Tear of anterior cruciate ligament leads to abnormal anterior mobility while tear of posterior ligament leads to abnormal posterior mobility of tibia (see Fig. 12.15).

Pes planus: Absence or collapse of the arches leads to flat foot (pes planus) (see Fig.13.8).



ARTERIES OF LOWER LIMB

Artery	Beginning, course and termination	Area of distribution
Femoral artery (see Fig. 3.21)	It is the continuation of external iliac artery, begins behind the inguinal ligament at the midinguinal point. Femoral artery courses through femoral triangle and adductor canal. Then it passes through opening in adductor magnus to continue as the popliteal artery	In femoral triangle, femoral artery gives three superficial branches, e.g. superficial external pudendal, superficial epigastric and superficial circumflex iliac, and three deep branches, e.g. profunda femoris, deep external pudendal and muscular branches. In adductor canal, femoral artery gives muscular and descending genicular artery
Superficial external pudendal (see Fig. 3.11)	Superficial branch of femoral artery	Supplies skin of external genitalia
Superficial epigastric (see Fig. 3.11)	Superficial branch of femoral artery	Supplies skin of anterior abdominal wall as it passes towards epigastric region
Superficial circumflex iliac	Superficial branch of femoral artery	Supplies skin over the iliac crest
Profunda femoris (see Fig. 3.22)	Largest branch of femoral artery which descends posterior to femoral vessels, and ends as the fourth perforating artery	Branches are medial circumflex femoral, lateral circumflex femoral, 1st, 2nd and 3rd perforating. All these branches supply all muscles of thigh and muscles attached to trochanters
Deep external pudendal	Deep branch of femoral artery	Supplies deeper structures in the perineal region
Muscular branches	Deep branch of femoral artery	Supply muscles of thigh
Descending genicular	Deep branch of femoral artery	Supplies the knee joint
Popliteal artery (see Fig. 6.5)	It is the continuation of femoral artery and lies in the popliteal fossa. Popliteal artery ends by dividing into anterior tibial artery and posterior tibial artery at the distal border of popliteus muscle	Gives five genicular: <ul style="list-style-type: none"> • Superior medial genicular • Superior lateral genicular • Middle genicular • Inferior medial genicular • Inferior lateral genicular Cutaneous branches for skin of popliteal fossa Muscular branches for the muscles of the fossa
Anterior tibial artery (see Fig. 8.8)	Smaller terminal branch of popliteal artery reaches the front of leg through an opening in the interosseous membrane. Runs amongst muscles of front of leg till midway between medial and lateral malleoli, where it ends by changing its name to dorsalis pedis artery	Muscular to the muscles of anterior compartment of leg. Cutaneous to the skin of leg. Articular to the knee joint through anterior and posterior tibial recurrent branches. Also to the ankle joint through anterior medial and anterior lateral malleolar branches
Dorsalis pedis artery (see Fig. 8.8)	Continuation of anterior tibial artery. Runs along medial side of dorsum of foot to reach proximal end of 1st intermetatarsal space where it enters the sole. In the sole it completes the plantar arch	Two tarsal branches for the intertarsal joints. Arcuate artery runs over the bases of metatarsal bones and gives off 2nd, 3rd and 4th dorsal metatarsal arteries. 1st dorsal metatarsal artery gives digital branches to big toe and medial side of 2nd toe
Posterior tibial artery (see Fig. 9.7)	It begins as the larger terminal branch of popliteal artery at the distal border of popliteus muscle. It descends down medially between the long flexor muscles to reach midway between medial malleolus and medial tubercle of calcaneus where it ends by dividing into medial plantar and lateral plantar arteries	Peroneal artery is the largest branch. Nutrient artery to tibia. Articular branches to the knee joint and ankle joint. Muscular branches to the neighbouring muscles
Peroneal artery (see Fig. 9.7)	Largest branch of popliteal artery given off 2.5 cm below lower border of popliteus	Muscular branches to muscles of posterior and lateral compartments. Cutaneous to skin of leg. Articular to ankle joint. Perforating branch enters

(Contd...)

**ARTERIES OF LOWER LIMB** (Contd...)

Artery	Beginning, course and termination	Area of distribution
Medial plantar artery (see Fig. 10.9)	The smaller terminal branch of posterior tibial artery given off under flexor retinaculum. Runs along the medial border of foot and ends by giving digital arteries	the front of leg through a hole in the interosseous membrane to assist the dorsalis pedis artery Muscular branches to muscles of medial side of foot. Cutaneous branches to medial side of sole and digital branches to medial 3½ digits. Also gives branches to the joints of foot
Lateral plantar artery (see Fig. 10.9)	The large terminal branch of posterior tibial artery given off under the flexor retinaculum. It runs laterally between muscles of 1st and 2nd layers of sole till the base of 5th metatarsal bone by becoming continuous with the plantar arch	Muscular branches to muscles of sole, cutaneous branches to skin and fasciae of lateral side of sole
Plantar arch (see Figs 10.9 and 10.10)	It is the direct continuation of lateral plantar artery and is completed medially by dorsalis pedis artery The arch lies between 3rd and 4th layers of muscles of sole. The deep branch of lateral plantar nerve lies in its concavity	Four plantar metatarsal arteries, each of them gives two digital branches for adjacent sides of two digits, including medial side of big toe and lateral side of little toe

MULTIPLE CHOICE QUESTIONS**A. Match the following on the left side with their appropriate answers on the right side.**

- Types of joints:
 - Hip joint
 - Ankle joint
 - Inferior tibiofibular joint
 - Calcaneocuboid joint
 - Saddle
 - Ball and socket
 - Syndesmosis
 - Hinge
- Characteristic features of tarsals:
 - Devoid of any muscular attachments
 - Forms the prominence of the heel
 - Boat-shaped
 - Has groove on inferior surface for the tendon of peroneus longus
 - Cuboid
 - Navicular
 - Calcaneus
 - Talus
- Muscles and their nerve supply:
 - Rectus femoris
 - Short head of biceps femoris
 - Ischial part of adductor magnus
 - Gracilis
 - Obturator
 - Femoral
 - Common peroneal
 - Tibial part of sciatic
- Movements at hip joint:
 - Extension
 - Flexion
 - Abduction
 - Lateral rotation
 - Gluteus medius
 - Iliacus
 - Obturator internus
 - Gluteus maximus

5. Cutaneous innervation:

- Medial aspect of leg
 - Lateral aspect of foot
 - Medial aspect of big toe
 - Interdigital cleft between 1st and 2nd toes
- Deep peroneal
 - Superficial peroneal
 - Saphenous
 - Sural

B. For each of the statements or questions below, one or more answers given is/are correct.

Select

- If only a, b and c are correct
- If only a, c are correct
- If only b, d are correct
- If only d is correct
- If all are correct

- The following structures pass through the saphenous opening:
 - Great saphenous vein
 - Lymph vessels connecting superficial inguinal lymph nodes with deep inguinal lymph nodes
 - Superficial epigastric artery
 - Superficial external pudendal vein
- When the neck of femur is fractured:
 - There may be avascular necrosis of head of femur
 - Trendelenburg's test is positive
 - The distal fragment of the bone is rotated laterally
 - The affected limb is shortened



3. The following statement/s is/are true regarding sciatic nerve:
 - a. It reaches gluteal region by passing through greater sciatic foramen above the piriformis muscle
 - b. All the muscular branches arise from its lateral side
 - c. At the back of the thigh it is crossed by semitendinosus
 - d. Tibial nerve is its larger terminal branch
4. The common peroneal nerve:
 - a. Conveys fibres from the dorsal divisions of ventral rami of L4, L5, S1 and S2
 - b. May get injured in the fracture of neck of fibula
 - c. Injury leads to foot drop
 - d. Injury results in sensory loss on the whole of the dorsum of foot
5. Popliteus muscle:
 - a. Has intracapsular origin
 - b. Pulls the medial meniscus backwards and prevents it from being trapped at the beginning of flexion
 - c. Initiates flexion of knee joint by unlocking the locked knee
 - d. Is innervated by a branch from the common peroneal nerve

ANSWERS

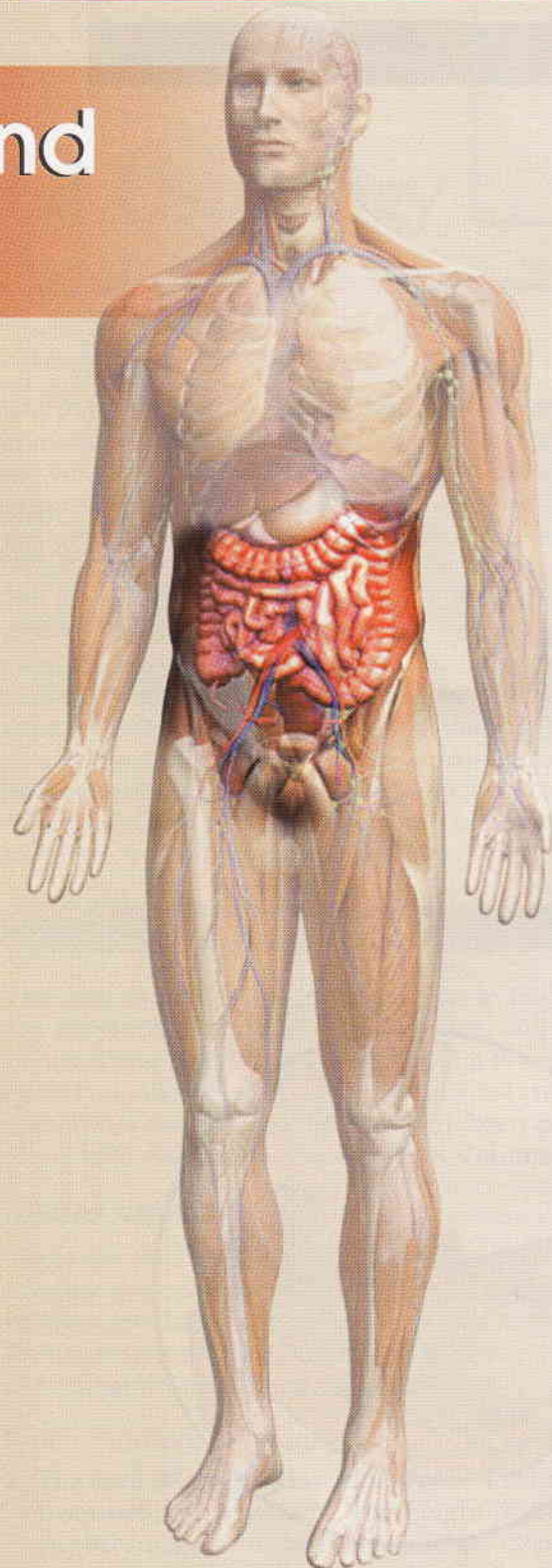
- | | |
|--------------------------------------|-----------------------------------|
| A. 1. a – ii, b – iv, c – iii, d – i | 2. a – iv, b – iii, c – ii, d – i |
| 3. a – ii, b – iii, c – iv, d – i | 4. a – iv, b – ii, c – i, d – iii |
| 5. a – iii, b – iv, c – ii, d – i | |
| B. 1. A | 2. E |
| 3. D | 4. A |
| | 5. B |

FURTHER READING

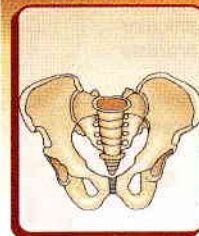
- Crock HV. An atlas of the arterial supply of the head and neck of femur in man. *Clin orthop* 1980; 152:17–25.
- Eckhoff PG, Kramer RC, Watkins JJ, Alongi CA, Van Gerven DP. Variation in femoral anteversion. *Clin Anat* 1994; 7:72–5.
- Gardner E, Gray DJ. The innervation of the joints of the foot. *Anat Rec* 1968; 161:141–8.
- Gupte CM, Bull AMJ, Thomas RD, Amis AA. A review of the function and biomechanics of the meniscofemoral ligaments. *Arthroscopy* 2003; 19:161–71.
- Jayakumari S, Suri RK, Rath G, Arora S. Accessory tendon and tripartite insertion of pattern of fibularis longus muscle, A case report. *Int J Morphol* 2006; 24: 633–636.
- Joseph J. Movements at the hip joint. *Ann R Coll Surg Eng*, 1975; 56:192–201
- Kakar S, Garg K, Raheja S. Functional anatomy of human foot in relation to dimensions of the sesamoid bones, *Ann Natl Acad Med Sci (India)* 1998; 34 (3): 157–161.
- Neidre A, Macnab I 1983. Anomalies of the lumbosacral nerve roots. *Spine* 8:294–9.
- Raheja S, Choudhry R, Singh P, Tuli A, Kumar H. Morphological description of combined variation of distal attachments of fibulares in a foot. *Surg radiol Anat* 2005; 27: 158–160
- Rajendran K. Mechanism of locking at the knee joint. *J Anat* 1985; 143:189–94.
- Sarrafian SK. *Anatomy of the Foot and Ankle, Descriptive, Topographic, Functional*, 2nd edn. Philadelphia: Lippincott 1993.
- Watanabe M, Takedas S, Ikeuchi H. Atlas of Arthroscopy. Berlin: Springer-Verlag 1979.

Spots on Lower Limb are given on pages 453 and 454

Abdomen and Pelvis



15. Introduction and Osteology	183
16. Anterior Abdominal Wall	196
17. Male External Genital Organs	219
18. Abdominal Cavity and Peritoneum	229
19. Abdominal Part of Oesophagus and Stomach	248
20. Small and Large Intestines	257
21. Large Blood Vessels of the Gut	275
22. Extrahepatic Biliary Apparatus	287
23. Spleen, Pancreas and Liver	294
24. Kidney and Ureter	312
25. Suprarenal Gland and Chromaffin System	326
26. Diaphragm	331
27. Posterior Abdominal Wall	337
28. Perineum	350
29. Preliminary Consideration of Boundaries and Contents of Pelvis	367
30. Urinary Bladder and Urethra	372
31. Female Reproductive Organs	382
32. Male Reproductive Organs	399
33. Rectum and Anal Canal	407
34. Walls of Pelvis	419
35. Surface Marking of Abdomen and Pelvis	431
36. Radiological and Imaging Procedures	436
Appendix 2	441



Introduction and Osteology

To know that we know what we know, and that we do not know what we do not know, that is true knowledge

—Confucius

INTRODUCTION TO ABDOMEN

The abdomen is the lower part of the trunk and lies below the diaphragm. It is divided by the plane of the pelvic inlet into a larger upper part, the abdomen proper, and a smaller lower part, the true or lesser pelvis and perineum. The abdomen is bounded to a large extent by muscles, which can easily adjust themselves to periodic changes in the capacity of the abdominal cavity. They can thin out to accommodate distensions of the abdomen imposed by *flatus* or gas, *fat*, *foetus* and *fluid*. The abdomen contains the greater parts of the digestive and urogenital systems. In addition, it also contains the spleen, the suprarenal glands, and numerous lymph nodes, vessels and nerves.

The abdominal wall is made up of the following six layers.

- 1 *Skin*,
- 2 *Superficial fascia*,
- 3 *Muscles* (and bones at places),
- 4 A continuous layer of fascia, named regionwise as the *diaphragmatic fascia*, *fascia transversalis*; *fascia iliaca*; *anterior layer of thoracolumbar fascia*, and *pelvic fascia*,
- 5 *Extraperitoneal connective tissue*, and
- 6 The *peritoneum* which provides a slippery surface for the movements of the abdominal viscera against one another.

The abdominal cavity is much more extensive than what it appears to be when seen from the outside. It projects upwards deep to the costal margin to reach the diaphragm. It also projects downwards as the pelvic cavity within the bony pelvis. Thus a considerable part of the abdominal cavity is overlapped by the thoracic bony cage above, and by the bony pelvis below.

The *importance of the abdomen* is manifold. To a physician, no examination is ever complete until he/she has thoroughly examined and auscultated the abdomen by the stethoscope (Greek *look at breast*) of

the patient. In fact, the patient, irrespective of his complaints, is never satisfied without an examination of his/her abdomen. To an obstetrician and gynaecologist, the importance of the abdomen is obvious. The surgeon considers the abdomen as an enigma because in a good proportion of his/her cases, the cause of abdominal pain, or the nature of an abdominal lump, may not be decided in spite of all possible investigations. Laparotomy, i.e. opening up of the abdomen by a surgeon, may reveal the disease in many obscure cases, but not in all of them. In the course of evolution, adoption of the erect posture by man has necessitated a number of structural modifications in the abdominal wall and pelvis, some of which will be mentioned in the appropriate sections.

OSTEOLOGY

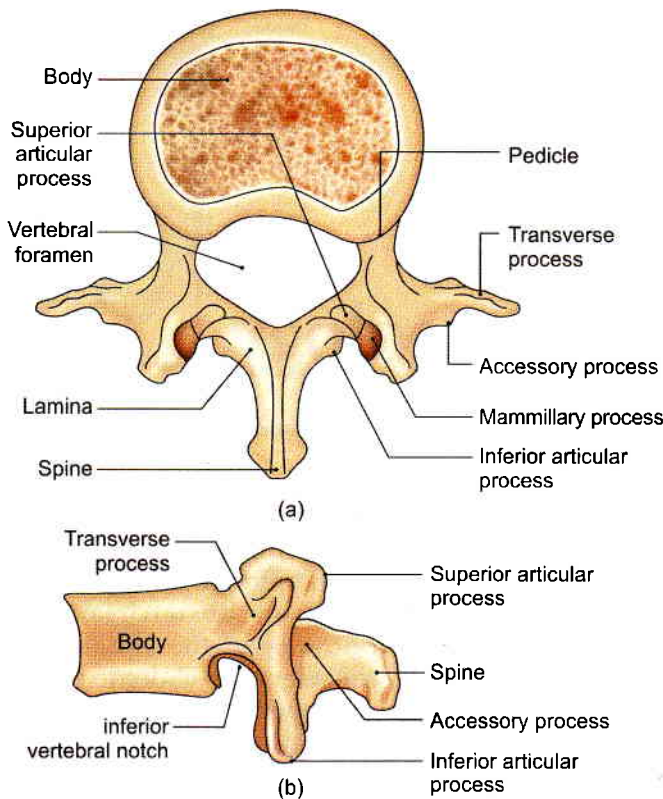
The various bones present in relation to the abdomen are the lumbar vertebrae, the sacrum, and the bony pelvis. These are described below. The lower ribs and costal cartilages are also closely related to the abdominal wall. These have already been considered along with the Thorax (Section 2) in Volume 1.

LUMBAR VERTEBRAE

There are five lumbar (Latin *loin*) vertebrae, of which the first four are typical, and the fifth is atypical. A lumbar vertebra is identified by (a) its large size, and (b) the absence of costal facets on the body (c) absence of foramen in transverse process.

Typical Lumbar Vertebra

- 1 The *body* is large, and is wider from side to side than from before backwards. The height of the body is slightly greater anteriorly than posteriorly; this difference contributes to the forward convexity of the lumbar spine (Figs 15.1a and b).



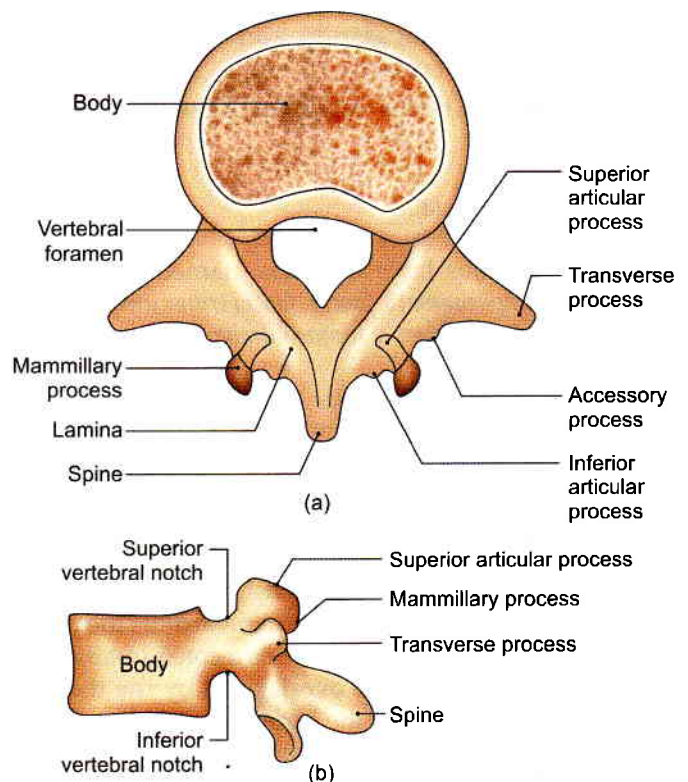
Figs 15.1a and b: Typical lumbar vertebra: (a) Seen from above, and (b) seen from the lateral side

- 2 The *vertebral foramen* is triangular in shape, and is larger than in the thoracic region; but is smaller than in the cervical region.
- 3 The *pedicles* are short and strong. They project backwards from the upper part of the body, so that the inferior vertebral notches are much deeper than the superior.
- 4 The *laminae* are short, thick and broad. They are directed backwards and medially to complete the vertebral foramen posteriorly. The overlapping between the laminae of the adjoining vertebrae is minimal.
- 5 The *spine* forms a vertical quadrilateral plate, directed almost backwards and only slightly downwards. It is thickened along its posterior and inferior borders.
- 6 The *transverse processes* are thin and tapering, and are directed laterally and slightly backwards. These develop from the costal element and are homologous with the ribs in the thoracic region. The postero-inferior aspect of the root of each transverse process is marked by a small, rough elevation, the accessory process, which represents the true transverse process of the vertebra as these develop from the transverse element of vertebra. The length of the transverse processes increases from vertebra L1 to L3 and, thereafter, it decreases (Fig. 15.1b).

- 7 The *superior articular processes* lie farther apart than the inferior. Each process bears a concave facet facing medially and backwards. The posterior border is marked by a rough elevation, the mammillary process.
- 8 The *inferior articular processes* lie nearer to each other than the superior. Each process bears a convex facet facing laterally and forwards.

Fifth Lumbar Vertebra

- 1 The most important distinguishing features are as follows.
 - a. The *transverse processes* are thick, short and pyramidal in shape. Their base is attached to the whole thickness of the pedicle and encroaches on the side of the body (Fig. 15.2a).
 - b. The distance between the *inferior articular processes* is equal to or more than the distance between the superior articular processes.
 - c. The *spine* is small, short and rounded at the tip.
- 2 Other features of the fifth lumbar vertebra are as follows.
 - a. The body is the largest of all lumbar vertebrae. Its anterior surface is much extensive than the posterior surface. This difference is responsible for the creation of the sharp lumbosacral angle and is 120° in an adult.



Figs 15.2a and b: Fifth lumbar vertebra: (a) Seen from above, and (b) seen from the lateral side



- b. The pedicles are directed backwards and laterally.
- c. The superior articular facets look more backwards than medially, and the inferior articular facets look more forwards than laterally, as compared to other lumbar vertebrae (Fig. 15.2b).

Attachments and Some Relations of Lumbar Vertebrae

Body

- 1 The upper and lower surfaces lie contact with the *intervertebral discs*.
- 2 The upper and lower borders give attachment to the *anterior and posterior longitudinal ligaments* in front and behind, respectively.
- 3 Lateral to the anterior longitudinal ligament, the *right crus of the diaphragm* is attached to the upper three vertebrae, and the *left crus of the diaphragm* to the upper two vertebrae.
- 4 Behind the line of the crura, the upper and lower borders of all the lumbar vertebrae give origin to the *psoas major* (Fig. 15.3).
- 5 Across the constricted part of the body on either side *tendinous arches* are attached. The *lumbar vessels*, and the *grey ramus communicans* from the *sympathetic chain*, pass deep to each of these arches.

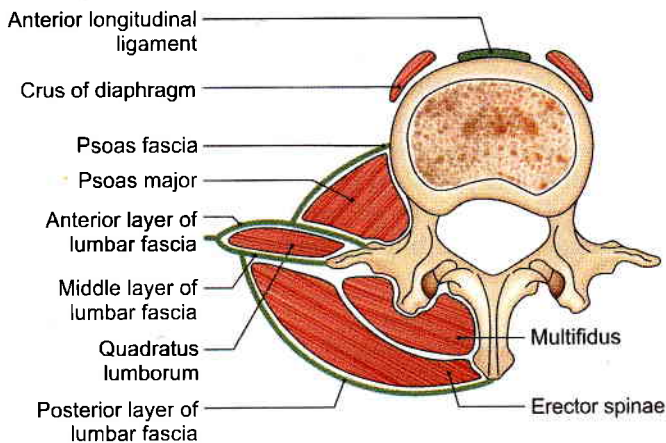


Fig. 15.3: Attachments of the lumbar vertebra

Vertebral Canal

The part of vertebral canal formed by the first lumbar vertebra contains the *conus medullaris*. The part formed by lower four vertebrae contains the *cauda equina*. The canal of all the lumbar vertebrae contains the *spinal meninges*.

Vertebral Arch

The *pedicles* are related above and below to spinal nerves.

The *laminae* provide attachment to the *ligamentum flava*.

The *spine* provides attachment to:

- a. The posterior layer of the lumbar fascia (Fig. 15.3).
- b. The interspinous and supraspinous ligaments.
- c. The erector spinae, the multifidus and the interspinous muscles.

Transverse Processes

- 1 The tips of the transverse processes of all lumbar vertebrae give attachment to the *middle layer of the lumbar fascia*. In addition, the tip of the first process gives attachment to the *medial and lateral arcuate ligaments*, (see Fig. 26.1) and the tip of the fifth process to the *iliolumbar ligament* (see Fig. 34.7).
- 2 The faint vertical ridge on the anterior surface of each transverse process gives attachment to the *anterior layer of the lumbar fascia*. Medial to the ridge, the anterior surface gives origin to the *psoas major*, and lateral to the ridge to the *quadratus lumborum* (Fig. 15.3).
- 3 The posterior surface is covered by deep muscles of the back, and gives origin to the fibres of the *longissimus thoracis*. The *accessory process* gives attachment to the *medial intertransverse muscle*.
- 4 The upper and lower borders provide attachment to the *lateral intertransverse muscles*.

Articular Processes

- 1 The concave articular facets permit some rotation as well as flexion and extension.
- 2 The *mammillary process* gives attachment to the multifidus and to the *medial intertransverse muscles*.

OSSIFICATION

A lumbar vertebra ossifies from three primary centres—one for the body or centrum and one each for each half of the neural arch. These appear in the *third month of foetal life*. The two halves of the neural arch fuse with each other, posteriorly during the *first year*. Fusion of the neural arch with the centrum occurs during the sixth year. The posterolateral parts of the body develop from the centre for the neural arch.

There are seven secondary centres as follows:

1. An upper annular epiphysis for the upper surface of the body.
2. A similar epiphysis for the lower surface of the body.
- 3 and 4. One centre for the tip of each transverse process.
- 5 and 6. One centre for each mammillary process.
7. One centre for the tip of the spine.



CLINICAL ANATOMY

- The lumbar region is a common site of a number of developmental deformities, causing symptoms ranging from simple backache to serious paralytic manifestations.

Sacralization of the fifth lumbar vertebra

- The *fifth lumbar vertebra* or its transverse process may be fused, on one or both sides, with the sacrum. Sometimes the transverse process may articulate with the ala of the sacrum or with the ilium. This may press on the fifth lumbar nerve.

Sometimes the body ossifies from two primary centres, and if one centre fails to develop, it results in a "hemivertebra".

Spina bifida

- The two halves of the neural arch may fail to fuse leaving a gap in the midline. This is called *spina bifida*. Meninges and spinal cord may herniate out through the gap.
- Protrusion of meninges alone results in the formation of a cystic swelling filled with cerebrospinal fluid. This swelling is called *meningocoele* (Fig. 15.4a). When the spinal cord is also present in the swelling the condition is called *meningomyelocoele* (Fig. 15.4b). The central canal of the herniated part of the cord may be dilated. This condition is called *syringomyelocoele*. At times the spinal cord may itself be open posteriorly. The condition is then called *myelocoele*. Sometimes a *spina bifida* is present, but there is no protrusion through it so that there is no swelling on the surface. This is referred to as *spina bifida occulta*.

Spondylolisthesis

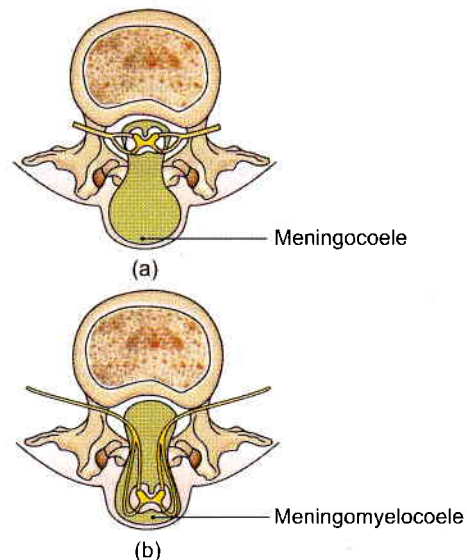
- Sometimes the greater part of the fifth lumbar vertebra slips forwards over the sacrum. Normally the tendency to forward slipping is prevented by the fact that the inferior articular processes of the fifth lumbar vertebra lie behind the superior articular processes of the first sacral vertebra. At times, however, the inferior articular processes, spine and laminae of the fifth lumbar vertebra are separate from the rest of the vertebra (due to an anomaly in the mode of ossification). The body of the vertebra can now slip forwards leaving the separated parts behind (Fig. 15.5).
- Spondylolisthesis may be the cause of backache and of pain radiating along the course of the sciatic nerve known as *sciatica*.

Fracture-dislocation

- Fracture-dislocation of lumbar vertebrae results in the *cauda equina syndrome* (Fig. 15.6). It is characterized by:
 - a. Flaccid paraplegia.

- b. Saddle-shaped area of anaesthesia, and analgesia.
- c. Sphincter disturbances in the form of incontinence of urine and faeces.
- d. Impotence.

- In the young adults, the discs are very strong and cannot be damaged alone. However, after the second decade, degenerative changes set in resulting in necrosis, with sequestration of nucleus pulposus, and softening and weakness of the annulus fibrosus. Such a disc is liable to internal or eccentric displacement or external derangements resulting in prolapse due to rupture of annulus fibrosus even after minor strains.
- Cauda equina syndrome described above.
- The unequal tension in the joint in internal derangement leads to muscle spasm and violent pain of acute lumbago.
- Disc prolapse is usually posterolateral (Fig. 15.7). This presses upon the adjacent nerve roots and gives rise to referred pain, such as sciatica. Disc prolapse occurs most commonly in lower lumbar region and is also common in lower cervical region (C5–C7). In sciatica, the pain is increased with rise of pressure in canal (as in sneezing); straight leg raising tests is positive; and the motor effects, with loss of power and reflexes, may follow.
- The spine of thoracic vertebrae may point to one side. The condition is scoliosis (Fig. 15.8).
- There may be projection of the spines posteriorly due to osteoporosis of the bodies of vertebrae leading to *kyphosis* (Fig. 15.9).
- Anterior convexity of lumbar vertebrae may get exaggerated, leading to "*lumbar lordosis*" (Fig. 15.10).



Figs 15.4a and b: (a) Meningocoele, and (b) meningomyelocoele

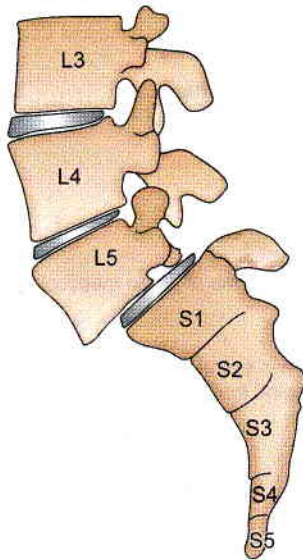


Fig. 15.5: Spondylolisthesis of fifth lumbar vertebra

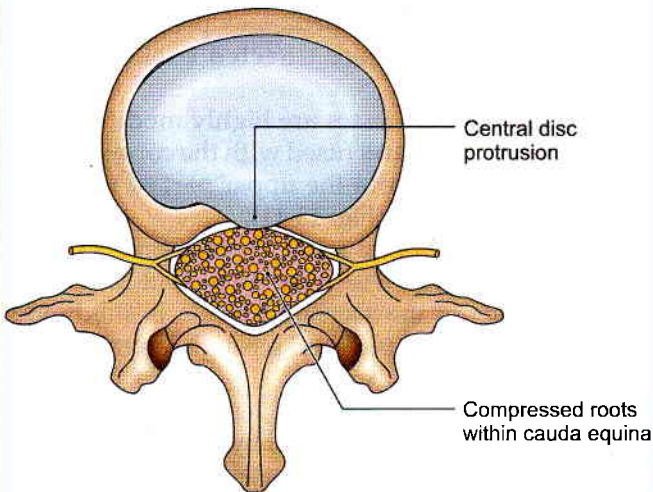


Fig. 15.6: Cauda equina syndrome

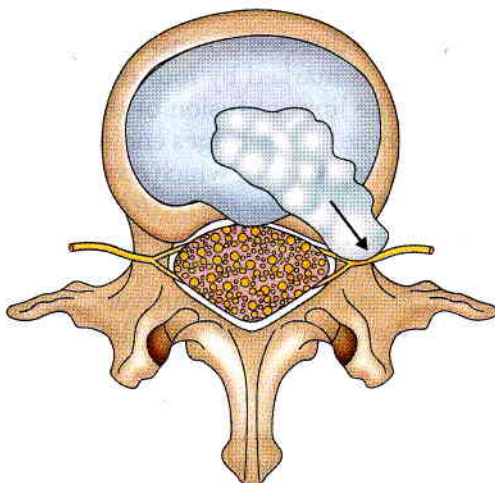


Fig. 15.7: Posterolateral disc prolapse

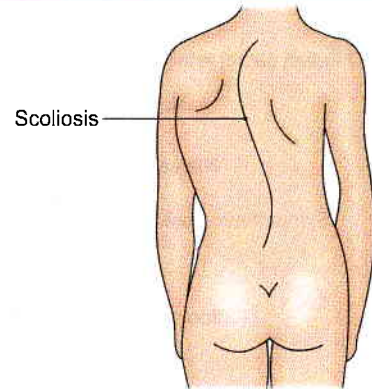


Fig. 15.8: Scoliosis

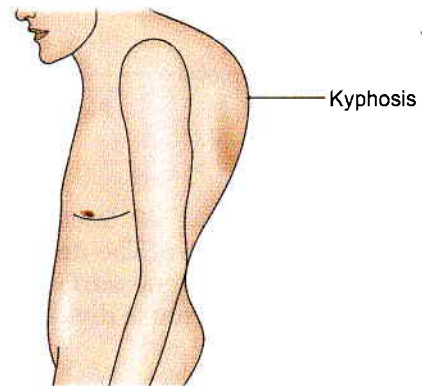


Fig. 15.9: Kyphosis

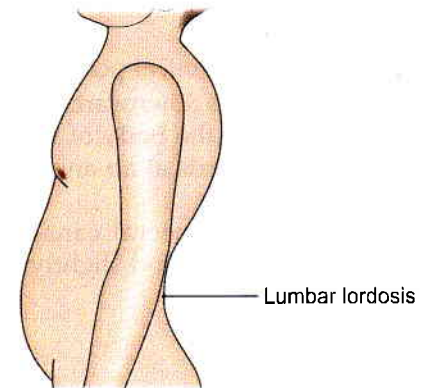


Fig. 15.10: Lumbar lordosis

THE SACRUM/VERTEBRA MAGNUM

The sacrum (Latin *sacred*) is a large, flattened, triangular bone formed by the fusion of five sacral vertebrae. It forms the posterosuperior part of the bony pelvis, articulating on either side with the corresponding hip bone at the sacroiliac joint. The upper part of the sacrum is massive because it supports the body weight and transmits it to the hip bones. The lower part is free from weight, and therefore tapers rapidly (Fig. 15.11).

Being triangular, the sacrum has a base or upper surface, an apex or lower end, and four surfaces—

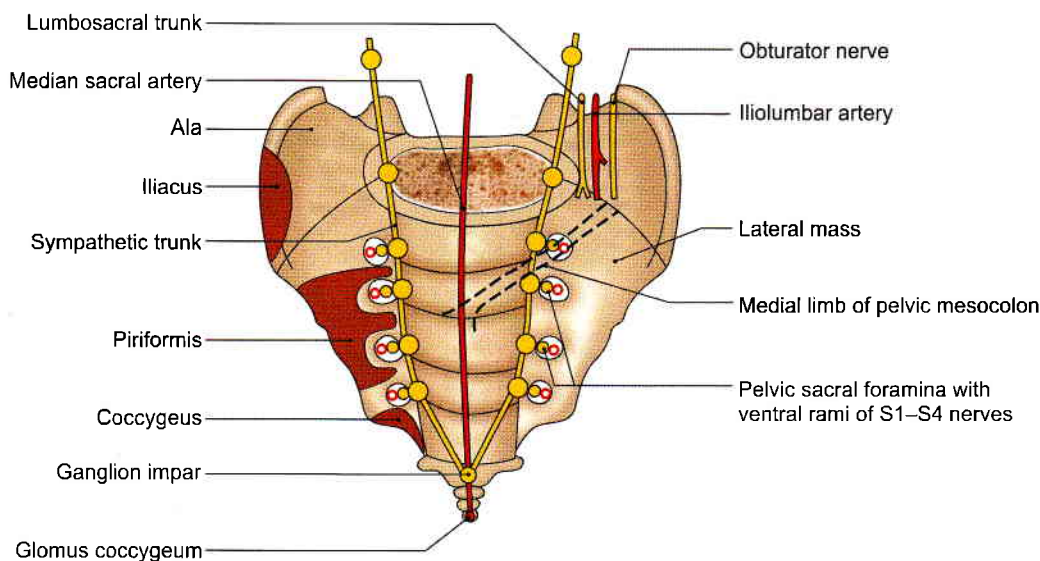


Fig. 15.11: Anterior (pelvic) view of the sacrum

pelvic, dorsal and right and left lateral. The pelvic surface is smooth and concave. The dorsal surface is irregular and convex. The lateral surface is irregular and partly articular. The sacrum is divided by rows of foramina into:

- Median portion, traversed by the sacral canal.
- A pair of *lateral masses* formed by fusion of the transverse processes posteriorly, and of the costal elements anteriorly.

When placed in the anatomical position:

- The pelvic surface faces downwards and forwards.
- The upper surface of the body of the first sacral vertebra slopes forwards at an angle of about 30 degrees.
- The upper end of the sacral canal is directed almost directly upwards and slightly backwards.

Features

Base

The base is directed upwards and forwards. It is formed by the upper surface of the first sacral vertebra, and presents features of a typical vertebra in a modified form.

- The body is lumbar in type. It articulates with vertebra L5 at the *lumbosacral joint*. The projecting anterior margin is called the *sacral promontory*. The surface slopes forwards at an angle of 30 degrees.
- The vertebral foramen lies behind the body, and leads into the sacral canal. It is triangular in shape.
- The pedicles are short and are directed backwards and laterally.
- The laminae are oblique.
- The spine forms the first spinous tubercle.

- The superior articular processes project upwards. The facets on them are directed backwards and medially.
- The transverse processes are highly modified. Each process is massive and fused with the corresponding costal element to form the upper part of the lateral mass of the sacrum (Fig. 15.11).

The base of the lateral mass, forms a broad sloping surface spreading fan wise from the side of the body. It is called the *ala* of the sacrum. The ala is subdivided into a smooth medial part and a rough lateral part.

Apex

The apex of the sacrum is formed by the inferior surface of the body of the fifth sacral vertebra. It bears an oval facet for articulation with the coccyx.

Pelvic Surface

This is concave and directed downwards and forwards. The median area is marked by four transverse ridges, which indicate the lines of fusion of the bodies of the five sacral vertebrae. These ridges end on either side at the *four pelvic sacral foramina*, which communicate with the sacral canal through the *intervertebral foramina*. The bony bars between the foramina represent the *costal elements*. Lateral to the foramina, the *costal elements* unite with each other and with the transverse processes to form the lateral mass of the sacrum (Fig. 15.11).

Dorsal Surface

The dorsal surface of the sacrum is rough, irregular and convex, and is directed backwards and upwards.

- In the median plane, it is marked by the *median sacral crest* which bears 3 to 4 spinous tubercles, representing



the fused spines of the upper four sacral vertebrae. Below the 4th tubercle, there is an inverted U-shaped gap in the posterior wall of the sacral canal: this is called the *sacral hiatus*. It results from failure of the laminae of the fifth sacral vertebra to meet posteriorly (Fig. 15.12).

- 2 Lateral to the median crest, the posterior surface is formed by the fused laminae.
- 3 Lateral to the laminae and in line with the superior articular process of the first sacral vertebra, there are four articular tubercles, representing the fused articular processes of adjacent vertebrae. The inferior articular processes of the fifth sacral vertebra are free and form the *sacral cornua*, (Latin *horn like*) which project downwards at the sides of the sacral hiatus.
- 4 Lateral to the articular tubercles there are four *dorsal sacral foramina*. They communicate with the sacral canal through the intervertebral foramina.
- 5 Lateral to the foramina, there is the *lateral sacral crest* on which there are transverse tubercles, representing the fused transverse processes.

Lateral Surface

It is formed by the fused transverse processes and the costal elements of the sacral vertebrae. It is wide above and narrow below. The upper wider part bears an L-shaped *auricular surface* anteriorly, and a rough, deeply pitted area posteriorly. The auricular surface is formed by the costal elements. It articulates with the auricular surface of the hip bone at the sacroiliac joint. The posterior, roughened and pitted area is formed by the transverse processes.

The abrupt medial bend at the lower end of the lateral surface is called the *inferior lateral angle* of the sacrum.

Sacral Canal

It is formed by the sacral vertebral foramina, and is triangular on cross-section. The upper end of the canal appears oblique, but actually it is directed upwards in the anatomical position. Inferiorly, the canal opens at the sacral hiatus, and laterally it communicates through the intervertebral foramina with the pelvic and dorsal sacral foramina.

The sacral canal contains the spinal meninges. The *filum terminale* and the *subdural* and *subarachnoid spaces* end at the level of the second sacral vertebra. Therefore, the lower sacral nerves and *filum terminale* pierce the dura and arachnoid at this (S2) level.

Attachments on the Sacrum

- 1 The anterior and posterior edges of the body of the first sacral vertebra give attachment to the lowest fibres of the *anterior and posterior longitudinal ligaments*. The lamina of this vertebra provide attachment to the *lowest pair of ligamentum flava*.
- 2 The rough part of the ala gives origin to the *iliacus* anteriorly, and attachment to the *lumbosacral ligament* posteriorly. The upper part of the *ventral sacroiliac ligament* is attached to its margin (Fig. 15.11).
- 3 The part of the pelvic surface lateral to the bodies of the middle three pieces of the sacrum gives origin to the *piriformis* (Fig. 15.11). The area extends into the intervals between the pelvic sacral foramina and is E-shaped.
- 4 The dorsal surface gives origin to the *erector spinae* along a U-shaped line passing over the spinous and transverse tubercles. The area in the concavity of the 'U' gives origin to the *multifidus* (Fig. 15.12).

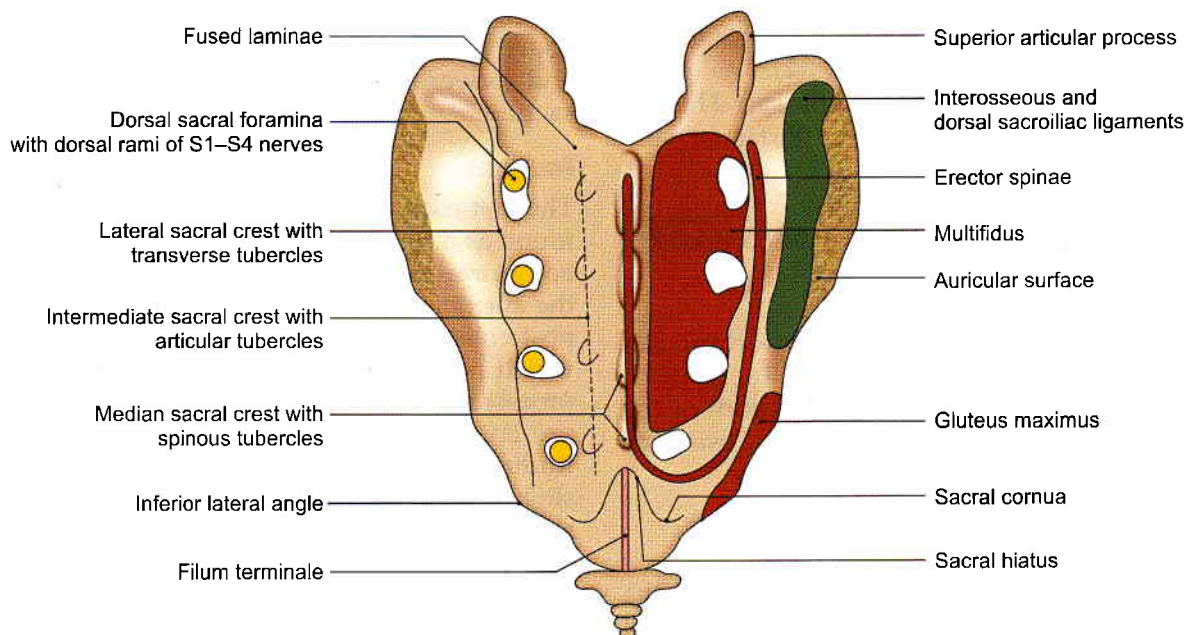


Fig. 15.12: Posterior aspect of the sacrum



- 5 The *interosseous sacroiliac ligament* is attached to the rough pitted area of the lateral surface, behind the auricular surface (Fig. 15.12).
- 6 The lower narrow part of the lateral surface, below the auricular surface gives origin to the *gluteus maximus*; attachment to the *sacrospinous* and *sacrospinous* ligaments; and origin to the *coccygeus*, in that order from behind forwards (see Fig. 34.7b).
- 7 The inferior lateral angle gives attachment to the *lateral sacrococcygeal ligament*.

Relations of the Sacrum

- 1 The smooth part of the ala is related, from medial to lateral side, to the *sympathetic chain*, the *lumbosacral trunk*, the *iliolumbar artery*, and the *obturator nerve*. All these structures are overlapped by the *psoas major* muscle (Fig. 15.11).
- 2 The pelvic surface is related to:
 - a. The *median sacral vessels* in the median plane.
 - b. The *sympathetic trunks* along the medial margin of the pelvic foramina.
 - c. The peritoneum in front of the bodies of the upper 2½ pieces, interrupted obliquely by the attachment of medial limb of the *pelvic or sigmoid mesocolon* (see Fig. 18.14).
 - d. The rectum in front of the bodies of the lower 2½ pieces. The bifurcation of the superior rectal artery lies between the rectum and the third sacral vertebra.

Structures Transmitted through Foramina

- 1 The pelvic sacral foramina transmit:
 - a. The *ventral rami of upper four sacral nerves*.
 - b. The *lateral sacral arteries* (Fig. 15.11).
- 2 The dorsal sacral foramina transmit the *dorsal rami of the upper four sacral nerves* (Fig. 15.12).
- 3 The following structures emerge at the sacral hiatus.
 - a. The *5th sacral nerves* which groove the lateral parts of the fifth sacral vertebra.
 - b. A pair of *coccygeal nerves*.
 - c. *Filum terminale* which passes to the coccyx.

Sex Differences

The sacrum shows a number of important sex differences. These are as follows.

- 1 The relationship of the length and breadth of the sacrum can be expressed quantitatively by using the *sacral index* which is calculated as:

$$\frac{\text{Breadth across the base} \times 100}{\text{Length from promontory to apex}}$$

The male sacrum is longer and narrower than in the female. The average sacral index is about 105 in the male and about 115 in the female.

- 2 The width of the body of first sacral vertebra is greater than that of each ala in the male. In female, the two are equal.
- 3 The dorsal concavity of auricular surface is less marked in male. In both, the auricular surface extends on to *upper three sacral vertebrae*.
- 4 The concavity on the ventral aspect of sacrum is more uniform, and is shallower in males. In females, the concavity is irregular especially between S1 and S2 and between S3 and S4.
- 5 The *sacrovertebral angle* is more prominent in the female and the downward direction of the pelvic surface is greater than in the male. The size of pelvic cavity is more in females.

OSSIFICATION

The ossification of the sacrum should be regarded as the ossification of five separate vertebrae. However, the upper 3 vertebrae have additional primary centres for the costal bars.

Thus there are 21 primary centres; 5 for the bodies, 10 for the arches, and 6 for the costal bars and 14 secondary centres; 10 for the epiphyses of the bodies, 2 for the auricular surfaces, and 2 for the margins below the auricular surfaces. The primary centres appear between 2nd and 8th week of foetal life, and fuse with each other between 2nd and 8th years of life. The secondary centres appear at puberty and fuse by 25 years.

COCCYX

The coccyx (Greek *cuckoo's beak*) is a small triangular bone formed by fusion of four rudimentary coccygeal vertebrae, which progressively diminish in size from above downwards. The bone is directed downwards and forwards, making a continuous curve with the sacrum.

Features

The first coccygeal piece is the largest. It is commonly found as a separate vertebra. The upper surface of its body forms the *base* of the coccyx, which articulates with the apex of the sacrum. Projecting upwards from the posterolateral side of the base are the *coccygeal cornua*, which represent the pedicles and superior articular processes. They articulate with the sacral cornua and are connected to them by *intercornual ligaments*. Rudimentary *transverse processes* project laterally and slightly upwards from the side of the base. They may articulate or fuse with the inferior lateral angle of the sacrum, creating a fifth pair of sacral foramina.

The second, third and fourth coccygeal vertebrae are mere bony nodules which diminish successively in size and are usually fused together.



Attachments

The dorsal surface of the coccyx gives:

- 1 Origin to the *gluteus maximus* on either side.
- 2 Origin to the *sphincter ani externus* at the tip.
- 3 Attachment to the *dorsal sacrococcygeal ligaments* and the *filum terminale* at the first piece.

The pelvic surface:

- 1 Provides insertion to the *coccygeus* and to the *levator ani* on either side.
- 2 Provides attachment to the ventral sacrococcygeal ligament over the first two pieces.
- 3 It is related to the *ganglion impar* and the *glomus coccygeum*. The lateral margins provide attachment to *sacrospinous* and *sacrotuberous* ligaments (see Figs 29.3 and 29.11).

OSSIFICATION

The coccyx ossifies from 4 primary centres one for each segment, which appear between 1st and 20th years, and fuse with each other between 20th and 30th years. The coccyx is slightly mobile at the sacrococcygeal joint, but fuses with it late in life.

BONY PELVIS

The bones forming the pelvis, (Latin *basin*) its division into the greater and lesser pelvis, and the important features of the lesser pelvis, including the inlet, outlet and cavity, are described in Chapter 29. Some other important aspects of the pelvis are described here.

Pelvimetry

The importance of the measurements of the pelvis is mainly obstetric, but also forensic and anthropological. Pelvimetry can be done in the following ways.

Pelvimetry on the skeletonized pelvis prepared from cadavers.

Clinical pelvimetry on living subjects.

Radiological pelvimetry.

Pelvimetry on Skeletonized Pelvis

The relevant diameters are summarized in Table 15.1.

Clinical Pelvimetry

Pelvic measurements in obstetric cases can be done both externally and internally. External pelvimetry has been mostly given up because of its limited value. It is helpful in diagnosis of gross pelvic contraction.

- 1 The *interspinous diameter*, between the outer borders of anterior superior iliac spines, measures 22–25 cm.
- 2 The *intercristal diameter*, the widest distance between the outer borders of the iliac crests, measures 25–28 cm.
- 3 The *external conjugate* or Baudelocque’s diameter, the distance between the tip of the spine of vertebra S5 and the upper border of the pubic symphysis, measures not less than 19 cm.
- 4 The *intertuberous diameter*, between the lowermost and innermost points on the two ischial tuberosities, measures 10 cm.
- 5 The *anteroposterior diameter of the outlet* measures about 13 cm.
- 6 The *posterior sagittal diameter*, from the midpoint of the intertuberous diameter to the tip of the coccyx, measures 8–9 cm.

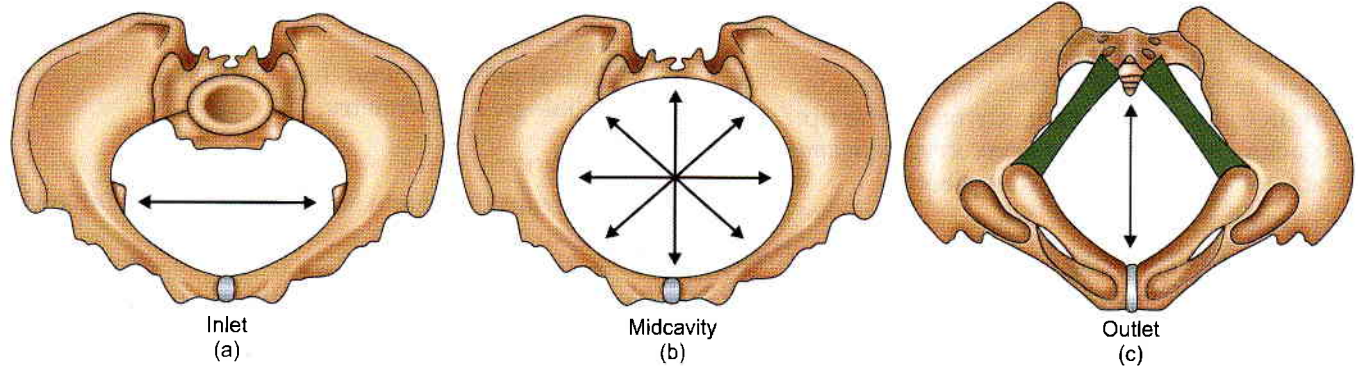
Internal Pelvimetry

It is done by digital examination per vaginum.

- 1 The *diagonal conjugate* is the distance between midpoint of promontory and lower border of

Table 15.1: Dimensions of the pelvis in female (Figs 15.13a to c)

Region	Diameter	Average measurements in cm
I. Pelvic inlet (Fig. 15.13a)	1. <i>Anteroposterior diameter</i> (true conjugate), from the midpoint of the sacral promontory to the upper border of the pubic symphysis	11
	2. <i>Transverse diameter</i> (maximum)	13
	3. <i>Oblique diameter</i> , from one iliopectic eminence to the opposite sacroiliac joint	12
II. Pelvic cavity (Fig. 15.13b)	1. <i>Anteroposterior diameter</i> , from midpoint of vertebra S3 to the posterior surface of the pubic symphysis	12
	2. <i>Transverse diameter</i>	12
	3. <i>Oblique diameter</i> , from the lowest point of one sacroiliac joint to the midpoint of the opposite obturator membrane	12
III. Pelvic outlet (Fig. 15.13c)	1. <i>Anteroposterior diameter</i> from the tip of the coccyx to the inferior margin of the pubic symphysis (maximum)	13
	2. <i>Transverse diameter</i> (bituberous diameter), between ischial tuberosities	11
	3. <i>Oblique diameter</i> , from the midpoint of the sacrotuberous ligament on one side to the junction of the ischiopubic rami on the other side	12



Figs 15.13a to c: The bony pelvis: (a) Inlet with longest transverse diameter, (b) cavity with all diameters equal, and (c) outlet with longest anteroposterior diameter

anterior surface of pubic symphysis. Normally, it is at least 11.5 cm. A rough estimate of the true conjugate is obtained by deducting 1.5 to 2 cm from the diagonal conjugate.

- The *interischial spinous diameter* of 9 cm, between the tips of the spines is difficult to assess digitally.
- In addition, a thorough palpation of the bony pelvis is done to assess the curvature of the sacrum, the mobility of the coccyx, the length of sacrospinous ligament (more than the width of two examining fingers), and the side wall for any tendency to funnelling.

Radiological Pelvimetry

It has become a highly refined technique, but radiation risks impose limitations.

Ultrasound is an extremely useful and safe procedure and has replaced radiological pelvimetry to a great extent.

Morphological Classification of Pelvis

According to Anatomical and Radiological Data

- Gynaecoid type (41.4%):** This is normal female pelvis, the average diameters of which have already been mentioned. The inlet is round or slightly ovoid with transverse diameter placed well forward from the sacrum. The side walls are more vertical than in the android pelvis.
- The android type (32.5%)** resembles a male pelvis. The inlet is triangular with the greatest transverse diameter placed much nearer the promontory than in the gynaecoid pelvis. The subpubic angle and greater sciatic notches are narrower, so that the cavity is funnel-shaped and the outlet is reduced in all diameters.
- The *anthropoid type (23.5%)* shows resemblance to the pelvis of anthropoid apes.
- The *platypelloid type (2.6%)* is somewhat opposite to the anthropoid pelvis.

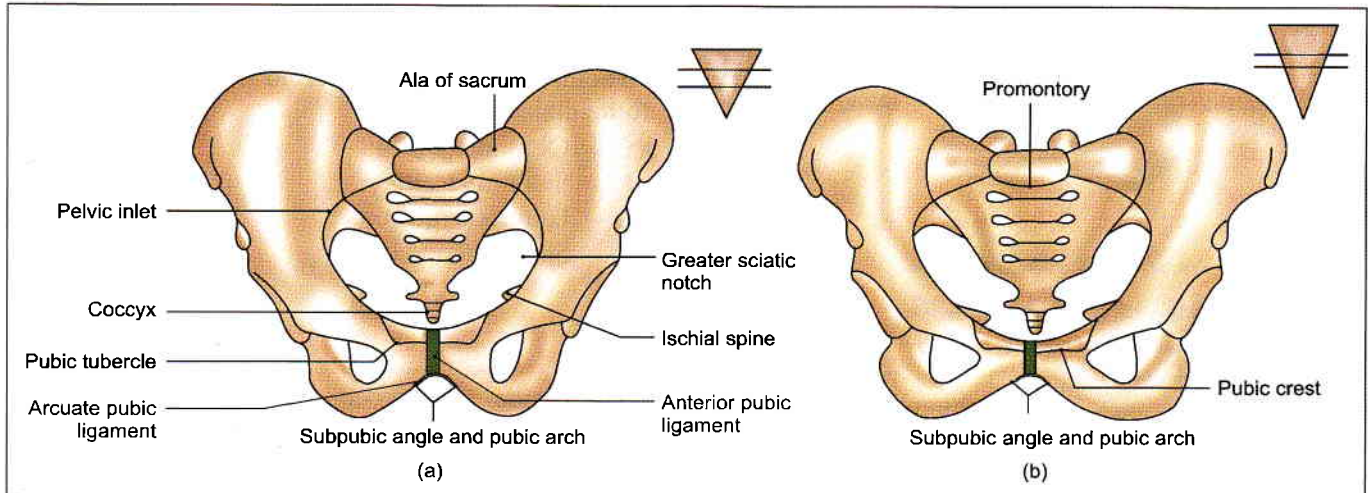
Out of the various types mentioned, only a gynaecoid pelvis permits a normal delivery of the child. The other three represent different types of *contracted pelvis*.

Sex Differences in the Pelvis

The most marked of these differences are due to adaptation of female pelvis for child bearing. Males have stronger muscles, thicker bones and prominent bony markings.

As compared to a male pelvis a female pelvis shows the following differences.

- The false pelvis is *deep in male* and *shallow in female*.
- Pelvic inlet is *heart-shaped in male* due to jutting forwards of sacral promontory. In *female it is transversely oval*.
- Pelvic cavity is *smaller and deeper in male* (Fig. 15.14a inset). In *female the pelvic cavity is roomier and shallower* (Fig. 15.14b inset), i.e. distance between inlet and outlet is shorter.
- The pelvic outlet is smaller with ischial tuberosities turned inside in male. In female the pelvic outlet is bigger with everted ischial tuberosities.
- Sacrum is *longer and narrow in male*, while it is *shorter and wider in female*.
- Subpubic angle* is narrower, i.e. 50° – 60° in male. The angle is wider, i.e. 80° – 85° in female. This is the most important difference (Figs 15.14a and b).
- The greater sciatic notch is wider in females (75°) than in males (50°).
- The acetabulum is large in males, and its diameter is approximately equal to the distance from its anterior margin to the pubic symphysis.
- The chilotic line extends from the iliopubic eminence to the iliac crest. In females, the pelvic part of the chilotic line is longer than the sacral part.
- The preauricular sulcus is more marked in females.



Figs 15.14a and b: Anterior view of (a) a male pelvis, and (b) a female pelvis

Anatomical Position of the Pelvis

When examining an isolated pelvis students generally do not orientate it as it is in the intact body. It can be correctly orientated keeping the following in mind.

In the anatomical position, i.e. with the person standing upright:

- 1 The anterior superior iliac spines and the pubic symphysis lie in the same vertical plane. A pelvis can be correctly oriented by placing these points against a wall.
- 2 The pelvic surface of the pubic symphysis faces backwards and upwards.
- 3 The plane of the pelvic inlet faces forwards and upwards at an angle of 50° to 60° with the horizontal.
- 4 The plane of the pelvic outlet makes an angle of 15° with the horizontal (see Fig. 29.6).
- 5 The upper end of the sacral canal is directed almost directly upwards.

INTERVERTEBRAL JOINTS

These joints include:

- 1 The joints between vertebral bodies.
- 2 The joints between vertebral arches.

The joints between vertebral bodies are *secondary cartilaginous* joints held by the intervertebral discs and two accessory ligaments, the anterior and posterior longitudinal ligaments. Intervertebral disc is described below.

Joints of the vertebral arches are formed by the articular processes of the adjacent vertebrae. These are plane synovial joints, permitting gliding movements.

The accessory ligaments include:

- a. Ligamenta flava,
- b. Supraspinous,
- c. Interspinous, and
- d. Intertransverse ligaments.

The lumbar spine permits maximum of extension, considerable amount of flexion and lateral flexion, and least of rotation.

Intervertebral Disc

It is a fibrocartilaginous disc which binds the two adjacent vertebral bodies, from axis or second cervical vertebra to sacrum. Morphologically, it is a segmental structure as opposed to the vertebral body which is intersegmental (Figs 15.15a to c).

Shape

Its shape corresponds to that of the vertebral bodies between which it is placed.

Thickness

It varies in different regions of the column and in different parts of the same disc. In cervical and *lumbar* regions, the *discs* are *thicker in front* than behind, while in the thoracic region they are of uniform thickness. The discs are thinnest in the upper thoracic and thickest in the lumbar region.

The discs contribute about one-fifth of the length of vertebral column. Such contribution is greater in cervical and lumbar regions than in thoracic region.

Structure

Each disc is made up of the following three parts.

- 1 *Nucleus pulposus* is the central part of the disc which is soft and gelatinous at birth. Its water content is 90% in newborn and 70% in old age. It is kept under tension and acts as a hydraulic shock-absorber. It represents the remains of the notochord, and contains a few multinucleated notochordal cells during the first decade of life, after which there is a gradual replacement of the mucoïd material by fibrocartilage, derived mainly from the cells of annulus fibrosus and partly from the cartilaginous



MULTIPLE CHOICE QUESTIONS

1. Ala of the sacrum is related to following structures *except*:
 - a. Sympathetic trunk
 - b. Lumbosacral trunk
 - c. Internal iliac artery
 - d. Obturator nerve
2. Anteroposterior, transverse and oblique diameters are same in which part of the pelvis?
 - a. At the inlet
 - b. Pelvic cavity
 - c. At the outlet
 - d. All the above parts
3. Subpubic angle is 50° – 60° in:
 - a. Male pelvis
 - b. Female pelvis
 - c. Platypelloid pelvis
 - d. Gynaecoid pelvis
4. Which of the following is not a layer of lumbar fascia:
 - a. Psoas fascia
 - b. Anterior layer
 - c. Middle layer
 - d. Posterior layer

ANSWERS

1. c 2. b 3. a 4. a



Anterior Abdominal Wall

In order to achieve a radical cure of inguinal hernia, it is absolutely essential to restore those conditions in the area of hernial orifice which exist under normal circumstances

—Edoardo Bassini

The attachments of the muscles of anterolateral abdominal wall are given in this chapter. The formation and contents of rectus sheath are mentioned. The inguinal canal has been described in detail as its relations are of importance in the reduction/repair of the inguinal hernia.

The heading “anterior abdominal wall” usually includes both the front as well as the side walls of the abdomen and needs to be called anterolateral abdominal wall.

SURFACE LANDMARKS

Before taking up the description of the abdominal wall proper it is desirable to draw attention to some surface landmarks that can be identified in the region.

- 1 In the anterior median plane, the abdominal wall extends from the *xiphoid process* which lies at the level of the ninth thoracic vertebra to the pubic symphysis, which lies at the level of the coccyx. Posteriorly and laterally, the vertical extent of the abdominal wall is much less, as it is replaced by the thoracic cage, above and behind; and by the gluteal region, on the posterior aspect of the lower part (Fig. 16.1).
- 2 The superolateral margins of the anterior abdominal wall are formed by the right and left *costal margins*. Each margin is formed by the seventh, eighth, ninth and tenth costal cartilages. The costal margin reaches its lowest level in the *midaxillary line*. Here the margin is formed by the tenth costal cartilage.

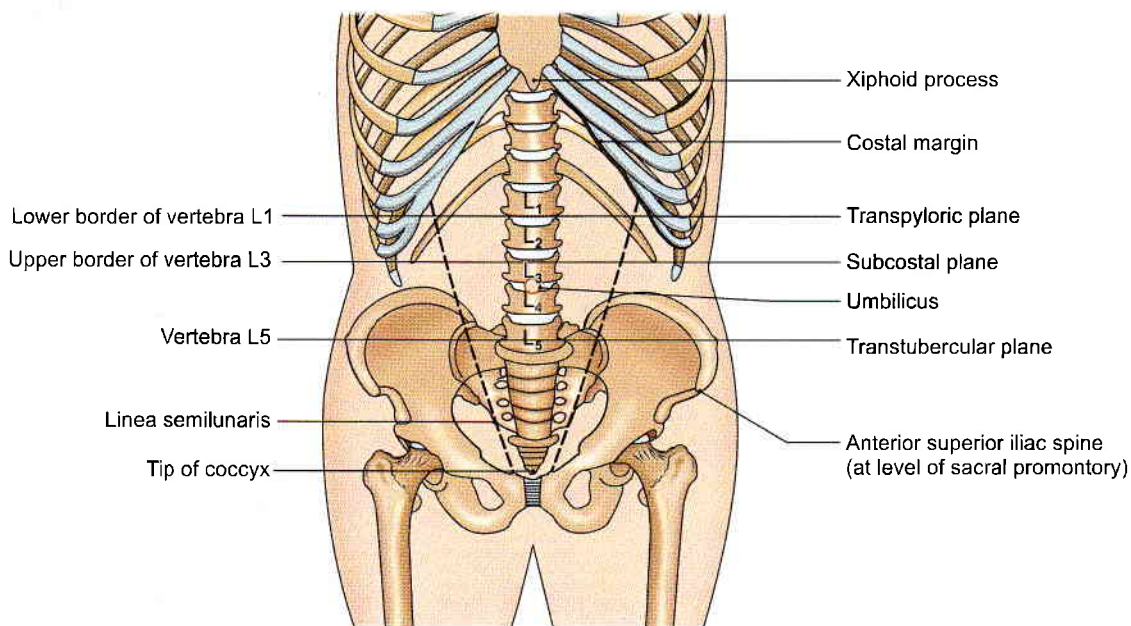


Fig. 16.1: Landmarks of the abdomen



The transverse plane passing through the lowest part of the costal margin is called the *subcostal plane*. It passes through the third lumbar vertebra.

- 3 The infrasternal or *subcostal angle* is formed between the right and left costal margins. The xiphoid process lies in a depression at the apex of the infrasternal angle at the level of the ninth thoracic vertebra (Fig. 16.2).
- 4 The *iliac crest* forms the lower limit of the abdominal wall at the side. The highest point of the iliac crest lies at the level of the fourth lumbar vertebra slightly below the normal level of the umbilicus.
- 5 The *anterior superior iliac spine* lies at the level of the *sacral promontory*.
- 6 The *tubercle of the iliac crest* is situated on the outer lip of iliac crest about 5 cm behind the anterior superior iliac spine. The *intertubercular plane* passes through the tubercles. It passes through the fifth lumbar vertebra.
- 7 The *inguinal ligament* extends from the anterior superior iliac spine to the pubic tubercle. It is convex downwards. It is placed at the junction of the anterior abdominal wall with the front of the thigh (Fig. 16.2).
- 8 The spermatic cord is a soft rounded cord present in the male. It can be felt through the skin as it passes downwards near the medial end of the inguinal ligament to enter the scrotum. It can be picked up between the finger and the thumb. When palpated in this way a firm cord-like structure can be felt within the posterior part of the spermatic cord. This is the *ductus deferens*.
- 9 The anterior abdominal wall is divided into right and left halves by a vertical groove. It marks the position of the underlying *linea alba* (Latin *white line*).

- 10 A little below the middle of the median furrow there is an irregular depressed or elevated area called the *umbilicus* (Latin *navel*). It lies at the level of the junction between third and fourth lumbar vertebrae.
- 11 A few centimetres lateral to the median furrow, the abdominal wall shows a curved vertical groove. Its upper end reaches the costal margin at the tip of the ninth costal cartilage. Inferiorly it reaches the pubic tubercle. This line is called the *linea semilunaris*. It corresponds to the lateral margin of a muscle called the *rectus abdominis*.
- 12 The *transpyloric plane* is an imaginary transverse plane often referred to in anatomical descriptions. Anteriorly, it passes through the tips of the ninth costal cartilages; and posteriorly, through the lower part of the body of the first lumbar vertebra. This plane lies midway between the suprasternal notch and the pubic symphysis. It is roughly a hand's breadth below the xiphisternal joint. It passes through pylorus of stomach, hila of the kidneys, fundus of gallbladder neck of pancreas, origin of coeliac axis and superior mesenteric arteries.
- 13 The angle between the last rib and outer border of erector spinae is known as *renal angle*. It overlies the lower part of kidney. The twelfth rib may only be just palpable lateral to erector spinae or may extend for some distance beyond it.
- 14 *Posterior superior iliac spine* lies about 4 cm lateral to the median plane.
- 15 Three transverse furrows may be seen crossing the upper part of rectus abdominis, corresponding to the tendinous intersections of the muscle. One usually lies opposite the umbilicus, the other opposite free end of xiphoid process, and the third midway between the two (Fig. 16.15).

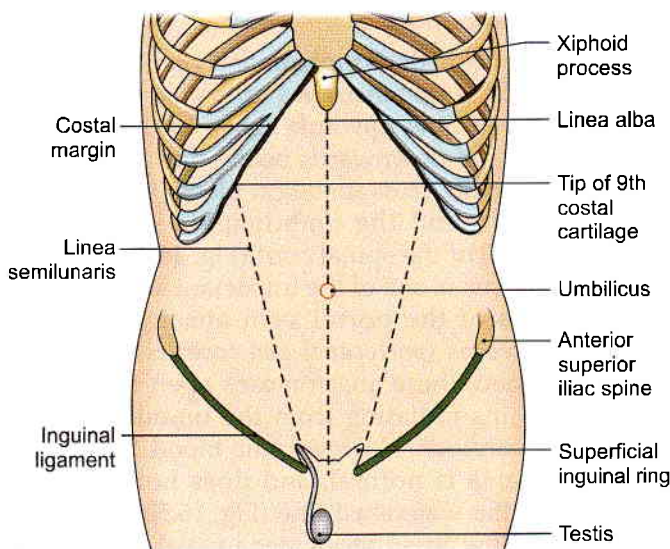


Fig. 16.2: Some superficial features in relation to the anterior abdominal wall

SKIN AND SUPERFICIAL FASCIA

DISSECTION

Give an incision from xiphoid process till the umbilicus. Make a small circular incision around the umbilicus and extend it till the pubic symphysis. Carry the incision laterally from the umbilicus till the lateral abdominal wall on both sides. Give curved incisions 3 cm below from anterior superior iliac spine to pubic symphysis on either side (Fig. 16.3).

Finally give a oblique incision from the xiphoid process along the costal margin till the lateral abdominal wall on either side.

Carefully reflect the skin in four flaps leaving both the layers of superficial fascia on the anterior abdominal wall.



Make a transverse incision through the entire thickness of the superficial fascia from the anterior superior iliac spine to the median plane. Raise the lower margin of the cut fascia and identify its fatty and membranous layers. Note that the fatty layer is continuous with the fascia of adjoining parts of the body.

The membranous layer of anterior abdominal wall is continuous with the similar fascia (Colles' fascia) of the perineum. Note its attachment to pubic arch and posterior margin of *perineal membrane* (inferior fascia of urogenital diaphragm).

Locate the *superficial inguinal ring* immediately superolateral to the pubic tubercle.

Note the anterior cutaneous branch of the *iliohypogastric nerve* piercing the aponeurosis of the external oblique muscle a short distance superior to the ring (Fig. 16.4).

The spermatic cord/round ligament of uterus along with *ilioinguinal nerve* leave the abdomen through the superficial inguinal ring. Identify the external spermatic fascia attaching the spermatic cord to the margins of the ring (refer to 8).

Divide the superficial fascia vertically in the median plane and in the line of the posterior axillary fold as far as the iliac crest.

Reflect the fascia by blunt dissection from these two cuts and find the anterior and lateral cutaneous branches of the lower intercostal nerves along with respective blood vessels coming out from the anterior and lateral regions of the abdominal wall.

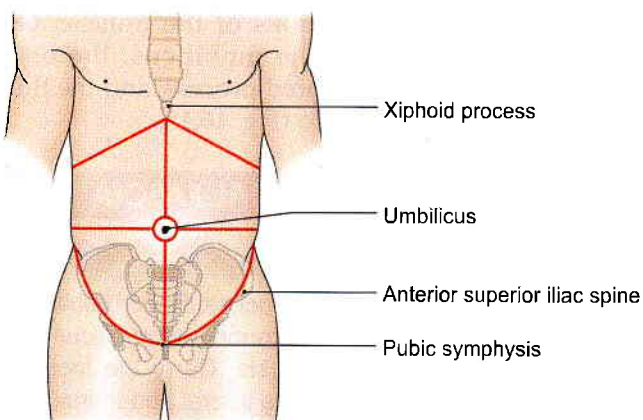


Fig. 16.3: Lines for dissection

THE SKIN

The skin of the anterior abdominal wall is capable of undergoing enormous stretching as is seen in pregnancy; with accumulation of fat, called *obesity* or of fluid called *ascitis*, and with growth of large intra-abdominal tumours.

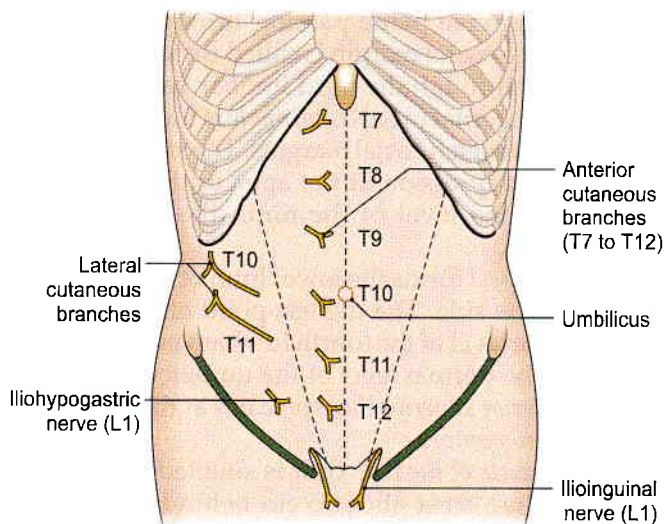


Fig. 16.4: The cutaneous nerves of the anterior abdominal wall

Undue stretching may result in the formation of whitish streaks in the skin of the lower part of the anterior abdominal wall; these are known as *lineae albicantes*.

THE UMBILICUS

Definition

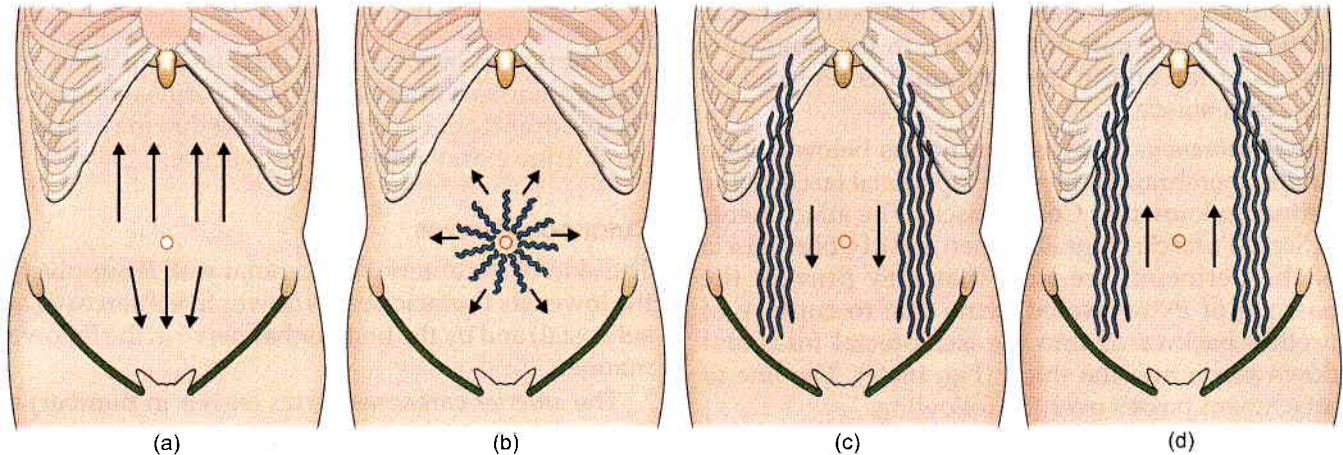
The umbilicus is the normal scar in the anterior abdominal wall formed by the remnants of the root of the *umbilical cord*.

The position of the umbilicus is variable. In healthy adults it lies in the anterior median line, at the level of the disc between the third and fourth lumbar vertebrae. It is lower in infants and in persons with a pendulous abdomen.

Apart from its embryological importance there are several facts of interest about the umbilicus. These are:

Anatomical Importance

- 1 With reference to the lymphatic and venous drainage, the level of the umbilicus is a *watershed*. Lymph and venous blood flow upwards above the plane of the umbilicus; and downwards below this plane. These do not normally cross umbilical plane (Fig. 16.5a).
- 2 The skin around the umbilicus is supplied by segment T10 of the spinal cord (Fig. 16.4).
- 3 The umbilicus is one of the important sites at which tributaries of the portal vein anastomose with systemic veins (*portocaval anastomoses*). In portal hypertension, these anastomoses open up to form dilated veins radiating from the umbilicus called the *caput medusae*. However, the blood flow in the dilated veins is normal, and does not break the barrier of the watershed line (Fig. 16.5b). Direction of blood flow in superior vena caval obstruction (Fig. 16.5c); and in inferior vena caval obstruction shown in Fig. 16.5d.



Figs 16.5a to d: The subcutaneous venous circulation in: (a) Normal subjects, (b) portal obstruction, (c) superior vena caval obstruction, and (d) inferior vena caval obstruction (arrows indicate the direction of blood flow)

Embryological Importance

- 1 Umbilicus is the meeting point of the four (two lateral, head and tail) folds of embryonic plate.
- 2 This is also the meeting point of three systems, namely the digestive (vitellointestinal duct), the excretory (urachus), and vascular (umbilical vessels).

CLINICAL ANATOMY

- Remnants of the vitellointestinal duct may form a tumour at the umbilicus (raspberry red tumour; or cherry red tumour). Persistence of a patent vitellointestinal duct results in a faecal fistula at the umbilicus (Fig. 16.6).
- Persistence of proximal part of vitellointestinal duct is Meckel's diverticulum.
- Persistence of middle part of vitellointestinal duct is enterocoele.
- Persistence of the urachus may form a urinary fistula opening at the umbilicus (Fig. 16.7).
- Umbilical vessels at birth can be identified at the umbilicus. These are two tortuous umbilical arteries and a single umbilical vein. For some clinical conditions, these vessels need to be catheterized.
- Umbilical hernia is seen if any weakness is present at the umbilicus.

SUPERFICIAL FASCIA

- 1 Below the level of the umbilicus, the superficial fascia of the anterior abdominal wall is divided into a superficial fatty layer (*fascia of Camper*) and a deep membranous layer (*fascia of Scarpa*). The various contents of the superficial fascia run between these two layers.

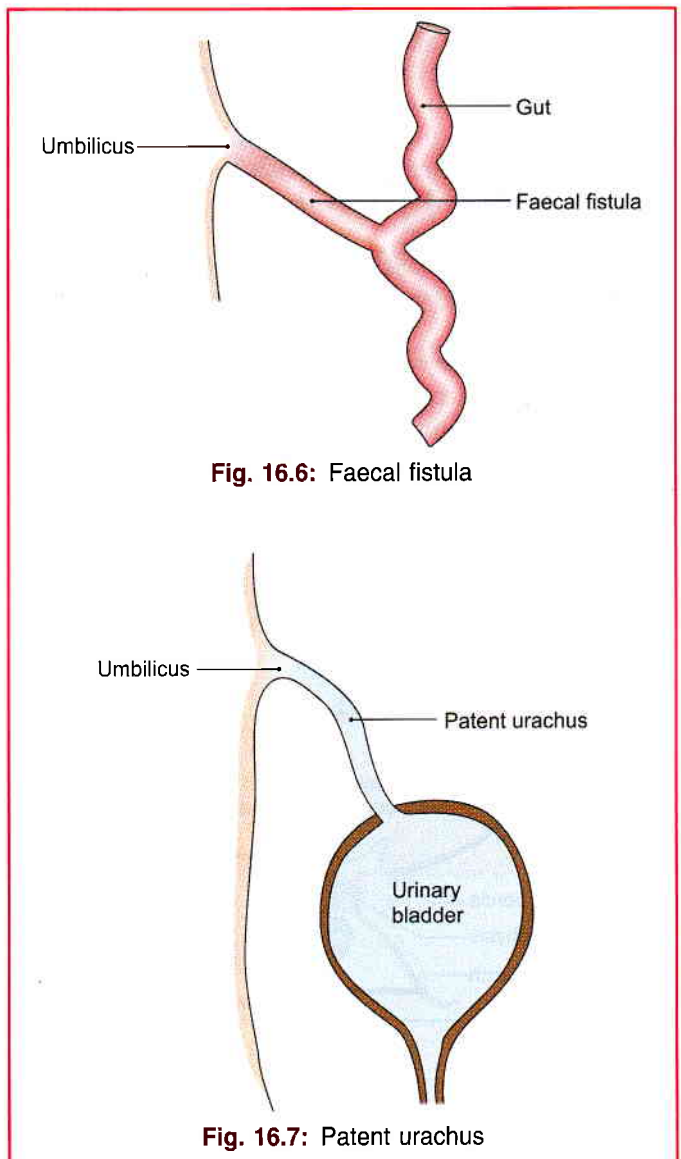


Fig. 16.6: Faecal fistula

Fig. 16.7: Patent urachus



The *fatty layer* is continuous with the superficial fascia of the adjoining part of the body. In the penis, it is devoid of fat, and in the scrotum it is replaced by the *dartos muscle*.

The *membranous layer* is continuous below with a similar membranous layer of superficial fascia of the perineum known as Colles' fascia. The attachments of Scarpa's fascia of the abdomen and of Colles' fascia of the perineum are such that they prevent the passage of extravasated urine due to rupture of urethra backwards into the ischioanal fossa and downwards into the thigh (Fig. 16.8a). The line of attachment passes over the following.

- a. Holden's line (it begins little lateral to pubic tubercle and extends laterally for 8 cm);
 - b. Pubic tubercle;
 - c. Body of the pubis and the deep fascia on the adductor longus and the gracilis near their origin;
 - d. Margins of the pubic arch; and
 - e. The posterior border of the perineal membrane.
 - f. Above the umbilicus the membranous layer merges with the fatty layer.
- 2 In the median plane, the membranous layer is thickened to form the *suspensory ligament and fundiform ligament of the penis or clitoris* (Fig. 16.8b).
 - 3 The fascia contains:
 - a. An extremely variable quantity of fat, which tends to accumulate in the lower part of the abdomen after puberty.
 - b. Cutaneous nerves.
 - c. Cutaneous vessels.
 - d. Superficial lymphatics.

CLINICAL ANATOMY

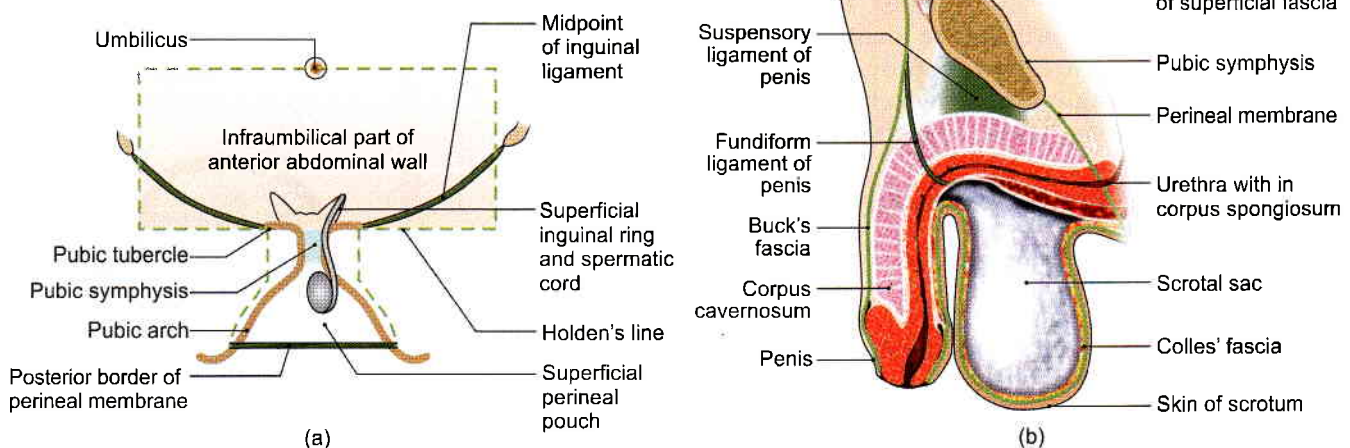
Membranous layer of superficial fascia of abdomen is continuous with the superficial perineal pouch via scrotum and penis. At times the urethra may rupture and urine extravasates into this space.

Cutaneous Nerves

The skin of the anterior abdominal wall is supplied by the lower six thoracic nerves (lower five intercostal and subcostal) and by the first lumbar nerve in the following manner.

The *anterior cutaneous nerves* (seven in number) are derived from the lower five intercostal nerves, the subcostal nerve and the iliohypogastric nerve (L1).

T7–T12 nerves enter the abdominal wall from the intercostal spaces. They pass between internal oblique and transversus muscle, pierce the posterior lamina of internal oblique aponeurosis to enter rectus sheath. Within the sheath, they pass behind rectus abdominis, then pierce the rectus muscles and the anterior wall of the rectus sheath close to the median plane, divide into medial and lateral branches and supply the skin of the front of the abdomen. They are arranged in serial order; T7 near the xiphoid process, T10 at the level of umbilicus, the iliohypogastric nerve 2.5 cm above the superficial inguinal ring, and others at proportionate distances between them (Fig. 16.4). Subcostal nerve supplies pyramidalis while iliohypogastric and ilioinguinal *do not* enter rectus sheath. Iliohypogastric becomes cutaneous 2.5 cm above the superficial inguinal ring (Fig. 16.9).



Figs 16.8a and b: The extent and attachments of the membranous layer of superficial fascia of the abdomen and perineum in a male: (a) Anterior view, and (b) sagittal section

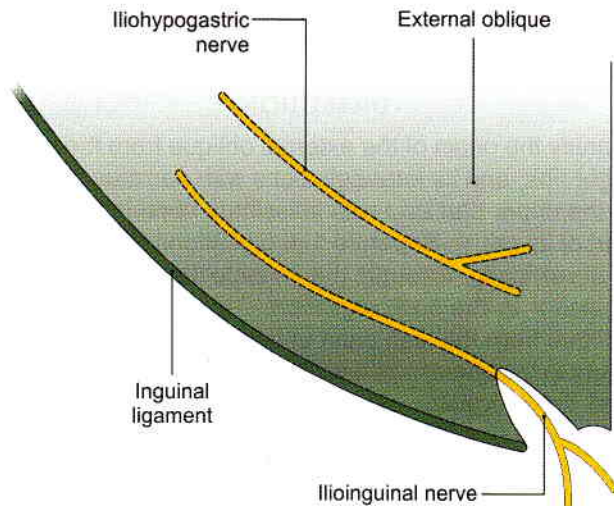


Fig. 16.9: Course of the iliohypogastric and ilioinguinal nerves

The terminal part of the ilioinguinal nerve emerges through the superficial inguinal ring, pierces the external spermatic fascia and descends to supply the skin of the *external genitalia* and the upper part of the medial side of the thigh.

The lateral cutaneous nerves are two in number and are derived from the lower two intercostal nerves (T10, T11). Each nerve pierces the external intercostal muscle and divides into a large anterior branch and a smaller posterior branch, both of which emerge between the lower *digitations of the external oblique muscle* and supply the skin of the side of the abdomen. The larger anterior branches also supply the external oblique muscle (Fig. 16.21).

The lateral cutaneous branches of the subcostal and iliohypogastric (T12, L1) nerves descend over the iliac crest and supply the skin of the anterosuperior part of the gluteal region (see Fig. 5.3).

Cutaneous Arteries

- 1 The *anterior cutaneous arteries* are branches of the *superior and inferior epigastric arteries*, and accompany the anterior cutaneous nerves (Fig. 16.10).
- 2 The *lateral cutaneous arteries* are branches of the lower intercostal arteries, and accompany the lateral cutaneous nerves.
- 3 The *superficial inguinal arteries* arise from the femoral artery and supply the skin of the lower part of the abdomen. The *superficial epigastric artery* runs upwards and medially and supplies the skin up to the umbilicus. The *superficial external pudendal artery* runs medially, to supply the skin of the external genitalia and the adjoining part of the lower abdominal wall. The *superficial circumflex iliac artery* runs laterally just below the inguinal ligament and along the iliac crest to supply the skin of the abdomen and thigh.

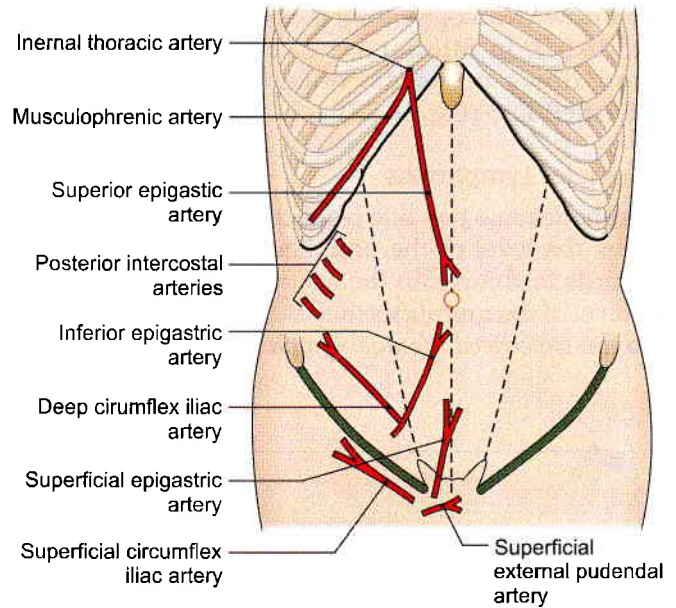


Fig. 16.10: Arteries of the anterior abdominal wall

Cutaneous Veins

The veins accompany the arteries. The superficial inguinal veins drain into the great saphenous vein (see Fig. 3.4).

CLINICAL ANATOMY

- Superior vena cava blockage → backflow in descending order → brachiocephalic → subclavian vein → axillary vein → lateral thoracic vein → thoracoepigastric vein → superficial epigastric vein → great saphenous vein → femoral vein → inferior vena cava → heart (Fig. 16.5c).
- Inferior vena cava blockage → back flow in common iliac → external iliac → femoral → great saphenous → superficial epigastric vein → thoracoepigastric vein → lateral thoracic vein → axillary vein → subclavian vein → brachiocephalic vein → superior vena cava → heart (Fig. 16.5d).

When the portal vein, or the superior vena cava, or the inferior vena cava is obstructed, the superficial abdominal veins are dilated and provide a collateral circulation. The dilated veins that radiate from the umbilicus are given the name *caput medusae* (Fig. 16.5b). They are seen typically in portal obstruction in which blood flow is upwards above the umbilicus, and downwards below the umbilicus. In vena caval obstructions, the *thoracoepigastric veins* open up, connecting the superficial epigastric vein (ending in great saphenous vein) with lateral thoracic vein (ending in axillary vein). In superior vena caval obstruction, the blood in the thoracoepigastric vein



flows downwards, *breaking the barrier of watershed line* (Fig. 16.5c). In inferior vena caval obstruction, the blood flows upwards, once again crossing the watershed line (Fig. 16.5d).

Superficial Lymphatics

Lymphatics also pay due respect to the watershed line. Above the level of the umbilicus the lymphatics run upwards to drain into the *axillary lymph nodes*. Below the level of the umbilicus they run downwards to drain into the *superficial inguinal lymph nodes* (Fig. 16.11).

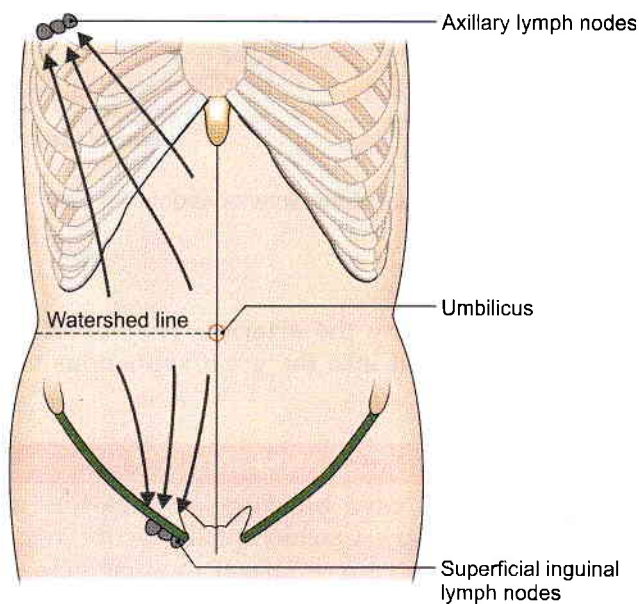


Fig. 16.11: Superficial lymphatics of the anterior abdominal wall

MUSCLES OF THE ANTEROLATERAL ABDOMINAL WALL

The anterolateral abdominal wall is made up mainly of muscles. On either side of the midline there are four large muscles. These are the *external oblique*, the *internal oblique*, the *transversus abdominis* and the *rectus abdominis*. Two small muscles, the *cremaster* and the *pyramidalis* are also present. The external oblique, the internal oblique and the transversus abdominis are large flat muscles placed in the anterolateral part of the abdominal wall. Each of them ends in an extensive aponeurosis that reaches the midline. Here the aponeuroses of the right and left sides decussate to form a median band called the *linea alba*. The rectus abdominis runs vertically on either side of the linea alba. It is enclosed in a *sheath* formed by the aponeuroses of the flat muscles named above. The various muscles are considered one by one below. The actions of these muscles are described later.

EXTERNAL AND INTERNAL OBLIQUE MUSCLES

DISSECTION

Identify the origin of the external oblique from the lower eight ribs, and its interdigitations with serratus anterior in the upper part and with latissimus dorsi in the lower part of its origin. Separate 1–6 digitations from the ribs. Cut vertically, through the muscle to the iliac crest posterior to the sixth digitation. Separate the external oblique from the iliac crest in front of this. Try to avoid injury to the lateral cutaneous branches of the subcostal and iliohypogastric nerves which pierce it close to the iliac crest.

Reflect the upper part of the external oblique forwards and expose the deeper internal oblique and its aponeurosis to the line of its fusion with the aponeurosis of the external oblique anterior to rectus abdominis. Just lateral to this line of fusion divide the external oblique aponeurosis vertically till the pubic symphysis. Turn the muscle and aponeurosis inferiorly. This exposes the inferior part of the internal oblique and the lowest portion of aponeurosis of external oblique, i.e. the *inguinal ligament* (refer to 8).

Identify the deep fibres of the inguinal ligament passing posteriorly to the *pecten pubis*. This is the *lacunar ligament* or pectineal part of the inguinal ligament.

EXTERNAL OBLIQUE MUSCLE

Origin

The muscle arises by eight fleshy slips from the outer surfaces middle of the shaft of the lower eight ribs. The fibres run downwards, forwards and medially (Fig. 16.12).

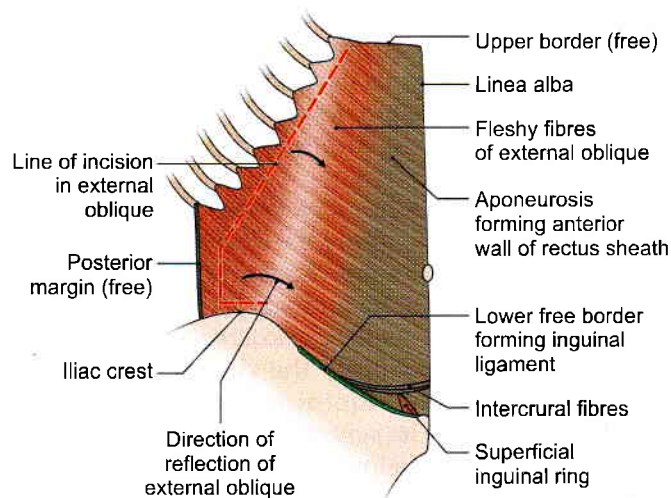


Fig. 16.12: External oblique muscle of the abdomen

**Insertion**

- 1 Most of the fibres of the muscle end in a broad aponeurosis through which they are inserted from above downwards into the xiphoid process, linea alba, pubic symphysis, pubic crest and the pectineal line of the pubis.
- 2 The lower fibres of the muscle are inserted directly into the anterior two-thirds of the outer lip of the iliac crest.

Nerve Supply

Lower six thoracic nerves.

Other Points of Interest

- 1 The upper four slips of origin of the muscle interdigitate with those of the serratus anterior; and the lower four slips with those of the latissimus dorsi.
- 2 The junction of the muscle fibres with the aponeurosis lies:
 - a. Medial to a vertical line drawn from the ninth costal cartilage in the upper part.
 - b. Below a line joining the anterior superior iliac spine to the umbilicus. Above the ninth costal cartilage the line curves upwards and medially.
- 3 Between the anterior superior iliac spine and the pubic tubercle the aponeurosis has a free inferior border that is folded on itself to form the *inguinal (Latin groin) ligament*. The ligament is described in detail later.
- 4 Between the linea semilunaris and the linea alba, the aponeurosis helps to form the anterior wall of rectus sheath.
- 5 Just above the pubic crest the aponeurosis of the external oblique muscle presents a triangular aperture called the *superficial inguinal ring* (Fig. 16.12).
- 6 The muscle has free posterior and upper borders.

INTERNAL OBLIQUE MUSCLE**Origin**

The muscle arises from:

- a. The lateral two-thirds of the inguinal ligament (Fig. 16.13).
- b. The anterior two-thirds of the intermediate area of the iliac crest, and
- c. The thoracolumbar fascia (see Fig. 24.11).

From this origin the fibres run upwards, forwards and medially crossing the fibres of the external oblique muscle at right angles.

Insertion

- 1 The uppermost fibres are inserted directly into the lower three or four ribs and their cartilages.
- 2 The greater part of the muscle ends in an aponeurosis through which it is inserted into the seventh, eighth

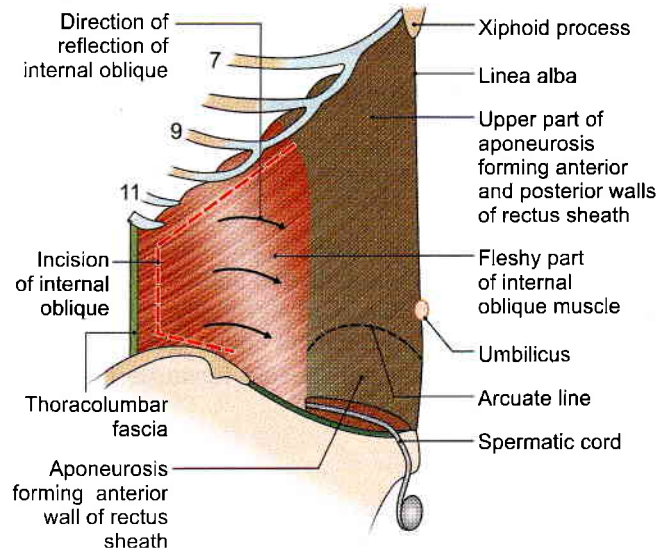


Fig. 16.13: Internal oblique muscle of the abdomen

and ninth costal cartilages, the xiphoid process, linea alba, pubic crest and the pectineal line of the pubis (Fig. 16.13). It does not extend beyond the costal margin.

Nerve Supply

Lower six thoracic nerves and the first lumbar nerve.

Other Points of Interest

- 1 The junction of the muscle fibres with the aponeurosis is roughly at the lateral border of the rectus abdominis.
- 2 The aponeurosis takes part in the formation of *rectus sheath* as follows. Up to the lateral margin of rectus abdominis, the aponeurosis has only one layer. Thereafter, the arrangement of aponeurosis differs in its upper and lower parts.
 - a. Below a level midway between the umbilicus and the pubic symphysis (lower 1/4th of the wall) the aponeurosis remains a single layer. It passes in front of rectus abdominis to reach linea alba. It, thus, takes part in forming the anterior wall of rectus sheath.
 - b. Above this level, i.e. upper 3/4th of the wall, the aponeurosis splits into an anterior lamina that passes medially in front of the rectus abdominis; and a posterior lamina that lies behind the rectus. The posterior lamina ends below, at the level midway between the umbilicus and the pubic symphysis, in a free curved margin called the *arcuate line* or *linea semicircularis*, or *fold of Douglas*. The line is concave downwards.
- 3 The *conjunct tendon* is formed partly by this muscle.
- 4 The *cremaster* muscle is formed by fibres of this muscle, and is described later.



TRANSVERSUS ABDOMINIS MUSCLE

DISSECTION

Lift the internal oblique and cut carefully through its attachments to the inguinal ligament, iliac crest and costal margin.

Carefully preserve the nerves of the anterior abdominal wall which lie between internal oblique and transversus abdominis. Cut vertically through the internal oblique from the twelfth costal cartilage to the iliac crest and reflect the muscle forwards from the transversus and the nerves.

FEATURES

Origin

The muscle has a fleshy origin from:

- 1 The lateral one-third of the inguinal ligament.
- 2 The anterior two-thirds of the inner lip of the iliac crest.
- 3 The thoracolumbar fascia (see Fig. 24.11).
- 4 The inner surfaces of the lower six costal cartilages. The fibres are directed horizontally forwards.

Insertion

The fibres end in a broad aponeurosis which is inserted into the xiphoid process, the linea alba, the pubic crest, and the pectineal line of the pubis (Fig. 16.14).

The lowest fibres of the muscle fuse with the lowest fibres of the internal oblique to form the *conjoint tendon*.

Nerve Supply

Lower six thoracic nerves, and first lumbar nerve.

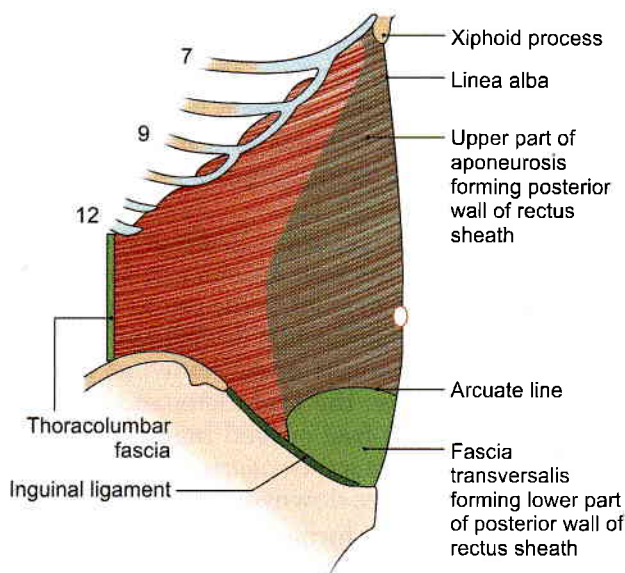


Fig. 16.14: Transversus abdominis muscle

Other Points of Interest

- 1 The aponeurosis of the transversus abdominis takes part in forming the rectus sheath as follows. Above the level of the arcuate line (upper 3/4th) the aponeurosis passes medially behind the rectus abdominis muscle along with the posterior lamina of the internal oblique aponeurosis. The lower edge of this part of the aponeurosis helps to form the *arcuate line*. In the uppermost part, some fleshy fibres of the transversus abdominis may lie behind the rectus abdominis. Below the level of the arcuate line the aponeurosis passes in front of the rectus abdominis and helps to form the anterior wall of the rectus sheath.
- 2 The *neurovascular plane* of the abdominal wall lies between the *internal oblique* and *transversus muscles*. This plane is continuous with the neurovascular plane of the thoracic wall. Various nerves and vessels run in this plane.
- 3 The aponeuroses of three flat muscles seem to end in the fibrous raphe—the *linea alba*. Each aponeurosis is made up of the two laminae, the superficial and deep laminae. The laminae of the two sides interdigitate in a manner that the superficial lamina of one gets continuous with deep lamina of the opposite side and vice versa. This provides enough strength to the anterior abdominal wall.

RECTUS ABDOMINIS MUSCLE

Origin

The muscle arises by two tendinous heads as follows.

- 1 *Lateral head* from the lateral part of the pubic crest (Fig. 16.15).
- 2 *Medial head* from the anterior pubic ligament. The fibres run vertically upwards.

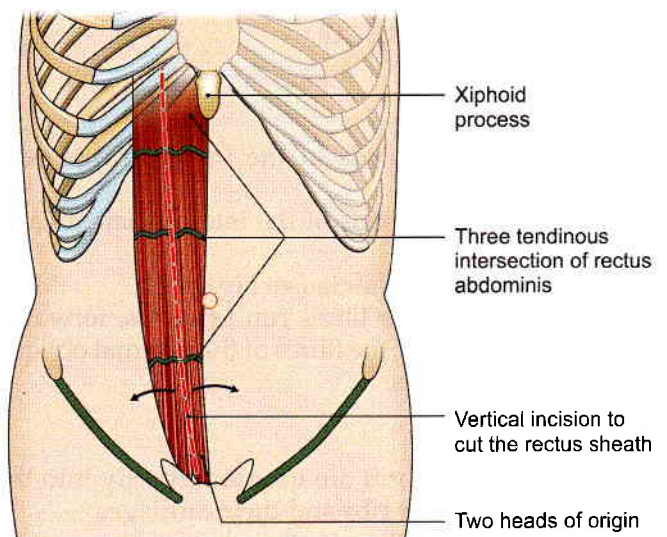


Fig. 16.15: Rectus abdominis muscle



Insertion

On the front of the wall of the thorax, along a horizontal line passing laterally from the xiphoid process, and cutting in that order, the 7th, 6th and 5th costal cartilages.

Nerve Supply

Lower six or seven thoracic nerves.

Other Points of Interest

- 1 The muscle is enclosed in a sheath formed mainly by the aponeuroses of the three flat muscles of the abdominal wall. The sheath is described later.
- 2 *Tendinous intersections*: These are three transverse fibrous bands which divide the muscle into smaller parts. One lies opposite the umbilicus, the second opposite the free end of the xiphoid process, and the third in between the two. One or two incomplete intersections may be present below the umbilicus. The intersections are actually zigzag in course, traverse only the anterior half of the muscle, and are adherent to the anterior wall of rectus sheath. Embryologically they may represent the segmental origin of muscle, but functionally they make the muscle more powerful by increasing the number of muscle fibres.

ACTIONS OF THE MAIN MUSCLES OF THE ANTERIOR ABDOMINAL WALL

- 1 *Support for abdominal viscera*: The abdominal muscles provide a firm but elastic support for the abdominal viscera against gravity. This is chiefly due to the tone of the oblique muscles, especially the internal oblique.
- 2 *Expulsive acts*: The oblique muscles, assisted by the transversus, can compress the abdominal viscera and thus help in all expulsive acts, like micturition, defaecation, parturition, vomiting, etc. This is one of the most important actions of the abdominal muscles.
- 3 *Forceful expiratory acts*: The external oblique can markedly depress and compress the lower part of the thorax producing forceful expiration, as in coughing, sneezing, blowing, shouting, etc. This is also an important action of the abdominal muscles.
- 4 *Movements of the trunk*:
 - a. Flexion of the trunk or lumbar spine is brought about mainly by the rectus abdominis.
 - b. Lateral flexion of the trunk is done by one sided contraction of the oblique muscles.
 - c. Rotation of the trunk is produced by a combined action of the external oblique with the opposite internal oblique.

INGUINAL LIGAMENT

- 1 The inguinal or Poupart's ligament is formed by the lower border of the external oblique aponeurosis which is thickened and folded backwards on itself. It extends from the anterior superior iliac spine to the pubic tubercle, and lies beneath the fold of the groin. Its lateral half is rounded and oblique. Its medial half is grooved upwards and is more horizontal (Fig. 16.16).
- 2 *Attachments*:
 - a. The fascia lata is attached to the lower border. Traction of this fascia makes the ligament convex downwards.
 - b. The upper surface of the ligament gives origin to the internal oblique from its lateral two-thirds, to the transversus abdominis from its lateral one-third, and to the cremaster muscle from its middle part.
- 3 *Relations*: The upper grooved surface of the medial half of the inguinal ligament forms the floor of the inguinal canal and lodges the spermatic cord or round ligament of the uterus.
- 4 *Extensions*:
 - a. The *pectineal part of the inguinal ligament* or lacunar ligament is triangular. Anteriorly, it is attached to the medial end of the inguinal ligament. Posteriorly, it is attached to the pecten pubis. It is horizontal in position and supports the spermatic cord. The apex is attached to the pubic tubercle. The base is directed laterally. It forms the medial boundary of the femoral ring. It is reinforced by the pectineal fascia and by fibres from the linea alba (Fig. 16.16).
 - b. The *pectineal ligament* or *ligament of Cooper* is an extension from the posterior part of the base of the lacunar ligament. It is attached to the pecten

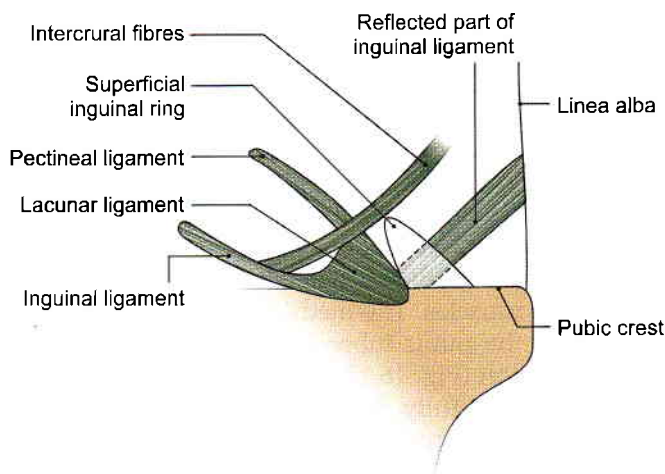


Fig. 16.16: Extensions of the inguinal ligament



pubis. It may be regarded as a thickening in the upper part of the pectineal fascia.

- c. The *reflected part of the inguinal ligament* consists of fibres that pass upwards and medially from the lateral crus of the superficial inguinal ring. It lies behind the superficial inguinal ring and in front of the conjoint tendon. Its fibres interlace with those of the opposite side at the linea alba.

CREMASTER MUSCLE AND CONJOINT TENDON

DISSECTION

Identify internal oblique deep to external oblique muscle. Remove the fascia from the surface of the internal oblique and its aponeurosis.

Identify the part of the internal oblique which passes around the spermatic cord. This is the *cremaster muscle*.

Trace the fibres of internal oblique into the conjoint tendon.

Dissect the *triple* relation of internal oblique to the inguinal canal.

CONJOINT TENDON OR FALX INGUINALIS

The conjoint tendon is formed by fusion of the lowest aponeurotic fibres of the internal oblique and of the transversus muscles, attached to the pubic crest and to the medial part of the pecten pubis. Medially, it is continuous with the anterior wall of the rectus sheath. Laterally, it is usually free. Sometimes it may be continuous with an inconstant ligamentous band, named the *interfoveolar ligament*, which connects the lower border of the transversus abdominis to the superior ramus of the pubis. The conjoint tendon strengthens the abdominal wall at the site where it is weakened by the superficial inguinal ring (Figs 16.17 and 16.26a).

THE CREMASTER MUSCLE

The cremaster muscle consists of muscle fasciculi embedded in the *cremasteric fascia*. The fasciculi form superficial loops from middle one-third of upper surface of inguinal ligament and deep loops from pubic tubercle, pubic crest and conjoint tendon. Here some fibres may be continuous with the internal oblique or transversus muscles. The medial ends of the loops are attached to the pubic tubercle, the pubic crest or the conjoint tendon (Fig. 16.17).

The muscle is fully developed only in the male. In the female it is represented by a few fibres only.

Along with the intervening connective tissue, the muscle loops to form a sac-like *cremasteric fascia* around

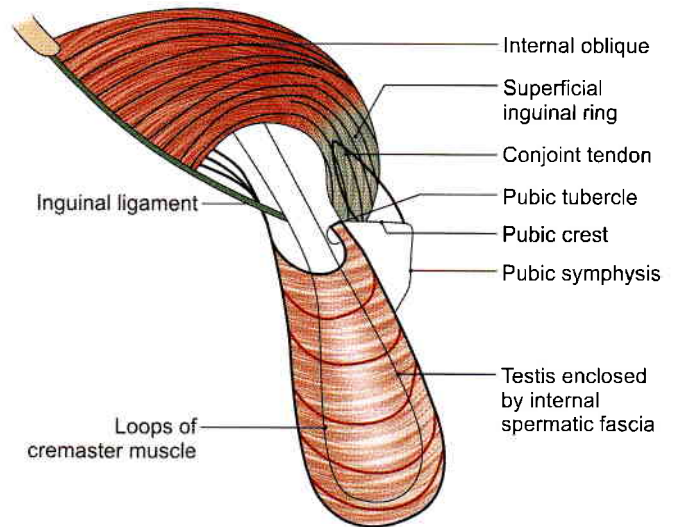


Fig. 16.17: The cremaster muscle

the spermatic cord and testis. It lies deep to the *external spermatic fascia* (see Fig. 17.4).

Nerve Supply

Genital branch of the genitofemoral nerve (L1).

Action

The cremaster helps to suspend the testis and can elevate it. The muscle also tends to close the superficial inguinal ring when the intra-abdominal pressure is raised.

Cremasteric Reflex

Upon stroking the skin of the upper part of the medial side of the thigh there is reflex contraction of the cremaster muscle, as evidenced by elevation and retraction of the testis. The reflex is more brisk in children. In upper motor neuron lesions above segment L1, the reflex is lost (Fig. 16.18).

CLINICAL ANATOMY

- While examining the abdomen, the knees and hip must be flexed to relax the abdominal muscles.
- Muscles of anterior abdominal wall contract during the expiratory phase of respiration.
- Due to lack of exercise, the tone of muscles of the anterior abdominal wall decreases leading to protrusion of the wall. This is called *visceroptosis*.
- The anterior abdominal wall is punctured for various procedures, like surgeries of gallbladder, vermiform appendix, etc.
- *Supraumbilical median incisions* through the linea alba have several advantages as being bloodless; safety to muscles and nerves but tend to leave a postoperative weakness through which a ventral



hernia may develop. *Infraumbilical median incisions* are safer because the close approximation of recti prevents formation of any ventral hernia. *Paramedian incisions* through the rectus sheath are more sound than median incisions. The rectus muscle is *retracted laterally* to protect the nerves supplying it from any injury. In these cases, the subsequent risk of weakness and of incisional or ventral hernia are minimal (Fig. 16.19).

- The nerves of anterior abdominal wall, T7–T12 and L1 supply skin, intercostal muscles and parietal pleura. In addition these supply skin, muscles of the abdominal wall and parietal peritoneum. Tubercular infection of lung and pleura may cause radiating pain in the abdominal wall. Peritonitis causes reflex contraction of the abdominal muscles.
- During repair of the wounds of anterior abdominal wall, the nerves T7–T12 need to be anaesthetised along the costal margin. Iliohypogastric and ilioinguinal nerves are anaesthetised by a needle above the anterior superior iliac spine on the spinoumbilical line.

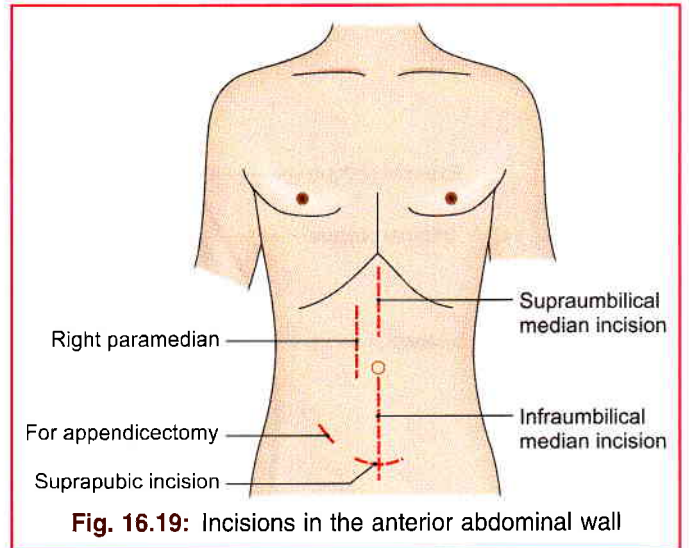


Fig. 16.19: Incisions in the anterior abdominal wall

DEEP NERVES OF THE ANTERIOR ABDOMINAL WALL

The anterior abdominal wall is supplied by the lower six thoracic nerves or lower five intercostal, and subcostal; and by the first lumbar nerve through its iliohypogastric and ilioinguinal branches. These are the nerves which emerge as cutaneous nerves. Their deep course is described briefly with the cutaneous nerves in the beginning of this chapter (Figs 16.9 and 16.20).

DEEP ARTERIES OF ANTERIOR ABDOMINAL WALL

The anterior abdominal wall is supplied by:

- 1 Two large arteries from above, the *superior epigastric* and *musculophrenic* (Fig. 16.10).
- 2 Two large arteries from below, the *inferior epigastric* and the *deep circumflex iliac*.
- 3 Small branches of the intercostal, subcostal and lumbar arteries, which accompany the corresponding nerves (Fig. 16.21).

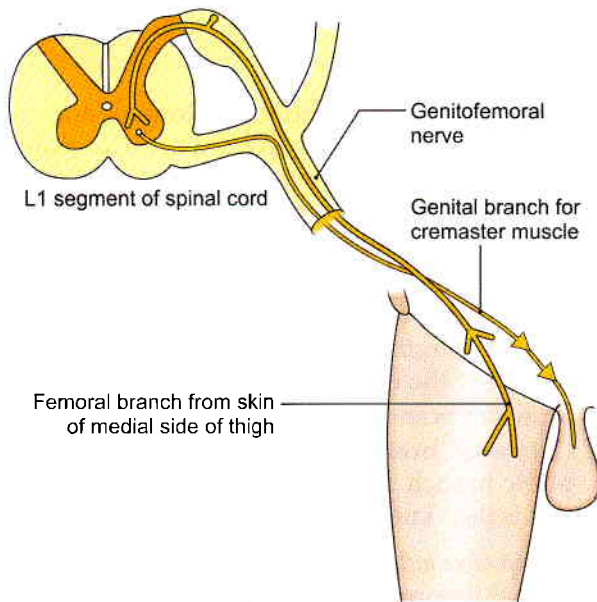


Fig. 16.18: Cremasteric reflex

PYRAMIDALIS

This is a small triangular muscle. It is rudimentary in human beings. It arises from the anterior surface of the body of the pubis. Its fibres pass upwards and medially to be inserted into the linea alba.

The muscle is supplied by the subcostal nerve (T12). It is said to be tensor of the linea alba, but the need for such action is not clear.

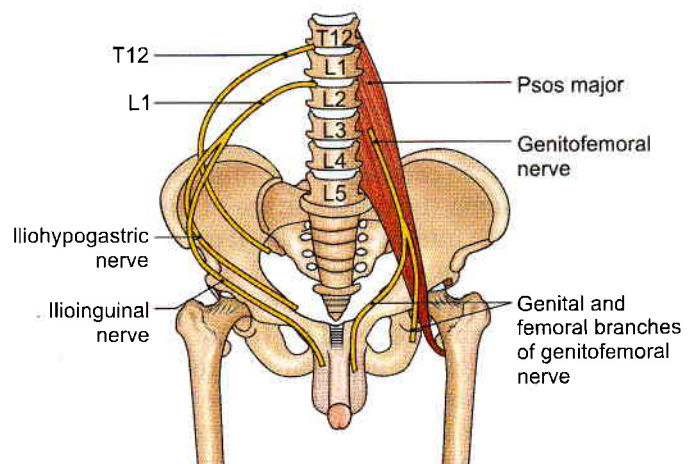


Fig. 16.20: Nerves of anterior abdominal wall

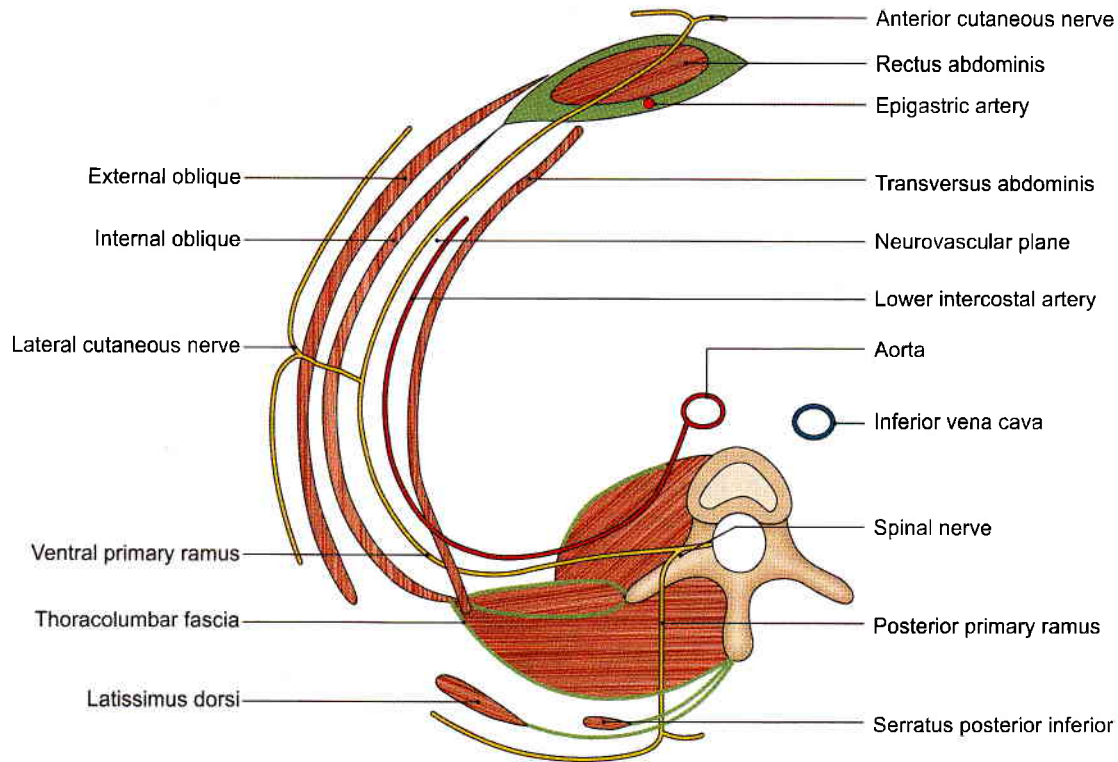


Fig. 16.21: A transverse section through the lumbar region showing the arrangement of the abdominal muscles and the neurovascular plane

The *superior epigastric artery* is one of the two terminal branches of the internal thoracic artery. It begins in the sixth intercostal space, and enters the abdomen by passing behind the seventh costal cartilage between the costal and xiphoid origins of the diaphragm. It enters the rectus sheath and runs vertically downwards, supplies the rectus muscle, and ends by anastomosing with the inferior epigastric artery. In addition to muscular and cutaneous branches, it gives a *hepatic branch* which runs in the *falciform ligament*, and an anastomotic branch, at the level of the xiphoid process, which anastomoses with the artery of the opposite side.

The *musculophrenic artery* is the other terminal branch of the internal thoracic artery. It runs downwards and laterally behind the seventh costal cartilage, and enters the abdomen by piercing the diaphragm between the seventh and eighth cartilages. It continues downwards and laterally along the deep surface of the diaphragm as far as the tenth intercostal space. It gives branches to the diaphragm, the anterior abdominal wall and the seventh, eighth and ninth intercostal spaces as the anterior intercostal arteries (Fig. 16.10).

The *inferior epigastric artery* arises from the external iliac artery near its lower end just above the inguinal ligament. It runs upwards and medially in the extraperitoneal connective tissue, passes just medial to the deep inguinal ring, pierces the fascia transversalis

at the lateral border of the rectus abdominis and enters the rectus sheath by passing in front of the arcuate line (Fig. 16.10). Within the sheath it supplies the rectus muscle and ends by anastomosing with the superior epigastric artery. It gives off the following branches.

- A *cremasteric branch* to the spermatic cord, in males or the artery of the round ligament in females.
- A *pubic branch* which anastomoses with the pubic branch of the obturator artery.
- Muscular* branches to the rectus abdominis.
- Cutaneous* branches to the overlying skin. The pubic branch may replace the obturator artery, and is then known as the *abnormal obturator artery*.

The *deep circumflex iliac artery* is the other branch of the external iliac artery, given off from its lateral side opposite the origin of the inferior epigastric artery. It runs laterally and upwards behind the inguinal ligament, pierces the fascia transversalis, and continues along the iliac crest, up to its middle where it pierces the transversus abdominis to enter the interval between the transversus and the internal oblique muscles. At the anterior superior iliac spine it anastomoses with the superior gluteal, the lateral circumflex femoral and superficial circumflex iliac arteries. Just behind the anterior superior iliac spine it gives off an ascending branch which runs upwards in the neurovascular plane.



RECTUS SHEATH

DISSECTION

Identify the rectus abdominis muscle. At the lateral edge of the rectus abdominis, the aponeurosis of the internal oblique splits to pass partly posterior and partly anterior to the rectus abdominis; the anterior layer fusing with the aponeurosis of external oblique and the posterior layer with that of the transversus abdominis. This is how most of the rectus sheath is formed. Identify the arcuate line midway between umbilicus and pubic symphysis.

Define the origins of the transversus and follow its aponeurosis to fuse with that of the internal oblique, posterior to the rectus abdominis above the arcuate line and anteriorly to the unsplit aponeurosis of internal oblique below the line. See that aponeurosis of all three muscles pass anterior to rectus abdominis below the arcuate line.

Open the rectus sheath by a vertical incision along the middle of the muscle. Reflect the anterior layer of the sheath side ways, cutting its attachments to the tendinous intersections in the anterior part of the rectus muscle (Fig. 16.15).

Lift the rectus muscle and identify the 7–11 intercostal and subcostal nerves entering the sheath through its posterior lamina, piercing the muscle and leaving through its anterior wall.

Divide the rectus abdominis transversely at its middle. Identify its attachments and expose the posterior wall of the rectus sheath by reflecting its parts superiorly and inferiorly. Identify and trace the superior and inferior epigastric arteries.

Define the arcuate line on the posterior wall of the rectus sheath.

RECTUS SHEATH

Definition

This is an aponeurotic sheath covering the rectus abdominis. It has two walls, anterior and posterior.

Features

Anterior Wall

- 1 It is complete, covering the muscle from end to end.
- 2 Its composition is variable as described below.
- 3 It is firmly adherent to the tendinous intersections of the rectus muscle (Fig. 16.22).

Posterior Wall

- 1 It is incomplete, being deficient above the costal margin and below the arcuate line.
- 2 Its composition is variable as described below.
- 3 It is free from the rectus muscle (Fig. 16.19).

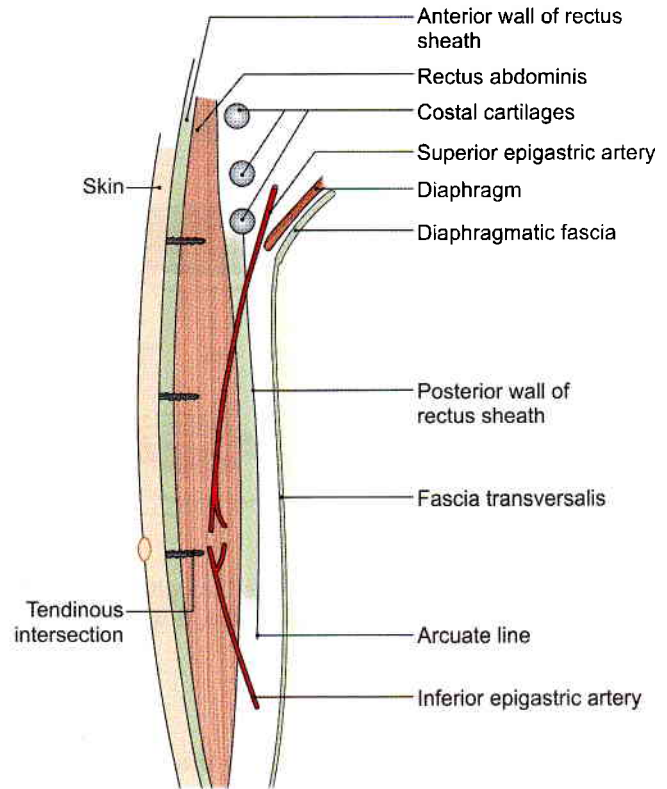


Fig. 16.22: Sagittal section through the rectus sheath

Medial Wall

Fusion of all the aponeuroses in the midline. It is called as linea alba.

Lateral Wall

It is called linea semilunaris, it extends from tip of 9th costal cartilage to pubic tubercle.

Formation

Details about the formation of the walls are as follows (Figs 16.23a and b).

Above the costal margin

Anterior wall: External oblique aponeurosis (Fig. 16.23a).

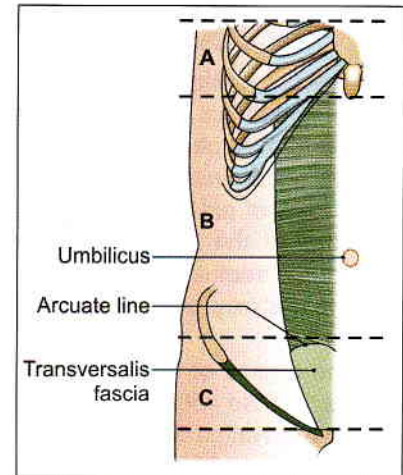
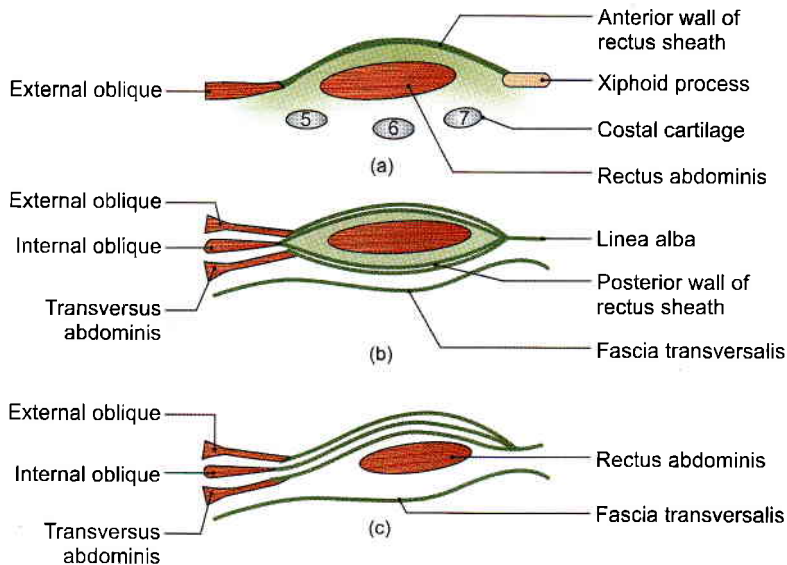
Posterior wall: It is deficient; the rectus muscle rests directly on the 5th, 6th and 7th costal cartilages.

Between the costal margin and the arcuate line

Anterior wall: External oblique aponeurosis and anterior lamina of the aponeurosis of the internal oblique.

Posterior wall: Posterior lamina of the aponeurosis of the internal oblique and aponeurosis of the transversus muscle (Fig. 16.23b).

Midway between the umbilicus and the pubic symphysis, the posterior wall of the rectus sheath ends in the arcuate line or *linea semicircularis* or *fold of Douglas*. The line is concave downwards.



Figs 16.23a to c: Transverse sections through the rectus abdominis, and its sheath: (a) Above the costal margin, A of inset, (b) between costal margin and arcuate line, B of inset and (c) below arcuate line, C of inset

Below the arcuate line

Anterior wall: Aponeuroses of all the three flat muscles of the abdomen. The aponeuroses of the transversus and the internal oblique are fused, but the external oblique aponeurosis remains separate (Fig. 16.23c).

Posterior wall: It is deficient. The rectus muscle rests on the fascia transversalis.

Contents

Muscles

- 1 The *rectus abdominis* is the chief and largest content.
- 2 The *pyramidalis* (if present) lies in front of the lower part of the rectus abdominis.

Arteries

- 1 The *superior epigastric artery* enters the sheath by passing between the costal and xiphoid origins of the diaphragm. It crosses the upper border of the transversus abdominis behind the seventh costal cartilage. It supplies the rectus abdominis muscle and anastomoses with the inferior epigastric artery (Fig. 16.22).
- 2 The *inferior epigastric artery* enters the sheath by passing in front of the arcuate line.

Veins

- 1 The *superior epigastric vena comitantes* accompany its artery and join the vena comitantes of internal thoracic vein.
- 2 The *inferior epigastric vena comitantes* accompany its artery and join the external iliac vein.

Nerves

These are the terminal parts of the lower six thoracic nerves, including the *lower five intercostal nerves* and the *subcostal nerves* (Fig. 16.21).

Functions

- 1 It checks bowing of rectus muscle during its contraction and thus increases the efficiency of the muscle.
- 2 It maintains the strength of the anterior abdominal wall.

NEW CONCEPT OF RECTUS SHEATH

Rectus sheath is formed by decussating fibres from three abdominal muscles of each side. Each forms a bilaminar aponeurosis at their medial borders. Fibres from all three anterior leaves run obliquely upwards, while the posterior fibers run obliquely downwards at right angles to anterior leaves.

Anterior Sheath of Rectus

Both leaves of external oblique aponeurosis and anterior leaf of internal oblique aponeurosis.

Posterior Sheath

Posterior leaf of aponeurosis of internal oblique and both leaves of aponeurosis of transversus abdominis.

Fibres of each layer decussate to the opposite side of the sheath. Fibres also decussate between anterior and posterior sheaths.

The three lateral abdominal muscles may be said to be digastric with a central tendon in the form of linea alba.



Linea alba is a tendinous raphe between xiphoid process above to symphysis pubis and pubic crest below. Above the umbilicus the linea alba is broader. Superficial fibres of linea alba are attached to symphysis pubis, while deep fibres are attached behind rectus abdominis to posterior surface of pubic crest.

THE FASCIA TRANSVERSALIS

Definition

The inner surface of the abdominal muscles is lined by fascia which is separated from peritoneum by extra-peritoneal connective tissue. That part of the fascia which lines the inner surface of the transversus abdominis muscle is called the fascia transversalis (Fig. 16.24a).

Extent

Anteriorly: It is adherent to the linea alba above the umbilicus.

Posteriorly: It merges with the anterior layer of the thoracolumbar fascia and is continuous with the renal fascia (Fig. 16.24b).

Superiorly: It is continuous with the diaphragmatic fascia.

Inferiorly: It is attached to the inner lip of the iliac crest and to the lateral half of the inguinal ligament. At both these places it is continuous with the fascia iliaca.

Medially it is attached to the pubic tubercle, the pubic crest and the pectineal line.

Part of it is prolonged into the thigh as the anterior wall of the femoral sheath.

Opening of Deep Inguinal Ring

About 1.2 cm above the midinguinal point there is an oval opening in the fascia transversalis. This opening is the deep inguinal ring (Fig. 16.25). The ring lies

immediately lateral to the inferior epigastric artery. It transmits the spermatic cord in males, and the round ligament of the uterus in females.

Prolongations

- 1 A tubular prolongation of the fascia transversalis surrounds the spermatic cord forming the *internal spermatic fascia*.
- 2 Over the femoral vessels, the fascia transversalis is prolonged into the thigh as the *anterior wall of femoral sheath* (see Fig. 3.14).

Relation to Vessels and Nerves

The main arteries of the abdominal wall and pelvis lie inside the fascia transversalis, while the main nerves are outside. That is why the femoral vessels are inside the femoral sheath, while the femoral nerve is outside the sheath (see Fig. 3.10b).

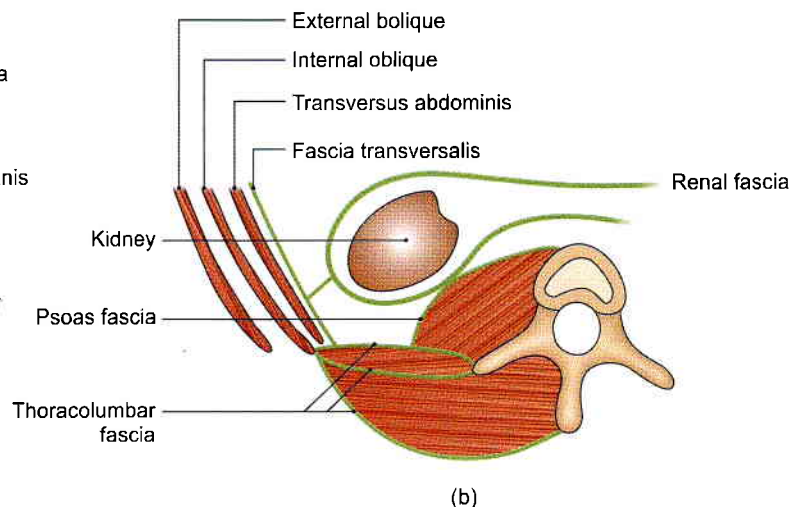
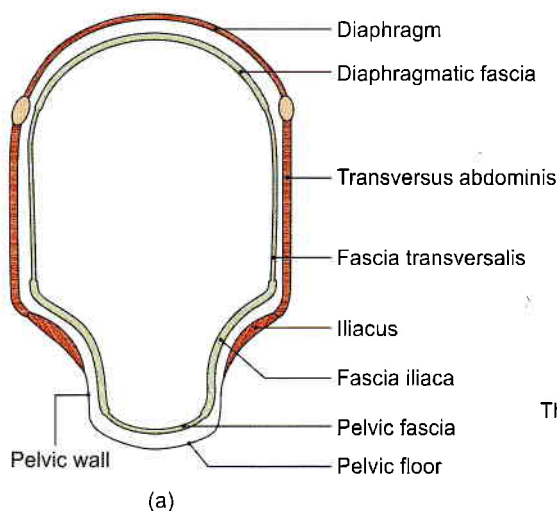
INGUINAL CANAL

DISSECTION

Identify again the superficial inguinal ring above the pubic tubercle. It lies in the aponeurosis of external oblique muscle and provides the external spermatic fascia to the spermatic cord/round ligament of uterus.

Identify internal oblique muscle deep to external oblique. Note that its fibres lie anterior to deep inguinal ring, then arch over the inguinal canal and finally fuse with the fibres of transversus abdominis to form the conjoint tendon attached to pubic crest and pecten pubis.

Lastly identify the deep inguinal ring in the fascia transversalis situated 1.2 cm above the midinguinal point. This fascia provides the internal spermatic fascia to the spermatic cord/round ligament of uterus.



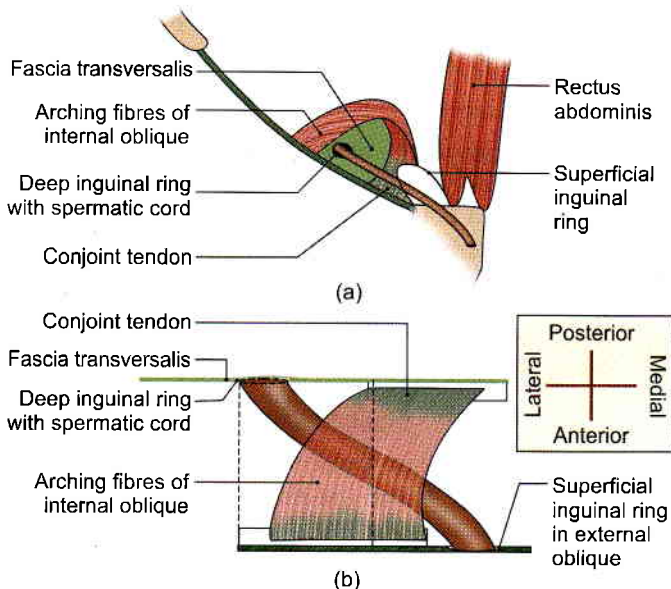
Figs 16.24a and b: Continuation of the fascia transversalis: (a) Coronal section, and (b) transverse section



DEFINITION

This is an oblique intermuscular passage in the lower part of the anterior abdominal wall, situated just above the medial half of the inguinal ligament.

Length and direction: It is about 4 cm (1.5 inches) long, and is directed downwards, forwards and medially (Figs 16.25a and b).



Figs 16.25a and b: (a) Superficial and deep inguinal rings, and (b) formation of the roof of inguinal canal

The inguinal canal extends from the deep inguinal ring to the superficial inguinal ring.

The *deep inguinal ring* is an oval opening in the fascia transversalis, situated 1.2 cm above the midinguinal point, and immediately lateral to the stem of the inferior epigastric artery.

The *superficial inguinal ring* is a triangular gap in the external oblique aponeurosis. It is shaped like an obtuse angled triangle. The base of the triangle is formed by the pubic crest. The two sides of the triangle form the lateral or lower and the medial or upper margins of the opening. It is 2.5 cm long and 1.2 cm broad at the base. These margins are referred to as *crura*. At and beyond the apex of the triangle, the two crura are united by intercrural fibres (Fig. 16.12).

BOUNDARIES

The Anterior Wall

- In its whole extent:*
 - Skin
 - Superficial fascia
 - External oblique aponeurosis.
- In its lateral one-third:* The fleshy fibres of the internal oblique muscle (Fig. 16.26a).

The Posterior Wall

- In its whole extent:*
 - The fascia transversalis
 - The extraperitoneal tissue
 - The parietal peritoneum.
- In its medial two-thirds:*
 - The conjoint tendon
 - At its medial end by the reflected part of the inguinal ligament.

Roof

It is formed by the arched fibres of the internal oblique and transversus abdominis muscles (Figs 16.25a and b).

Floor

It is formed by the grooved upper surface of the inguinal ligament; and at the medial end by the lacunar ligament (Fig. 16.26b).

Sex Difference

The inguinal canal is larger in males than in females.

STRUCTURES PASSING THROUGH THE CANAL

- The *spermatic cord in males*, or the *round ligament of the uterus in females*, enters the inguinal canal through the deep inguinal ring and passes out through the superficial inguinal ring (Fig 16.2).
- The ilioinguinal nerve enters the canal through the interval between the external and internal oblique muscles and passes out through the superficial inguinal ring (Fig. 16.9).

CONSTITUENTS OF THE SPERMATIC CORD

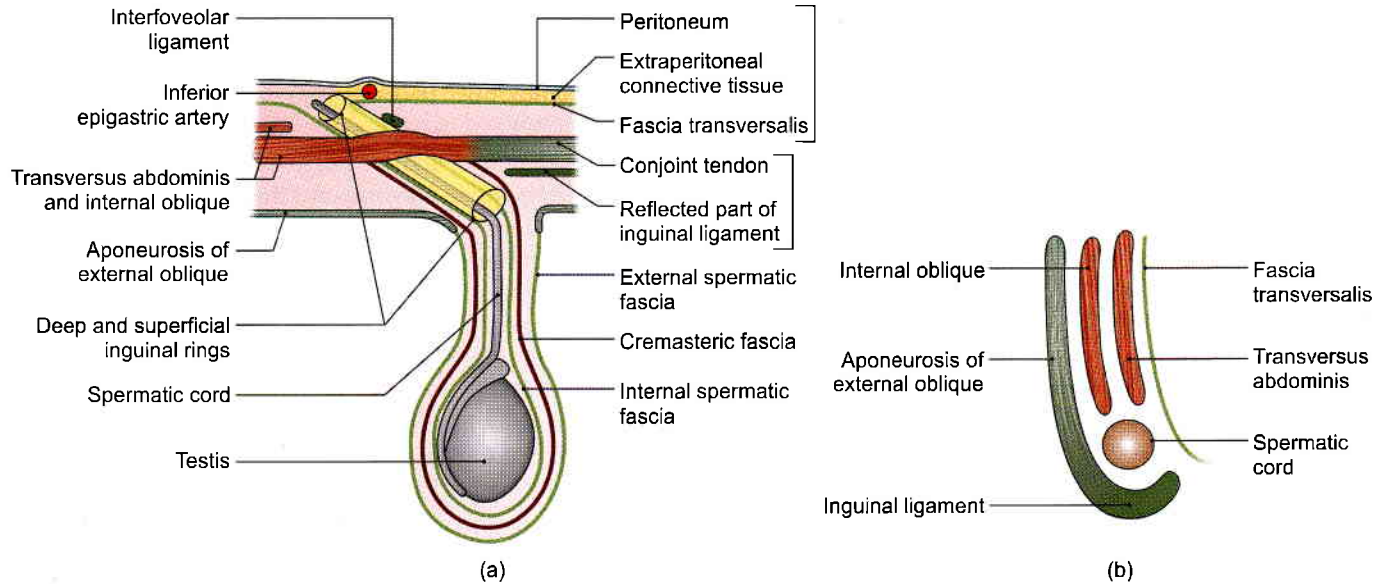
These are as follows.

- The ductus deferens (Fig. 16.27).
- The testicular and cremasteric arteries, and the artery of the ductus deferens.
- The pampiniform plexus of veins.
- Lymph vessels from the testis.
- The ilioinguinal nerve, genital branch of the genitofemoral nerve, and the plexus of sympathetic nerves around the artery to the ductus deferens and visceral afferent nerve fibres.
- Remains of the processus vaginalis.

COVERINGS OF SPERMATIC CORD

From within outwards, these are as follows.

- The *internal spermatic fascia*, derived from the fascia transversalis; it covers the cord in its whole extent (Figs 16.26a and b).
- The *cremasteric fascia* is made up of the muscle loops constituting the cremaster muscle, and the intervening areolar tissue. It is derived from the internal oblique and transversus abdominis muscles,



Figs 16.26a and b: Boundaries of the inguinal canal: (a) Anterior and posterior walls in a horizontal section, and (b) the roof and floor in a sagittal section

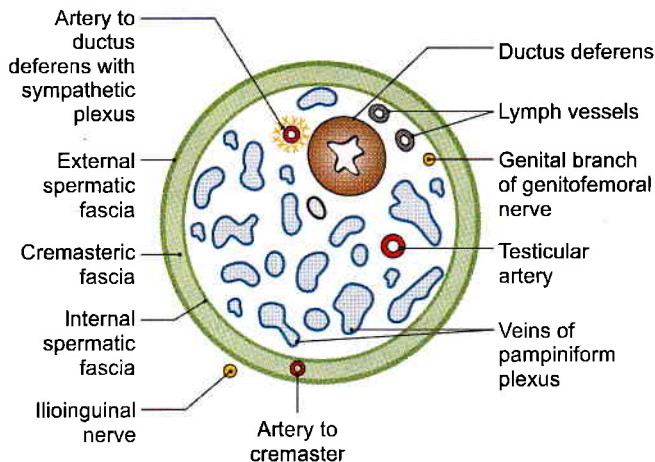


Fig. 16.27: Transverse section through the spermatic cord

and therefore covers the cord below the level of these muscles (Fig. 16.17).

- 3 The *external spermatic fascia* is derived from the external oblique aponeurosis. It covers the cord below the superficial inguinal ring.

Mechanism of Inguinal Canal

The presence of the inguinal canal is a cause of weakness in the lower part of the anterior abdominal wall. This weakness is compensated by the following factors.

- 1 *Obliquity of the inguinal canal:* The two inguinal rings do not lie opposite each other. Therefore, when the intra-abdominal pressure rises the anterior and posterior walls of the canal are approximated, thus obliterating the passage. This is known as the flap valve mechanism.

- 2 The *superficial inguinal ring* is guarded from behind by the conjoint tendon and by the reflected part of the inguinal ligament.
- 3 The *deep inguinal ring* is guarded from the front by the fleshy fibres of the internal oblique.
- 4 *Shutter mechanism of the internal oblique:* This muscle has a *triple relation* to the inguinal canal. It forms the anterior wall, the roof, and the posterior wall of the canal. When it contracts the roof is approximated to the floor, like a shutter. The arching fibres of the transversus also take part in the shutter mechanism (Fig. 16.22a).
- 5 Contraction of the cremaster helps the spermatic cord to plug the superficial inguinal ring (*ball valve mechanism*).
- 6 Contraction of the external oblique results in approximation of the two crura of the superficial inguinal ring (*slit valve mechanism*). The integrity of the superficial inguinal ring is greatly increased by the intercrural fibres.
- 7 *Hormones* may play a role in maintaining the tone of the inguinal musculature.

Whenever, there is a rise in intra-abdominal pressure as in coughing, sneezing, lifting heavy weights all these mechanisms come into play, so that the inguinal canal is obliterated, its openings are closed, and herniation of abdominal viscera is prevented.

DEVELOPMENT OF INGUINAL CANAL

Inguinal canal represents the passage of *gubernaculum* through the abdominal wall. It extends from the caudal end of the developing gonad (in lumbar region) to the *labioscrotal swelling*. In early life, the canal is very short.



As the pelvis increases in width, the deep inguinal ring is shifted laterally and the adult dimensions of the canal are attained.

CLINICAL ANATOMY

Hernia is a protrusion of any of the abdominal contents through any of its walls. This is called *external hernia*. At times the intestine or omentum protrudes into the "no entry" zone within the abdominal cavity itself. The condition is called as internal hernia.

Hernia consists of a sac, contents and coverings. Sac is the protrusion of the peritoneum. It comprises a neck, the narrowed part; and a body, the bigger part (Fig. 16.28).

Contents are mostly the long mobile, keen to move out, coils of small intestine or omentum or any other viscera.

Coverings are the layers of abdominal wall which are covering the hernial sac.

Complications

Irreducibility: In the beginning, the loop of intestine herniates out but comes back to the abdomen. At times, the loop goes out but does not return, leading to irreducible hernia.

Obstruction: The loop may get narrowed in part, so that contents of the loop cannot move forwards, leading to obstruction.

Strangulation: When the arterial supply is blocked, the loop gets necrosed.

Types of abdominal hernia

Internal hernia

- Protrusion of loop of intestine within a "no entry" zone of peritoneum.
- Internal hernia mostly occurs in epiploic foramen or opening into the lesser sac or foramen of Winslow. The loop mostly gets strangulated. It may also occur in the "paraduodenal fossae". These are discussed in Chapter 18.

External hernia

- Umbilical
- Paraumbilical
- Femoral
- Inguinal
- Epigastric
- Divarication of recti
- Incisional
- Lumbar

Umbilical hernia: Congenital umbilical hernia: Due to non-return of midgut loop back to the abdominal cavity (Fig. 16.29).

Acquired infantile umbilical hernia: Due to weakness of umbilical scar, a part of the gut may be seen protruding out. It disappears as the infant grows (Fig. 16.30).

Paraumbilical hernia: Loop of intestine protrude through the linea alba around the region of umbilicus (Fig. 16.31).

Femoral hernia: Occurs more in females, due to larger pelvis, smaller blood vessels and larger femoral canal. Its neck lies below and lateral to the pubic tubercle. Surgery is essential for its treatment (Fig. 16.32).

Inguinal hernia: Protrusion of the loop of intestine through the inguinal wall or inguinal canal is called inguinal hernia (Fig. 16.32).

When the protrusion occurs through the deep inguinal ring, inguinal canal, superficial inguinal ring into the scrotum, it is called *indirect or oblique inguinal hernia*.

It occurs in male infants, children and has a narrow neck of the hernial sac.

When the protrusion occurs through the weak posterior wall of the inguinal canal or triangle of Hesselbach the hernia is a *direct inguinal hernia*. It occurs in much older men and has a wider neck of hernial sac.

Differences between indirect and direct hernia are give in Table 16.1.

- a. *Indirect or oblique hernia:* Occurs due to partial or complete patency of the processus vaginalis (an invagination of the peritoneum). It may descend into the scrotum.

The coverings are:

- i. Extraperitoneal tissue
 - ii. Internal spermatic fascia (Fig. 16.33)
 - iii. Cremasteric fascia
 - iv. External spermatic fascia
 - v. Skin
- b. *Direct inguinal hernia:* Occurs through the posterior wall of the inguinal canal. It occurs through Hesselbach's triangle (Fig. 16.34), bounded by inferior epigastric artery, lateral border of rectus abdominis and inguinal ligament. This area is divided into a medial and lateral parts by the passage of obliterated umbilical artery.

Coverings of the lateral direct inguinal hernia:

- i. Extraperitoneal tissue
- ii. Fascia transversalis (Fig. 16.35)
- iii. Cremasteric fascia
- iv. External spermatic fascia
- v. Skin



Coverings of medial direct inguinal hernia:

- i. Extraperitoneal tissue
- ii. Fascia transversalis
- iii. Conjoint tendon
- iv. External spermatic fascia
- v. Skin

Epigastric hernia: It occurs through the upper part of wide linea alba (Fig. 16.36).

Divarication of recti: Occurs in multiparous female with weak anterolateral abdominal muscles. Loop of intestine protrude during coughing, but returns back (Fig. 16.36).

Incisional hernia: Occurs through the anterolateral abdominal wall when some incisions were made for the surgery, involving cutting of the spinal nerves.

Lumbar hernia: Occurs through the lumbar triangle in the posterior part of the abdominal wall. It is bounded by the iliac crest, anterior border of latissimus dorsi and posterior border of external oblique muscle.

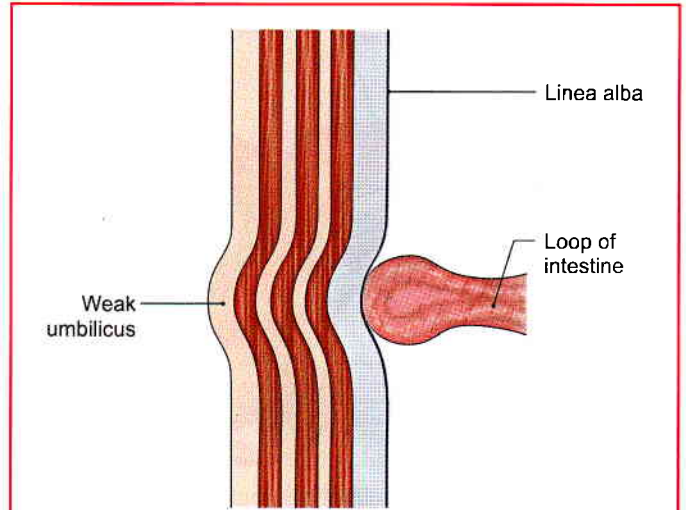


Fig. 16.30: Infantile umbilical hernia

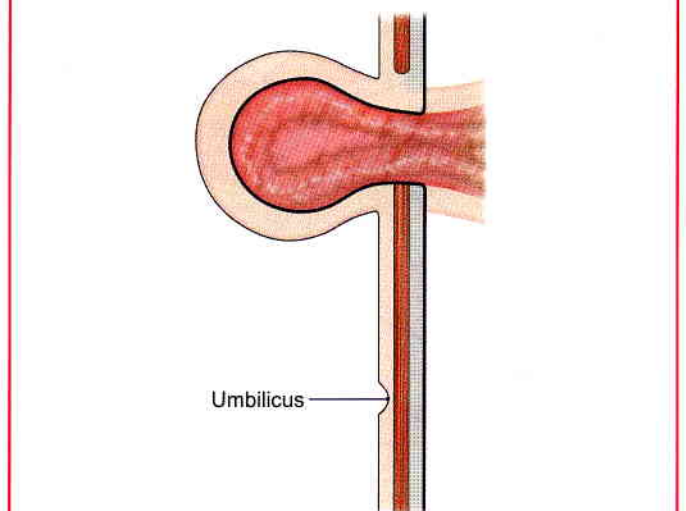


Fig. 16.31: Paraumbilical hernia

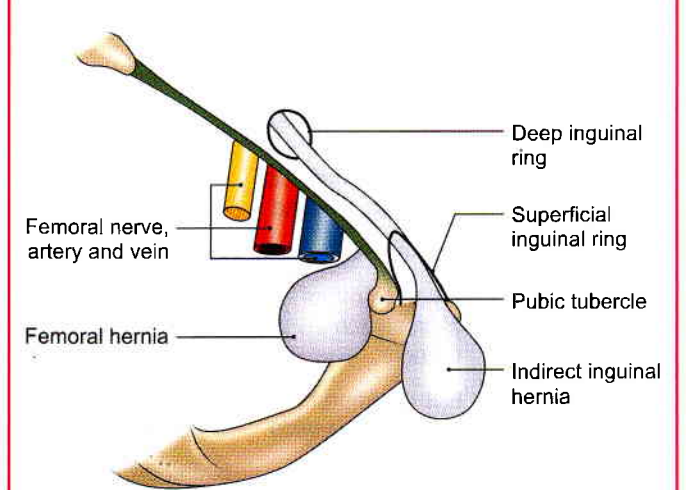


Fig. 16.32: Femoral and inguinal hernia

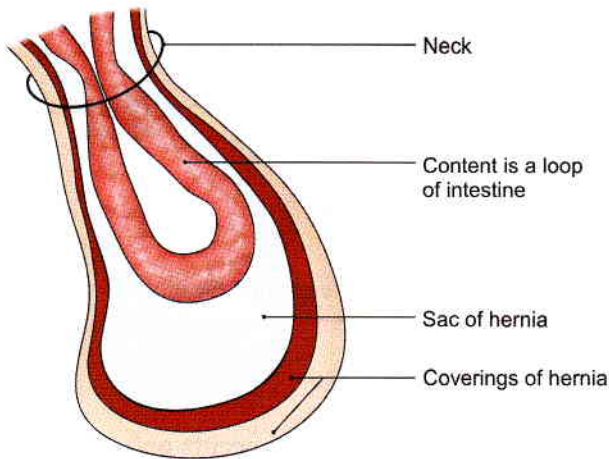


Fig. 16.28: Parts of a hernia

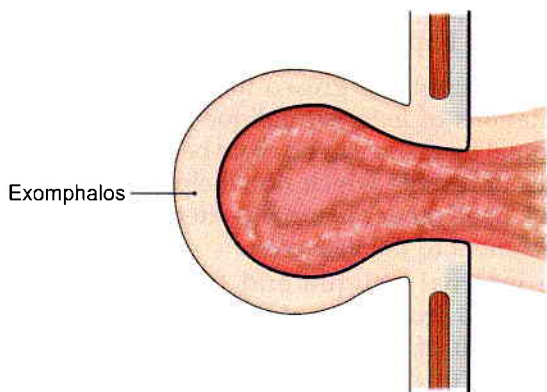


Fig. 16.29: Exomphalos

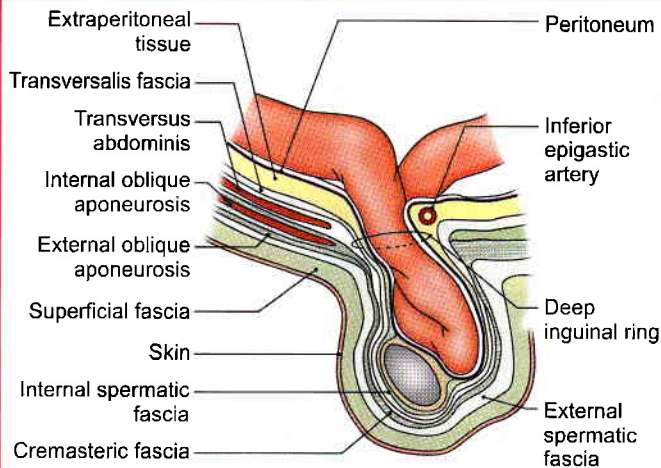


Fig. 16.33: Indirect inguinal hernia

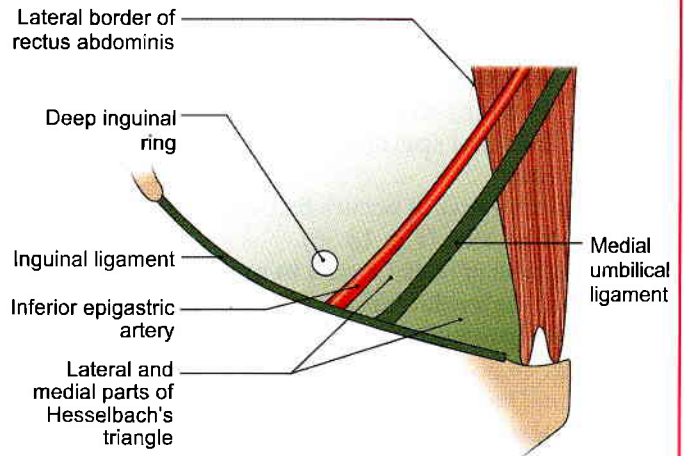


Fig. 16.34: Hesselbach's triangle

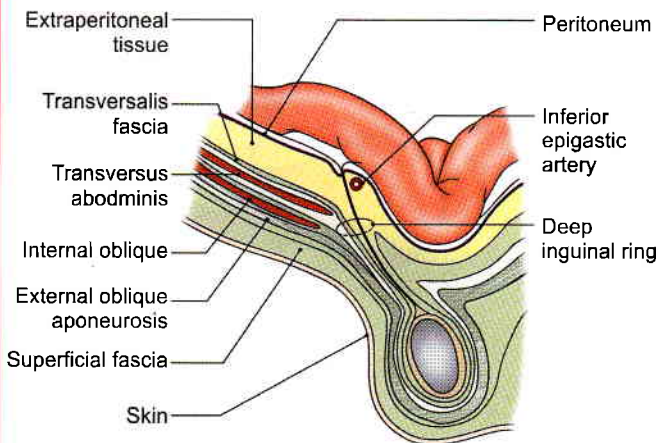


Fig. 16.35: Direct inguinal hernia

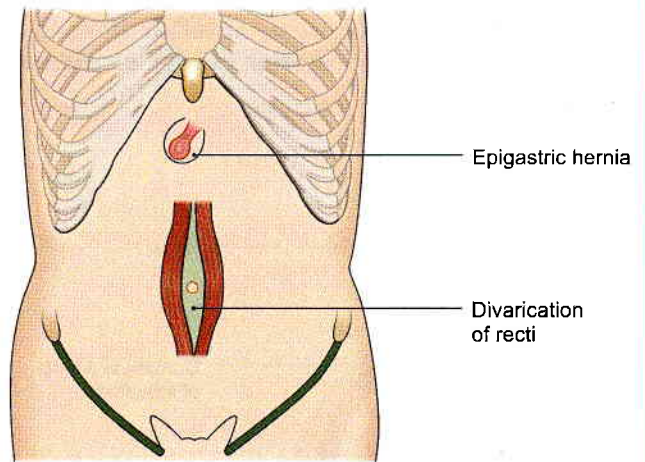


Fig. 16.36: Epigastric hernia and divarication of recti

Table 16.1: Differences between direct and indirect inguinal hernia

	<i>Direct inguinal hernia</i>	<i>Indirect inguinal hernia</i>
1. Aetiology	Weakness of posterior wall of inguinal canal	Preformed sac
2. Precipitating factors	Chronic bronchitis, enlarged prostate	—
3. On standing	Comes out	Does not come out
4. Direction of the sac	It comes out of Hesselbach's triangle	Sac comes through the deep inguinal ring
5. Obstruction	Not common because neck is wide	Common, as neck is narrow
6. Internal ring occlusion test	The swelling is seen	Not seen

Morphologically

The inguinal hernia peculiarly occurs only in man and not in any other mammal. This predisposition of man to hernia is due to the evolutionary changes that have taken place in the inguinal region as a result of his upright posture. He has to pay a heavy price for being upright. The important changes are as follows.

- 1 The iliac crest has grown forwards into the lower digitations of external oblique muscle, so that the inguinal ligament can no more be operated by fleshy fibres of muscle which now helps in balancing the body. In all other mammals, external oblique has no attachment to the iliac crest.
- 2 The internal oblique and transversus initially originated from the anterior border of ilium and the sheath of iliopsoas, and acted as a powerful sphincter of the inguinal canal. The shift of their origin to the inguinal ligament and iliac crest has minimised their role.



- 3 Due to peculiar growth of hip bones and pelvis, the crural passage (between hip bone and inguinal ligament) in man has become much wider than any other mammal. This predisposes to femoral hernia.

Mnemonics

Spermatic cord contents "3-3-3"



3 arteries: Testicular artery, artery to ductus deferens, cremasteric artery

3 nerves: Genital branch of the genitofemoral, ilioinguinal, autonomic nerves

3 other things: Ductus deferens, pampiniform plexus, remains of processus vaginalis



FACTS TO REMEMBER

- Transpyloric plane is an important landmark in the abdominal cavity.
- Umbilicus is normally a region of "water shed" for the lymphatic and venous drainage. It is an important landmark.
- At umbilicus three systems meet. These are digestive (vitellointestinal duct), the excretory (urachus) and vascular (umbilical vessels).
- Thoracic 10 spinal nerve supplies the region of umbilicus.
- External oblique is the largest and most superficial muscle of anterior abdominal wall.
- Internal oblique forms anterior wall, roof and posterior wall of the inguinal canal. It forms rectus sheath differently in upper and lower parts of abdominal wall. It also forms the cremaster muscle and conjoint tendon.

- Rectus abdominis is the largest content of rectus sheath.
- Transversus abdominis interdigitates with the fibres of thoracoabdominal diaphragm.
- Inguinal ligament forms the boundary between abdomen and lower limb.
- Cremasteric reflex indicates that L1 segment of spinal cord is intact
- Inguinal hernia lies above and medial to pubic tubercle. Femoral hernia lies below and lateral to pubic tubercle.
- Femoral hernia is never congenital.
- Femoral hernia is common in females because of the larger pelvis, bigger femoral canal and smaller femoral artery.
- Indirect inguinal hernia is more liable to obstruction as the neck of such a hernia is narrow.
- Paramedian incision in the anterior abdominal wall is mostly preferred.

CLINICOANATOMICAL PROBLEM

In a case of intestinal obstruction an incision is to be made above the umbilicus.

- Which is an ideal site for the incision?
- Should the rectus muscle be retracted medially or laterally?

Ans: The ideal site is a paramedian incision, Though the median incision is relatively bloodless, it tends to leave a postoperative weakness through which a ventral hernia may develop. Paramedian incision through the rectus sheath are more sound than median incisions. Rectus abdominis muscles is retracted laterally to the protect the thoracic nerves. The nerves enter the rectus muscle from lateral side.

MULTIPLE CHOICE QUESTIONS

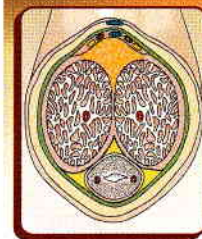
- The skin around the umbilicus is innervated by one of the following segments:
 - T8
 - T9
 - T10
 - T11
- Which of the following does not contribute to the formation of the posterior wall of inguinal canal?
 - Fascia transversalis
 - Conjoint tendon
 - Lacunar ligament
 - Reflected part of inguinal ligament
- Which is the most important landmark for distinguishing inguinal from femoral hernia?
 - Superficial inguinal ring
 - Pubic tubercle
 - Midinguinal point
 - Inguinal ligament
- Hernia resulting due to non-return of the umbilical loop of midgut is:
 - Acquired
 - Congenital
 - Infantile
 - None of the above
- Indirect inguinal hernia coming out at the superficial inguinal ring will have the following coverings:
 - Cremasteric fascia
 - Internal spermatic fascia
 - External spermatic fascia
 - All of the above



6. Which is the covering in all varieties of inguinal hernia?
- Fascia transversalis
 - Internal spermatic fascia
 - External spermatic fascia
 - All of the above
7. Which type of hernia is commonest in young adults?
- Lateral direct inguinal
 - Medial direct inguinal
 - Oblique inguinal
 - Umbilical
8. Transpyloric plane passes through all the following structures *except*:
- L1 vertebra
 - Pylorus of stomach
 - Tip of 10th rib
 - Neck of pancreas
9. Which aponeurosis forms the inguinal ligament?
- Aponeurosis of internal oblique
 - Aponeurosis of external oblique
 - Aponeurosis of transversus abdominis
 - All of the above
10. The plane passing through the body of lumbar 3 vertebra is:
- Subcostal
 - Transpyloric
 - Transumbilical
 - Intertubercular

ANSWERS

1. c 2. c 3. b 4. b 5. d 6. d 7. c 8. c 9. b 10. a



Male External Genital Organs

Commit the oldest sins, the newest kind of ways
—Shakespeare

INTRODUCTION

Male genital organs are situated both outside the pelvic cavity and within the pelvic cavity. As lower temperature is required for *spermatogenesis*, the *testes* are placed outside the pelvic cavity in the scrotal sac. Since urethra serves both the functions of urination and ejaculation, there is only one tube enclosed in the urogenital triangle.

DISSECTION

From the superficial inguinal ring, make a longitudinal incision downwards through the skin of the anterolateral aspects of the scrotum till its lower part. Reflect the skin alone if possible otherwise reflect skin, *dartos* and the other layers together till the testis enveloped in its *tunica vaginalis* is visualised.

Lift the testis and spermatic cord from the scrotum. Cut through the spermatic cord at the superficial inguinal ring and remove it together with the testis and put it in a tray of water.

Incise and reflect the coverings if any, e.g. remains of external spermatic fascia, cremaster muscle, cremasteric fascia and internal spermatic fascia. Separate the various structures of spermatic cord. Feel ductus deferens as the important constituent of spermatic cord. Make a transverse section through the testis to visualise its interior.

Identify the *epididymis* capping the superior pole and lateral surface of the testis. The slit-like *sinus of epididymis* formed by tucking-in of the visceral layer of peritoneum between the testis and the epididymis is seen on the anterolateral aspect of the testis.

Cut through and reflect the skin along the *dorsum of the penis* from the symphysis pubis to the end of the *prepuce*.

Find the extension of the membranous layer of the superficial fascia of the abdominal wall on to the penis

(*fundiform ligament*). The *superficial dorsal vein* of the penis lies in the superficial fascia. Trace it proximally to drain into any of the superficial external pudendal veins of thigh.

Deep to this vein is the deep fascia and *suspensory ligament* of the penis. Divide the deep fascia in the same line as the skin incision. Reflect it to see the *deep dorsal vein* with the *dorsal arteries* and *nerves* on each side.

Make a transverse section through the body of the penis, but leave the two parts connected by the skin of urethral surface or ventral surface. Identify two *corpora cavernosa* and single *corpus spongiosum* traversed by the urethra.

ORGANS INCLUDED

- 1 Penis,
- 2 Scrotum,
- 3 Testes,
- 4 Epididymes, and
- 5 Spermatic cords.

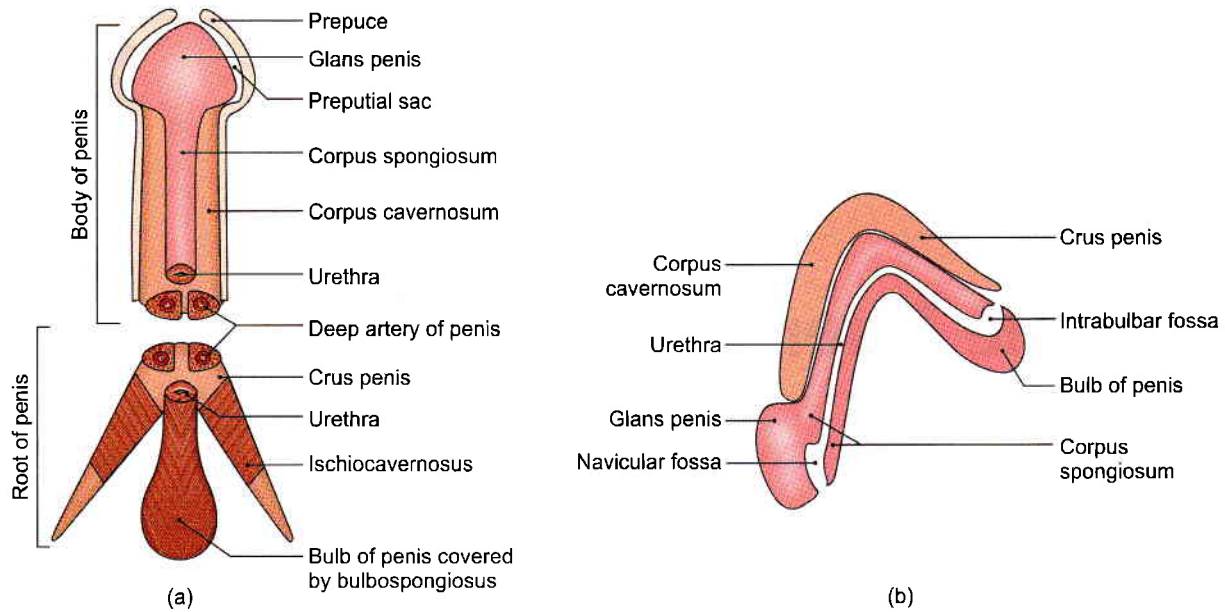
The spermatic cord has been described in Chapter 16.

PENIS

The penis is the male organ of copulation. It is made up of: (a) A root or attached portion, and (b) a body or free portion (Fig. 17.1a).

Root of Penis

The root of the penis is situated in the *superficial perineal pouch*. It is composed of three masses of erectile tissue, namely the two *crura* and one *bulb*. Each *crus* (Latin *leg*) is firmly attached to the margins of the pubic arch, and is covered by the *ischiocavernosus*. The *bulb* is attached to the perineal membrane in between the two *crura*. It is covered by the *bulbospongiosus*. Its deep



Figs 17.1a and b: Parts of the penis: (a) Ventral view, and (b) sagittal section

surface is pierced (above its centre) by the urethra, which traverses its substance to reach the corpus spongiosum (located in the body). This part of the urethra within the bulb shows a dilatation in its floor, called the *intrabulbar fossa* (Fig. 17.1b).

Body of Penis

The free portion of the penis is completely enveloped by skin. It is continuous with the root in front of the lower part of the pubic symphysis. It is composed of three elongated masses of erectile tissue. During erection of the penis these masses become engorged with blood leading to considerable enlargement. These masses are the right and left corpora cavernosa, and a median corpus spongiosum (Fig. 17.2).

The penis has a ventral surface that faces backwards and downwards, and a dorsal surface that faces forwards and upwards.

The two *corpora cavernosa* (Latin *hollow*) are the forward continuations of the crura. They are in close apposition with each other throughout their length. The corpora cavernosa do not reach the end of the penis. Each of them terminates under cover of the *glans penis* in a blunt conical extremity. They are surrounded by a strong fibrous envelope called the *tunica albuginea*. The tunica albuginea has superficial longitudinal fibres enclosing both the corpora, and deep circular fibres that enclose each corpus separately, and also form a median septum.

The *corpus spongiosum* is the forward continuation of the bulb of the penis. Its terminal part is expanded to form a conical enlargement, called the *glans penis*. Throughout its whole length it is traversed by the urethra. Like the corpora, it is also surrounded by a fibrous sheath (Fig. 17.2).

The base of the *glans* (Latin *acron*) *penis* has a projecting margin, the *corona* (Latin *crown*) *glandis*, which overhangs an obliquely grooved constriction, known as the *neck of the penis*. Within the glans the urethra shows a dilatation (in its roof) called the *navicular fossa*.

The *skin* covering the penis is very thin and dark in colour. It is loosely connected with the fascial sheath of the organ. At the neck it is folded to form the *prepuce* (Latin *before penis*) or *foreskin* which covers the glans to a varying extent and can be retracted backwards to expose the glans. On the undersurface of the glans there is a median fold of skin called the *frenulum* (Latin *bridle*).

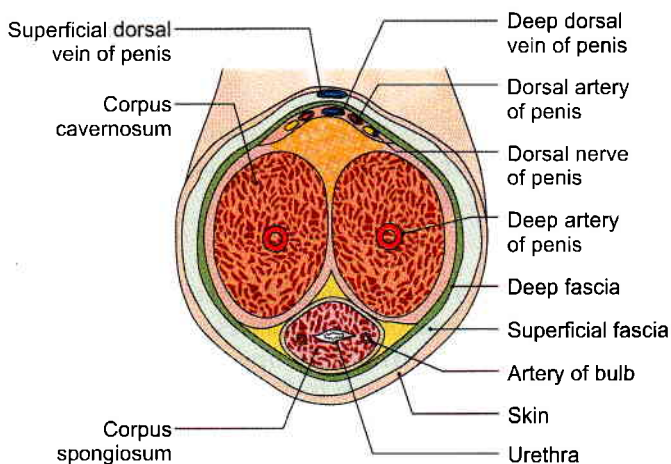


Fig. 17.2: Transverse section through the body of the penis



The potential space between the glans and the prepuce is known as the *preputial sac*. On the corona glandis and on the neck of the penis there are numerous small preputial or sebaceous glands which secrete a sebaceous material called the *smegma*, which collects in the preputial sac (Fig. 17.1a).

The *superficial fascia of the penis* consists of very loosely arranged areolar tissue, completely devoid of fat. It may contain a few muscle fibres. It is continuous with the membranous layer of superficial fascia of the abdomen above and of the perineum below. It contains the superficial dorsal vein of the penis.

The deepest layer of superficial fascia is membranous and is called the *fascia of the penis* or *deep fascia of penis*, or Buck's fascia. It surrounds all three masses of erectile tissue, but does not extend into the glans. Deep to it there are the deep dorsal vein, the dorsal arteries and dorsal nerves of the penis. Proximally, it is continuous with the dartos and with the fascia of the urogenital triangle.

The supports of the body of penis are the following.

- a. The *fundiform ligament* which extends downwards from the linea alba and splits to enclose the penis. It lies superficial to the suspensory ligament (see Fig. 16.8b).
- b. The *suspensory ligament* lies deep to the fundiform ligament. It extends from the pubic symphysis and blends below with the fascia on each side of the penis.

Arteries of the Penis

- 1 The internal pudendal artery gives off three branches which supply the penis.
 - a. The *deep artery of the penis* runs in the corpus cavernosum. It breaks up into arteries that follow a spiral course and are, therefore, called *helicine arteries*.
 - b. The *dorsal artery of the penis* runs on the dorsum, deep to the deep fascia, and supplies the glans penis and the distal part of the corpus spongiosum, the prepuce and the frenulum.
 - c. The *artery of the bulb of the penis* supplies the bulb and the proximal half of the corpus spongiosum.
- 2 The femoral artery gives off the *superficial external pudendal artery* which supplies the skin and fasciae of the penis.

Veins of the Penis

The dorsal veins, superficial and deep, are unpaired. Superficial dorsal vein drains the prepuce and penile skin. It runs back in subcutaneous tissue and inclines to right or left, before it opens into one of the external pudendal veins.

Deep dorsal vein lies deep to Buck's fascia. It receives blood from the glans penis and corpora cavernosa

penis, and courses back in midline between paired dorsal arteries.

Near the root of the penis, it passes deep to the suspensory ligament and through a gap between the arcuate pubic ligament and anterior margin of perineal membrane, it divides into right and left branches which connect below the symphysis pubis with the internal pudendal veins and ultimately enters the prostatic plexus.

Nerve Supply of the Penis

- 1 The sensory nerve supply to the penis is derived from the dorsal nerve of the penis and the ilioinguinal nerve. The muscles of the root of the penis are supplied by the *perineal branch of the pudendal nerve*.
- 2 The autonomic nerves are derived from the pelvic plexus via the *prostatic plexus*. The *sympathetic nerves* are *vasoconstrictor*, and the *parasympathetic nerves* (S2, S3, S4) are *vasodilator*. The autonomic fibres are distributed through the branches of the *pudendal nerve*.

Lymphatic Drainage

Lymphatics from the glans drain into the deep inguinal nodes also called gland of Cloquet. Lymphatics from the rest of the penis drain into the superficial inguinal lymph nodes.

Mechanism of Erection of the Penis

Erection of the penis is a purely vascular phenomenon. The turgidity of the penis during its erection is contributed to by the following factors.

- 1 Dilatation of the *helicine* arteries pours an increased amount of arterial blood into the *cavernous spaces* of the corpora cavernosa. Blood is also poured in small amount into the corpus spongiosum and into the glans by their arteries. As the spaces within the *erectile tissue* fill up, the penis enlarges.
- 2 This enlargement presses on the veins preventing outflow of blood through them. Contraction of the ischiocavernosus muscles probably has the same effect.
- 3 Expansion of the corpora cavernosa, and to a lesser extent of the corpus spongiosum, stretches the deep fascia. This restricts enlargement of the penis. Further flow of blood increases the pressure within the erectile tissue and leads to rigidity of the penis.
- 4 Erection is controlled by parasympathetic nerves (*nervi erigentes*, S2, S3, S4).

SCROTUM

The scrotum (Latin *bag*) is a cutaneous bag containing the right and left testes, the epididymis and the lower parts of the spermatic cords.



- 1 Externally, the scrotum is divided into right and left parts by a ridge or raphe which is continued forwards on to the undersurface of the penis and backwards along the middle of the perineum to the anus (Fig. 17.3).
- 2 The left half of the scrotum hangs a little lower than the right, in correspondence with the greater length of the left spermatic cord.
- 3 Under the influence of cold, and in young and robust persons, the scrotum is short, corrugated and closely applied to the testis. This is due to contraction of the subcutaneous muscle of scrotum, called the *dartos* (Greek *skinny*). However, under the influence of warmth, and in old and debilitated persons, the scrotum is elongated and flaccid due to relaxation of *dartos*. From this it appears that the *dartos* muscle helps in regulation of temperature within the scrotum.

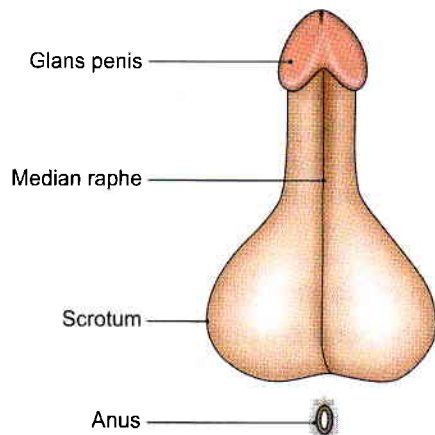


Fig. 17.3: Scrotum and penis viewed from below to show the median raphe

Layers of the Scrotum

The scrotum is made up of the following layers from outside inwards (Fig. 17.4).

- 1 Skin, continuation of abdominal skin.
- 2 Dartos muscle which replaces the superficial fascia. The *dartos* muscle is prolonged into a median vertical septum between the two halves of the scrotum.
- 3 The external spermatic fascia from external oblique muscle.
- 4 The cremasteric (Greek *to hang*) muscle and fascia from internal oblique muscle.
- 5 The internal spermatic fascia from fascia transversalis.

Blood Supply

The scrotum is supplied by the following arteries: Superficial external pudendal, deep external pudendal, scrotal branches of internal pudendal, and cremasteric branch of inferior epigastric.

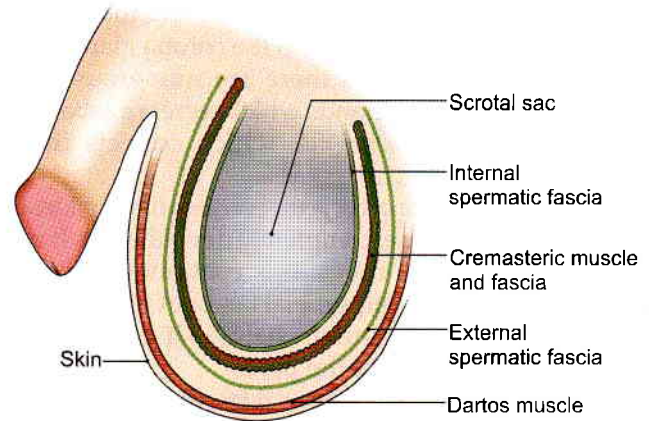


Fig. 17.4: Layers of the scrotum

Nerve Supply

The anterior one-third of the scrotum is supplied by segment L1 of the spinal cord through the *ilioinguinal nerve* and the *genital branch of the genitofemoral nerve* (Fig. 17.5).

The posterior two-thirds of the scrotum are supplied by segment S3 of the spinal cord through the *posterior scrotal branches of the pudendal nerve*, and the *perineal branch of the posterior cutaneous nerve of the thigh*. The areas supplied by segments L1 and S3 are separated by the *ventral axial line*.

The *dartos* muscle is supplied by the *genital branch of the genitofemoral nerve*.

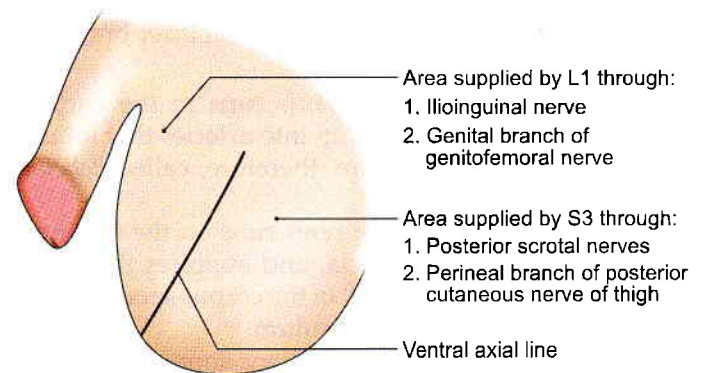


Fig. 17.5: Nerve supply of the scrotum

CLINICAL ANATOMY

- Due to laxity of skin and its dependent position, the scrotum is a *common site for oedema*. Abundance of hair and of sebaceous glands also makes it a *site of sebaceous cysts* (Fig. 17.6).
- As the scrotum is supplied by widely separated dermatomes (L1, S3) spinal anaesthesia of the whole scrotum is difficult to achieve (Fig. 17.5).
- The scrotum is *bifid* in male—*pseudohermaphroditism*.



- *Hydrocoele* is a condition in which fluid accumulates in the processus vaginalis of peritoneum. Types of hydrocoele are shown in Figs 17.7a to d.
- Some common abnormalities of scrotal contents are:
 - a. Tumour of the testis
 - b. Hydrocoele
 - c. Epididymitis
 - d. Varicocele
 - e. Spermatocele
- Tapping a hydrocoele is a procedure for removing the excess fluid from tunica vaginalis. The layers penetrated by the instrument are:
 - a. Skin.
 - b. Dartos muscle and membranous layer of superficial fascia (Fig. 17.4).
 - c. External spermatic fascia.
 - d. Cremasteric muscle and fascia.
 - e. Internal spermatic fascia.
 - f. Parietal layer of tunica vaginalis (Fig. 17.9).

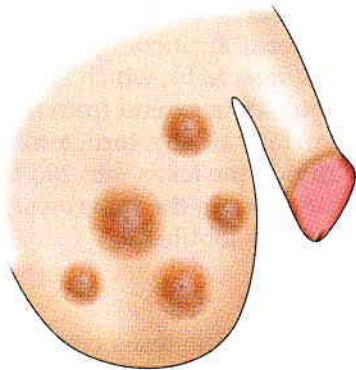


Fig. 17.6: Sebaceous cysts on the scrotum

TESTIS

The testis is the male gonad. It is homologous with the ovary of the female.

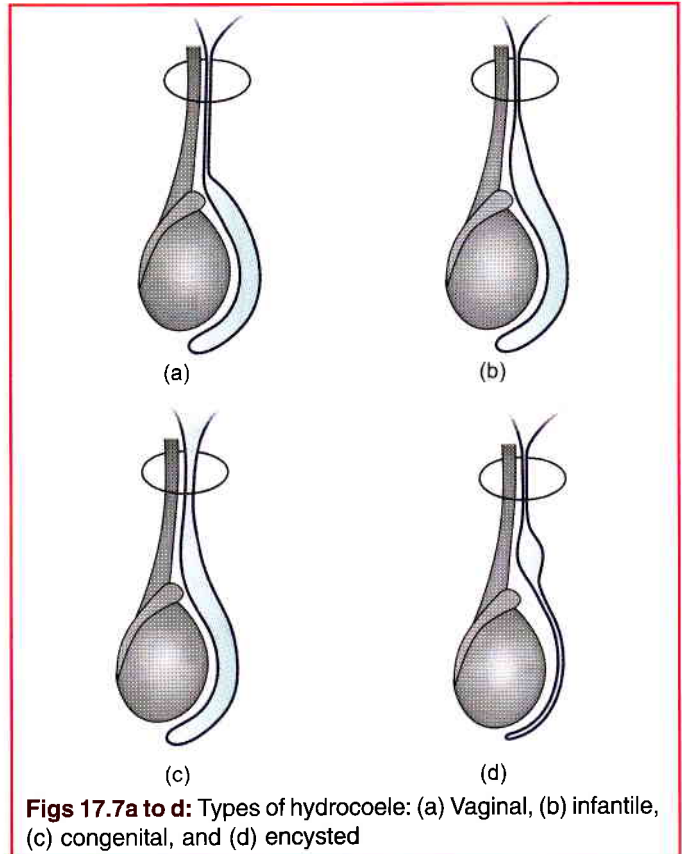
It is suspended in the scrotum by the spermatic cord. It lies obliquely, so that its upper pole is tilted forwards and medially. The left testis is slightly lower shape and size than the right.

The testis is oval in shape, and is compressed from side to side. It is 3.75 cm long, 2.5 cm broad from before backwards, and 1.8 cm thick from side to side. An adult testis weighs about 10 to 15 g.

External Features

The testis has:

- 1 Two poles or ends, upper and lower.
- 2 Two borders, anterior and posterior (Fig. 17.9).
- 3 Two surfaces, medial and lateral (Fig. 17.9).



Figs 17.7a to d: Types of hydrocoele: (a) Vaginal, (b) infantile, (c) congenital, and (d) encysted

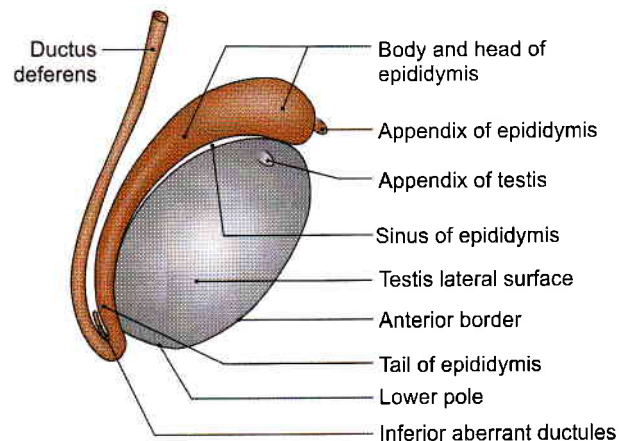


Fig. 17.8: Lateral view of the right testis and surrounding structures with the embryonic remnants present in the region

The *upper* and *lower* poles are convex and smooth. The upper pole provides attachment to the spermatic cord.

The *anterior* border is convex and smooth, and is fully covered by the tunica vaginalis. The *posterior* border is straight, and is only partially covered by the tunica vaginalis. The *epididymis* lies along the lateral part of the posterior border. The lateral part of the epididymis is separated from the testis by an extension of the cavity of the tunica vaginalis. This extension is called the *sinus of epididymis* (Figs 17.9 and 17.10).

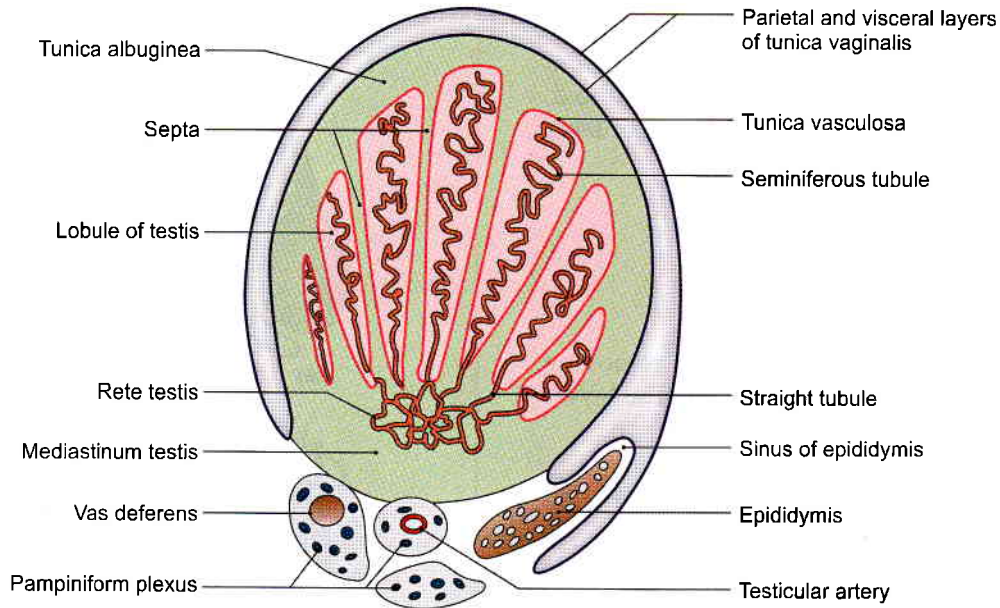


Fig. 17.9: Transverse section of the testis and epididymis

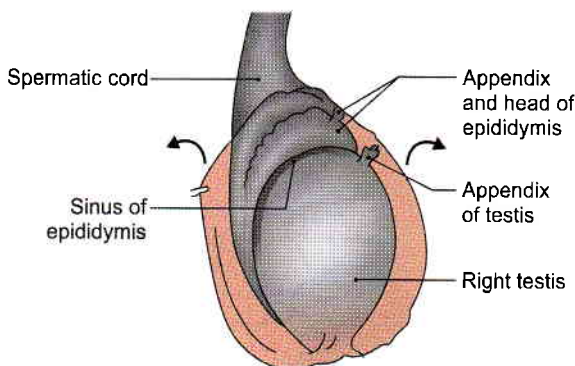


Fig. 17.10: Epididymis and sinus of the epididymis

The *medial* and *lateral surfaces* are convex and smooth.

Attached to the upper pole of the testis, there is a small oval body called the *appendix of the testis*. It is a remnant of the *paramesonephric duct*.

Coverings of the Testis

The testis is covered by layers of the scrotum. In addition it is also covered by three coats. From outside inwards, these are the *tunica (Latin cover) vaginalis*, the *tunica albuginea* and the *tunica vasculosa* (Fig. 17.8).

The *tunica vaginalis (Latin sheath)* represents the lower persistent portion of the *processus vaginalis*. It is invaginated by the testis from behind and, therefore, has a parietal and a visceral layer with a cavity in between. It covers the whole testis, except for its posterior border.

The *tunica albuginea (Latin white)* is a dense, white fibrous coat covering the testis all around. It is covered by the visceral layer of the *tunica vaginalis*, except

posteriorly where the testicular vessels and nerves enter the gland. The posterior border of the *tunica albuginea* is thickened to form an incomplete vertical septum, called the *mediastinum testis*, which is wider above than below. Numerous septa extend from the mediastinum to the inner surface of the *tunica albuginea*. They incompletely divide the testis into 200 to 300 lobules.

The *tunica vasculosa* is the innermost, vascular coat of the testis lining its lobules.

Structure of the Testis

The glandular part of the testis consists of 200 to 300 lobules. Each lobule contains two to three seminiferous tubules. Each tubule is highly coiled on itself. When stretched out, each tubule measures about 60 cm in length, and is about 0.2 mm in diameter. The tubules are lined by cells which represent stages in the formation of spermatozoa.

The *seminiferous tubules* join together at the apices of the lobules to form 20 to 30 *straight tubules* which enter the mediastinum (Fig. 17.9). Here they anastomose with each other to form a network of tubules, called the *rete testis*. In its turn, the *rete testis* gives rise to 12 to 30 *efferent ductules* which emerge near the upper pole of the testis and enter the epididymis. Here each tubule becomes highly coiled and forms a lobe of the head of the epididymis. The tubules end in a single duct which is coiled on itself to form the body and tail of the epididymis. It is continuous with the ductus deferens.

Arterial Supply

The *testicular artery* is a branch of the abdominal aorta given off at the level of vertebra L2. It descends on the



posterior abdominal wall to reach the deep inguinal ring where it enters the spermatic cord. At the posterior border of the testis, it divides into branches. Some small branches enter the posterior border, while larger branches; medial and lateral, pierce the tunica albuginea and run on the surface of the testis to ramify in the tunica vasculosa (Fig. 17.9).

Venous Drainage

The veins emerging from the testis form the *pampiniform plexus* (pampiniform = like a vine). The anterior part of the plexus is arranged around the testicular artery, the middle part around the ductus deferens and its artery, and the posterior part is isolated. The plexus condenses into four veins at the superficial inguinal ring, and into two veins at the deep inguinal ring. These veins accompany the testicular artery. Ultimately one vein is formed which drains into the *inferior vena cava* on the right side, and into the *left renal vein* on the left side (Fig. 17.11).

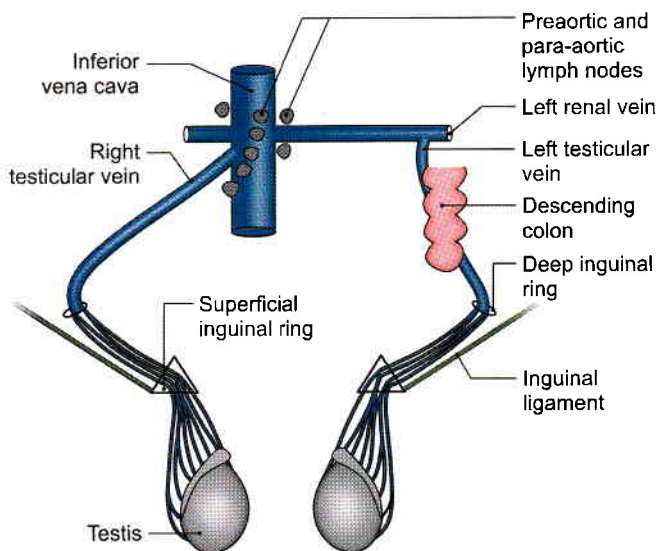


Fig. 17.11: Venous drainage of testis, lymph nodes of testis

Lymphatic Drainage

The lymphatics from the testis ascend along the testicular vessels and drain into the *preaortic* and *para-aortic* groups of lymph nodes at the level of second lumbar vertebra (Fig. 17.11).

Nerve Supply

The testis is supplied by sympathetic nerves arising from segment T10 of the spinal cord. They pass through the renal and aortic plexuses. The nerves are both afferent for testicular sensation and efferent to the blood vessels (vasomotor).

Histology of Seminiferous Tubule

The seminiferous tubule consists of cells arranged in 4–8 layers in fully functioning testis. These cells are of two types, namely:

- The spermatogenic cells forming the vast majority.
- The supporting/sustentacular or cells of Sertoli.

The spermatogenic cells include spermatogonia, primary spermatocytes, secondary spermatocytes, spermatids and spermatozoa. The cells of Sertoli are tall and columnar in shape extending from the basal lamina to the central lumen. They support and protect the developing germ cells and help in maturation of spermatozoa. Spermatogenesis is controlled by follicle stimulating hormone (FSH) of the anterior pituitary gland.

Interstitial cells or cells of Leydig are found as small clusters in between the seminiferous tubules. They secrete testosterone/androgen (I make man). The activity of Leydig cells is controlled by interstitial cell stimulating hormone (ICSH) of the anterior pituitary gland.

CLINICAL ANATOMY

- Unilateral absence of testis—*monorchism* or bilateral absence of testis—*anorchism*.
- Undescended testis* or *cryptorchidism*: The organ may lie in the lumbar, iliac, inguinal, or upper scrotal region (Fig. 17.12). The important features of an undescended testis are as follows.
 - The testis may complete its descent after birth.
 - Spermatogenesis may fail to occur in it.
 - A malignant tumour is more prone to develop in it.
 - The condition can be surgically corrected.
- Ectopic testis*: The testis may occupy an abnormal position due to deviation from the normal route of descent. It may be under the skin of the lower part of the abdomen, under the skin of the front of the thigh, in the femoral canal, under the skin of the penis, and in the perineum behind the scrotum (Fig. 17.13). The important features of an ectopic testis are as follows.
 - The testis is usually fully developed.
 - It is usually accompanied by indirect inguinal hernia.
 - It may be divorced from the epididymis which may lie in the scrotum.
- Hermaphroditism* or intersex is a condition in which an individual shows some features of a male and some of a female. In true hermaphroditism, both testis and ovary are present. In pseudohermaphroditism, the gonad is of one sex while the external or internal genitalia are of the opposite sex.



- The testis and epididymis may be the site of various infections and of tumours.
- Testis may be palpated to check any nodules, or any irregularity or size or consistency.
- *Varicocele* is produced by dilatation of the pampiniform plexus on veins (Fig. 17.14). It is usually left-sided; possibly because the left testicular vein is longer than the right, enters the left renal vein at a right angle and is crossed by the colon which may compress it when loaded.

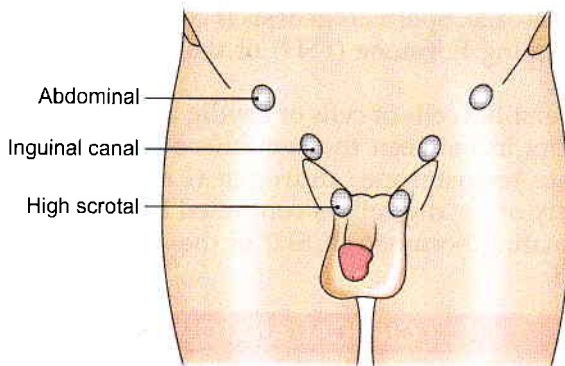


Fig. 17.12: Bilateral undescended testis

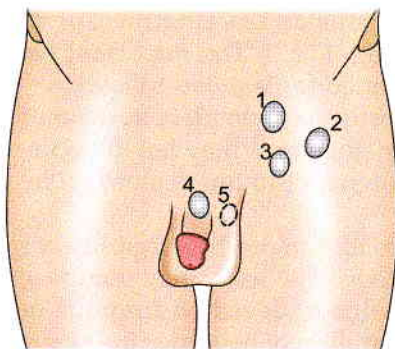


Fig. 17.13: Positions of ectopic testis: 1. Lower part of abdomen, 2. front of thigh, 3. femoral canal, 4. skin of penis, and 5. behind the scrotum

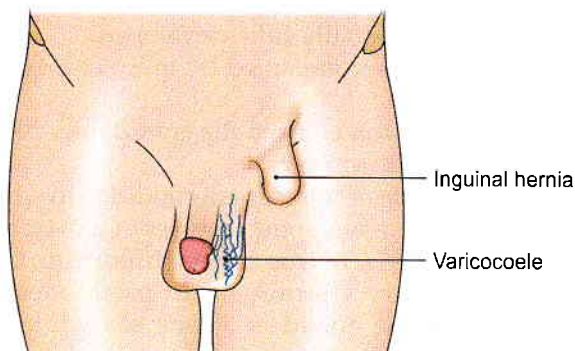


Fig. 17.14: Varicocele with inguinal hernia

EPIDIDYMIS

The epididymis is an organ made up of highly coiled tube that act as reservoir of spermatozoa.

Parts: Its upper end is called the *head*. The head is enlarged and is connected to the upper pole of the testis by *efferent ductules*. The middle part is called the *body*. The lower part is called the *tail*. The head is made up of highly coiled efferent ductules. The body and tail are made up of a single duct, *the duct of the epididymis* which is highly coiled on itself. At the lower end of the tail this duct becomes continuous with the *ductus deferens* (Latin *conducting away*) (Figs 17.9 and 17.10).

Vessels and Nerves

The epididymis is supplied by the testicular artery through a branch which anastomoses with and reinforces the tiny artery to the ductus deferens. The venous and lymphatic drainage are similar to those of the testis. Like the testis the epididymis is supplied by sympathetic nerves through the testicular plexus, the fibres of which are derived from segments T11 to L1 of the spinal cord.

Histology

The tubules of epididymis are lined by pseudostratified columnar epithelium with stereocilia. The tubules are surrounded by connective tissue.

CLINICAL ANATOMY

The common causes of epididymitis and epididymo-orchitis are tuberculosis, filariasis, the gonococcal and other pyogenic infections.

Spermatic Cord

See Fig. 16.27.

DEVELOPMENT

Testis

It is comprised of spermatogenic cells, cells of Sertoli and Leydig's cells.

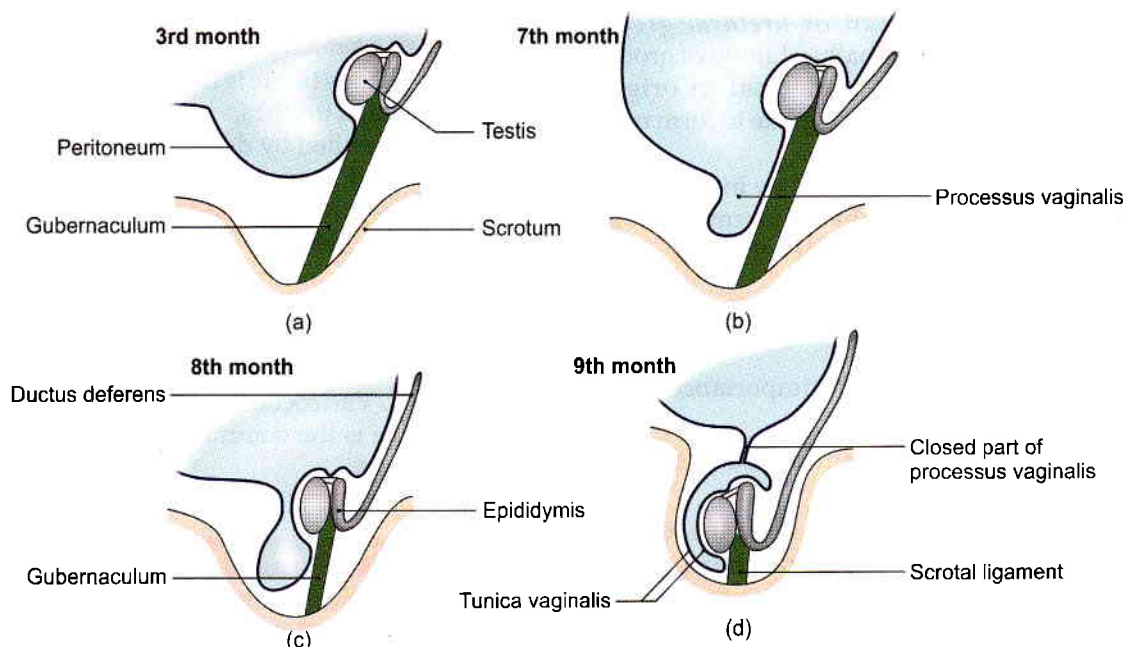
Spermatogenic series of cells are derived from endoderm of dorsocaudal part of yolk sac, i.e. endoderm.

Cells of Sertoli are derived from epithelial cells, i.e. coelomic epithelium.

Leydig's cells: Mesodermal in origin. There is thick tunica albuginea in the testis and the medulla portion of developing gland predominates.

Descent of the Testis

- The testes develop in relation to the developing mesonephros, at the level of segments T10 to T12.



Figs 17.15a to d: Stages of descent of testis include formation of processus vaginalis

- Subsequently, they descend to reach the scrotum (Fig. 17.15). Each testis begins to descend during the second month of intrauterine life.
- It reaches the iliac fossa by the 3rd month,
- Rests at the deep inguinal ring from the 4th to the 6th month,
- Traverses the inguinal canal during the 7th month,
- Reaches the superficial inguinal ring by the 8th month
- And the bottom of the scrotum by the 9th month.
- An extension of peritoneal cavity called the *processus vaginalis* precedes the descent of testis into the scrotum, into which the testis invaginates. The processus vaginalis closes above the testis. Descent does not occur after one year of age.

The *causes of descent* are not well known. The following factors may help in the process.

- Hormones including the male sex hormone produced by the testis, and maternal gonadotropins.
- Differential growth of the body wall.
- Formation of the gubernaculum: This is a band of loose tissue extending from the lower pole of the testis to the scrotum. The gubernaculum helps in the descent of the testis. The remaining part of gubernaculum after the descent of testis is known as ligament of scrotum.
- Intra-abdominal temperature and intra-abdominal pressure may have something to do with descent of the testis.

Ducts

- The predominant duct in males is the medially placed mesonephric or Wolffian duct. Distally, it opens into the primitive urogenital sinus. Its development and differentiation is affected by *Müllerian inhibiting substance, testosterone and dihydrotestosterone*.

Its functional derivatives are:

- Trigone of urinary bladder
 - Epididymis
 - Ductus deferens
 - Seminal vesicles
 - Ejaculatory duct
- Paramesonephric duct forms vestigial component, the appendix of testis.
 - Mesonephric tubules form functional rete testis and vestigial paradidymis and aberrant ductules.

External Genitalia

As early as 3rd week of development, the mesenchymal cells from *primitive streak* migrate around the *cloacal membrane*. These form raised *cloacal folds*. Cranially the folds fuse to form *genital tubercle*.

During 6th week of development cloacal folds are divided into *urethral folds* anteriorly and *anal folds* posteriorly. Lateral to urethral folds a pair of swellings, the *genital swellings* appear.

Genital swellings form the scrotum. Genital tubercle elongates to form the *phallus*. Urethral folds get pulled



forwards to form lateral wall of *urethral groove* extending on inferior aspect of phallus. Lining of groove forms *urethral plate* and is endodermal in origin. Urethral folds close over the urethral plate to form most of the penile urethra.

Urethra in the glans penis is formed by invagination of *ectodermal cells* into the glans. The ectodermal urethra gets continuous with the endodermal urethra.

Embryological Remnants Present in Relation to the Testis

These are as follows (Fig. 17.8). Their importance is that they may sometimes form cysts:

- 1 The *appendix of the testis* or pedunculated hydatid of Morgagni.
- 2 The *appendix of the epididymis* is a small rounded pedunculated body attached to the head of the epididymis. It represents the cranial end of the mesonephric duct.
- 3 The *superior aberrant ductules* are attached to the testis cranial to the efferent ductules. They represent the upper mesonephric tubules.
- 4 The *inferior aberrant ductules*, one or two, are attached to the tail of the epididymis, and represent the intermediate mesonephric tubules. One of them which is more constant may be as long as 25 cm.
- 5 The *paradidymis* or organ of Giralde consists of free tubules lying in the spermatic cord above the head of the epididymis. They are neither connected to the testis nor to the epididymis, and represent the caudal mesonephric tubules.

FACTS TO REMEMBER

- The cavernous tissue is finer in corpus spongiosum as it contains urethra.
- Penis is supplied by deep, dorsal arteries, artery to the bulb and superficial external pudendal artery.
- Tunica vaginalis is the lower persistent part of processes vaginalis, an extension of peritoneal cavity.
- Right testicular vein drains into inferior vena cava. Left testicular vein drains into left renal vein.
- Lymph node of Cloquet is involved in cancer of the penis. Varicocele is common on left side.
- Hydrocele is the commonest cause of swelling of the scrotum.

CLINICOANATOMICAL PROBLEM

A premature male infant was brought to the hospital. His mother complained of empty right scrotal sac and a swelling in right inguinal region.

- Why is the right side of scrotal sac empty?
- What are the time events of the descent of testis?

Ans: Since the child is premature, the testis has not descended on right side. The mass in the right inguinal region is the testis only. It will descend down on its own within few months.

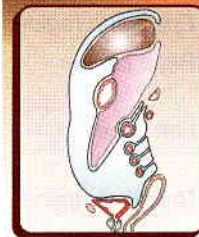Testis begins to descend during 2nd month of intrauterine life →reaches iliac fossa (3rd month) →reaches inguinal canal in 7th month, comes down to superficial inguinal ring during 8th month and reaches scrotum during 9th month.

MULTIPLE CHOICE QUESTIONS

1. Testis is supplied by sympathetic nerves from one of the following segments.
 - a. T10
 - b. T11
 - c. T12
 - d. L1
2. Lymphatics from glans penis drain into:
 - a. External iliac lymph nodes
 - b. Internal iliac lymph nodes
 - c. Superficial inguinal lymph nodes
 - d. Deep inguinal lymph nodes
3. A needle pierces all the structures to drain hydrocele of testis *except*:
 - a. Tunica vaginalis
 - b. Tunica albuginea
 - c. Internal spermatic fascia
 - d. Cremasteric muscle and fascia
4. Artery of ductus deferens is a branch of:
 - a. Abdominal aorta
 - b. Common iliac
 - c. Internal iliac
 - d. Superior vesical
5. Fascia transversalis of abdominal wall forms one of the following coverings of testis.
 - a. Cremasteric muscle and fascia
 - b. External spermatic fascia
 - c. Internal spermatic fascia
 - d. Tunica vaginalis fascia

ANSWERS

1. a 2. d 3. b 4. d 5. c



Abdominal Cavity and Peritoneum

Peritoneum is called as "Abdominal Policeman" as it tries to localize the infection

INTRODUCTION

Abdominal cavity is the largest cavity. It encloses the peritoneal cavity between its parietal and visceral layers. Parietal layer clings to the wall of parieties while visceral layer is intimately adherent to viscera concerned. So their vascular supply and nerve supply are same as the parieties and viscera respectively.

There are very lengthy organs in the peritoneal cavity. These had to be disciplined with limited movements for proper functioning of the gut in particular and the body in general. Infections involving the parietal peritoneum impart protective "board-like rigidity" to the abdominal wall. Referred pain from the viscera to a distant area is due to somatic and sympathetic nerves reaching the same spinal segment.

NINE REGIONS OF ABDOMEN

For the purpose of describing the location of viscera, the abdomen is divided into nine regions by four imaginary planes, two horizontal and two vertical. The horizontal planes are the transpyloric and transtubercular planes. The vertical planes are the right lateral and the left lateral planes (Fig. 18.1).

The *transpyloric plane* of Addison passes midway between the suprasternal notch and the pubic

symphysis. It lies roughly a hand's breadth below the xiphisternal joint. Anteriorly, it passes through the tips of the ninth costal cartilage; and posteriorly through the body of vertebra L1 near its lower border. Organs present on this plane are pylorus of stomach beginning of duodenum, neck of pancreas and hila of the kidneys.

The *transtubercular plane* passes through the tubercles of the iliac crest and the body of vertebra L5 near its upper border.

The *right* and *left lateral planes* correspond to the midclavicular or mammary lines. Each of these vertical planes passes through the midinguinal point and crosses the tip of the ninth costal cartilage.

The nine regions marked out in this way are arranged in three vertical zones, median, right and left. From above downwards, the median regions are *epigastric*, *umbilical* and *hypogastric*. The right and left regions, in the same order, are *hypochondriac*, *lumbar* and *iliac*.

Position of many organs is mentioned in Table 18.1. Liver chiefly occupies the right hypochondrium. Stomach and spleen occupy the left hypochondrium. Duodenum lies in relation to posterior abdominal wall. Coils of jejunum and ileum fill up the umbilical, lumbar and iliac regions.

Large intestine lies at the periphery of abdominal cavity, caecum, ascending colon on right side, descending colon on left side and transverse colon across the cavity (Fig. 18.7).

PERITONEUM

The peritoneum (Greek *stretched over*) is a large serous membrane lining the abdominal cavity. Histologically, it is composed of an outer layer of fibrous tissue, which gives strength to the membrane and an inner layer of mesothelial cells which secrete a serous fluid which lubricates the surface, thus allowing free movements of viscera.

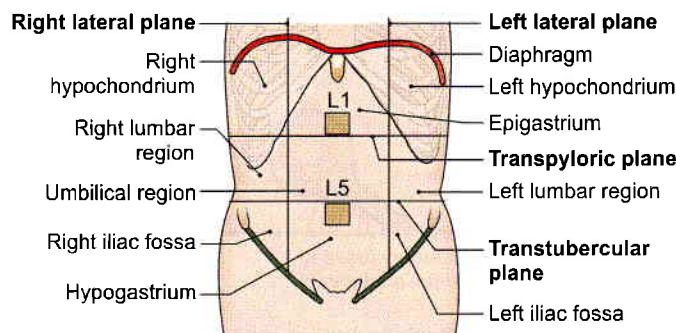


Fig. 18.1: Regions of the abdomen



Table 18.1: Abdominal regions and their main contents

Right hypochondrium	Liver, gallbladder
Left hypochondrium	Spleen, left colic flexure
Epigastric region	Stomach, duodenum, pancreas
Right lumbar	Right kidney and ureter, ascending colon
Left lumbar	Left kidney and ureter, descending colon
Umbilical region	Aorta, inferior vena cava, coils of small intestine
Right iliac fossa	Caecum, vermiform appendix
Left iliac fossa	Sigmoid colon
Hypogastric region	Urinary bladder, coils of small intestine, enlarged uterus

The peritoneum is in the form of a closed sac which is invaginated by a number of viscera. As a result the peritoneum is divided into:

- An outer or parietal layer.
- An inner or visceral layer;
- Folds of peritoneum by which the viscera are suspended.

The peritoneum which is a simple cavity, before being invaginated by viscera becomes highly complicated (Fig. 18.2).

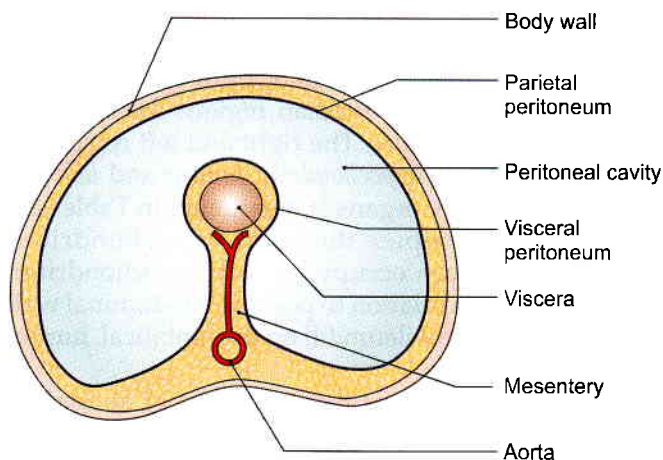


Fig. 18.2: Diagrammatic transverse section of the abdomen showing the arrangement of the peritoneum. The peritoneal cavity is actually a potential space and not so spacious as shown

Parietal Peritoneum

- It lines the inner surface of the abdominal and pelvic walls and the lower surface of the diaphragm. It is loosely attached to the walls by extraperitoneal connective tissue and can, therefore, be easily stripped.

- Embryologically, it is derived from the somatopleuric layer of the lateral plate mesoderm.
- Its blood supply and nerve supply are the same as those of the overlying body wall. Because of the somatic innervation, parietal peritoneum is *pain sensitive*.

Visceral Peritoneum

- It lines the outer surface of the viscera, to which it is firmly adherent and cannot be stripped. In fact it forms a part and parcel of the viscera.
- Embryologically, it is derived from the splanchnopleuric layer of the lateral plate mesoderm.
- Its blood supply and nerve supply are the same as those of the underlying viscera. Because of the autonomic innervation, visceral peritoneum evokes pain when viscera is stretched, ischaemic or distended.

Folds of Peritoneum

- Many organs within the abdomen are suspended by folds of peritoneum. Such organs are mobile. The degree and direction of mobility are governed by the size and direction of the peritoneal fold. Other organs are fixed and immobile. They rest directly on the posterior abdominal wall, and may be covered by peritoneum on one side. Such organs are said to be *retroperitoneal* (Table 18.2). Some organs are

Table 18.2: Relation of peritoneum to various viscera

Relation to peritoneum	Organs
1. Intraperitoneal	Stomach, jejunum, ileum, caecum, appendix
2. Partially covered	Ascending colon, descending colon, rectum
3. Retroperitoneal	Duodenum, pancreas, kidney, ureter, suprarenal
4. Subperitoneal	Urinary bladder, prostate, seminal vesicle, cervix uteri, vagina

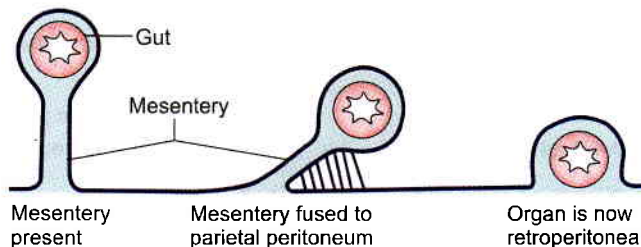


Fig. 18.3: Scheme to show how a loop of gut may lose its mesentery



suspended by peritoneal folds in early embryonic life, but later become retroperitoneal (Fig. 18.3).

- 2 Apart from allowing mobility, the peritoneal folds provide pathways for passage of vessels, nerves and lymphatics.
- 3 Peritoneal folds are given various names:
 - a. In general, the name of the fold is made up of the prefix 'mes' or 'meso' followed by the name of the organ, e.g. the fold suspending the small intestine or *enteron* is called the *mesentery*; and a fold suspending part of the colon is called *mesocolon*.
 - b. Large peritoneal folds attached to the stomach are called *omenta*; singular of which is *omentum* which means cover.
 - c. In many situations, double-layered folds of peritoneum connect organs to the abdominal wall or to each other. Such folds are called *ligaments*. These may be named after the structures they connect. For example, the gastrosplenic ligament connects the stomach to the spleen. Other folds are named according to their shape, e.g. the triangular ligaments of the liver.

Some of the larger peritoneal folds are considered in this chapter, while others are considered along with the organs concerned.

Peritoneal Cavity

The viscera which invaginate the peritoneal cavity completely fill it so that the cavity is reduced to a potential space separating adjacent layers of peritoneum. Between these layers there is a thin film of serous fluid secreted by the mesothelial cells. This fluid performs a lubricating function and allows free movement of one peritoneal surface over another. Under abnormal circumstances there may be collection of fluid called *ascites*, or of blood called *haemoperitoneum*, or of air called *pneumoperitoneum* within the peritoneal cavity.

The peritoneal cavity is divided broadly into two parts. The main, larger part is known as the *greater sac*, and the smaller part, situated behind the stomach, the lesser omentum and the liver, is known as the omental bursa or *lesser sac*. The two sacs communicate with each other through the *epiploic foramen* or *foramen of Winslow* or *opening into the lesser sac*.

Small pockets or recesses of the peritoneal cavity may be separated from the main cavity by small folds of peritoneum. These peritoneal recesses or fossae are of clinical importance. Internal hernia may take place into these recesses.

Sex Differences

In the male, the peritoneum is a closed sac lined by mesothelium or flattened epithelium. The female peritoneum has the following distinguishing features.

- 1 The peritoneal cavity communicates with the exterior through the uterine tubes.
- 2 The peritoneum covering the ovaries is lined by cubical epithelium.
- 3 The peritoneum covering the fimbria is lined by columnar ciliated epithelium.

Functions of Peritoneum

- 1 *Movements of viscera*: The chief function of the peritoneum is to provide a slippery surface for free movements of abdominal viscera. This permits peristaltic movements of the stomach and intestine, abdominal movements during respiration and periodic changes in the capacity of hollow viscera associated with their filling and evacuation. The efficiency of the intestines is greatly increased as a result of the wide range of mobility that is possible because the intestines are suspended by large folds of peritoneum.
- 2 *Protection of viscera*: The peritoneum contains various phagocytic cells which guard against infection. Lymphocytes present in normal peritoneal fluid provide both cellular and humoral immunological defence mechanisms. The greater omentum has the power to move towards sites of infection and to seal them thus preventing spread of infection. For this reason the greater omentum is often designated as the "policeman of the abdomen".
- 3 *Absorption and dialysis*: The mesothelium acts as a semipermeable membrane across which fluids and small molecules of various solutes can pass. Thus, the peritoneum can absorb fluid effusions from the peritoneal cavity. Water and crystalloids are absorbed directly into the blood capillaries, whereas colloids pass into lymphatics with the aid of phagocytes. The greater absorptive power of the upper abdomen or subphrenic area is due to its larger surface area and because respiratory movements aid absorption. Therapeutically, considerable volumes of fluid can be administered through the peritoneal route. Conversely, metabolites, like urea can be removed from the blood by artificially circulating fluid through the peritoneal cavity. This procedure is called *peritoneal dialysis*.
- 4 *Healing power and adhesions*: The mesothelial cells of the peritoneum can transform into fibroblasts which promote healing of wounds. They may also form abnormal adhesions causing obstruction in hollow organs.
- 5 *Storage of fat*: Peritoneal folds are capable of storing large amounts of fat, particularly in obese persons.



CLINICAL ANATOMY

- Collection of free fluid in the peritoneal cavity is known as *ascites*. Common causes of ascites are cirrhosis of the liver, tubercular peritonitis, congestive heart failure, and malignant infiltration of the peritoneum. Veins also get prominent in cirrhosis of liver.
- Fluid from the (peritoneal cavity) may be removed by puncturing the abdominal wall either in the median plane midway between the umbilicus and pubic symphysis, or at a point just above the anterior superior iliac spine. The procedure is called *paracentesis*. Urinary bladder must be emptied before the procedure (Fig. 18.4).
- Inflammation of the peritoneum is called *peritonitis*. It may be localized when a subjacent organ is infected; or may be generalized. The latter is a very serious condition.
- The presence of air in the peritoneal cavity is called *pneumoperitoneum*. It may occur after perforation of the stomach or intestines.
- *Laparoscopy* is the examination of the peritoneal cavity under direct vision using an instrument called *laparoscope*.
- Opening up the abdominal cavity by a surgeon is called *laparotomy*.
- Greater omentum limits the spread of infection by sealing off the site of ruptured vermiform appendix or gastric ulcer and tries to delay the onset of peritonitis. It is called "abdominal policeman".
- Inflammation of parietal peritoneum causes localized severe pain and rebound tenderness on removing the fingers.
- Peritoneal dialysis is done in case of renal failure. The procedure removes the urea, etc. as it diffuses through blood vessels into the peritoneal cavity.

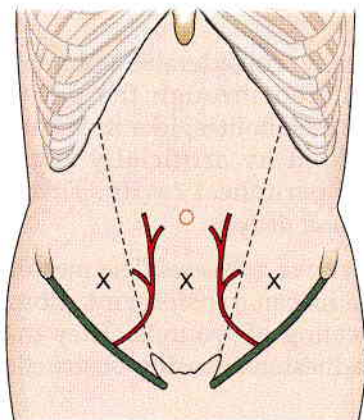


Fig. 18.4: X sites for paracentesis

PERITONEAL FOLDS

DISSECTION

Expose the extensive abdominal cavity by reflecting anterior abdominal wall into four flaps, two (right and left) above and two below the umbilicus.

Identify the *peritoneum*. Divide and reflect it with the anterior abdominal wall. Cut the fold of peritoneum which passes from the median part of the supra-umbilical part of the anterior abdominal wall to the liver known as the *falciform ligament*. This fold contains the *ligamentum teres* of the liver or the *obliterated left umbilical vein* in its free posterior border.

Examine the posterior surface of the reflected lower parts of anterior abdominal wall. Identify five ill-defined *peritoneal folds* which pass upwards (Fig. 18.19) towards the umbilicus. These are *two lateral, two medial and one median umbilical folds*.

Identify the parietal peritoneum, adherent to the parieties or walls of the abdominal cavity. Trace it from the walls to form various double layered folds which spread out to enclose the viscera as the visceral peritoneum.

Identify and lift up the greater omentum. See its continuity with the stomach above and the transverse colon fused with its posterior surface a short distance inferior to the stomach.

Cut through the anterior layers of the greater omentum 2–3 cm inferior to the arteries to open the lower part of the omental bursa sufficiently to admit a hand. Explore the bursa.

Pull the liver superiorly and lift its inferior margin anteriorly to expose the lesser omentum. Examine the right free margin of lesser omentum, containing the bile duct, proper hepatic artery and portal vein. This free margin forms the anterior boundary of the opening into the lesser sac, i.e. epiploic foramen. The posterior boundary is the inferior vena cava. Superior to opening into the lesser sac is the caudate process of liver and inferiorly is the first part of duodenum.

Remove the anterior layer of peritoneum from the lesser omentum along the lesser curvature of the stomach. Find and trace the left gastric vessels along the lesser curvature of stomach. Trace the oesophageal branches to the oesophagus.

Trace the right gastric artery to the proper hepatic artery and the vein to the portal vein. Expose the proper hepatic artery and trace its branches to the porta hepatis.

Trace the cystic duct from the gallbladder. Follow the common hepatic duct to the porta hepatis and the bile duct till it passes posterior to the duodenum.



Features

The folds can be best understood by recapitulating the embryology of the gut. The developing gut is divisible into three parts, foregut, midgut and hindgut. Each part has its own artery which is a ventral branch of the abdominal aorta. The coeliac artery supplies the foregut; the superior mesenteric artery supplies the midgut; and the inferior mesenteric artery supplies the hindgut (Fig. 18.5).

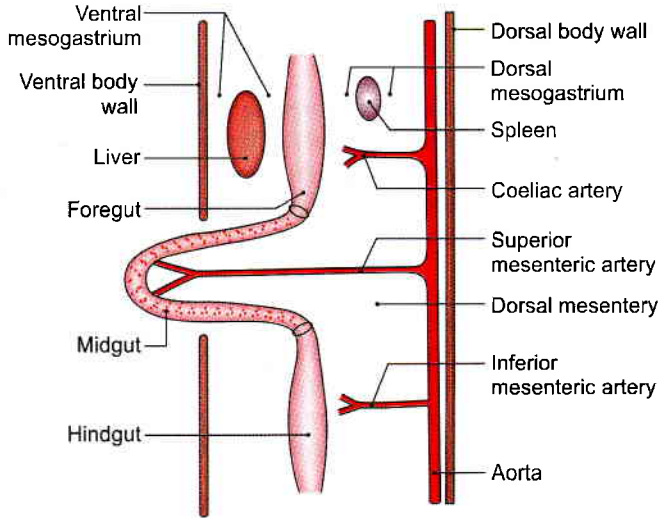


Fig. 18.5: Three parts of the primitive gut with their arteries

Apart from some other structures the *foregut* forms the oesophagus, the stomach, and the upper part of the duodenum up to the opening of the bile duct. The *midgut* forms the rest of the duodenum, the jejunum, the ileum, the appendix, the caecum, the ascending colon, and the right two-thirds of the transverse colon. The *hindgut* forms the left one-third of the transverse colon, the descending colon, the sigmoid colon, proximal part of rectum and the upper part of the anal canal up to the pectinate line.

The abdominal part of the foregut is suspended by mesenteries both ventrally and dorsally. The ventral mesentery of the foregut is called the *ventral mesogastrium*, and the dorsal mesentery is called *dorsal mesogastrium* (*gastrium* means stomach) (Fig. 18.6).

The *ventral mesogastrium* becomes divided by the developing liver into a ventral part and a dorsal part. The ventral part forms the ligaments of the liver, namely:

- a. The falciform (Latin *sickle-shaped*) ligament,
- b. The right and left triangular ligaments, and
- c. The superior and inferior layers of the coronary ligament.

The dorsal part of the ventral mesogastrium forms the lesser omentum.

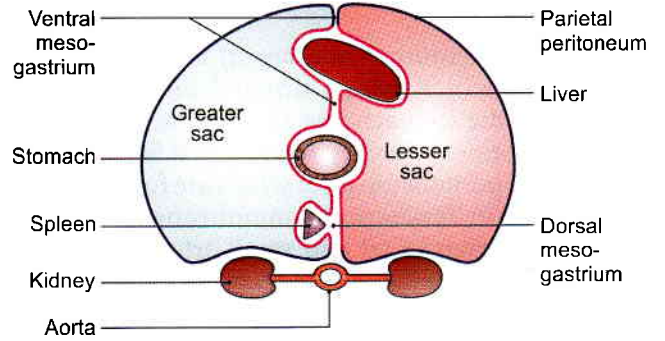


Fig. 18.6: Transverse section through the embryonic foregut showing the ventral and dorsal mesogastria and their divisions

- The fate of the *dorsal mesogastrium* is as follows.
- a. The greater or caudal part of the dorsal mesogastrium becomes greatly elongated and forms the greater omentum.
 - b. The spleen develops in relation to the cranial part of the dorsal mesogastrium, and divides it into dorsal and ventral parts. The ventral part forms the gastrosplenic ligament while the dorsal part forms the lienorenal ligament.
 - c. The cranial most part of the dorsal mesogastrium forms the gastrophrenic ligament.

The *midgut* and *hindgut* have only a dorsal mesentery, which forms the mesentery of jejunum and ileum, the mesoappendix, the transverse mesocolon and the sigmoid mesocolon. The mesenteries of the duodenum, the ascending colon, the descending colon and the rectum are lost during development (Fig. 18.7).

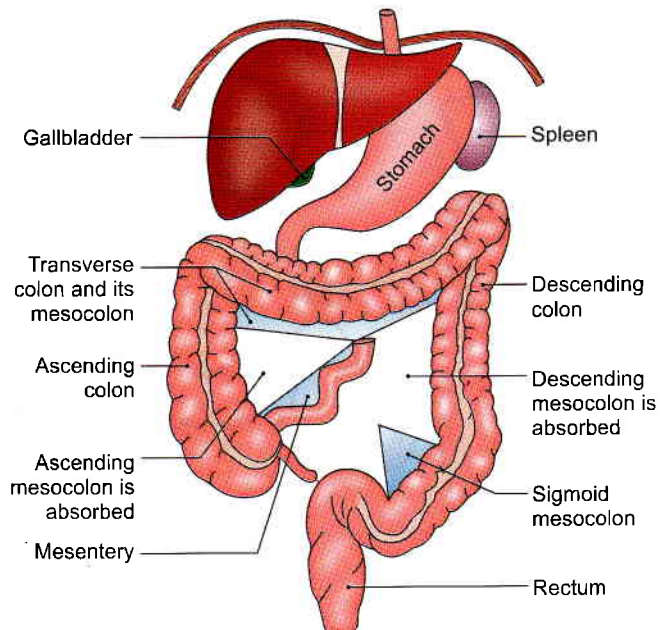


Fig. 18.7: Diaphragm, liver, stomach and spleen in position. Anterior view of the small and large intestines showing the parts of the dorsal mesentery that persist and other parts which are absorbed



Greater Omentum

The greater omentum (Latin *apron*) is a large fold of peritoneum which hangs down from the greater curvature of the stomach like an apron and covers the loops of intestines to a varying extent. It is made up of four layers of peritoneum all of which are fused together to form a thin fenestrated membrane containing variable quantities of fat and small arteries and veins (Figs 18.8 and 18.9).

Attachments

The anterior two layers descend from the greater curvature of the stomach to a variable extent, and fold

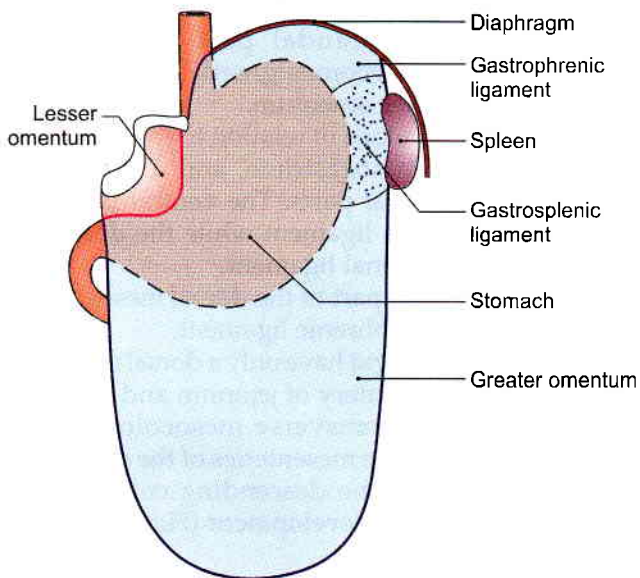


Fig. 18.8: Anterior view of the peritoneal folds attached to the greater and lesser curvatures of the stomach

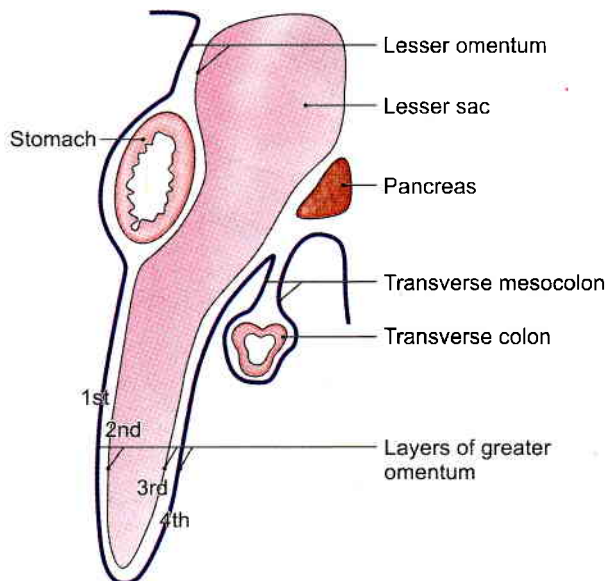


Fig. 18.9: Left view of a sagittal section of the abdomen showing the greater and lesser omenta and the transverse mesocolon

upon themselves to form the posterior two layers which ascend to the anterior surface of the head, and the anterior border of the body of the pancreas. The folding of the omentum is such that the first layer becomes the fourth layer and the second layer becomes the third layer. In its upper part, the fourth layer is partially fused to the anterior surface of the transverse colon and of the transverse mesocolon. The part of the peritoneal cavity called the lesser sac between the second and third layers gets obliterated, except for about 2.5 cm below the greater curvature of the stomach.

Contents

- 1 The right and left gastroepiploic vessels anastomose with each other in the interval between the first two layers of the greater omentum a little below the greater curvature of the stomach.
- 2 It is often laden with fat.

Functions

- 1 It is a storehouse of fat.
- 2 It protects the peritoneal cavity against infection because of the presence of macrophages in it. Collections of macrophages form small, dense patches, known as *milky spots*, which are visible to the naked eye.
- 3 It also limits the spread of infection by moving to the site of infection and sealing it off from the surrounding areas. On this account, the greater omentum is also known as the *policeman of the abdomen*.

The greater omentum forms a partition between the supracolic and infracolic compartments of the greater sac.

LESSER OMENTUM, MESENTERY AND MESOAPPENDIX

DISSECTION

Remove the remains of the lesser omentum leaving the vessels and duct intact and examine the abdominal wall posterior to the omentum and the omental bursa.

Turn the small intestine to the left. Cut through the right layer of peritoneum of the mesentery along the line of its attachment to the posterior abdominal wall and strip it from the mesentery. Remove the fat from the mesentery to expose the superior mesenteric vessels in its root and their branches and tributaries in the mesentery.

Trace the superior mesenteric vessels proximally and distally. Dissect the branches to the jejunum, ileum, caecum, appendix, ascending colon, right two-thirds of transverse colon, the distal part of duodenum and pancreas.



Turn the small intestine and its mesentery to the right. Remove the peritoneum and fat on the posterior abdominal wall between the mesentery and descending colon to expose the inferior mesenteric vessels and the autonomic nerves and lymph nodes associated with them.

Turn the caecum upwards and uncover the structures posterior to it. Trace the three taeniae on the external surface of the colon and cranial to the root of the vermiform appendix.

LESSER OMENTUM

This is a fold of peritoneum which extends from the lesser curvature of the stomach and the first 2 cm of the duodenum to the liver. The portion of the lesser omentum between the stomach and the liver is called the *hepatogastric ligament*, and the portion between the duodenum and the liver is called the *hepatoduodenal ligament*. Behind the lesser omentum there lies a part of the lesser sac. The lesser omentum has a free right margin behind which there is the *epiploic foramen*. The greater and lesser sacs communicate through this foramen.

Attachments

Inferiorly, the lesser omentum is attached to the lesser curvature of the stomach and to the upper border of the first 2 cm of the duodenum. Superiorly, it is attached to the liver, the line of attachment being in the form of an inverted 'L'. The vertical limb of the 'L' is attached to the bottom of the fissure for the ligamentum

venosum, and the horizontal limb to the margins of the porta hepatis (Fig. 18.10).

Contents

The right free margin of the lesser omentum contains:

- 1 The proper hepatic artery;
- 2 The portal vein;
- 3 The bile duct;
- 4 Lymph nodes and lymphatics; and
- 5 The hepatic plexus of nerves, all enclosed in a perivascular fibrous sheath.

Along the lesser curvature of the stomach and along the upper border of the adjoining part of the duodenum it contains:

- 1 The right gastric vessels;
- 2 The left gastric vessels;
- 3 The gastric group of lymph nodes and lymphatics; and
- 4 Branches from the gastric nerves (Fig. 18.10).

Mesentery

The mesentery (Greek *fold of intestine*) of the small intestine or mesentery proper is a broad, fan-shaped fold of peritoneum which suspends the coils of jejunum and ileum from the posterior abdominal wall (Fig. 18.11).

Border

The *attached border*, or *root of the mesentery*, is 15 cm long, and is directed obliquely downwards and to the right. It extends from the duodenojejunal flexure on the left side of vertebra L2 to the upper part of right sacroiliac joint. It crosses the following structures:

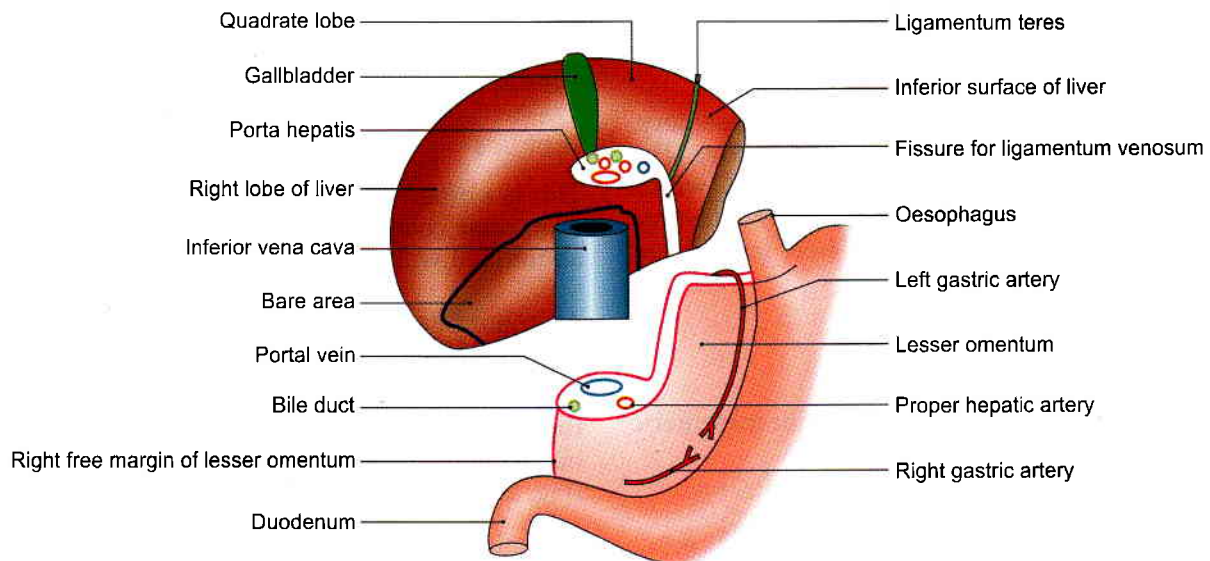


Fig. 18.10: The attachments and contents of the lesser omentum. The liver has been turned upwards so that its posteroinferior surface can be seen



- 1 The third part of the duodenum where the superior mesenteric vessels enter into it;
- 2 The abdominal aorta;
- 3 The inferior vena cava;
- 4 The right ureter; and
- 5 The right psoas major.

The free or *intestinal border* is 6 metres long, and is thrown into pleats (Fig. 18.11). It is attached to the gut, forming its visceral peritoneum or serous coat.

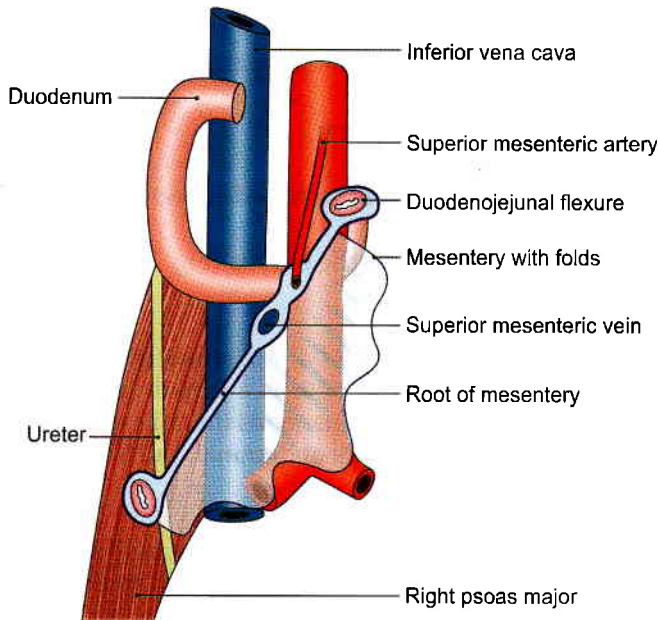


Fig. 18.11: Structures crossed by the root of mesentery

The *breadth* of the mesentery is maximum and is about 20 cm in the central part, but gradually diminishes towards both the ends.

Distribution of Fat

Fat is most abundant in the lower part of the mesentery, extending from the root to the intestinal border. The upper part of the mesentery contains less fat, which tends to accumulate near the root. Near the intestinal border it leaves oval or circular fat free, translucent areas, or *windows*.

Contents

The contents of the mesentery are:

- 1 Jejunal and ileal branches of the superior mesenteric artery;
- 2 Accompanying veins;
- 3 Autonomic nerve plexuses;
- 4 Lymphatics or lacteals;
- 5 100–200 lymph nodes; and
- 6 Connective tissue with fat.

MESOAPPENDIX

It is a small, triangular fold of peritoneum which suspends the vermiform appendix from the posterior surface of the lower end of the mesentery close to the ileocaecal junction. Usually the fold extends up to the tip of the appendix, but sometimes it fails to reach the distal one-third or so. It contains vessels, nerves, lymph nodes and lymphatics of the appendix (Fig. 18.12).

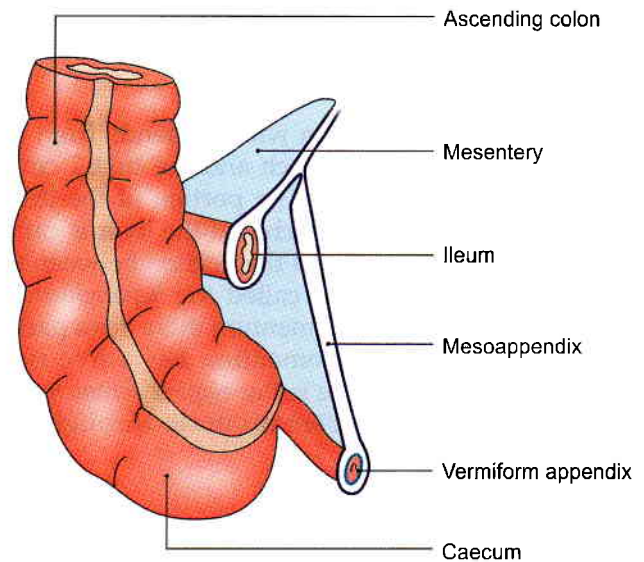


Fig. 18.12: The attachment of the mesoappendix to the posterior (left) surface of the lower end of the mesentery

TRANSVERSE MESOCOLON

DISSECTION

Expose the anterior border of the pancreas and define the attachments of the transverse mesocolon. Trace the duodenum from the pylorus to the duodenojejunal flexure.

Features

This is a broad fold of peritoneum which suspends the transverse colon from the upper part of the posterior abdominal wall (Figs 18.7 and 18.9).

Attachments

The root of the transverse mesocolon is attached to the anterior surface of the head, and the anterior border of the body of the pancreas. The line of attachment is horizontal with an upward inclination towards the left (Fig. 18.13).

Contents

It contains the middle colic vessels; the nerves, lymph nodes and lymphatics of the transverse colon.

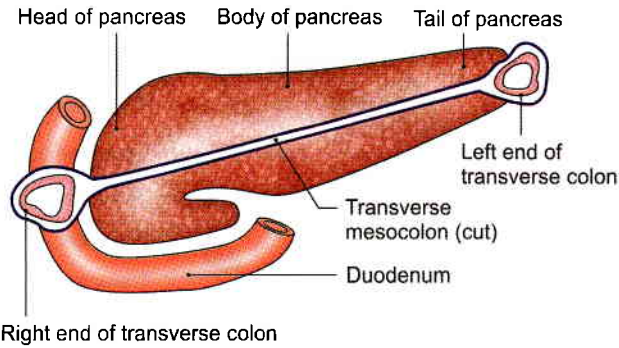


Fig. 18.13: Attachment of the root of the transverse mesocolon

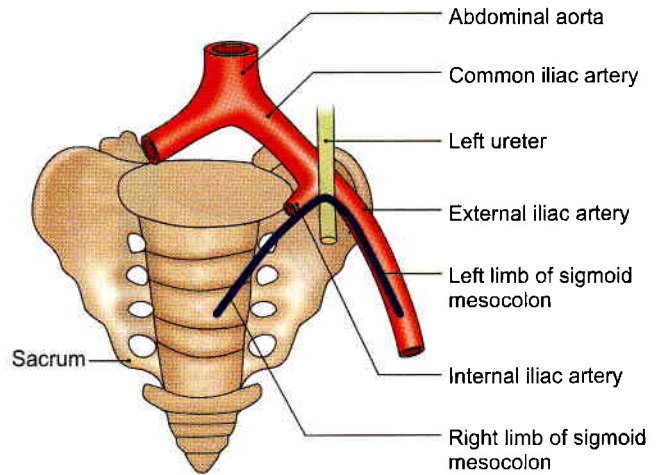


Fig. 18.14: Attachment of the root of the sigmoid mesocolon

SIGMOID MESOCOLON

DISSECTION

Trace the fold of peritoneum from the upper half of left external iliac artery to the termination of left common iliac artery and then downwards till the third piece of sacrum.

Features

This is a triangular (Greek 'S' shape) fold of peritoneum which suspends the sigmoid colon from the pelvic wall (Fig. 18.7).

Attachment

The root is shaped like an inverted 'V'. Its apex lies over the left ureter at the termination of the left common iliac artery. The left limb of 'V' is attached along the upper half of the left external iliac artery; and the right limb to the posterior pelvic wall extending downwards and medially from the apex to the median plane at the level of vertebra S3 (Fig. 18.14).

Contents

The sigmoid vessels in the left limb; superior rectal vessels, nerves, lymph nodes and lymphatics in the right limb of the sigmoid colon.

REFLECTION OF PERITONEUM ON THE LIVER

From Fig. 18.15 it can be seen that on reaching the liver, the peritoneum forming the two layers of the lesser omentum passes on to the surface of the liver. After lining the surfaces of the liver this peritoneum is reflected on to the diaphragm and to the anterior abdominal wall in the form of a number of ligaments. These are the falciform ligament, the left triangular ligament, the coronary ligaments and the right triangular ligament. The falciform ligament is described below. The other ligaments are described later along with the liver.

The *falciform ligament* is a sickle-shaped fold of peritoneum which connects the anterosuperior surface of the liver to the anterior abdominal wall and to the undersurface of the diaphragm. This fold is raised by the ligamentum teres of the liver. The ligamentum teres extends from the umbilicus to the inferior border and inferior surface of the liver. It joins the left branch of

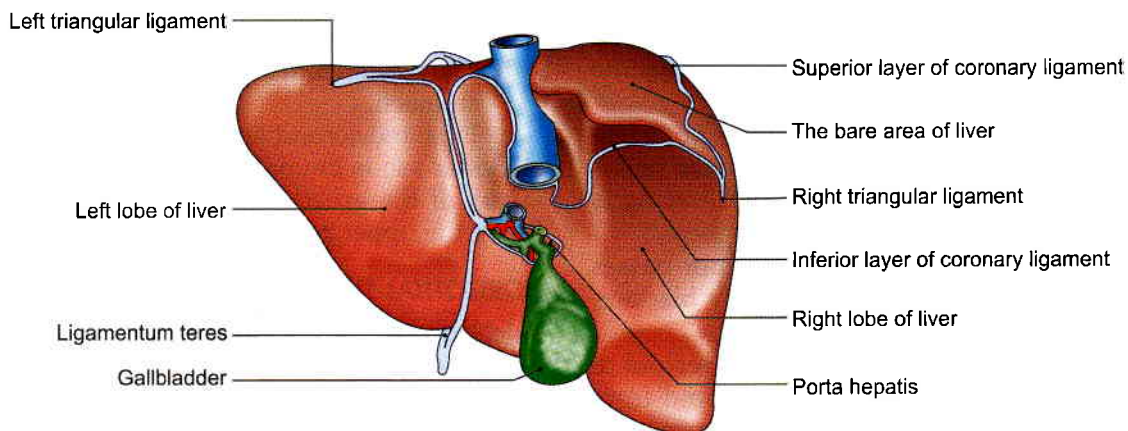


Fig. 18.15: Reflections of peritoneum on the liver. Superior and posterior aspect

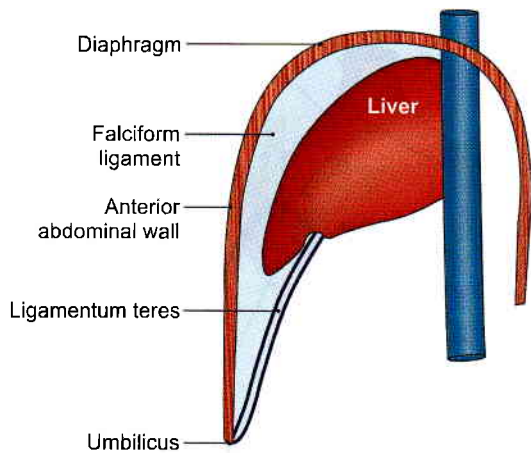


Fig. 18.16: Falciform ligament

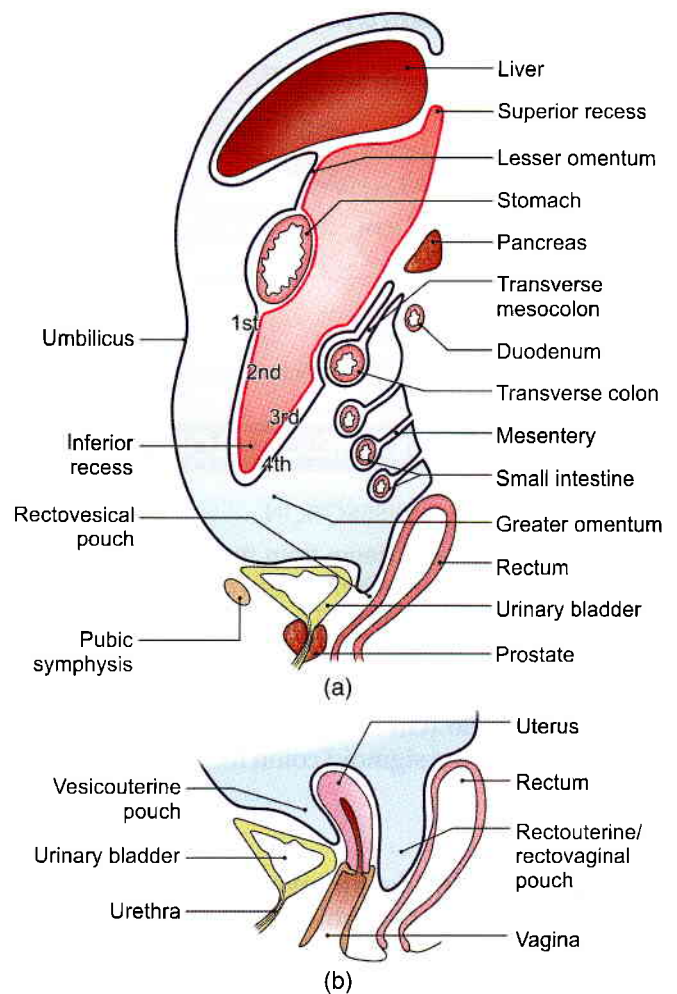
the portal vein (at the left end of the porta hepatis) to the ligamentum venosum (Fig. 18.16).

Peritoneal Cavity

The layout of the greater sac can be studied by tracing the peritoneum both vertically and horizontally.

VERTICAL TRACING OR SAGITTAL TRACING

- 1 Peritoneum lining the anterior abdominal wall and diaphragm, layer 1st.
- 2 Peritoneum lining upper part of posterior abdominal wall and diaphragm, layer 3rd.
- 3 Layers 1st and 2nd enclose most of the liver. The two layers get reflected at porta hepatis to form the lesser omentum.
- 4 Lesser omentum encloses the stomach and two layers pass downwards as greater omentum, where these fold upon themselves. First layer becomes fourth layer and second layer becomes the third layer.
- 5 Third and fourth layers enclose transverse colon to continue as transverse mesocolon.
- 6 Third layer lines the structures in the upper part of posterior abdominal wall.
- 7 The fourth layer passes around the small intestine to form the mesentery of small intestine.
- 8 Peritoneum lines the structures in the posterior abdominal wall and descends into the true pelvis in front of the rectum. The subsequent tracing is different in the male and in the female.
- 9 In the male (Fig. 18.17a), the peritoneum passes from the front of rectum to the urinary bladder, forming rectovesical pouch.
- 10 In the female, it passes from the front of rectum to the uterus forming rectouterine pouch and from the uterus to the urinary bladder forming the vesicouterine pouch (Fig. 18.17b).



Figs 18.17a and b: (a) Sagittal section through the abdomen (male) to show the reflections of peritoneum, and (b) sagittal section through a female pelvis showing the peritoneal reflections

Both in the male and female the peritoneum passes from the urinary bladder to the anterior abdominal wall, thus completing the sagittal tracing of the peritoneum.

In Fig. 18.17a note that the lesser sac is bounded in front by:

- a. The posterior layer of lesser omentum.
- b. The peritoneum lining the posterior surface of the stomach.
- c. First and second layers of greater omentum.

Lesser sac is bounded behind by third and fourth layers of the greater omentum and the peritoneum lining the upper part of the posterior abdominal wall.

HORIZONTAL TRACING ABOVE TRANSVERSE COLON

Falciform ligament from the anterior abdominal wall encloses the liver. At *porta hepatis* it forms lesser omentum which encloses the stomach. The two layers pass to left towards spleen as *gastrosplenic* ligament. At the hilum, the two layers of gastrosplenic ligament



diverge. The anterior layer encloses the spleen, forms one layer of *lienorenal ligament*, covers left kidney and continues to line the structures in the anterior abdominal wall (Fig. 18.18). The posterior layer forms the other layer of lienorenal ligament and lines the structures in the posterior abdominal wall. The two layers get reflected as *falciform ligament* on the liver.

HORIZONTAL TRACING BELOW THE LEVEL OF THE TRANSVERSE COLON

On the back of the anterior abdominal wall we see a number of peritoneal folds, and fossae (Fig. 18.19). Starting from the median plane these are:

1 The median umbilical fold raised by the median umbilical ligament (remnant of the urachus).

- 2 The medial inguinal fossa.
- 3 The medial umbilical fold raised by the obliterated umbilical artery.
- 4 The lateral inguinal fossa.
- 5 The lateral umbilical fold raised by the inferior epigastric vessels.
- 6 The femoral fossa overlying the femoral septum.

Further laterally the peritoneum passes over the lateral part of abdominal wall to reach the posterior abdominal wall. Near the middle, the peritoneum becomes continuous with the two layers of the mesentery and thus reaches the small intestine.

At this level we also see the greater omentum made up of four layers. It lies between the intestines and the anterior abdominal wall.

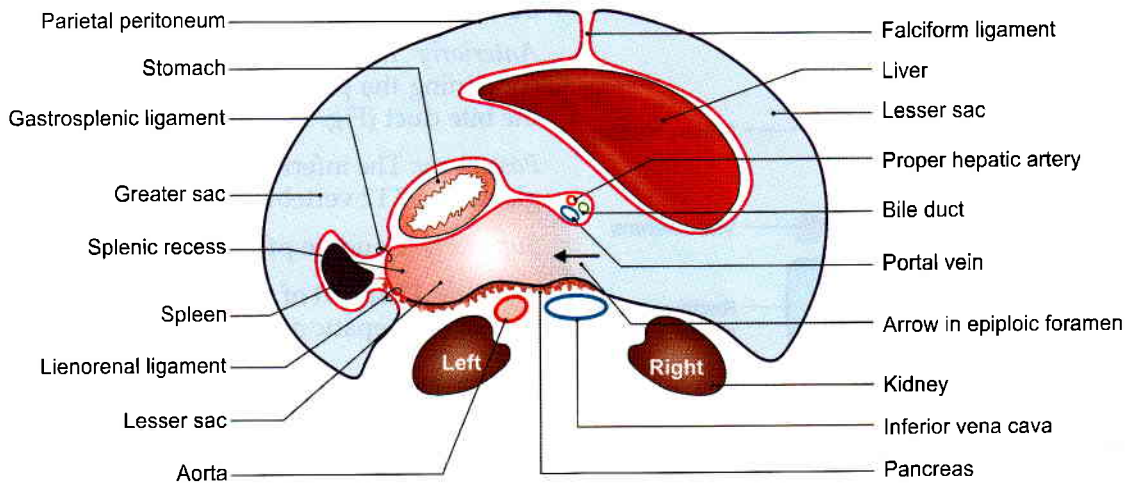


Fig. 18.18: Horizontal section through the supracoelic compartment of the abdomen showing the horizontal disposition of the peritoneum

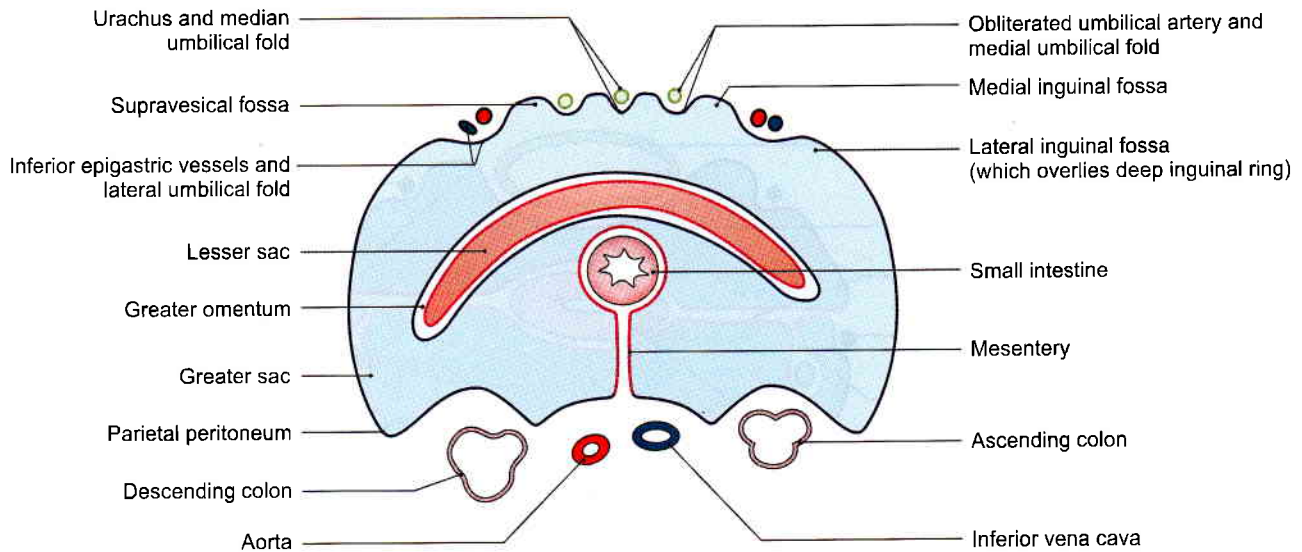


Fig. 18.19: Horizontal section through infracolic compartment of the abdomen showing the horizontal disposition of the peritoneum



HORIZONTAL TRACING OF PERITONEUM IN THE LESSER PELVIS (MALE)

In Fig. 18.20 note the following.

- 1 The rectovesical pouch;
- 2 The pararectal fossae;
- 3 The sacrogenital folds forming the lateral limit of the rectovesical pouch;
- 4 The pararectal fossae;
- 5 The paravesical fossae. The sigmoid colon and mesocolon are present, but are not shown in the diagram.

HORIZONTAL TRACING OF PERITONEUM IN THE LESSER PELVIS (FEMALE)

In Fig. 18.21 note the following.

- 1 The uterus and the broad ligaments form a transverse partition across the pelvis.
- 2 The pararectal and paravesical fossae.

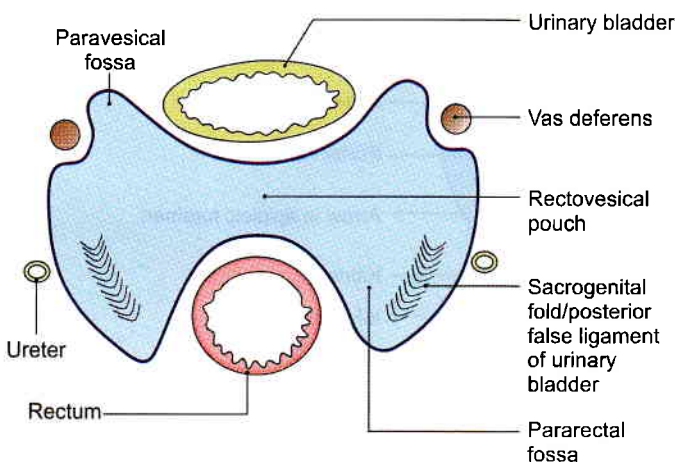


Fig. 18.20: Horizontal section through the male pelvis showing the horizontal disposition of the peritoneum

- 3 The rectouterine pouch.
- 4 The mesovarium by which the ovary is suspended from the posterior (superior) layer of the broad ligament.

EPIPLOIC FORAMEN/OMENTAL FORAMEN/FORAMEN OF WINSLOW

Synonyms: Foramen of Winslow, aditus or opening to the lesser sac. This is a vertical slit-like opening through which the lesser sac communicates with the greater sac.

The foramen is situated behind the right free margin of the lesser omentum at the level of the 12th thoracic vertebra.

BOUNDARIES

Anteriorly: Right free margin of the lesser omentum containing the portal vein, proper hepatic artery, and the bile duct (Fig. 18.22).

Posteriorly: The inferior vena cava, the right suprarenal gland and T12 vertebra.

Superiorly: Caudate process of the liver.

Inferiorly: First part of the duodenum and the horizontal part of the hepatic artery (Fig. 18.23).

LESSER SAC OR OMENTAL BURSA

This is a large recess of the peritoneal cavity behind the stomach, the lesser omentum and the caudate lobe of the liver. It is closed all around, except in the upper part of its right border where it communicates with the greater sac through the epiploic foramen (Figs 18.19 and 18.24).

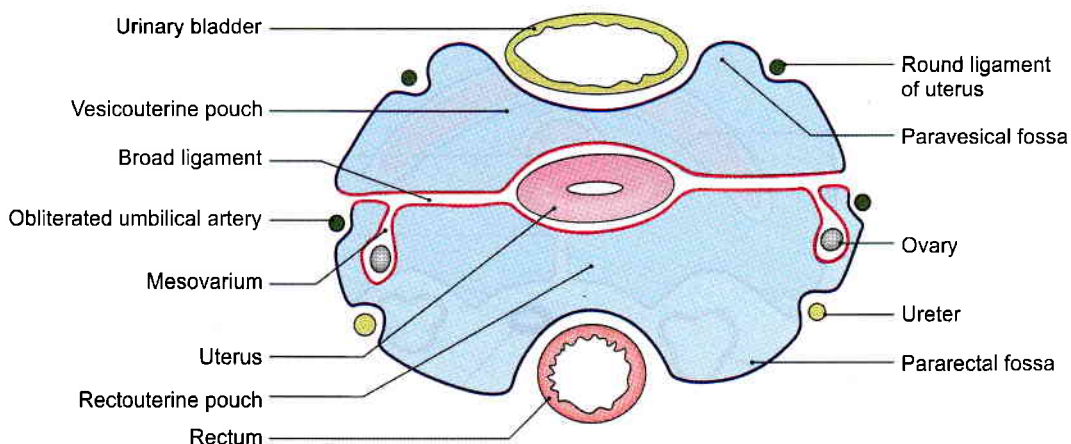


Fig. 18.21: Horizontal section through the female pelvis showing the horizontal disposition of the peritoneum

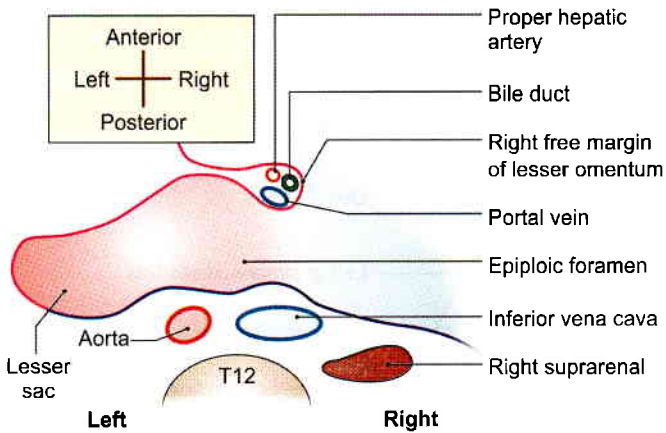


Fig. 18.22: Epiploic foramen as seen in a transverse section at the level of the twelfth thoracic vertebra

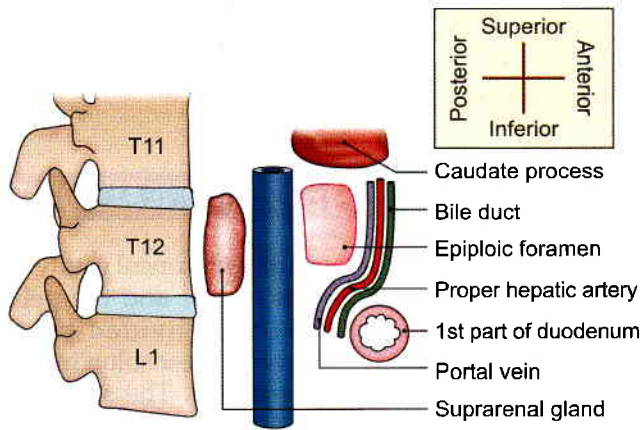


Fig. 18.23: Boundaries of epiploic foramen

BOUNDARIES OF LESSER SAC

Anterior

- 1 Peritoneum covering caudate lobe and caudate process of liver.
- 2 Posterior layer of lesser omentum
- 3 Peritoneum covering posterior surface of stomach
- 4 Second layer of greater omentum.

Posterior

- 1 Third layer of greater omentum.
- 2 Peritoneum covering anterosuperior surface of transverse colon.
- 3 Upper layer of transverse mesocolon.
- 4 Peritoneum covering the anterior surface of body of pancreas, left suprarenal, left kidney, splenic vessels and diaphragm.

Upper Reflection of peritoneum from diaphragm to liver.

Lower Right margin of greater omentum. Reflection of peritoneum from neck of pancreas to 1st part of duodenum.

Right Epiploic foramen
Peritoneal reflection from diaphragm to caudate lobe.

Left Left margin of greater omentum. Inner layers of gastrosplenic and lineorenal ligaments.

SUBDIVISION OF THE LESSER SAC

- 1 The downward and forward course of the common hepatic artery raises a sickle-shaped fold of peritoneum from the posterior wall; this is known as the *right gastropancreatic fold*. Similarly, the upwards course of the left gastric artery raises another similar fold, called the *left gastropancreatic fold*. These folds divide the lesser sac into a superior and an inferior recess (Figs 18.24 and 18.25).
- 2 The *superior recess* of the lesser sac lies behind the lesser omentum and the liver. The portion behind the lesser omentum is also known as the *vestibule* of the lesser sac.
- 3 The *inferior recess* of the lesser sac lies behind the stomach and within the greater omentum.
- 4 The *splenic recess* of the lesser sac lies between the gastrosplenic and lienorenal ligaments.

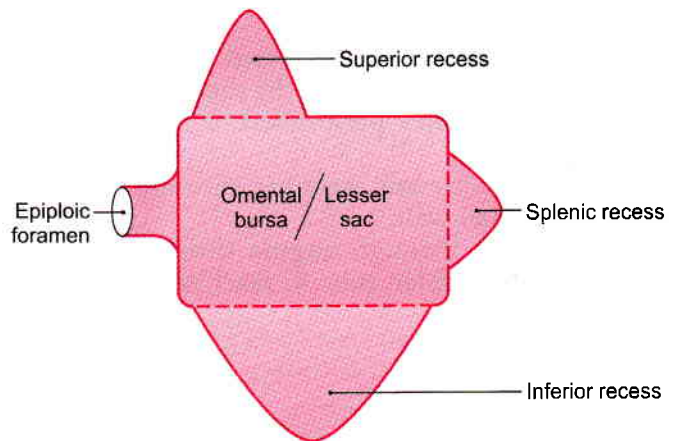


Fig. 18.24: The lesser sac with its opening and recesses

CLINICAL ANATOMY

- Strangulated internal hernia into the lesser sac through epiploic foramen is approached through the greater omentum because the epiploic foramen cannot be enlarged due to the presence of important structures all around it (Fig. 18.26).
- A posterior gastric ulcer may perforate into the lesser sac. The leaking fluid passes out through epiploic foramen to reach the hepatorenal pouch. Sometimes in these cases the epiploic foramen is closed by adhesions. Then the lesser sac becomes distended, and can be drained by a tube passed through the lesser omentum.
- *Peritonitis:* Parietal peritoneum of abdomen is supplied by T7–T12 and L1 nerves, while that of

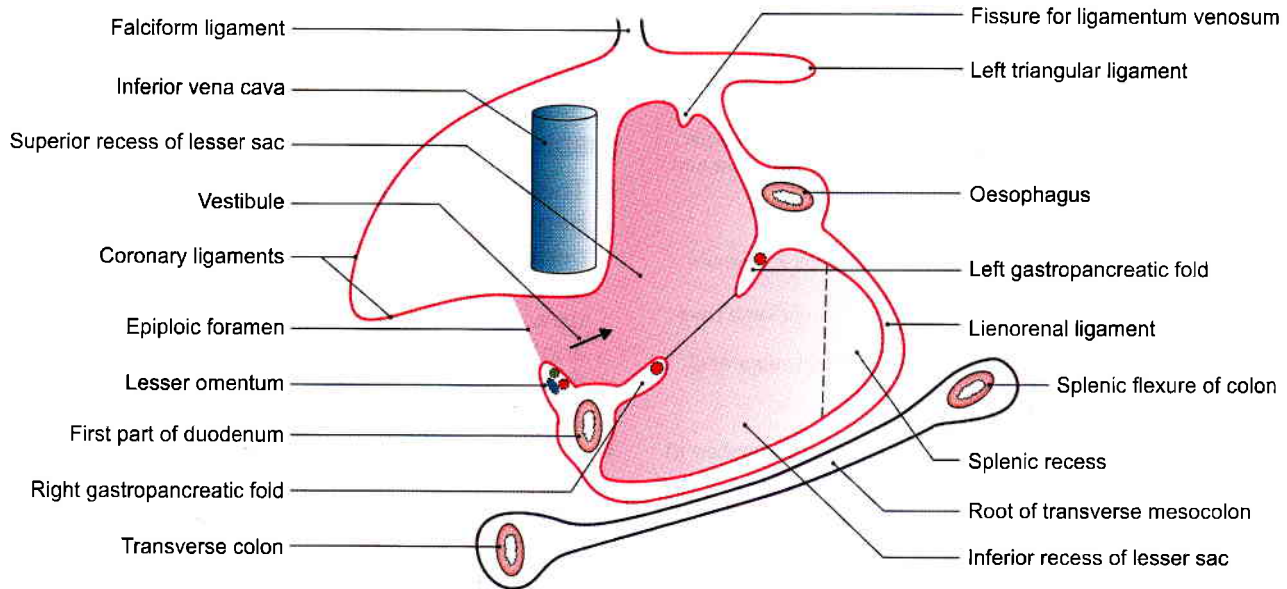


Fig. 18.25: Lesser sac seen after removal of its anterior wall

the pelvis is supplied by the obturator nerve. Peritonitis may occur:

- By an opening in the closed gastrointestinal tract in abdominal cavity, by ruptured appendix or gastric ulcer perforation or typhoid ulcer perforation.
- Infection by any opening through anterior abdominal wall.
- Infection through vagina through uterine cavity, fallopian tube to reach the peritoneal cavity.

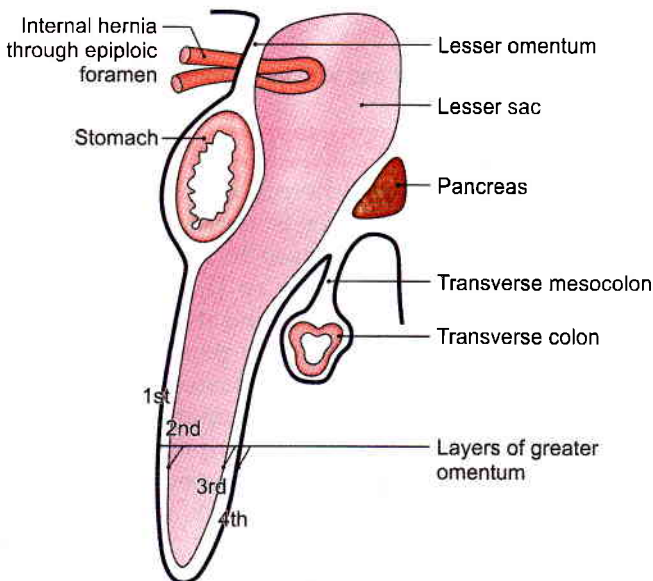


Fig. 18.26: Internal hernia into the lesser sac

SPECIAL REGIONS OF THE PERITONEAL CAVITY

From a surgical point of view the peritoneal cavity has two main parts, the abdomen proper and the pelvic cavity. The abdominal cavity is divided by the transverse colon and the transverse mesocolon into the *supracolic* and *infracolic compartments*. The supracolic compartment is subdivided by the reflection of peritoneum around the liver into a number of *subphrenic spaces*. The infracolic compartment is also subdivided, by the mesentery, into right and left parts. Further, the right *paracolic gutter* lies along the lateral side of the ascending colon, and the *left paracolic gutter* along the lateral side of the descending colon (Fig. 18.27).

DEVELOPMENT

- Right pneumo-enteric recess in the right wall of dorsal mesogastrium grows to form the greater part of the lesser sac, except for the vestibule.

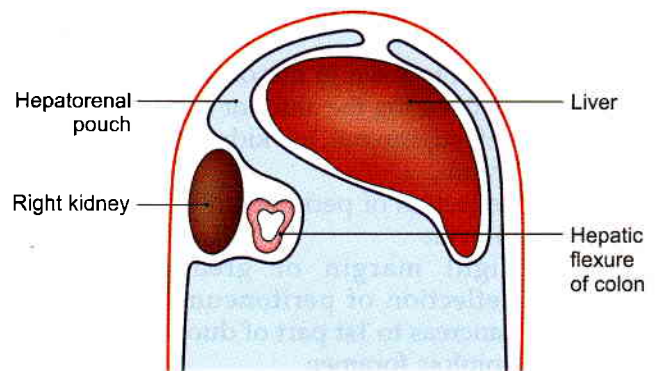


Fig. 18.27: Subphrenic spaces shown in relation to the transverse colon



- 2 Vestibule develops from the general peritoneal cavity lying behind the lesser omentum after the rotation of stomach.

SUPRACOLIC COMPARTMENT/SUBPHRENIC SPACES

Subphrenic spaces are present just below the diaphragm in relation to the liver (Fig. 18.27).

Classification

The *intraperitoneal spaces* are:

- 1 The left anterior space
- 2 The left posterior space
- 3 The right anterior space
- 4 The right posterior space.

The *extraperitoneal spaces* include:

- 1 The right extraperitoneal space
- 2 The left extraperitoneal space
- 3 Midline extraperitoneal space is the name given to bare area of liver.

Some details of these spaces are as follows.

- a. The *left anterior space* or the left subphrenic space lies between the left lobe of the liver and the diaphragm, in front of the left triangular ligament. Inferiorly, it extends to the front of the lesser omentum and of the stomach. Towards the left it reaches the spleen. An abscess may form in this space following operations on the stomach, the spleen, the splenic flexure of the colon, and the tail of the pancreas.
- b. The *left posterior space* or the left subhepatic space is merely the lesser sac which has already been described.
- c. The *right anterior space* or right subphrenic space lies between the right lobe of the liver and the diaphragm, in front of the superior layer of the coronary ligament and the right triangular ligament. Infection may spread to this space from the gallbladder, or the vermiform appendix; or may follow operations on the upper abdomen.
- d. The *right posterior space* or right subhepatic space is also called the hepatorenal pouch of Morrison. It is described below.
- e. The *left extraperitoneal space* lies around the left suprarenal gland and the upper pole of the left kidney. This is the site for a left perinephric abscess.
- f. Right extraperitoneal space lies around upper pole of right kidney.
- g. The midline *extraperitoneal space* corresponds to the bare area of the liver. It lies between the bare area and the diaphragm. It is bounded above and below by the superior and inferior layers of the coronary ligament. Infection can spread to this space from the liver, resulting in liver abscess (Fig. 18.15).

Hepatorenal Pouch (Morrison's Pouch)

Boundaries

Anteriorly

- 1 The inferior surface of the right lobe of the liver.
- 2 The gallbladder.

Posteriorly

- 1 The right suprarenal gland
- 2 The upper part of the right kidney
- 3 The second part of the duodenum
- 4 The hepatic flexure of the colon
- 5 The transverse mesocolon
- 6 A part of the head of the pancreas.

Superiorly: The inferior layer of the coronary ligament:

Inferiorly: It opens into the general peritoneal cavity (Fig. 18.28).

Left: Communicate with omental bursa.

Right: Limited by diaphragm.

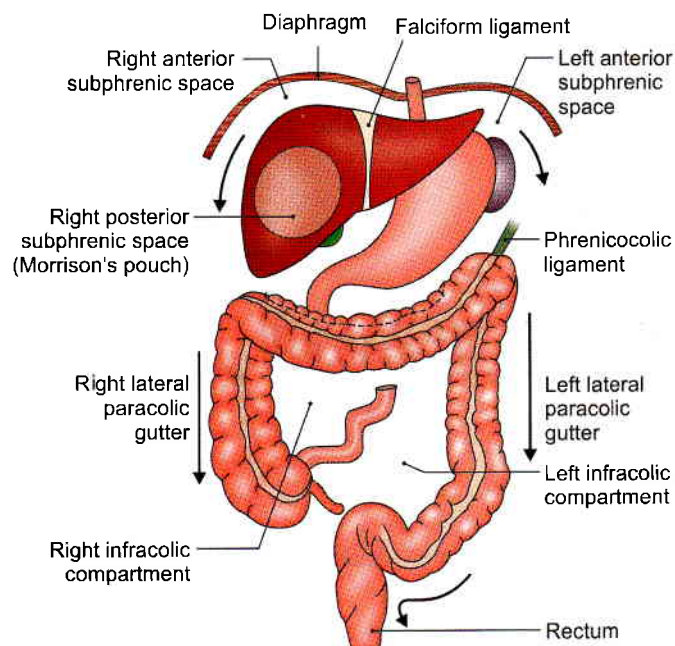


Fig. 18.28: Subphrenic spaces

INFRACOLIC COMPARTMENTS

Right Infracolic Compartment

It lies between the ascending colon and the mesentery, below the transverse mesocolon. It is triangular in shape with its apex directed downwards (Fig. 18.28).

Left Infracolic Compartment

It lies between the descending colon and the mesentery. It is also triangular with its apex directed upwards. Inferiorly, it opens freely into the pelvis.



Paracolic Gutters

The *right lateral paracolic gutter* opens freely into the hepatorenal pouch at its upper end. It may be infected by a downwards spread of infection from the hepatorenal pouch or from the lesser sac, or by an upward spread from the appendix.

The *left lateral paracolic gutter* opens freely into the pelvis at its lower end. Above it is separated from the spleen and from the lienorenal space by the phrenicocolic ligament. It may be infected from the supracolic compartment, or by an upward spread of infection from the pelvis (Fig. 18.28).

RECTOUTERINE POUCH (POUCH OF DOUGLAS)

This is the most dependent part of the peritoneal cavity when the body is in the upright position. In the supine position, it is the most dependent part of the pelvic cavity (Fig. 18.30).

Boundaries

- *Anteriorly*, by the uterus and the posterior fornix of the vagina.
- *Posteriorly*, by the rectum (Figs 18.29 and 18.30).
- *Inferiorly* (floor) by the rectovaginal fold of peritoneum.

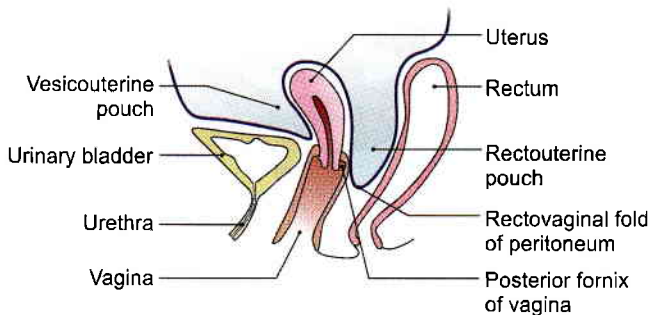


Fig. 18.29: Morrison's or hepatorenal pouch with rectouterine or Douglas pouch

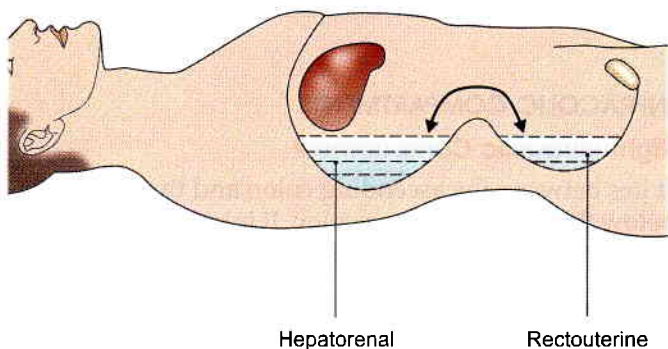


Fig. 18.30: Left view of a sagittal section through the rectouterine pouch

CLINICAL ANATOMY

- Intraoperative subphrenic spaces may get distended by collection of pus. These are called subphrenic abscesses (Fig. 18.31).
- Hepatorenal space is of considerable importance as it is the most dependent (lowest) part of the abdominal cavity proper when the body is supine. Fluids tend to collect here. This is the commonest site of a subphrenic abscess, which may be caused by spread of infection from the gallbladder, the appendix, or other organs in the region (Figs 18.27 and 18.28).
- The floor of the rectouterine pouch is 5.5 cm from the anus, and can be easily felt with a finger passed through the rectum or the vagina. The corresponding rectovesical pouch in males lies 7.5 cm above the anus (Fig. 18.28).

Being the most dependent part of the peritoneal cavity, pus tends to collect here.

The infected fluid collects mostly in subphrenic space especially the hepatorenal pouch as it is deepest when person is lying supine. If patient sits in inclined position, the infected material tracks down to rectouterine pouch in female or to rectovesical pouch in male (Figs 18.29 and 18.30).

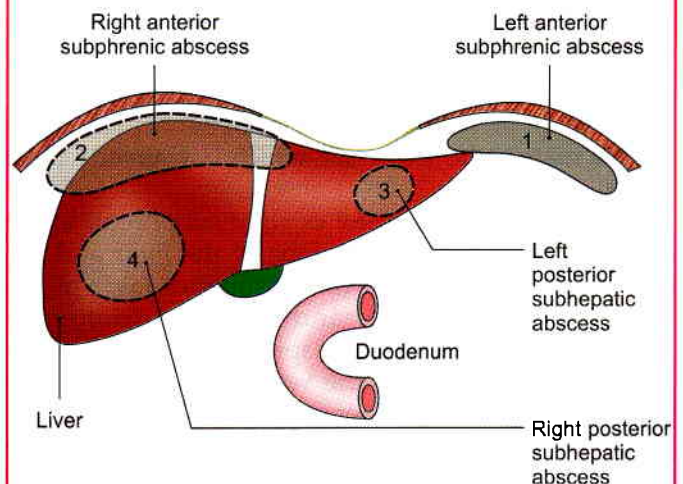
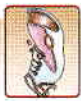

Fig. 18.31: 1–4 are sites of intraperitoneal subphrenic abscesses. Peritoneal reflections on the liver is also shown

PERITONEAL FOSSAE (RECESSES)

These are small pockets of the peritoneal cavity enclosed by small, inconstant folds of peritoneum. They commonly occur at the transitional zones between the absorbed and unabsorbed parts of the mesentery. These are best observed in foetuses, and are mostly obliterated in adults. Sometimes they persist to form potential sites for internal hernia and their strangulation.



Classification

Lesser Sac

The lesser sac is the largest recess. It is always present, and has been described earlier.

Duodenal Fossae or Recesses

- 1 The *superior duodenal recess* is present in about 50% of subjects. It is situated at the level of vertebra L2. It is about 2 cm deep. Its orifice looks downwards (Fig. 18.32).
- 2 The *inferior duodenal recess* is present in about 75% of subjects. It is situated at the level of vertebra L3. It is about 3 cm deep. Its orifice looks upwards.
- 3 The *paraduodenal recess* is present in about 20% of subjects. The *inferior mesenteric vein* lies in the free edge of the peritoneal fold. Its orifice looks to the right.
- 4 The *retroduodenal recess* is present occasionally. It is the largest of the duodenal recesses. It is 8 to 10 cm deep. Its orifice looks to the left.
- 5 The *duodenojejunal* or *mesocolic recess* is present in about 20% of subjects. It is about 3 cm deep. Its orifice looks downwards and to the right.
- 6 The *mesentericoparietal fossa* of Waldeyer is present in about 1% of subjects. It lies behind the upper part of the mesentery. Its orifice looks to the left. The superior mesenteric vessels lie in the fold of peritoneum covering this fossa.

Caecal Fossae

- 1 The *superior ileocaecal recess* is quite commonly present. It is formed by a vascular fold present between the ileum and the ascending colon. Its orifice looks downwards and to the left (Fig. 18.33).

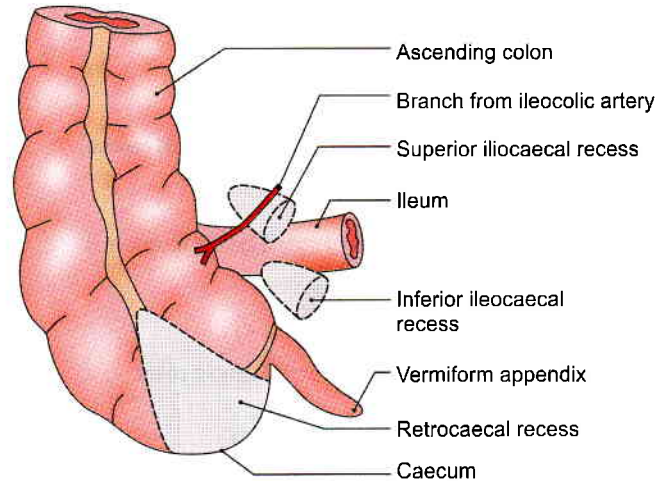


Fig. 18.33: Caecal recesses of peritoneum

- 2 The *inferior ileocaecal recess* is covered by the bloodless fold of Treves. The orifice of the recess looks downwards and to the left.
- 3 The *retrocaecal recess* lies behind the caecum. It often contains the appendix. Its orifice looks downwards.

The Intersigmoid Recess

This recess is constantly present in the foetus and in early infancy, but may disappear with age. It lies behind the apex of the sigmoid mesocolon. Its orifice looks downwards (Fig. 18.34).

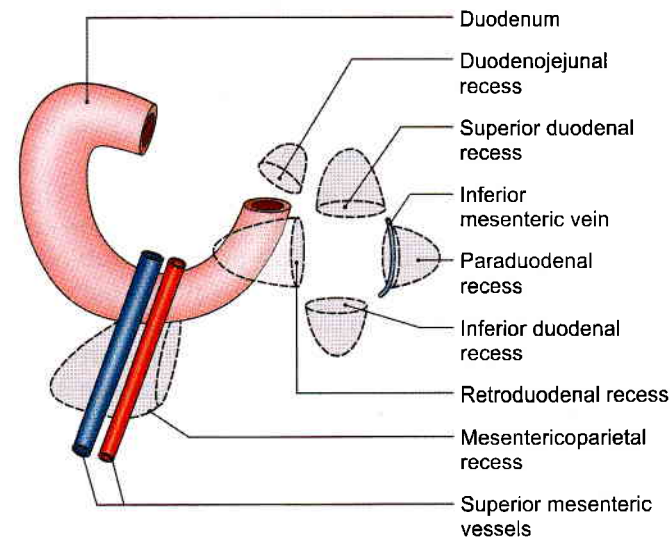


Fig. 18.32: Duodenal recesses of peritoneum

CLINICAL ANATOMY

- *Internal hernia:* May occur in the opening of lesser sac. It may also occur in between paraduodenal recesses. One has to remember the inferior mesenteric vein in the paraduodenal fold during reduction of the hernia (Fig. 18.32).
- Pain of foregut derived structures is felt in the epigastric area.
- Pain of midgut derived structures is felt in the periumbilical area (Fig. 18.35).
- Pain of hindgut derived structures is felt in the suprapubic area.
- Palpation of the abdominal viscera is done when the patient is in supine position, and the hip and knee are flexed. In extended position fascia lata of thigh exerts a pull on the inguinal ligament, making palpation difficult.

DEVELOPMENT

The primitive gut is formed by incorporation of secondary yolk sac into the embryo. The gut is divided into the following.

- 1 Pharyngeal gut (from buccopharyngeal membrane to tracheobronchial diverticulum). Its derivatives have been dealt in Volume 3.

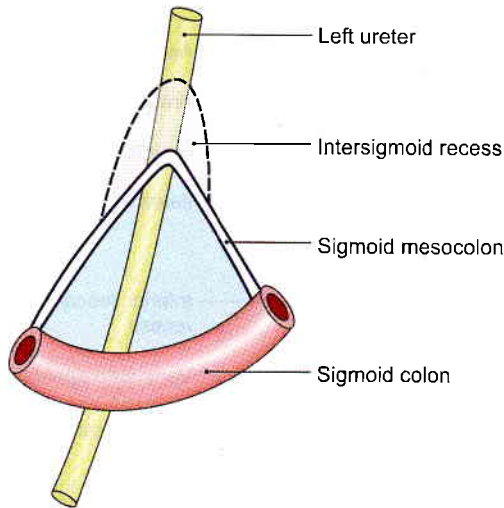


Fig. 18.34: Intersigmoid recess of peritoneum

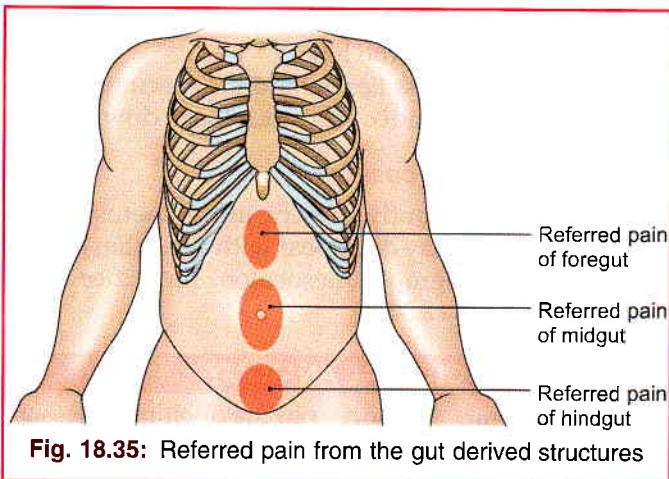


Fig. 18.35: Referred pain from the gut derived structures

- 2 Foregut situated caudal to pharyngeal gut till the origin of hepatic bud.
- 3 Midgut extends from origin to hepatic bud downwards. Its terminal point is the junction of right two-thirds and left one-third of transverse colon of adult. It communicates with the yolk sac.
- 4 Hindgut spans between the end of midgut and the cloacal membrane.

Dorsal mesentery is double fold of peritoneum connecting the caudal part of foregut, midgut and most of the hindgut to the posterior abdominal wall. It is subdivided into mesogastrum and mesoduodenum for foregut, into dorsal mesentery proper for jejunum and ileum; and mesentery of vermiform appendix, transverse and pelvic mesocolons for large intestine. Ventral mesentery only exists ventral to the foregut. It is a derivative of the septum transversum.

Derivatives of ventral mesogastrum:

- Lesser omentum
- Falciform ligament

- Coronary ligaments
- Triangular ligaments

Derivatives of dorsal mesogastrum:

- Greater omentum
- Lienorenal ligament
- Gastrophrenic ligament
- Gastrosplenic ligament



FACTS TO REMEMBER

- There are 9 regions of the abdominal cavity. These are right and left hypochondrium and middle epigastrium in upper part. In middle part are right and left lumbar and middle umbilical regions. In the lower part are right and left iliac fossae and middle hypogastrium.
- Abdominal part of foregut has a dorsal and ventral mesentery each.
- Midgut and hindguts have only the dorsal mesenteries each.
- Lesser sac with its fluid prevents compression of most of the posterior abdominal organs by the full stomach.
- Rectouterine pouch in female is 5.5 cm from surface of perineal skin.
- Rectovesical pouch in male is 7.5 cm away from the perineal skin.
- Peritoneal recesses are mostly present at the junction of intraperitoneal and retroperitoneal organs.
- Right posterior subphrenic space or Morrison's pouch is the deepest pouch in lying position.
- Spleen forming stomach bed is separated from stomach by the cavity of greater sac. Other organs forming bed are separated from stomach by lesser sac.

CLINICOANATOMICAL PROBLEM

An alcoholic patient has swelling of abdomen with veins radiating from the umbilicus

- Why does abdomen swell up in alcoholic person?
- What do the veins indicate?

Ans: In alcoholism, the liver is the site of insult. The hepatic cells shrink and get replaced by fibrous tissue. The portal vein is not able to empty its blood due to fibrosis. Pressure in portal vein, splenic vein and superior mesenteric vein rises leading to exudation of fluid and oedema. The veins around the umbilicus is an anastomoses between the paraumbilical veins tributaries of portal vein and superior and inferior epigastric veins, tributaries of vena cavae. This is a site of portosystemic anastomoses and is an attempt to take the portal blood back into systemic circulation.



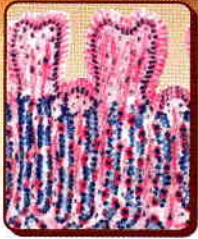
MULTIPLE CHOICE QUESTIONS

- Which of the following is not a retroperitoneal organ?
 - Pancreas
 - Spleen
 - Duodenum
 - Kidney
- Ligamentum teres is a remnant of:
 - Lesser omentum
 - Ductus venosus
 - Left umbilical vein
 - Left umbilical artery
- Blood vessel related to paraduodenal fossa is:
 - Portal vein
 - Gonadal vein
 - Superior mesenteric vein
 - Inferior mesenteric vein
- Posterior relation of foramen of Winslow is:
 - Liver
 - Duodenum
 - Inferior vena cava
 - Pancreas
- Lining of peritoneum is called
 - Mesothelium
 - Endothelium
 - Epithelium
 - None of the above
- Visceral peritoneum is derived from:
 - Somatic mesoderm
 - Splanchnic mesoderm
 - Neural crest
 - Endoderm
- Peritoneum is very loosely attached to:
 - Anterior abdominal wall close to the urinary bladder
 - Anterior abdominal wall above the umbilicus
 - Thoracoabdominal diaphragm
 - Posterior wall of pelvis around the rectum
- All the following organs have the mesentery *except*:
 - Small intestine
 - Rectum
 - Transverse colon
 - Sigmoid colon
- Duodenum is retroperitoneal *except*:
 - First 2.5 cm of 1st part
 - 2nd part
 - 3rd part
 - 4th part
- Ganglia situated in the submucosal and myenteric plexuses of intestine is
 - Sympathetic
 - Parasympathetic
 - Sensory
 - All of the above

ANSWERS

1. b 2. c 3. d 4. c 5. a 6. b 7. a 8. b 9. a 10. b

19



Abdominal Part of Oesophagus and Stomach

Whether one eats to live or lives to eat is controversial

INTRODUCTION

Only about one centimeter of oesophagus lies in the abdominal cavity. It acquires great importance as it is a site of portosystemic anastomoses.

Stomach is the chief organ in the epigastric and left hypochondriac regions. Its lesser curvature bears the brunt of all fluids which are too hot or too cold, including the insults by the alcoholic beverages.

OESOPHAGUS AND STOMACH

DISSECTION

Identify the stomach and trace it towards the abdominal part of oesophagus. Clean this part of oesophagus. Note various parts of stomach, e.g. cardiac end, fundus, body and pyloric parts. Trace the right and left gastric arteries along the lesser curvature and right and left gastroepiploic arteries along the greater curvature.

Tie two ligatures each at the lowest part of oesophagus and the pylorus. Remove the stomach by cutting between two upper ligatures through the oesophagus, left gastric artery, gastrophrenic ligament; and by cutting the pylorus between the lower two ligatures. Free the stomach from the adherent peritoneum if any and put it in a tray for further dissection.

ABDOMINAL PART OF OESOPHAGUS

- 1 The abdominal part of the oesophagus is only about 1.25 cm long (Fig. 19.1).
- 2 It enters the abdomen through the oesophageal opening of the diaphragm situated at the level of vertebra T10, slightly to the left of the median plane. It continues with the cardiac end of stomach (Fig. 19.2).
- 3 The oesophageal opening also transmits the anterior and posterior gastric nerves, the oesophageal branches of the left gastric artery and the accompanying veins.

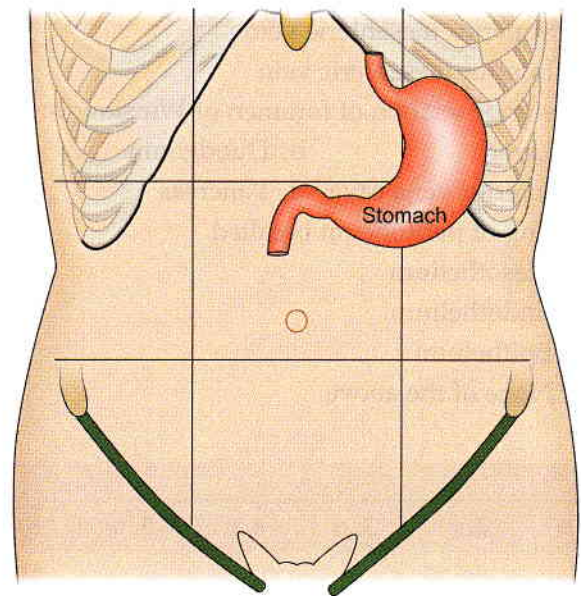


Fig. 19.1: Location of the stomach

- 4 These veins of oesophagus drain partly into portal and partly into systemic circulation. Veins accompanying left gastric vein drain into portal vein. Others drain into hemiazygos, in thoracic cavity, and continue into vena azygos and superior vena cava. So it is a site of portosystemic anastomoses (Fig. 19.3).
- 5 The oesophagus runs downwards and to the left in front of the left crus of the diaphragm and of the inferior surface of the left lobe of the liver, and ends by opening into the cardiac end of the stomach at the level of vertebra T11, about 2.5 cm to the left of the median plane. Its right border is continuous with the lesser curvature of the stomach, but the left border is separated from the fundus of the stomach by the cardiac notch (Figs 19.2 and 19.3). Peritoneum covers the oesophagus only anteriorly and on the left side.

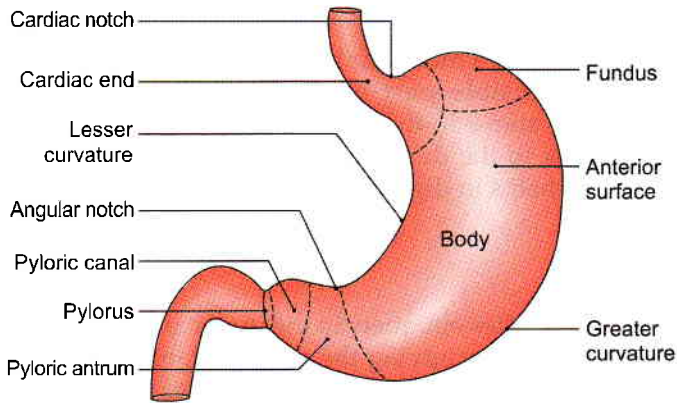


Fig. 19.2: External features of the stomach

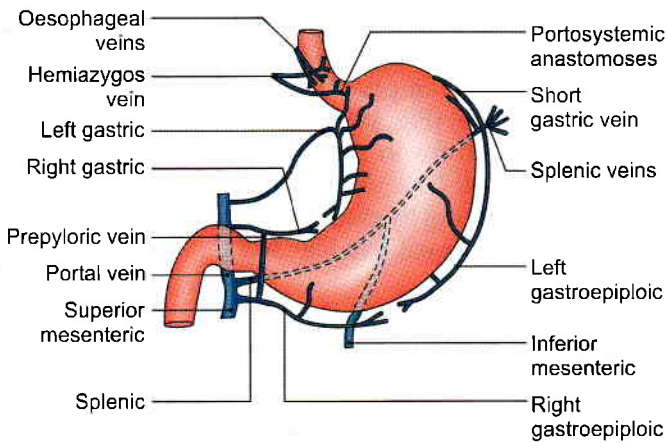


Fig. 19.3: Venous drainage of oesophagus and stomach

6 Anterior gastric nerve contains mainly the left vagal fibres, and the posterior gastric nerve mainly the right vagal fibres. Each gastric nerve is represented by one or two trunks and combines a few sympathetic fibres from the greater splanchnic nerve (Fig. 19.12a).

HISTOLOGY

Mucous membrane—Epithelial lining is stratified squamous nonkeratinised in nature. Lamina propria consists of loose connective tissue with papillae.

Muscularis mucosae is distinct in lower part and formed by longitudinal muscle fibres.

Submucosa contains mucus secreting oesophageal glands.

Muscularis externa is composed of striated muscle in upper third, mixed type in middle third and smooth muscles in lower third. Its outer layer comprises of longitudinal coat and inner layer comprises of circular coat of muscle fibres.

Adventitia is the connective tissue with capillaries.

CLINICAL ANATOMY

- The lower end of the oesophagus is one of the important sites for portosystemic anastomoses. In portal hypertension, the anastomoses opens and forms venous dilatations called *oesophageal varices*. Their rupture causes severe and dangerous haematemesis (Fig. 19.4).
- Normally the lower end of the oesophagus remains closed and dilates only during the passage of food. However, due to neuromuscular incoordination it may fail to dilate leading to difficulty in passage of food or dysphagia. The condition is known as *achalasia cardia*. Marked dilatation of the oesophagus may occur due to collection of food in it (Fig. 19.5).
- The lower end of the oesophagus is also prone to inflammation or ulceration by regurgitation of acid from the stomach. It is the commonest site of oesophageal carcinoma. Next site is the middle third of oesophagus.
- Hiatal hernia occurring through the oesophageal opening and can be rolling or paraoesophageal and sliding (Figs 19.6a and b).
- *Barrett's oesophagus*: Squamous epithelium of lower oesophagus may be replaced by columnar epithelium in certain clinical conditions. The abnormal type of epithelium present in oesophagus is referred as Barrett's epithelium.
- *Tracheo-oesophageal fistula*: At times the separation of trachea and oesophagus may not be complete. Proximal segment ends in a blind pouch and distal segment communicates with trachea (Fig. 19.7).
- The lumen of the oesophagus may be abnormally narrowed due to improper canalisation.
- The lumen of oesophagus may not be canalised at all leading to oesophageal stenosis.

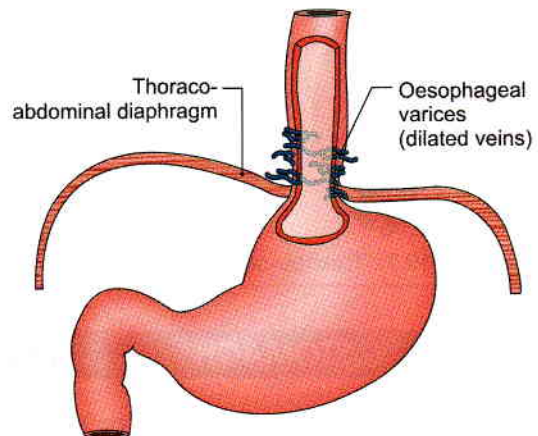


Fig. 19.4: Oesophageal varices at the lower end of oesophagus

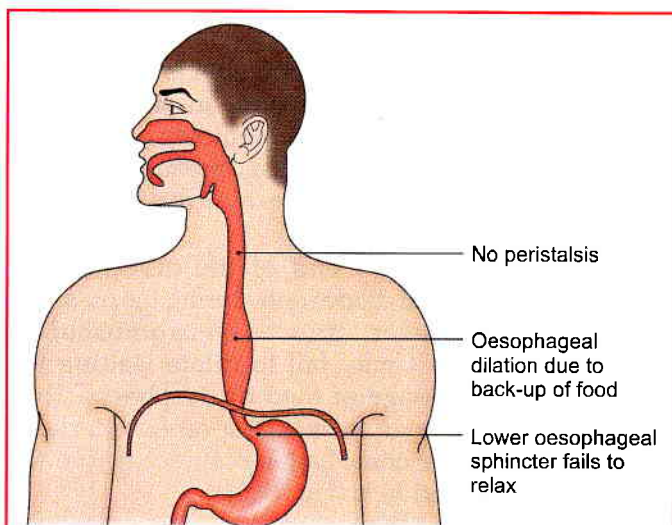
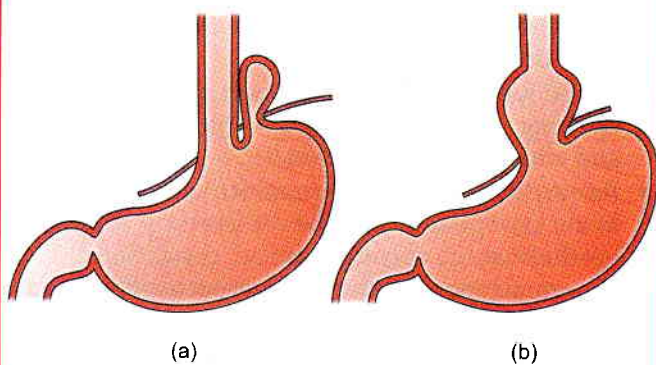


Fig. 19.5: Achalasia cardia



Figs 19.6a and b: Hiatal hernia: (a) Rolling, and (b) sliding

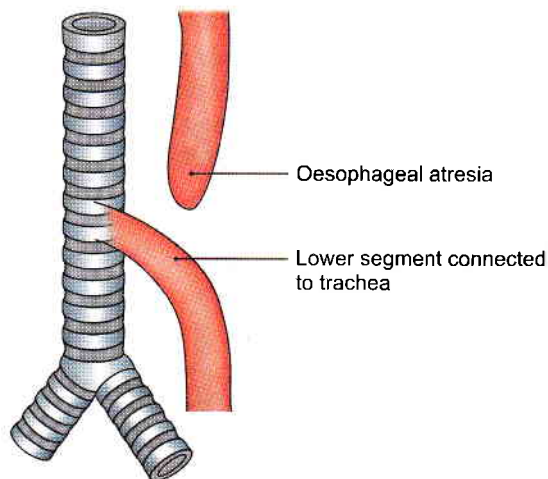


Fig. 19.7: Tracheo-oesophageal fistula

STOMACH

The stomach is also called the gaster or venter from which we have the adjective gastric applied to structures related to the organ (Fig. 19.1).

Definition

The stomach is a muscular bag forming the widest and most distensible part of the digestive tube. It is connected above to the lower end of the oesophagus, and below to the duodenum. It acts as a reservoir of food and helps in digestion of carbohydrates, proteins and fats.

Location

The stomach lies obliquely in the upper and left part of the abdomen, occupying the epigastric, umbilical and left hypochondriac regions. Most of it lies under cover of the left costal margin and the ribs (Figs 19.1 and 19.8).

Shape and Position

The shape of the stomach depends upon the degree of its distension and that of the surrounding viscera, e.g. the colon. When empty, the stomach is somewhat J-shaped (vertical) (Fig. 19.2); when partially distended, it becomes pyriform in shape. In obese persons, it is more horizontal. The shape of the stomach can be studied in the living by radiographic examination after giving a barium meal (see Fig. 36.2).

Size and Capacity

The stomach is a very distensible organ. It is about 25 cm long, and the mean capacity is one ounce (30 ml) at birth, one litre (1000 ml) at puberty, and 1½ to 2 liters or more in adults.

EXTERNAL FEATURES

The stomach has two orifices or openings, two curvatures or borders, and two surfaces (Fig. 19.2).

Two Orifices

The *cardiac orifice* is joined by the lower end of the oesophagus. It lies behind the left 7th costal cartilage 2.5 cm from its junction with the sternum, at the level of vertebra T11. There is physiological evidence of sphincteric action at this site, but a sphincter cannot be demonstrated anatomically.

The *pyloric orifice* opens into the duodenum. In an empty stomach and in the supine position, it lies 1.2 cm to the right of median plane, at the level of lower border of vertebra L1 or transpyloric plane. Its position is indicated on the surface of the stomach:

- By a circular groove (*pyloric constriction*, i.e. *sthenic*. Sometime it may be *hyposthenic* (thin and long) *hypersthenic pylorus*) produced by the underlying pyloric sphincter or pylorus (*pylorus* = gate guard) which feels like a large firm nodule (Fig. 19.2).
- By the *prepyloric vein* which lies in front of the constriction (Fig. 19.3).



Two Curvatures

The *lesser curvature* is concave and forms the right border of the stomach. It provides attachment to the lesser omentum. The most dependent part of the curvature is marked by the *angular notch* or *incisura angularis* (Fig. 19.2).

The *greater curvature* is convex and forms the left border of the stomach (see Figs 18.9 and 18.18). It provides attachment to the greater omentum, the gastrosplenic ligament and the gastrophrenic ligament. At its upper end the greater curvature presents the *cardiac notch* which separates it from the oesophagus.

Two Surfaces

The *anterior* or *anterosuperior surface* faces forwards and upwards.

The *posterior* or *posteroinferior surface* faces backwards and downwards.

Two Parts Subdivided into Four

The stomach is divided into two parts. (i) Cardiac and (ii) Pyloric, by a line drawn downwards and to the left from the *incisura angularis*. The larger, cardiac part is further subdivided into the fundus and body, and the smaller, pyloric part is subdivided into the pyloric antrum and pyloric canal (Fig. 19.2).

Cardiac Part

- 1 The *fundus* of the stomach is the upper convex dome-shaped part situated above a horizontal line drawn at the level of the cardiac orifice. It is commonly distended with gas which is seen clearly in radiographic examination under the left dome of the diaphragm (see Fig. 20.14).
- 2 The *body* of the stomach lies between the fundus and the pyloric antrum. It can be distended enormously along the greater curvature. The gastric glands distributed in the fundus and body of stomach, contain all three types of secretory cells, namely:
 - a. The mucous cells.
 - b. The chief, peptic or zymogenic cells which secrete the digestive enzymes.
 - c. The parietal or oxyntic cells which secrete HCl.

Pyloric Part

- 1 The *pyloric antrum* is separated from the pyloric canal by an inconstant sulcus, *sulcus intermedius* present on the greater curvature. It is about 7.5 cm long. The pyloric glands are richest in mucous cells.
- 2 The *pyloric canal* is about 2.5 cm long. It is narrow and tubular. At its right end it terminates at the pylorus.

Relations of Stomach

Peritoneal Relations

The stomach is lined by peritoneum on both its surfaces. At the lesser curvature the layers of peritoneum lining the anterior and posterior surfaces meet and become continuous with the *lesser omentum* (see Fig. 18.8).

Along the greater part of the greater curvature the two layers meet to form the *greater omentum*.

Near the fundus the two layers meet to form the gastrosplenic ligament.

Near the cardiac end the peritoneum on the posterior surface is reflected on to the diaphragm as the *gastrophrenic ligament* (see Fig. 18.8). Cranial to this ligament a small part of the posterior surface of the stomach is in direct contact with the diaphragm (left crus). This is the *bare area of the stomach*. The greater and lesser curvatures along the peritoneal reflections are also bare.

Visceral Relations

The anterior surface of the stomach is related to the liver, the diaphragm, transverse colon and the anterior abdominal wall. The areas of the stomach related to these structures are shown in Fig. 19.8. The diaphragm separates the stomach from the left pleura, the pericardium, and the sixth to ninth ribs. The costal cartilages are separated from the stomach by the *transversus abdominis*. Gastric nerves and vessels ramify deep to the peritoneum.

The space between left costal margin and lower edge of left lung on stomach is known as *Traube's space*. Normally, on percussion there is resonant note over this space; but in splenomegaly or pleural effusion, a dull note is felt at this site.

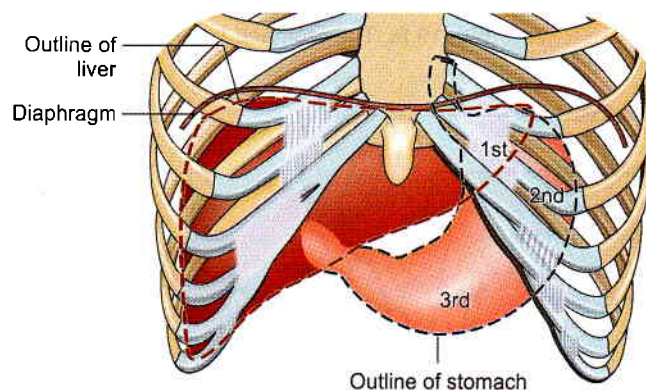


Fig. 19.8: Anterior relations of stomach. Area 1st is covered by the liver; area 2nd by the diaphragm; and area 3rd by the anterior abdominal wall

The posterior surface of the stomach is related to structures forming the stomach bed, all of which are separated from the stomach by the cavity of the lesser sac.



These structures are:

- a. Diaphragm.
- b. Left kidney.
- c. Left suprarenal gland.
- d. Pancreas (Fig. 19.9).
- e. Transverse mesocolon.
- f. Splenic flexure of the colon.
- g. Splenic artery (Fig. 19.9). Sometimes the spleen is also included in the stomach bed, but it is separated from the stomach by the cavity of the greater sac (and not of the lesser sac). Gastric nerves and vessels ramify deep to the peritoneum (Figs 19.10 and 19.12).

Blood Supply

The stomach is supplied along the lesser curvature by:

- 1 The left gastric artery, a branch of the coeliac trunk.
- 2 The right gastric artery, a branch of the proper hepatic artery.

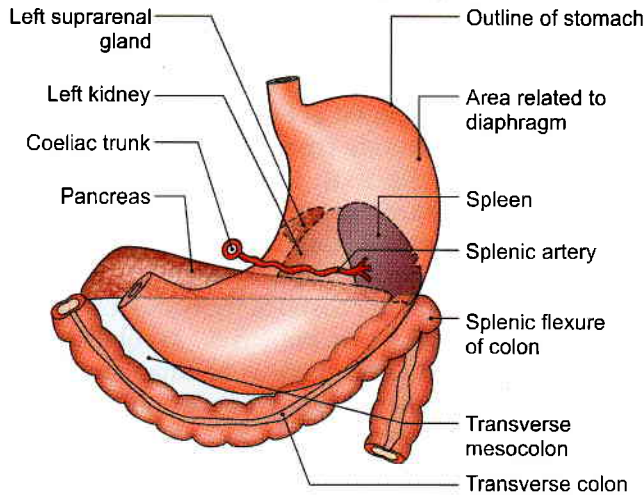


Fig. 19.9: The stomach bed

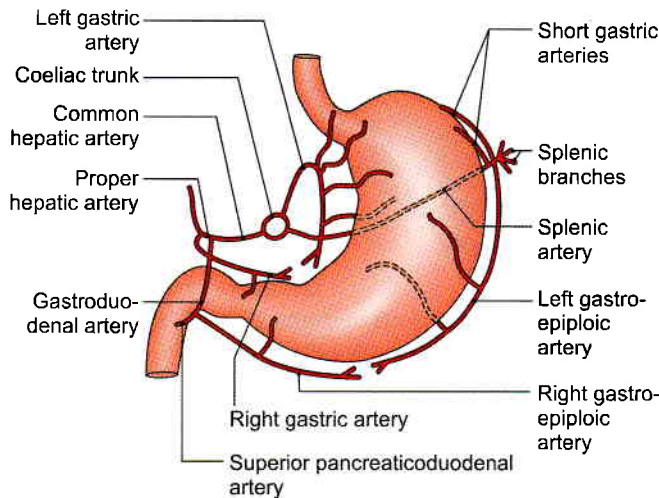


Fig. 19.10: Arteries supplying the stomach

- 3 Along the greater curvature it is supplied by the right gastroepiploic artery, a branch of the gastroduodenal.
- 4 The left gastroepiploic artery, a branch of the splenic.
- 5 Fundus is supplied by 5 to 7 short gastric arteries, which are also branches of the splenic artery (Fig. 19.10).

The veins of the stomach drain into the portal, superior mesenteric and splenic veins.

Right and left gastric drain in the portal vein. Right gastroepiploic ends in superior mesenteric vein; while left gastroepiploic and short gastric veins terminate in splenic vein (Fig. 19.3).

LYMPHATIC DRAINAGE

The stomach can be divided into four lymphatic territories as shown in Fig. 19.11. The drainage of these areas is as follows.

Area (a) of Fig. 19.11, i.e. upper part of left 1/3rd drains into the *pancreaticosplenic nodes* lying along the splenic artery, i.e. on the back of the stomach. Lymph vessels from these nodes travel along the splenic artery to reach the coeliac nodes.

Area (b), i.e. right 2/3rd drains into the *left gastric nodes* lying along the artery of the same name. These nodes also drain the abdominal part of the oesophagus. Lymph from these nodes drains into the coeliac nodes.

Area (c), i.e. lower part of left 1/3rd drains into the right gastroepiploic nodes that lie along the artery of the same name. Lymph vessels arising in these nodes drain into the subpyloric nodes which lie in the angle between the first and second parts of the duodenum. From here the lymph is drained further into the hepatic nodes that lie along the hepatic artery; and finally into the coeliac nodes.

Lymph from *area (d)*, i.e. pyloric part drains in different directions into the pyloric, hepatic, and left

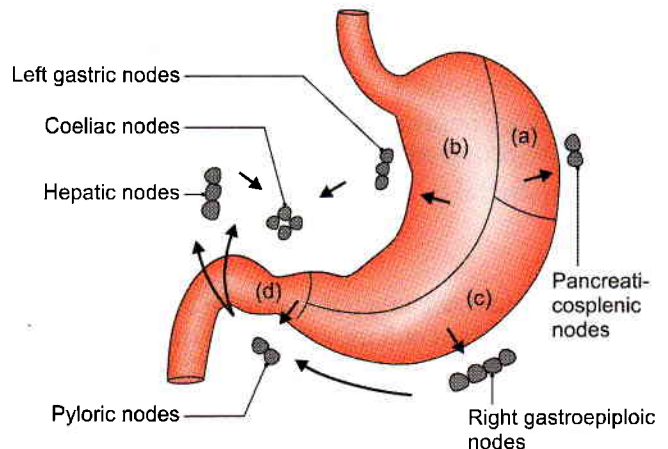


Fig. 19.11: Lymphatic drainage of the stomach. Note the manner in which the organ is subdivided into a to d different territories



gastric nodes, and passes from all these nodes to the coeliac nodes.

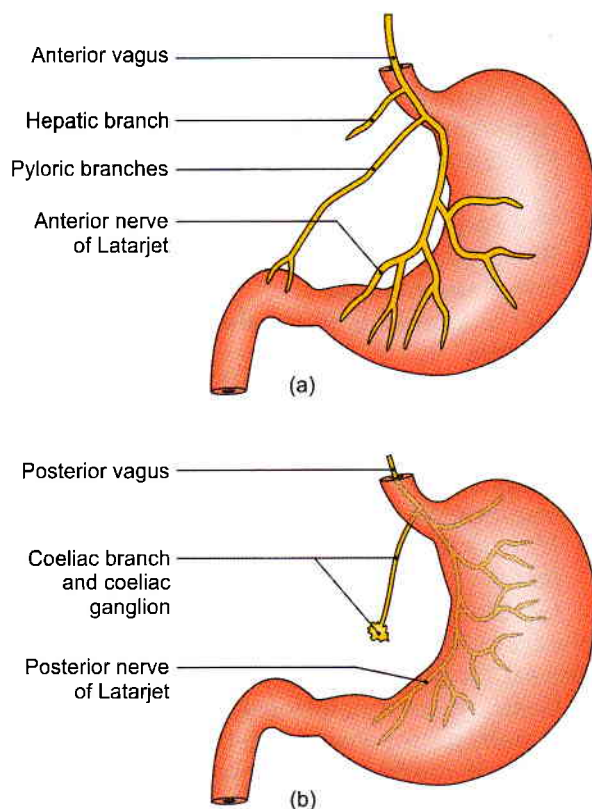
Note that lymph from all areas of the stomach ultimately reaches the coeliac nodes. From here it passes through the *intestinal lymph trunk* to reach the *cisterna chyli*.

Nerve Supply

The stomach is supplied by sympathetic and parasympathetic nerves. The *sympathetic nerves* are derived from thoracic six to ten segments of the spinal cord, via the greater splanchnic nerves, and coeliac and hepatic plexuses. They travel along the arteries supplying the stomach. These nerves are:

- Vasomotor.
- Motor to the pyloric sphincter, but inhibitory to the rest of the gastric musculature.
- The chief pathway for pain sensations from the stomach.

The *parasympathetic nerves* (Figs 19.12a and b) are derived from the vagi, through the oesophageal plexus and gastric nerves. The anterior gastric nerve (made up of one or two trunks) contains mainly the left vagal fibres, and the posterior gastric nerve (again made up of one to two trunks) contains mainly the right vagal fibres.



Figs 19.12a and b: Nerve supply of the stomach: (a) Anterior gastric nerve, and (b) posterior gastric nerve

The *anterior gastric nerve* divides into:

- A number of gastric branches for the anterior surface of the fundus and body of the stomach.
- Two pyloric branches, one for the pyloric antrum and another for the pylorus.

The *posterior gastric nerve* divides into:

- Smaller, gastric branches for the posterior surface of the fundus, the body and the pyloric antrum.
- Larger, coeliac branches for the coeliac plexus.

Parasympathetic nerves are motor and secreto-motor to the stomach. Their stimulation causes increased motility of the stomach and secretion of gastric juice rich in pepsin and HCl. These are inhibitory to the pyloric sphincter.

INTERIOR OF STOMACH

DISSECTION

Open the stomach along the greater curvature and examine the mucous membrane with a hand lens.

Then strip the mucous membrane from one part and expose the internal muscle coat. Dissect the muscle coat, e.g. outer longitudinal, middle circular and inner oblique muscle fibres. Feel thickened pyloric sphincter.

Incise the beginning of duodenum and examine the duodenal and pyloric aspects of the pyloric sphincter.

Features

The stomach has to be opened to see its internal structure.

- The *mucosa* of an empty stomach is thrown into folds termed as gastric rugae. The rugae are longitudinal along the lesser curvature and are irregular elsewhere. The rugae are flattened in a distended stomach. On the mucosal surface there are numerous small depressions that can be seen with a hand lens. These are the *gastric pits*. The gastric glands open into these pits.

The part of the lumen of the stomach that lies along the lesser curvature, and has longitudinal rugae, is called the *gastric canal* or *magenstrasse*. This canal allows rapid passage of swallowed liquids along the lesser curvature directly to the lower part before it spreads to the other part of stomach (Fig. 19.13).

Thus lesser curvature bears maximum insult of the swallowed liquids, which makes it vulnerable to peptic ulcer. *So, beware of your drinks.*

- Submucous coat* is made of connective tissue, arterioles and nerve plexus.
- Muscle coat* is arranged as under:
 - Longitudinal fibres are most superficial, mainly along the curvatures.
 - Inner circular fibres encircle the body and are thickened at pylorus to form pyloric sphincter (Fig. 19.14).

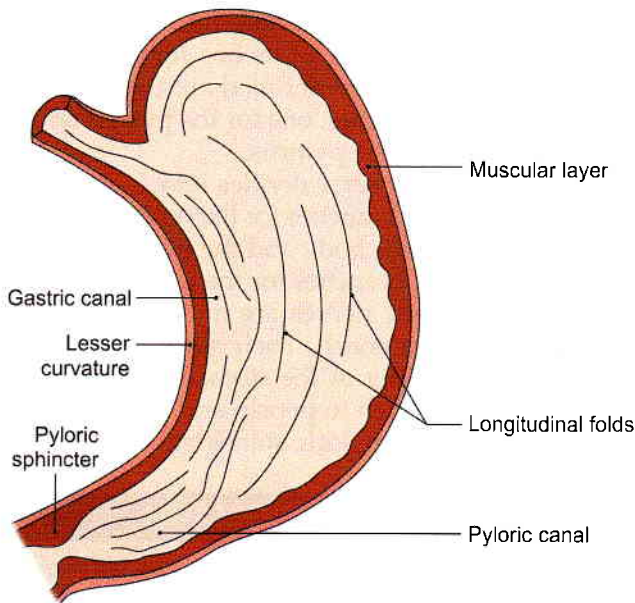


Fig. 19.13: Longitudinal folds of mucous membrane

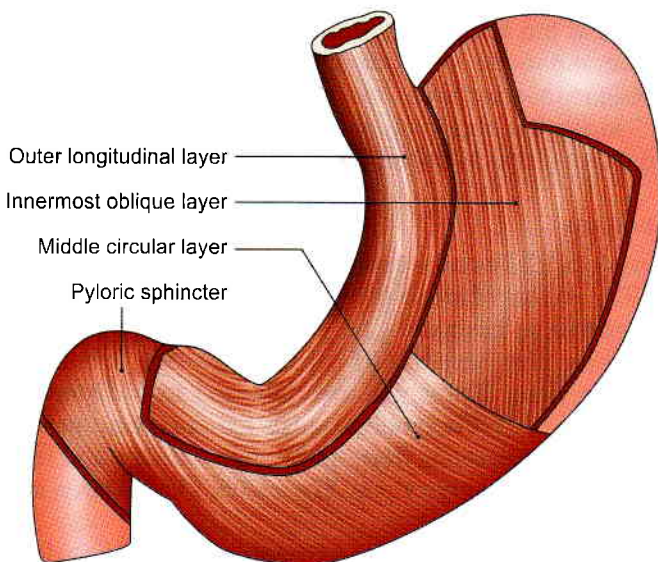


Fig. 19.14: Smooth muscle layers of the wall of stomach

c. The deepest layer consists of oblique fibres which loop over the cardiac notch. Some fibres spread in the fundus and body of stomach. Rest form a well-developed ridge on each side of the lesser curvature. These fibres on contraction form "gastric canal" for the passage of fluids.

4 *Serous coat* consists of the peritoneal covering.

Functions of Stomach

- 1 The stomach acts primarily as a reservoir of food. It also acts as a mixer of food.
- 2 By its peristaltic movements it softens and mixes the food with the gastric juice.

- 3 The gastric glands produce the gastric juice which contains enzymes that play an important role in digestion of food.
- 4 The gastric glands also produce hydrochloric acid which destroys many organisms present in food and drink.
- 5 The lining cells of the stomach produce abundant mucus which protects the gastric mucosa against the corrosive action of hydrochloric acid.
- 6 Some substances like alcohol, water, salt and few drugs are absorbed in the stomach.
- 7 Stomach produces the "intrinsic factor" of Castle which helps in the absorption of vitamin B₁₂.

CLINICAL ANATOMY

- Gastric pain is felt in the epigastrium because the stomach is supplied from segments T6 to T9 of the spinal cord, which also supply the upper part of the abdominal wall. Pain is produced either by spasm of muscle, or by over-distension. Ulcer pain is attributed to local spasm due to irritation (see Fig. 18.35).
- *Peptic ulcer* can occur in the sites of pepsin and hydrochloric acid, namely the stomach, first part of duodenum, lower end of oesophagus and Meckel's diverticulum. It is common in blood group 'O'.

Gastric ulcer occurs typically along the lesser curvature (Fig. 19.13). This is possibly due to the following peculiarities of lesser curvature.

- a. It is homologous with the gastric trough of ruminants.
- b. Mucosa is not freely movable over the muscular coat.
- c. The epithelium is comparatively thin.
- d. Blood supply is less abundant and there are fewer anastomoses.
- e. Nerve supply is more abundant, with large ganglia.
- f. Because of the gastric canal, it receives most of the insult from irritating drinks.
- g. Being shorter in length the wave of contraction stays longer at a particular point, viz., the standing wave of incisura.
- h. *H. pylori* infection is also an important causative factor.

Gastric ulcers are common in people who are always in "hurry", mostly "worry" about incidents and eat "spicy curry".

Gastric ulcer is notoriously resistant to healing and persists for years together, causing great degree of morbidity. To promote healing the irritating effect of HCl can be minimised by antacids, partial gastrectomy or vagotomy.



- *Gastric carcinoma* is common and occurs along the greater curvature. On this account the lymphatic drainage of stomach assumes importance. Metastasis can occur through the thoracic duct to the left supraclavicular lymph node (Troisier's sign). These lymph nodes are called as "signal nodes". It is common in blood group 'A'.
- *Pyloric obstruction* can be congenital or acquired. It causes visible peristalsis in the epigastrium, and vomiting after meals.
- *Hyposthenic stomach* is more prone for gastric ulcer, while hypersthenic stomach is prone for duodenal ulcer.

HISTOLOGY OF STOMACH

At the cardiac end of stomach the stratified epithelium of oesophagus *abruptly* changes to simple columnar epithelium of stomach.

Cardiac End

Mucous membrane: The epithelium is simple columnar with small tubular glands. Lower half of the gland is secretory and upper half is the conducting part. Muscularis mucosae consists of smooth muscle fibres.

Submucosa: It consists of loose connective tissue with Meissner's (German histologist 1829–1909) plexus.

Muscularis externa: It is made of outer longitudinal and inner circular layer including the myenteric plexus of nerves or Auerbach's plexus (German anatomist 1828–97).

Serosa: It is lined by single layer of squamous cells.

Fundus and Body of Stomach

Mucous membrane: It contains tall simple tubular gastric glands. Upper one-third is conducting, while lower two-thirds is secretory. The various cell types seen in the gland are chief or zymogenic, oxyntic or parietal and mucous neck cells (Fig. 19.15).

Muscularis mucosae and **submucosa** are same.

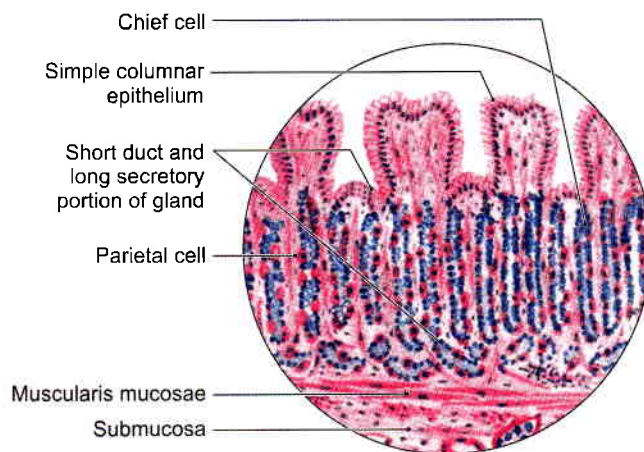
Muscularis externa: It contains an additional innermost oblique coat of muscle fibres.

Serosa is same as of cardiac end.

Pyloric Part

Mucous membrane: There are pyloric glands which consist of basal one-third as mucus secretory component and upper two-thirds as conducting part. Muscularis mucosae is made of two layers of fibres. Submucosa is same as in the cardiac end.

Muscularis externa comprises thick layer of circular fibres forming the pyloric sphincter. **Serosa** is same as of cardiac end.



- All epithelial cells are simple columnar in type
- Parietal cells are large and pink, Chief cell are small and blue
- Duct is 1/3rd and secretory part is 2/3rd

Fig. 19.15: Body/fundic mucosa

DEVELOPMENT

Oesophagus

The posterior part of foregut forms the oesophagus. It is very small in the beginning, but it lengthens due to descent of lungs and heart. The muscle of upper one-third is striated, middle one-third, mixed, and lower one-third smooth. Nerve supply to upper two-thirds is from vagus and to lower one-third is from autonomic plexus. Epithelium of oesophagus is endodermal and rest of the layers are from splanchnic mesoderm.

Stomach

The caudal part of foregut shows a fusiform dilatation with anterior and posterior borders and left and right surfaces. This is the stomach. It rotates 90° clockwise, so that left surface faces anteriorly. Even the original posterior border of stomach grows faster, forming the greater curvature.

The stomach also rotates along anteroposterior axis, so that distal or pyloric part moves to right and proximal or cardiac part moves to left side.

The 90° rotation of stomach along the vertical axis pulls the dorsal mesogastrum to the left side creating the lesser sac or omental bursa.

Spleen appears as mesodermal condensation in the left leaf of dorsal mesogastrum.

Mnemonics

25 cm long

Oesophagus, ureter and duodenum





FACTS TO REMEMBER

- Abdominal part of oesophagus is the site of porto-systemic anastomoses. Some veins drain into hemiazygos → vena azygos → superior vena cava. Other veins drain into oesophageal veins → left gastric vein → portal vein.
- Stomach comprises:
 - Two orifices: Cardiac and pyloric
 - Two curvatures: Lesser and greater
 - Two parts: Cardiac and pyloric
 - Cardiac part: Fundus and body
 - Pyloric part: Pyloric antrum, pyloric canal and pylorus.
- Anterior gastric nerve contains left vagal fibres and posterior gastric nerve contains right vagal fibres.
- Lesser curvature is the anterior border and greater curvature is the posterior border.
- Left and right gastric arteries run along lesser curvature.
- Left and right gastroepiploic arteries lie along greater curvature.
- Pylorus is identified by prepyloric vein
- Stomach bed is separated from the stomach by lesser sac.

- The gastric ulcer is common in people who “worry, hurry and eat hot curries”. Gastric ulcer commonly occurs along lesser curvature.
- Gastric cancer mostly occurs along greater curvature. Lymph from cancer → thoracic duct → left, supraclavicular node. It is called Virchow’s node. This sign is called Troisier’s sign.

CLINICOANATOMICAL PROBLEM

A young executive complained of pain in the abdomen, above the umbilicus. He was always in “hurry”, gets ‘worried’ very often and loves to eat spicy “curries”.

- What is the cause of pain?
- Why is pain referred to epigastric region?

Ans: The young man is suffering from gastric ulcer. The sympathetic nerves to the stomach are supplied by segments T6–T9 of the spinal cord, which also supply the upper part of the abdominal walls so the pain of gastric ulcer is referred to epigastric region. The pain of foregut derived areas is referred to epigastric region; those of midgut derived organs to periumbilical region while those of hindgut derived viscera to the suprapubic region.

A lifestyle change is recommended in such a case.

MULTIPLE CHOICE QUESTIONS

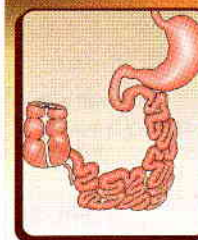
- Following structures form part of the stomach bed *except*:
 - Left suprarenal gland
 - Coeliac trunk
 - Splenic artery
 - Pancreas
- Which of the following is not present in the bed of stomach?
 - Splenic artery
 - Transverse mesocolon
 - Transverse colon
 - Fourth part of duodenum
- A posteriorly perforating peptic ulcer will most likely produce peritonitis in the following:

a. Greater sac	b. Lesser sac
c. Bare area of liver	d. Morrison’s pouch
- Which of the following arteries supply the fundus of the stomach?
 - Right gastric artery
 - Splenic artery
 - Short gastric arteries
 - Gastroduodenal artery
- Which cell of gastric gland gives it a beaded appearance?
 - Zymogenic
 - Oxyntic
 - Mucus cells
 - Columnar cell
- Cardiac orifice of stomach lies behind one of the following costal cartilages:

a. Left fifth	b. Left seventh
c. Left eighth	d. Right eighth

ANSWERS

1. b 2. d 3. b 4. c 5. b 6. b



Small and Large Intestines

A good surgeon is he who has a hawk's eye, a lions heart and a lady's hand
—Napolean Bonaparte

INTRODUCTION

The intestine, which is the longest part of the digestive tube, is divided into long, less distensible, small intestine, and shorter, more distensible large intestine. Food has to be digested, metabolised and stored for expulsion in the intestines. Intestines suffer from bacterial infection like typhoid, tuberculosis; parasitic infection, like roundworm, tape worm, etc. in addition to diarrhoea and dysentery. Good and healthy eating habits definitely prevent some of these conditions.

The proximal one and a half parts of duodenum, including liver, gallbladder and pancreas, develop from foregut. The distal two and a half parts of duodenum, jejunum, ileum, caecum, appendix, ascending colon and right two-thirds of transverse colon develop from midgut. Lastly, the left one-third of transverse colon, descending colon, pelvic colon and proximal part of rectum develop from hind gut.

SMALL INTESTINE

The small intestine extends from the pylorus to the ileocaecal junction. It is about 6 meters long. The length is greater in males than in females, and greater in cadavers, due to loss of tone than in the living. It is divided into:

- 1 An upper, fixed part, called the duodenum, which measures about 25 cm in length; and
- 2 A lower, mobile part, forming a very long convoluted tube.

The upper two-fifths of the mobile intestine are known as the jejunum, and the lower three-fifths are known as the ileum (Fig. 20.1). The structure of the small intestine is adapted for digestion and absorption.

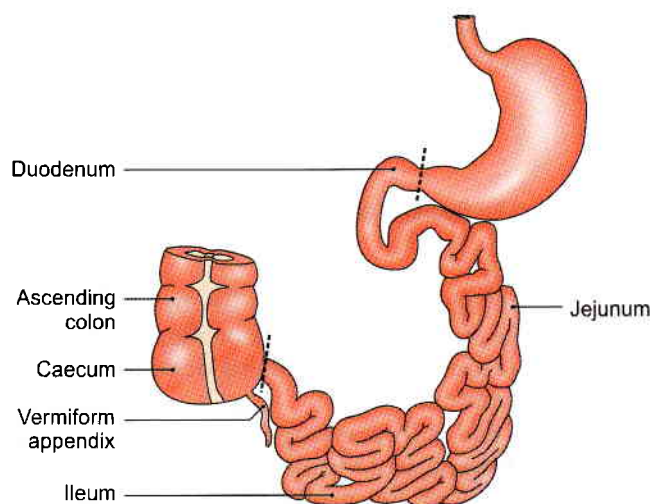


Fig. 20.1: Parts of small intestine

RELEVANT FEATURES

Large Surface Area

For absorption of digested food a very large surface area is required. This is achieved by:

- a. The great length of the intestine.
- b. The presence of circular folds of mucous membrane, villi and microvilli.

The circular folds of mucous membrane, *plicae circulares*, or *valves of Kerkring* form complete or incomplete circles. These folds are permanent, and are not obliterated by distension. They begin in the second part of the duodenum, and become large and closely set below the level of the major duodenal papilla. They continue to be closely set in the proximal half of the jejunum (Fig. 20.2), but diminish progressively in size and number in the distal half of the jejunum and in the proximal half of the ileum (Fig. 20.3). They are almost

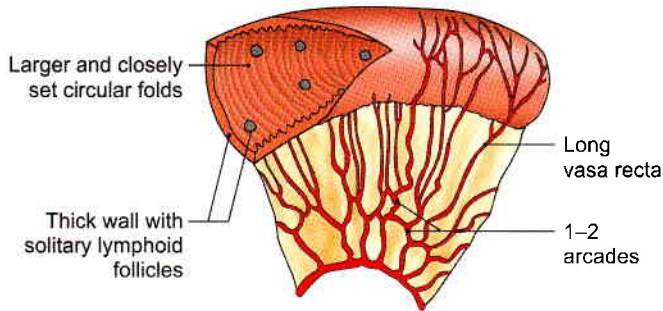


Fig. 20.2: Plicae circulares of jejunum.

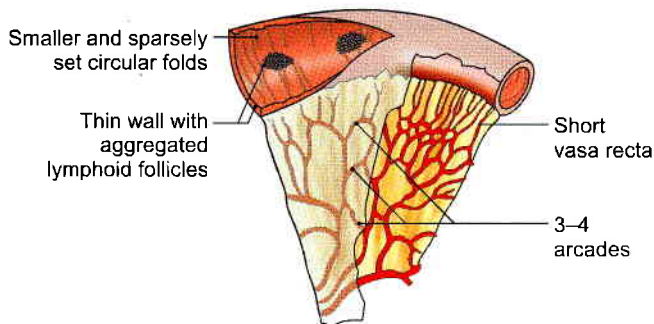


Fig. 20.3: Sparsely set plicae circulares of ileum

absent in the distal half of the ileum. Apart from increasing the surface area for absorption, the circular folds facilitate absorption by slowing down the passage of intestinal contents.

The *intestinal villi* are finger-like projections of mucous membrane, just visible to the naked eye. They give the surface of the intestinal mucosa a velvety appearance. They are large and numerous in the duodenum and jejunum, but are smaller and fewer in the ileum. They vary in density from 10 to 40 per square millimeter, and are about 1 to 2 mm long. They increase the surface area of the small intestine about eight times (Fig. 20.4).

Each villus is covered by a layer of absorptive columnar cells. The surface of these cells has a striated border which is seen, under the electron microscope to be made of *microvilli*.

Intestinal Glands or Crypts of Lieberkuhn

These are simple tubular glands distributed over the entire mucous membrane of the jejunum and ileum. They open by small circular apertures on the surface of mucous membrane between the villi. They secrete digestive enzymes and mucus. The epithelial cells deep in the crypts show a high level of mitotic activity. The proliferated cells gradually move towards the surface, to be shed from the tips of the villi. In this way, the complete epithelial lining of the intestine is replaced every *two to four days*.

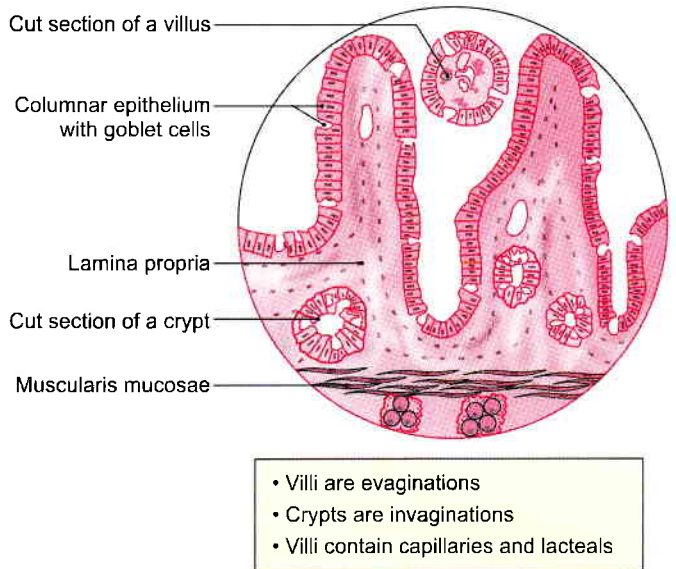


Fig. 20.4: Villi, crypts and submucous plexus of Meissner

The duodenal glands or Brunner's glands lie in the submucosa. These are small, compound tubuloacinar glands which secrete mucus.

Lymphatic Follicles

The mucous membrane of the small intestine contains two types of lymphatic follicles. The *solitary lymphatic follicles* are 1 to 2 mm in diameter, and are distributed throughout the small and large intestines. The *aggregated lymphatic follicles* or *Peyer's patches* form circular or oval patches, varying in length from 2 to 10 cm and containing 10 to over 200 follicles. They are largest and most numerous in the ileum, and are small, circular and fewer in the distal jejunum. They are placed lengthwise along the antimesenteric border of the intestine. Peyer's patches get ulcerated in *typhoid fever*, forming oval ulcers with their long axes along the long axis of the bowel.

Both the solitary and aggregated lymphatic follicles are most numerous at puberty, but thereafter diminish in size and number, although they may persist up to old age.

Each villus has a central lymph vessel called a *lacteal*. Lymph from lacteals drains into plexuses in the walls of the gut and from there to regional lymph nodes.

Arterial Supply

The *arterial supply* to jejunum and ileum is derived from the jejunal and ileal branches of the superior mesenteric artery. The *vasa recta* are distributed alternately to the opposite surfaces of the gut. They run between the serous and muscular coats, and give off numerous branches which supply and pierce the muscular coat



and form a plexus in the submucosa. From this plexus, minute branches pass to the glands and villi.

Lymphatics

The *lymphatics* (lacteals) have a circular course in the walls of the intestine. Tuberculous ulcers and subsequent strictures are due to involvement of these lymphatics. Large lymphatic vessels formed at the mesenteric border pass to the mesenteric lymph nodes.

Nerve Supply

The *nerve supply* of the small intestine is sympathetic (T9 to T11) as well as parasympathetic (vagus), both of which pass through the coeliac and superior mesenteric plexuses.

The nerves form the *myenteric plexus* of Auerbach, containing parasympathetic ganglia between circular and longitudinal muscle coats. Fibres from this plexus form the *submucous plexus* of Meissner which also contains parasympathetic ganglia.

Sympathetic nerves are motor to the sphincters and to the muscularis mucosae, and inhibitory for peristaltic movements.

The parasympathetic nerves stimulate peristalsis, but inhibit the sphincters.

The nerve plexuses and neurotransmitters of the gut are quite complex. These are called the *enteric nervous system*.

Function

The *function* of the small intestine comprises *digestion* and *absorption* of the digested contents from the fluid.

The parts of the small intestine are considered one by one.

DUODENUM

DISSECTION

Examine the C-shaped duodenum and head of pancreas lying in its concavity (Fig. 20.5). Cut through the lower wall of the first part extending the cut on medial wall of second and upper wall of third part of duodenum to see its interior.

Carefully look for the longitudinal fold on the posteromedial wall below the middle of second part. The longitudinal fold is often covered by a circular fold containing orifice of the major duodenal papilla draining both the bile and pancreatic ducts.

Identify and dissect the structures related to all the four parts of the duodenum.

Term

The term *duodenum* is a Latin corruption of the Greek word, *dudekadactulos*, meaning twelve fingers long.

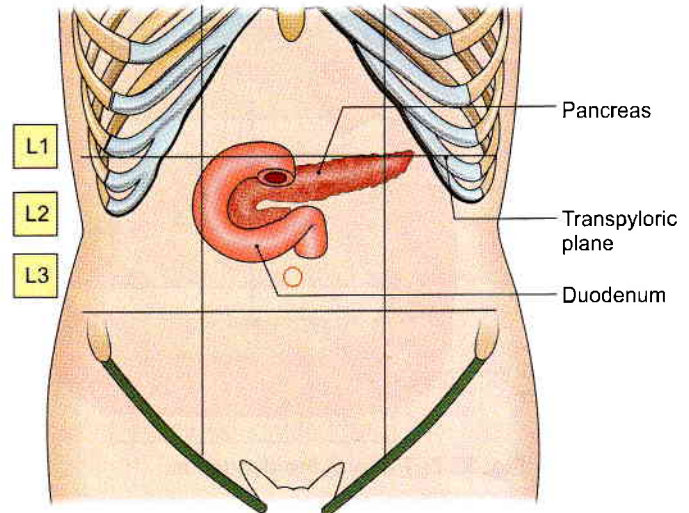


Fig. 20.5: Location of the duodenum

Definition and Location

The duodenum is the shortest, widest and most fixed part of the small intestine. It extends from the pylorus to duodenojejunal flexure. It is curved around the head of pancreas in the form of letter 'C'. The duodenum lies above the level of umbilicus, opposite first, second and third lumbar vertebrae.

Length and Parts

Duodenum is 25 cm long and is divided into the following four parts (Figs 20.6 and 20.7).

- 1 First or superior part, 5 cm or 2 inches long.
- 2 Second or descending part, 7.5 cm or 3 inches long.
- 3 Third or horizontal part, 10 cm or 4 inches long.
- 4 Fourth or ascending part, 2.5 cm or 1 inch long.

Peritoneal Relations

The duodenum is mostly retroperitoneal and fixed, except at its two ends where it is suspended by folds of peritoneum, and is, therefore, mobile. Anteriorly, the duodenum is only partly covered with peritoneum.

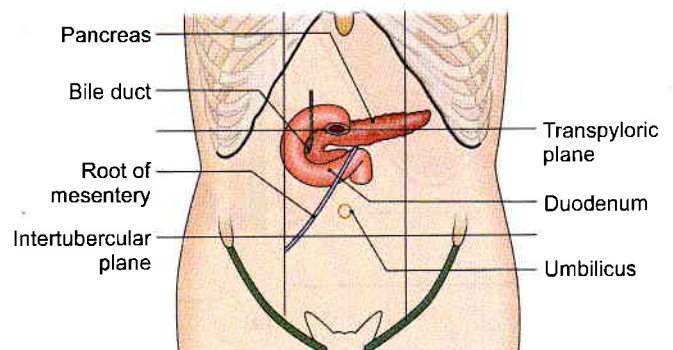


Fig. 20.6: Position of duodenum, pancreas, root of mesentery

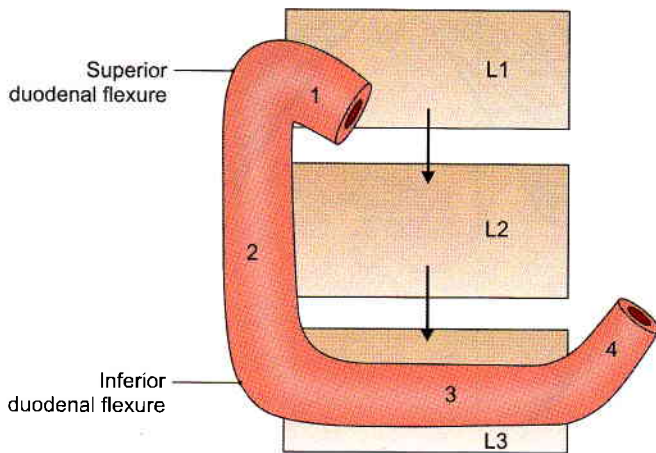


Fig. 20.7: Parts of the duodenum

First Part

The first part begins at the pylorus, and passes backwards, upwards and to the right to meet the second part at the superior duodenal flexure. Its relations are as follows.

Peritoneal Relations

- 1 The proximal 2.5 cm is movable. It is attached to the lesser omentum above, and to the greater omentum below (see Fig. 18.8).
- 2 The distal 2.5 cm is fixed. It is retroperitoneal. It is covered with peritoneum only on its anterior aspect.

Visceral Relations

Anteriorly: Quadrate lobe of liver, and gallbladder (Fig. 20.8a).

Posteriorly: Gastroduodenal artery, bile duct and portal vein (Fig. 20.8b).

Superiorly: Epiploic foramen (Fig. 20.8a).

Inferiorly: Head and neck of the pancreas.

Second Part

Course

This part is about 7.5 cm long. It begins at the superior duodenal flexure, passes downwards to reach the lower border of the third lumbar vertebra, where it curves towards the left at the inferior duodenal flexure, to become continuous with the third part. Its relations are as follows.

Peritoneal Relations

It is retroperitoneal and fixed. Its anterior surface is covered with peritoneum, except near the middle, where it is directly related to the colon.

Visceral Relations

Anteriorly

- 1 Right lobe of the liver
- 2 Transverse colon
- 3 Root of the transverse mesocolon
- 4 Small intestine (Fig. 20.9a).

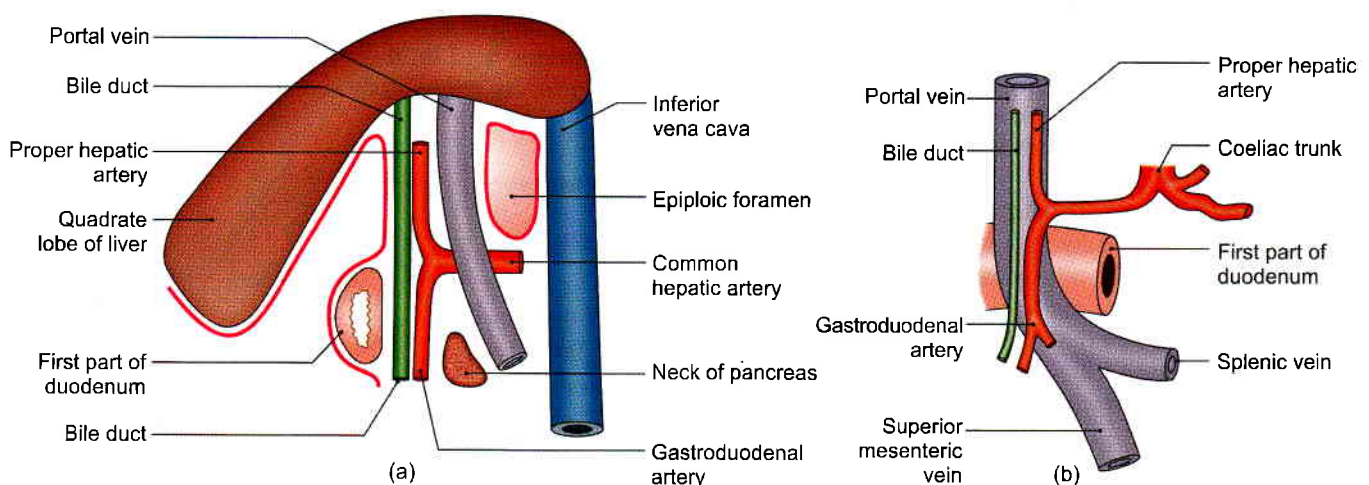
Posteriorly

- 1 Anterior surface of the right kidney near the medial border
- 2 Right renal vessels
- 3 Right edge of the inferior vena cava
- 4 Right psoas major (Fig. 20.9b).

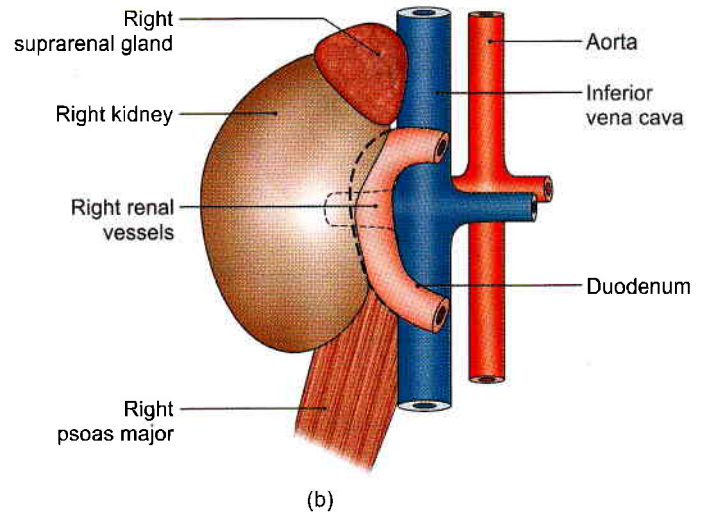
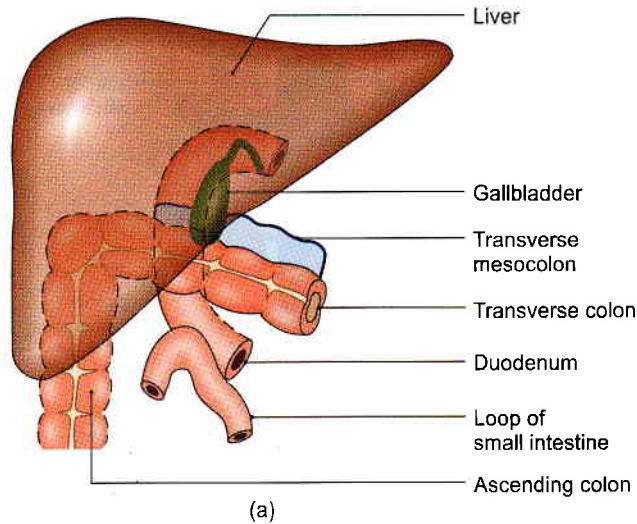
Medially

- 1 Head of the pancreas
- 2 The bile duct (Fig. 20.6).

Laterally: Right colic flexure (Fig. 20.9a).



Figs 20.8a and b: Relations of the first part of the duodenum: (a) Sagittal section viewed from the left side, and (b) posterior relations



Figs 20.9a and b: Relations of the second part of the duodenum: (a) Anterior relations, and (b) posterior relations

The interior of the second part of the duodenum shows the following special features.

- The *major duodenal papilla* is an elevation present posteromedially, 8 to 10 cm distal to the pylorus. The hepatopancreatic ampulla opens at the summit of the papilla.
- The *minor duodenal papilla* is present 6 to 8 cm distal to the pylorus, and presents the opening of the accessory pancreatic duct (see Fig. 23.16).
- Below major duodenal papilla, a longitudinal fold called *plica longitudinalis* is seen.

Third Part

Course

This part is about 10 cm long. It begins at the inferior duodenal flexure, on the right side of the lower border of the third lumbar vertebra. It passes almost horizontally and slightly upwards in front of the inferior vena cava, and ends by joining the fourth part in front of the abdominal aorta. Its relations (Fig. 20.10) are as follows.

Peritoneal Relations

It is retroperitoneal and fixed. Its anterior surface is covered with peritoneum, except in the median plane, where it is crossed by the superior mesenteric vessels and by the root of the mesentery.

Visceral Relations

Anteriorly

- 1 Superior mesenteric vessels
- 2 Root of mesentery (Fig. 20.10a).

Posteriorly

- 1 Right ureter
- 2 Right psoas major

- 3 Right testicular or ovarian vessels
- 4 Inferior vena cava
- 5 Abdominal aorta with origin of inferior mesenteric artery (Fig. 20.10b).

Superiorly: Head of the pancreas with uncinata process (Fig. 20.5).

Inferiorly: Coils of jejunum.

Fourth Part

Course

This part is 2.5 cm long. It runs upwards on or immediately to the left of the aorta, up to the upper border of the second lumbar vertebra, where it turns forwards to become continuous with the jejunum at the duodenojejunal flexure. Its relations are as follows.

Peritoneal Relations

It is mostly retroperitoneal, and covered with peritoneum only anteriorly. The terminal part is suspended by the uppermost part of the mesentery, and is mobile.

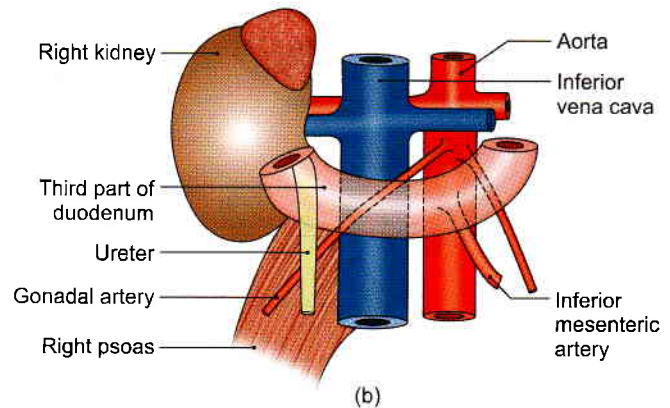
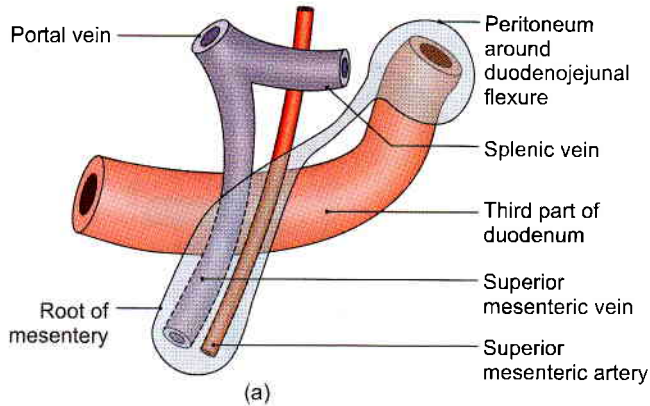
Visceral Relations

Anteriorly

- 1 Transverse colon,
- 2 Transverse mesocolon,
- 3 Lesser sac, and
- 4 Stomach.

Posteriorly

- 1 Left sympathetic chain,
- 2 Left renal artery,
- 3 Left gonadal artery, and
- 4 Inferior mesenteric vein (Fig. 20.11).



Figs 20.10a and b: Relations of the third part of the duodenum: (a) Anterior relations, and (b) posterior relations

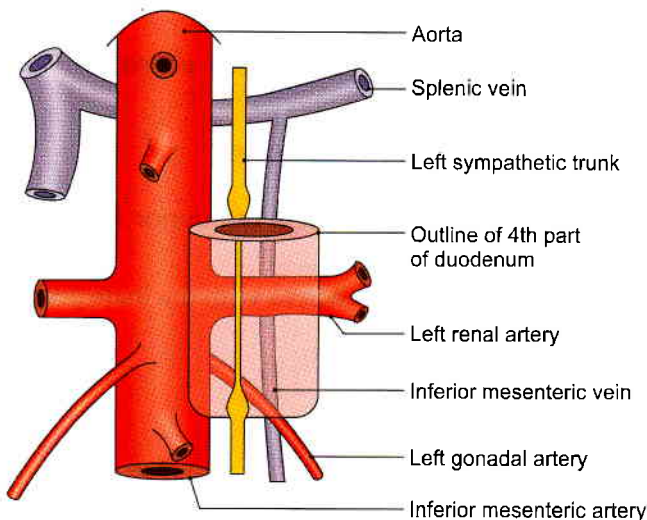


Fig. 20.11: Posterior relations of the fourth part of the duodenum

To the right: Attachment of the upper part of the root of the mesentery (Fig. 20.10).

To the left

- 1 Left kidney and
- 2 Left ureter.

Superiorly: Body of pancreas (Fig. 20.6).

SUSPENSORY MUSCLE OF DUODENUM OR LIGAMENT OF TREITZ

This is a fibromuscular band which suspends and supports the duodenojejunal flexure. It arises from the left crus of the diaphragm, close to the right side of the oesophagus, passes downwards behind the pancreas, and is attached to the posterior surface of the duodenojejunal flexure and the third and fourth parts of the duodenum (Fig. 20.12).

It is made up of:

- a. Striped muscle fibres in its upper part
- b. Elastic fibres in its middle part
- c. Plain muscle fibres in its lower part.

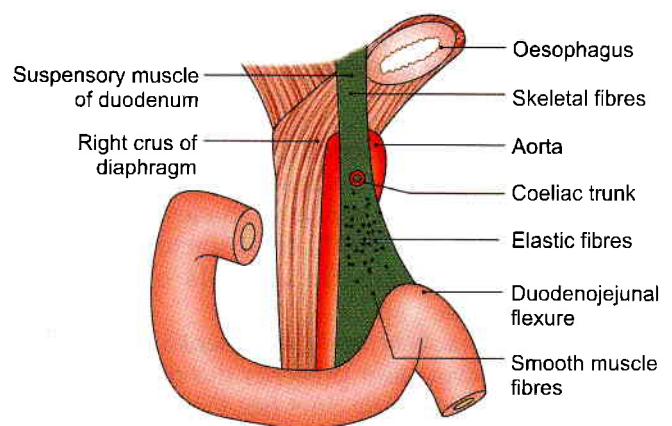


Fig. 20.12 Suspensory muscle of the duodenum

Normally its contraction increases the angle of the duodenojejunal flexure. Sometimes it is attached only to the flexure, and then its contraction may narrow the angle of the flexure, causing partial obstruction of the gut.

Arterial Supply

The duodenum develops partly from the foregut and partly from the midgut. The opening of the bile duct into the second part of the duodenum represents the junction of the foregut and the midgut. Up to the level of the opening, the duodenum is supplied by the *superior pancreaticoduodenal artery*, and below it by the *inferior pancreaticoduodenal artery* (Fig. 20.13).

The first part of the duodenum receives additional supply from:

- a. The right gastric artery.
- b. The supraduodenal artery of Wilkie, which is usually a branch of the common hepatic artery.
- c. The retroduodenal branches of the gastroduodenal artery.
- d. Some branches from the right gastroepiploic artery.

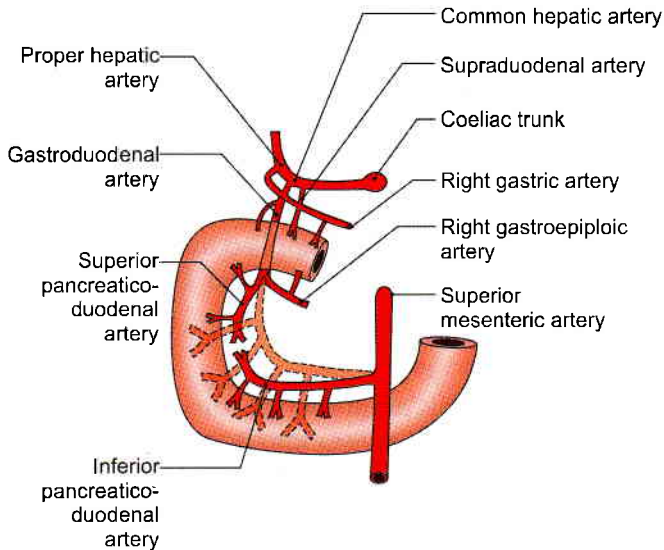


Fig. 20.13: Arterial supply of the duodenum

Venous Drainage

The veins of the duodenum drain into the splenic, superior mesenteric and portal veins.

Lymphatic Drainage

Most of the lymph vessels from the duodenum end in the *pancreaticoduodenal nodes* present along the inside of the curve of the duodenum, i.e. at the junction of the pancreas and the duodenum. From here the lymph passes partly to the *hepatic nodes*, and through them to the *coeliac nodes*; and partly to the superior mesenteric nodes and ultimately via *intestinal lymph trunk* into the *cisterna chyli*.

Some vessels from the first part of the duodenum drain into the pyloric nodes, and through them to the hepatic nodes. All the lymph reaching the hepatic nodes drains into the coeliac nodes.

Nerve Supply

Sympathetic nerves from thoracic ninth and tenth spinal segments and parasympathetic nerves from the vagus, pass through the coeliac plexus and reach the duodenum along its arteries.

HISTOLOGY

Mucous membrane: Shows evaginations in the form of *villi* and invaginations to form *crypts of Lieberkuhn*. Lining of villi is of columnar cells with microvilli. Muscularis mucosae comprises two layers.

Submucosa is full of mucus-secreting *Brunner's glands*.

The *muscularis externa* comprises outer longitudinal and inner circular layer of muscle fibres.

Outermost layer is mostly connective tissue.

CLINICAL ANATOMY

- In the skiagram taken after giving a barium meal, the first part of the duodenum is seen as a triangular shadow called the duodenal cap (Fig. 20.14).
- The first part of the duodenum is one of the commonest sites for peptic ulcer, possibly because of direct exposure of this part to the acidic contents reaching it from the stomach.
The patient is usually an over busy young person with a tense temperament. The ulcer pain located at the right half of epigastrium is relieved by meals and reappears on an empty stomach.
- The first part of duodenum is overlapped by the liver and gallbladder, either of which may become adherent to, or even ulcerated by a duodenal ulcer. Other clinically important relations of duodenum are the right kidney and transverse colon (Fig. 20.9).
- Duodenal diverticula are fairly frequent. They are seen along its concave border, generally at points where arteries enter the duodenal wall.
- Congenital stenosis and obstruction of the second part of the duodenum may occur at the site of the opening of the bile duct. Other causes of obstruction are:
 - a. An annular pancreas.
 - b. Pressure by the superior mesenteric artery (Fig. 20.15) on the third part of duodenum.
 - c. Contraction of the suspensory muscle of the duodenum (Fig. 20.12).
- Duodenal carcinoma

JEJUNUM AND ILEUM

DISSECTION

For examining the jejunum and ileum, tie a pair of ligatures around the jejunum close to the duodenojejunal flexure and a pair around the ileum close to the caecum. Cut through the small intestine between each pair of ligatures and remove it by dividing the mesentery close to the intestine.

Wash intestine with running tap water. Remove 10 cm each of jejunum and ileum and open it longitudinally. Remove the peritoneal coat to expose the longitudinal muscle layer.

Identify villi with a hand lens. Remove only the mucous membrane and submucosa to see the underlying circular muscle coat. Examine the differences between jejunum and ileum.

Features

The jejunum and ileum are suspended from the posterior abdominal wall by the mesentery and,

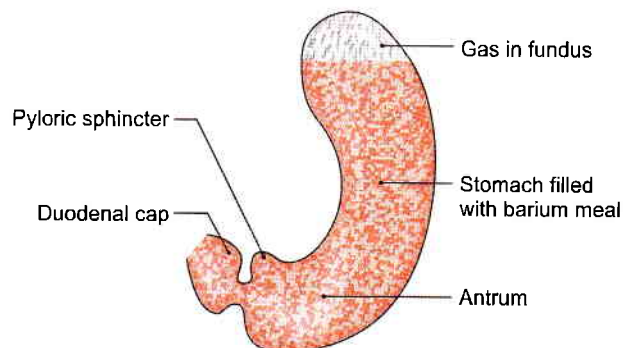


Fig. 20.14: Line drawing of radiograph of the stomach after barium meal

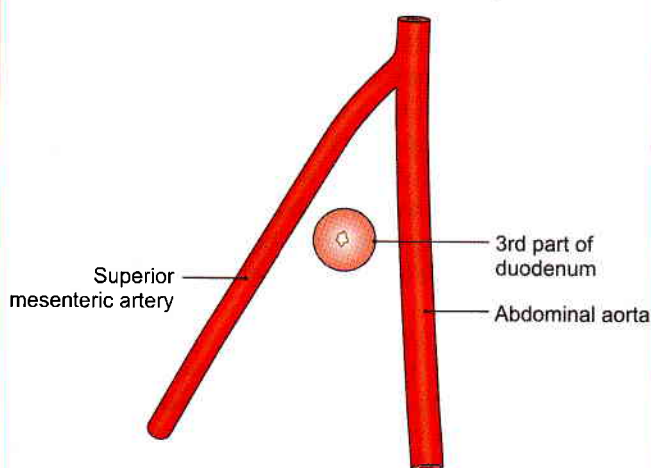


Fig. 20.15: Obstruction of third part of the duodenum between the two arteries

therefore, enjoy considerable mobility. The jejunum constitutes the upper two-fifths of the mobile part of the small intestine, while the ileum constitutes the lower three-fifths. The jejunum begins at the duodenojejunal

flexure. The ileum terminates at the ileocaecal junction. The structure and functions of the jejunum and ileum correspond to the general description of the small intestine. The differences between the jejunum and the ileum are given in Table 20.1.

Blood Supply

The jejunum and ileum are supplied by branches from the superior mesenteric artery, and are drained by corresponding veins.

Lymphatic Drainage

Lymph from lacteals drains into plexuses in the wall of the gut. From there it passes into lymphatic vessels in the mesentery. Passing through numerous lymph nodes present in the mesentery, and along the superior mesenteric artery, it ultimately drains into nodes present in front of the aorta at the origin of the superior mesenteric artery.

Nerve Supply

Sympathetic nerves are from T9–T11 segments and parasympathetic is from vagus.

HISTOLOGY

Jejunum

The *villi* here are tongue-shaped. No mucous glands or aggregated lymphoid follicles are present in the *submucosa*. *Muscularis externa* is same as in duodenum. Outermost is the serous layer.

Ileum

The *villi* are few, thin and finger-like. Collection of lymphocytes in the form of *Peyer's patches* in lamina propria extending into submucosa is a characteristic feature.

Rest is same as above.

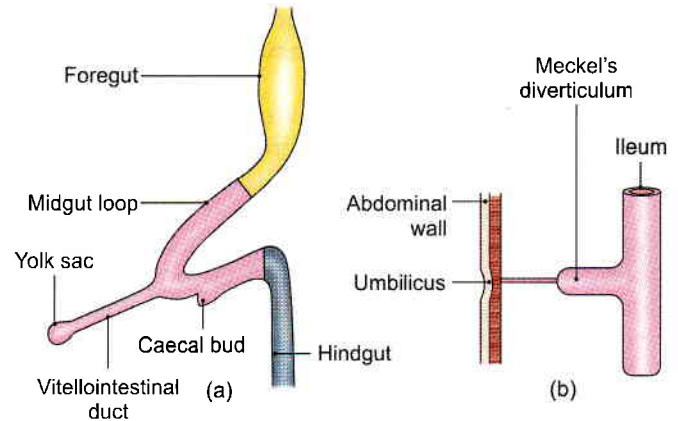
Table 20.1: Differences between jejunum and ileum

Feature	Jejunum	Ileum
1. Location	Occupies upper and left parts of the intestinal area	Occupies lower and right parts of the intestinal area
2. Walls	Thicker and more vascular	Thinner and less vascular
3. Lumen	Wider and often empty	Narrower and often loaded
4. Mesentery	a. Windows present b. Fat less abundant c. Arterial arcades, 1 or 2 d. Vasa recta longer and fewer	a. No windows b. Fat more abundant c. Arterial arcades, 3 or 6 d. Vasa recta shorter and more numerous
5. Circular mucosal folds	Larger and more closely set	Smaller and sparse
6. Villi	Large, thick (leaf-like) and more abundant	Shorter, thinner (finger-like) and less abundant
7. Peyer's patches	Absent	Present
8. Solitary lymphatic follicles	Fewer	More numerous

**MECKEL'S DIVERTICULUM (DIVERTICULUM ILEI)**

Meckel's diverticulum is the persistent proximal part of the vitellointestinal duct which is present in the embryo, and which normally disappears during the 6th week of intrauterine life. Some points of interest about it are as follows (Figs 20.16a and b).

- 1 It occurs in 2% subjects.
- 2 Usually it is 2 inches or 5 cm long.
- 3 It is situated about 2 feet or 60 cm proximal to the ileocaecal valve, attached to antimesenteric border of the ileum.
- 4 Its calibre is equal to that of the ileum.
- 5 Its apex may be free or may be attached to the umbilicus, to the mesentery, or to any other abdominal structure by a fibrous band.



Figs 20.16a and b: Meckel's diverticulum: (a) Vitellointestinal duct in an early embryo, and (b) Meckel's diverticulum, the proximal persistent part of the vitellointestinal duct

CLINICAL ANATOMY

- Meckel's diverticulum may cause intestinal obstruction (Figs 20.16a and b).
- Occasionally it may have small regions of gastric mucosa.
- Acute inflammation of the diverticulum may produce symptoms that resemble those of appendicitis.
- It may be involved in other diseases similar to those of the intestine.

LARGE INTESTINE**DISSECTION**

Locate the various parts of large intestine, beginning from caecum, vermiform appendix, ascending, transverse, descending and sigmoid colons and ending with the rectum and anal canal. Identify the taenia, haustration and appendices epiploicae. Trace the taenia from the root of the vermiform appendix through the ascending to the transverse colon and note the change in their respective positions.

Features

The large intestine extends from the ileocaecal junction to the anus. It is about blind 1.5 m long, and is divided into the caecum, (Latin *blind pouch*), the ascending colon, right colic flexure, the transverse colon, left colic flexure, the descending colon, the sigmoid colon, the rectum and the anal canal. In the angle between the caecum and the terminal part of the ileum there is a narrow diverticulum called the vermiform appendix (Latin *attachment*) (Fig. 20.17).

The general structure of large intestine is considered first followed by its parts one by one.

The structure of the large intestine is adapted for storage of matter reaching it from the small intestines,

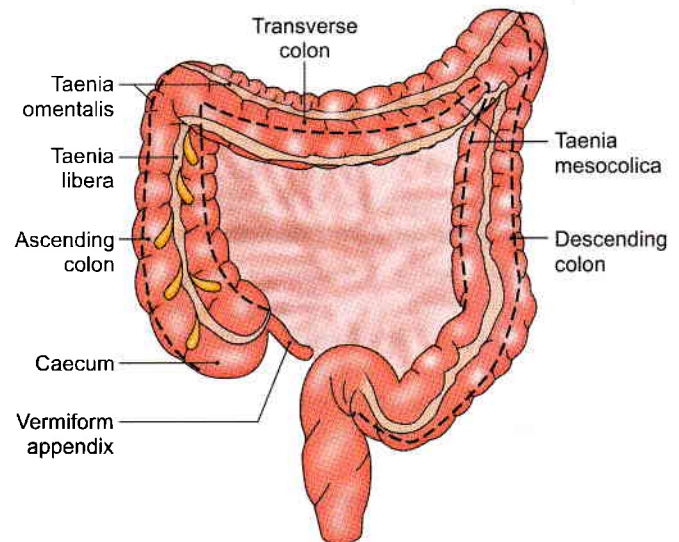


Fig. 20.17: Large intestine and the position of three taenia

and for absorption of fluid and solutes from it. The epithelium is absorptive (columnar), but *villi are absent*. Adequate lubrication for passage of its contents is provided by numerous goblet cells scattered in the crypts as well as on the surface of the mucous membrane. The presence of numerous solitary lymphatic follicles provides protection against bacteria present in the lumen of the intestine.

Relevant Features

The relevant features of the large intestine are as follows:

- 1 The large intestine is *wider in calibre* than the small intestine. The calibre is greatest at its commencement, and gradually diminishes towards the rectum where it is dilated to form the rectal ampulla just above the anal canal.



- 2 The greater part of the large intestine is *fixed*, except for the appendix, the transverse colon and the sigmoid colon.
- 3 The longitudinal muscle coat forms only a thin layer in this part of the gut. The greater part of it forms three ribbon-like bands, called the *taeniae coli*. Proximally the taeniae converge at the base of the appendix, and distally they spread out on the terminal part of the sigmoid colon to become continuous with the longitudinal muscle coat of the rectum. In the caecum, the ascending colon, the descending colon and sigmoid colon and sigmoid colon the positions of taeniae are anterior or taenia libera; posteromedial or taenia mesocolica and posterolateral or taenia omentalis but in the transverse colon the corresponding positions of taenia are inferior, posterior and superior.

One taenia, *taenia libera*, is placed anteriorly in the caecum, ascending, descending and sigmoid colon, but is placed inferiorly in the transverse colon.

Second taenia, *taenia mesocolica* is present on the posteromedial surface of caecum, ascending, descending and sigmoid colon, but is placed posteriorly on transverse colon at the site of attachment of the transverse mesocolon (Fig. 20.17).

Third taenia, *taenia omentalis*, is situated posterolaterally in caecum, ascending, descending and sigmoid colon, but is situated on the anterosuperior surface of transverse colon where layers three and four of greater omentum meet the transverse colon. This change in position is due to twist in transverse colon.

- 4 Since the taeniae are shorter than the circular muscle coat, the colon is *puckered* and *sacculated*.
- 5 Small bags of peritoneum filled with fat, and called the *appendices epiploicae*, (Greek *to float on*) are scattered

over the surface of the large intestine, except for the appendix, the caecum and the rectum. These are most numerous on the sides of the sigmoid colon and on the posterior surface of the transverse colon.

The differences between the small and large intestine are summarised in Table 20.2.

- 6 The *blood supply* to the colon is derived from the marginal artery of Drummond. It is formed by colic branches of superior and inferior mesenteric arteries (see Fig. 21.11). Terminal branches from the marginal artery are distributed to the intestine as long and short vessels, *vasa longa* and *vasa brevia*. The long arteries divide into anterior and posterior branches close to the mesocolic taenia to pass between the serous and muscular coats and reach the amesocolic taeniae. They gradually pierce the muscular coat and reach the submucosa. The anastomosis between the two amesocolic taeniae is extremely poor. So longitudinal incisions should be made along this line.

Short branches arise either from the marginal artery or from the long branches, and the majority of them at once sink into the bowel wall at the mesocolic border. The short and long branches together thus provide the mesocolic region of the wall with abundant blood supply. It is only the amesocolic region which has scanty blood supply.

Subserous coat of long branches is intimately related to appendices epiploicae, to which they contribute branches. During removal of these appendages care must be taken not to pull on them in order to avoid traction on the subjacent vessel.

Bowel wall is weakened where it is pierced by the vessels and at the sites of attachment of appendices epiploicae. Mucosa may herniate in these situations

Table 20.2: Differences between the small intestine and the large intestine

Feature	Small intestine	Large intestine
1. Appendices epiploicae	Absent	Present
2. Taeniae coli	Absent	Present
3. Sacculations	Absent	Present
4. Distensibility and diameter	Less distensibility and less diameter	More distensibility and more diameter
5. Fixity	Greater part is freely mobile	Greater part is fixed
6. Villi	Present	Absent
7. Transverse mucosal folds	Permanent	Obliterated when longitudinal muscle coat relaxes
8. Peyer's patches	Present in ileum	Absent
9. Common site for	a. Intestinal worms b. Typhoid c. Tuberculosis	a. <i>Entamoeba histolytica</i> b. Dysentery organisms c. Carcinoma
10. Effects of infection and irritation	Diarrhoea	Dysentery (Greek <i>bad intestine</i>)



causing diverticulosis, with associated dangers of diverticulitis, fibrosis and stricture.

- 7 Lymph from the large intestine passes through four sets of lymph nodes.
 - a. *Epicolic lymph nodes*, lying on the wall of the gut (Fig. 20.26).
 - b. *Paracolic nodes*, on the medial side of the ascending and descending colon and near the mesocolic border of the transverse and sigmoid colon.
 - c. *Intermediate nodes*, on the main branches of the vessels.
 - d. *Terminal nodes*, on the superior and inferior mesenteric vessels.

In carcinoma of the colon, the related paracolic and intermediate lymph nodes have to be removed. Their removal is possible only after the ligation of the main branch of the superior or inferior mesenteric artery along which the involved lymph nodes lie. It is necessary, therefore, to remove a large segment of the bowel than is actually required by the extent of the disease, in order to avoid gangrene as a result of interference with the blood supply. It is always wise to remove the whole portion of the bowel supplied by the ligated vessel.

- 8 The *nerve supply* of the large intestine, barring the lower half of the anal canal, is both sympathetic and parasympathetic. The midgut territory receives its sympathetic supply from the coeliac and superior mesenteric ganglia (T11 to L1), and its parasympathetic supply from the vagus. Both types of nerves are distributed to the gut through the superior mesenteric plexus.

The hindgut territory receives its sympathetic supply from the lumbar sympathetic chain (L1, L2), and its parasympathetic supply from the pelvic splanchnic nerve (*nervei erigentes*), both via the superior hypogastric and inferior mesenteric plexuses. Some parasympathetic fibres reach the colon along the posterior abdominal wall. The ultimate distribution of nerves in the gut is similar to that in the wall of the small intestine.

The parasympathetic nerves are motor to the large intestine and inhibitory to the internal anal sphincter. The sympathetic nerves are largely vasomotor, but also motor to the internal anal sphincter, and inhibitory to colon. Pain impulses from the gut up to the descending colon travel through the sympathetic nerves, and from the sigmoid colon and rectum through the pelvic splanchnic nerves.

Functions of Colon

The functions of the colon are as follows.

- 1 Lubrication of faeces by mucus.
- 2 Absorption of the water, salts and the other solutes.
- 3 Bacterial flora of colon synthesises vitamin B.

- 4 Mucoid secretion of colon is rich in antibodies of IgA group, which protect it from invasion by micro-organisms.
- 5 The microvilli (apical tufts) of some columnar cells serve a sensory function.

CLINICAL ANATOMY

- Large intestine can be directly viewed by a procedure called *colonoscopy*.
- Diverticulum is a small evagination of mucous membrane of colon at the entry point of the arteries. Its inflammation is called diverticulitis (Fig. 20.18).

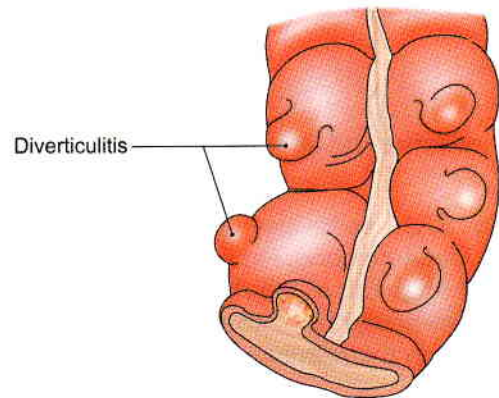


Fig. 20.18: Diverticulitis

CAECUM

DISSECTION

Turn the caecum upwards and identify its posterior relations.

Incise the lateral wall of the caecum and locate the ileocaecal orifice and its associated valve. Below the ileocaecal valve identify the orifice of the vermiform appendix.

Features

Caecum is a large blind sac (Latin *blind*) forming the commencement of the large intestine. It is situated in the right iliac fossa, above the lateral half of inguinal ligament. It communicates superiorly with ascending colon, medially at the level of caecocolic junction with ileum, and posteromedially with the appendix (Fig. 20.19).

Dimensions

It is 6 cm long and 7.5 cm broad. It is one of those organs of the body that have greater width than the length. The other examples are the prostate, pons and pituitary.

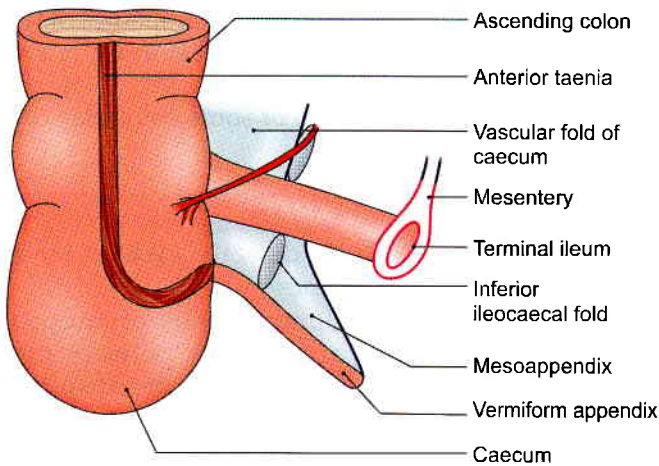


Fig. 20.19: Anterior view of the ileocaecal region

Relations

Anterior

Coils of intestine and anterior abdominal wall.

Posterior

- 1 **Muscles:** Right psoas and iliacus (Fig. 20.20).
- 2 **Nerves:** Genitofemoral, femoral and lateral cutaneous nerve of thigh (all of the right side).
- 3 **Vessels:** Testicular or ovarian.
- 4 Appendix in the retrocaecal recess.

Vessels and Nerves

The arterial supply of the caecum is derived from the caecal branches of the ileocolic artery. The veins drain into the superior mesenteric vein. The nerve supply is

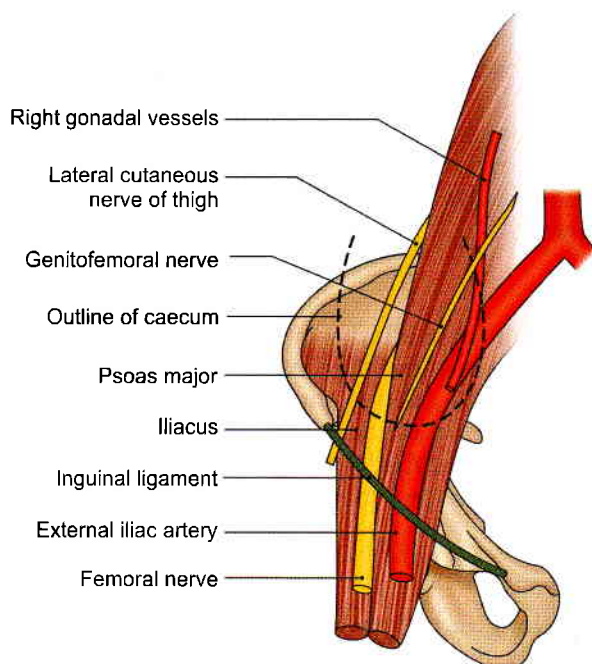


Fig. 20.20: Relations of caecum

same as that of the midgut (thoracic 11 to lumbar 1; parasympathetic, vagus).

DEVELOPMENT

The caecum and appendix develop from the caecal bud arising from the *postarterial segment* of the midgut loop. The proximal part of the bud dilates to form the caecum. The distal part remains narrow to form the appendix. Thus initially the appendix arises from the apex of the caecum. However, due to rapid growth of the lateral wall of the caecum, the attachment of the appendix shifts medially (Fig. 20.21).

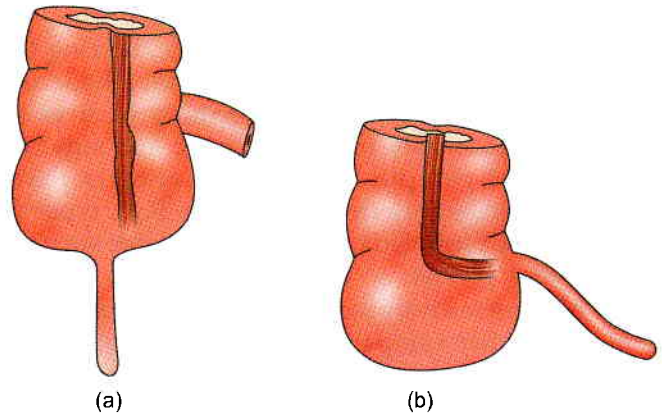
ILEOCAECAL VALVE

The lower end of the ileum opens on the posteromedial aspect of the caecocolic junction. The ileocaecal opening is guarded by the ileocaecal valve (Fig. 20.22).

Structure

The valve has two lips and two frenula.

- 1 The *upper lip* is horizontal and lies at the ileocolic junction.



Figs 20.21a and b: Development of the caecum: (a) Early stage, and (b) later stage

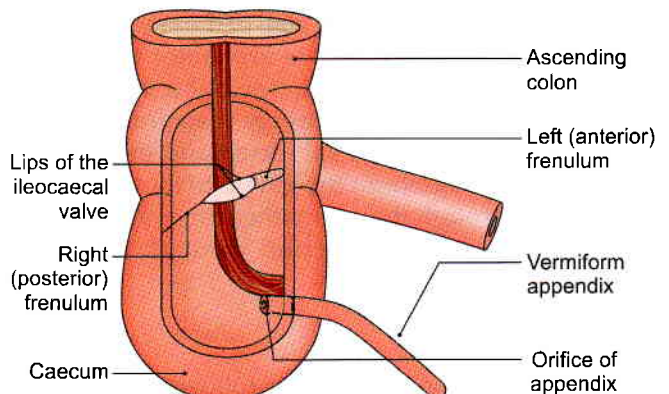


Fig. 20.22: The ileocaecal valve seen after removal of the anterior walls of the caecum and of the lower part of the ascending colon



2 The *lower lip* is longer and concave, and lies at the ileocaecal junction.

The two *frenula* are formed by the fusion of the lips at the ends of the aperture. These are the left or anterior and the right or posterior frenula. The left end of the aperture is rounded, and the right end narrow and pointed.

Control and Mechanism

- 1 The valve is actively closed by sympathetic nerves, which cause tonic contraction of the ileocaecal sphincter.
- 2 It is mechanically closed by distension of the caecum.

Functions

- 1 It prevents reflux from caecum to ileum.
- 2 It regulates the passage of ileal contents into the caecum, and prevents them from passing too quickly.

CLINICAL ANATOMY

- Caecum is commonly involved in:
 - a. Amoebiasis, causing amoebic dysentery.
 - b. Intestinal tuberculosis (ileocaecal tuberculosis) and carcinoma.
 - c. Inflammation of caecum is known as caecitis or typhlitis.

VERMIFORM APPENDIX

This is a worm-like diverticulum arising from the posteromedial wall, of the caecum, about 2 cm below the ileocaecal orifice (Fig. 20.22).

Dimensions

The length varies from 2 to 20 cm with an average of 9 cm. It is longer in children than in adults. The diameter is about 5 mm. The lumen is quite narrow and may be obliterated after mid-adult life.

Positions

The appendix lies in the right iliac fossa. Although the base of the appendix is fixed, the tip can point in any direction, as described below. The positions are often compared to those of the hour hand of a clock (Figs 20.23 and 20.24).

- 1 The appendix may pass upwards and to the right. This is paracolic or 11 o'clock position.
- 2 It may lie behind the caecum or colon, known as retrocaecal or 12 o'clock position. This is the commonest position of appendix, about 65%.
- 3 The appendix may pass upwards and to the left. It points towards the spleen. This is the splenic or 2 o'clock position. The appendix may lie in front of the ileum (preileal) or behind the ileum (postileal). The postileal type is most dangerous type.
- 4 It may pass horizontally to the left (as if pointing to the sacral promontory called promontoric or 3 o'clock position.
- 5 It may descend into the pelvis called pelvic or 4 o'clock position. This is the second most common position about 30%.
- 6 It may lie below the caecum (subcaecal) and may point towards the inguinal ligament called as midinguinal or 6 o'clock position.

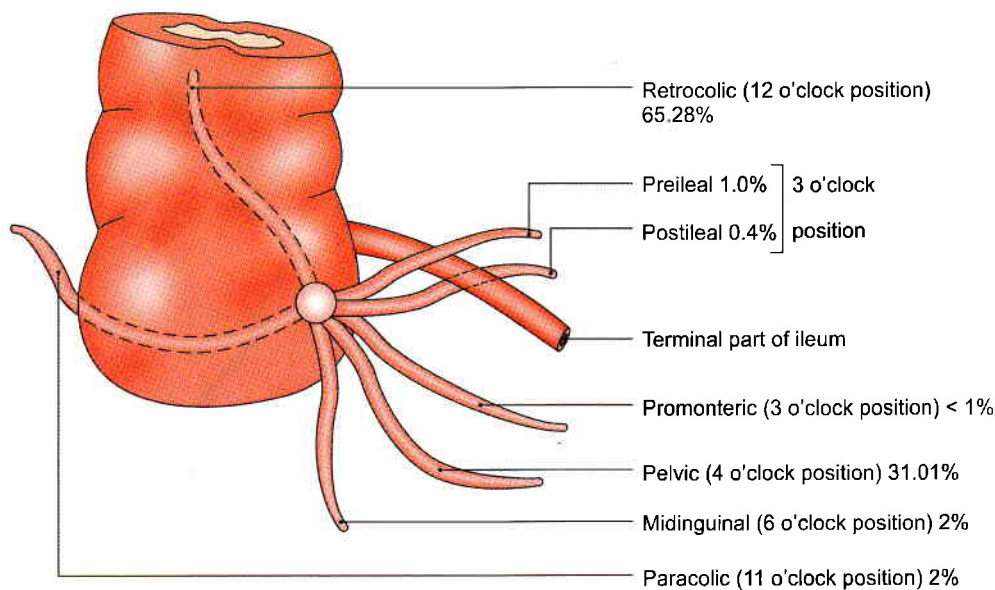


Fig. 20.23: Positions of the appendix

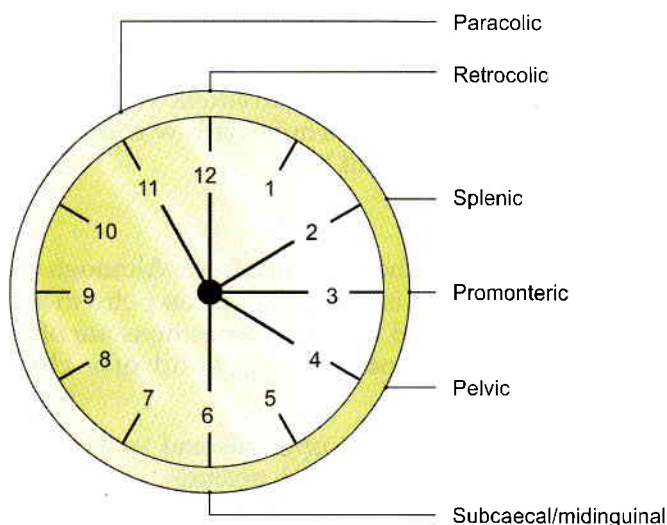


Fig. 20.24: Positions of the appendix according to the clock

Appendicular Orifice

- 1 The appendicular orifice situated on the postero-medial aspect of the caecum 2 cm below the ileocaecal orifice.
- 2 The appendicular orifice is occasionally guarded by an indistinct semilunar fold of the mucous membrane, known as the *valve of Gerlach*.
- 3 The orifice is marked on the surface by a point situated 2 cm below the junction of transtuberular and right lateral planes (Fig. 20.25a).
- 4 McBurney's point is the site of maximum tenderness in appendicitis. The point lies at the junction of lateral one-third and medial two-thirds of line joining the right anterior superior iliac spine to umbilicus (Fig. 20.25b).

Lumen of Appendix

It is quite small and may be partially or completely obliterated after mid-adult life.

Peritoneal Relations

The appendix is suspended by a small, triangular fold of peritoneum, called the mesoappendix, or appendicular mesentery. The fold passes upwards behind the ileum, and is attached to the left layer of the mesentery (Fig. 20.19).

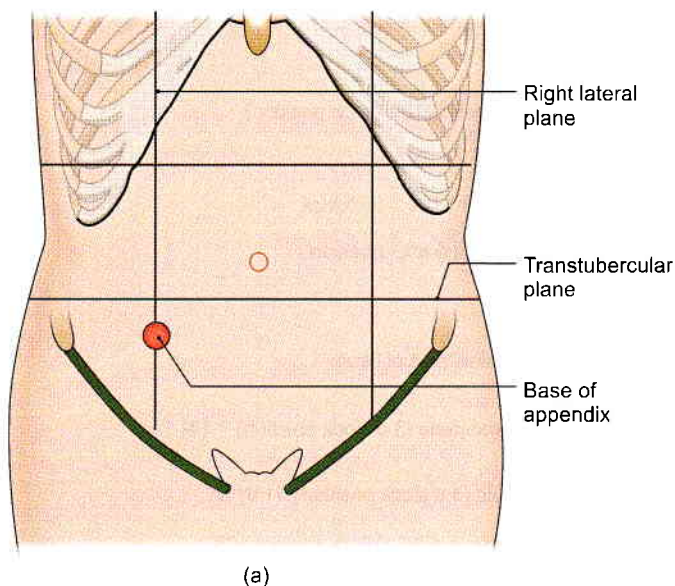
Blood Supply

The appendicular artery is a branch of the lower division of the ileocolic artery. It runs behind the terminal part of the ileum and enters the mesoappendix at a short distance from its base. Here it gives a recurrent branch which anastomoses with a branch of the posterior caecal artery. The main artery runs towards the tip of the appendix lying at first near to and then in the free border of the mesoappendix. The terminal part of the artery lies actually on the wall of the appendix (Fig. 20.26).

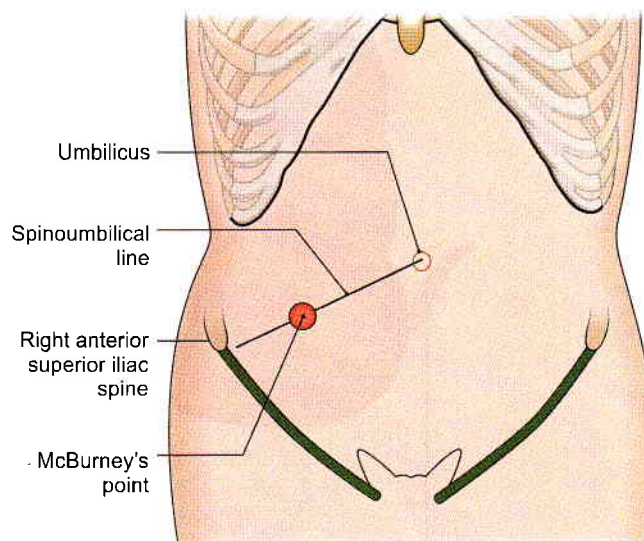
Blood from the appendix is drained by the appendicular, ileocolic and superior mesenteric veins, to the portal vein.

Nerve Supply

Sympathetic nerves are derived from thoracic nine and ten segments through the coeliac plexus. Parasympathetic nerves are derived from the vagus. Referred pain of appendix is felt at umbilicus, similar to that of small intestine and testis.



(a)



(b)

Figs 20.25a and b: Position of the appendix: (a) The base of the appendix is marked by a point 2 cm below the junction of the transtuberular and right lateral planes, and (b) McBurney's point is the site of maximum tenderness in acute appendicitis

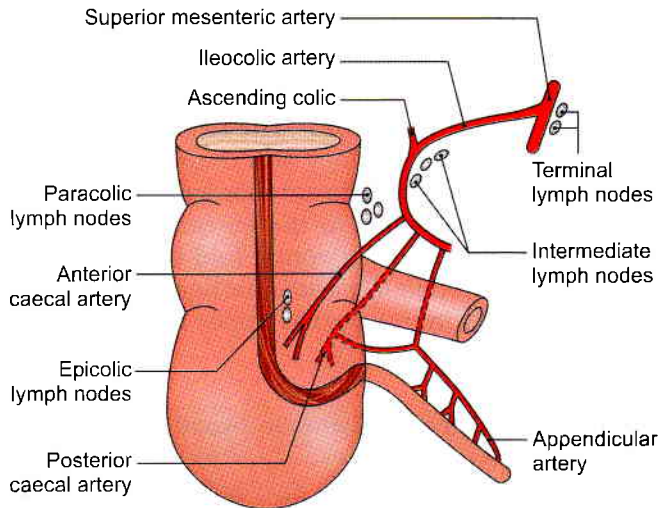
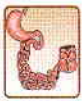

Fig. 20.26: Arterial supply of caecum and appendix. Various groups of lymph nodes are also seen

Lymphatic Drainage

Most of the lymphatics pass directly to the ileocolic nodes, but a few of them pass indirectly through the appendicular nodes situated in the mesoappendix.

HISTOLOGY

The lumen of appendix is very narrow. There are *no villi*. The epithelium invaginates to form crypts of Lieberkuhn. Muscularis mucosae is ill defined.

Submucosa reveals many lymphoid masses. That is why it is called the *abdominal tonsil*. *Muscularis externa* comprises two layers. Outermost is the serous layer.

CLINICAL ANATOMY

- Inflammation of the appendix is known as appendicitis seen in adolescent age. In this condition, it is usually necessary to remove the appendix. The operation for removal of the appendix is called *appendicectomy*. Some anatomical facts relevant to the diagnosis and treatment of appendicitis are as follows.
- Pain caused by appendicitis is first felt in the region of the umbilicus. This is referred pain. Note the fact that both the appendix and the umbilicus are innervated by segment T10 of the spinal cord; appendix by sympathetic fibres and umbilicus by somatic fibres. With increasing inflammation pain is felt in the right iliac fossa. This is caused by involvement of the parietal peritoneum of the region (remember that parietal peritoneum is sensitive to pain, but visceral peritoneum is not): Appendicitis is common because:
 - i. Presence of lymphatic follicles in submucosa.
 - ii. Appendicular artery is an end artery.

- iii. As the lumen is small it gets obstructed by faecolith.
- iv. Gaps in muscularis is external cause fast spread of infection.

- *McBurney's point* is the site of maximum tenderness in appendicitis. The point lies at the junction of the lateral one-third and the medial two-thirds of the line joining the umbilicus to the right anterior superior iliac spine. It corresponds, roughly, to the position of the base of the appendix (Fig. 20.27). Examination of a case of acute appendicitis reveals following physical signs.

- a. Hyperaesthesia in the right iliac fossa
 - b. Tenderness at McBurney's point
 - c. Muscle guard and rebound tenderness over the appendix.
- When the appendix is retrocaecal, extension of the hip joint may cause pain because the appendix is disturbed by stretching of the psoas major muscle.
 - In pelvic appendicitis pain may be felt when the thigh is flexed and medially rotated, because the obturator internus is stretched.
 - *Appendicular dyspepsia*: Chronic appendicitis produces dyspepsia resembling disease of stomach, duodenum or gallbladder. It is due to passage of infected lymph to the subpyloric nodes which cause irritation of pylorus. There is history of earlier acute appendicitis.

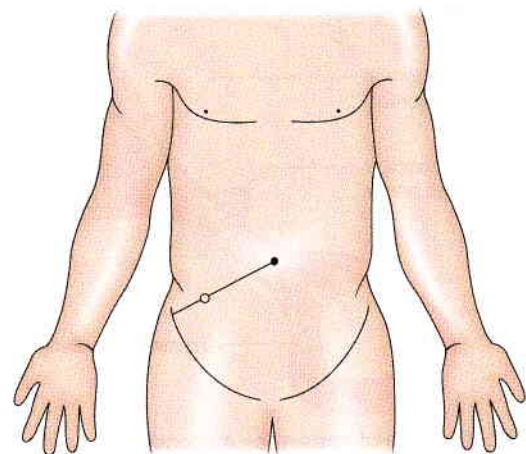


Fig. 20.27: Site of McBurney's point

ASCENDING COLON

Ascending colon is about 12.5 cm long and extends from the caecum to the inferior surface of the right lobe of the liver. Here it bends to the left to form the right colic flexure. It is covered by peritoneum on three sides.



Anteriorly, it is related to the coils of small intestine, the right edge of the greater omentum, and the anterior abdominal wall. *Posteriorly*, it is related to the iliacus, the quadratus lumborum, the transversus abdominis, the lateral cutaneous, ilioinguinal, and iliohypogastric nerves and the right kidney.

RIGHT COLIC FLEXURE (HEPATIC FLEXURE)

Right colic flexure lies at the junction of the ascending colon and transverse colon. Here the colon bends forwards, downwards and to the left. The flexure lies on the lower part of right kidney. Anterosuperiorly, it is related to the colic impression on inferior surface of the right lobe of liver (Fig. 20.9a).

TRANSVERSE COLON

Transverse colon is about 50 cm long and extend across the abdomen from the right colic flexure to the left colic flexure. Actually it is not transverse, but hangs low as a loop to a variable extent. It is suspended by the transverse mesocolon attached to the anterior border of pancreas, and has a wide range of mobility (Fig. 20.28).

Anteriorly, it is related to the greater omentum and to the anterior abdominal wall. *Posteriorly*, it is related to the second part of the duodenum, the head of the pancreas, and to coils of small intestine (Table 20.3).

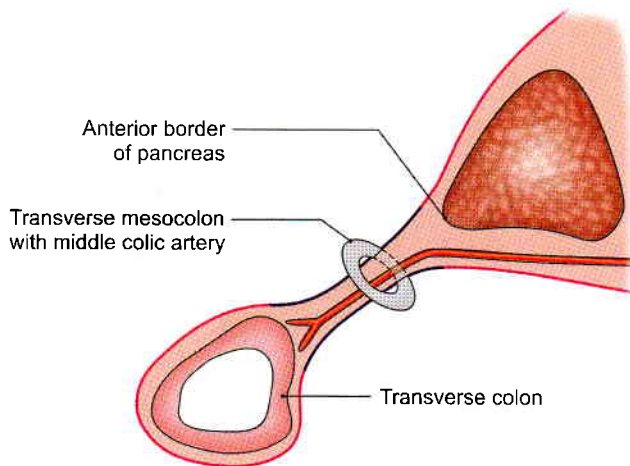


Fig. 20.28: Relation of transverse mesocolon to anterior border of pancreas

Table 20.3: The comparison between right two-thirds and left one-third of transverse colon

	<i>Right two-thirds of transverse colon</i>	<i>Left one-third of transverse colon</i>
Position	Descending till umbilicus	Ascending to left hypochondrium
Arterial supply	Middle colic branch of superior mesenteric artery	Ascending branch of left colic artery
Nerve supply and development	Branches of vagus, as it develops from midgut	Branches of pelvic splanchnic, S2, S3, S4, as it develops from hindgut.

LEFT COLIC FLEXURE (SPLENIC FLEXURE)

Left colic flexure lies at the junction of the transverse colon and the descending colon. Here the colon bends downwards, and backwards. The flexure lies on the lower part of the left kidney and diaphragm, behind the stomach, and below the anterior end of the spleen. The flexure is attached to the eleventh rib (in the midaxillary line) by a horizontal fold of peritoneum, called the *phrenicocolic ligament*. This ligament supports the spleen and forms a partial upper limit of the left paracolic gutter (Table 20.4).

Table 20.4: Differences between hepatic flexure and splenic flexure

<i>Hepatic flexure</i>	<i>Splenic flexure</i>
Placed anteriorly on right side	Placed posteriorly on left side
Right angle	Acute angle
Lies on right kidney	Lies on spleen
Supplied by right colic artery	Supplied by left colic artery
No ligament is attached	Phrenicocolic ligament is attached
Lies at level of L2 vertebra	Lies at level of T12 vertebra

DESCENDING COLON

Descending colon is about 25 cm long and extends from the left colic flexure to the sigmoid colon. It runs vertically up to the iliac crest, and then inclines medially on the iliacus and psoas major to reach the pelvic brim, where it is continuous with the sigmoid colon. The descending colon is narrower than the ascending colon.

Anteriorly, it is related to the coils of small intestine. *Posteriorly*, it is related to the transversus abdominis, the quadratus lumborum, the iliacus and psoas muscles; the iliohypogastric, ilioinguinal, lateral cutaneous, femoral and genitofemoral nerves; the gonadal and external iliac vessels.

SIGMOID COLON (PELVIC COLON)

Sigmoid colon is about 37.5 cm long, and extends from the pelvic brim to the third piece of the sacrum, where



it becomes the rectum. It forms a sinuous loop, and hangs down in pelvis over the bladder and uterus. Occasionally, it is very short, and takes a straight course. It is suspended by the sigmoid mesocolon and is covered by coils of small intestine.

The rectum and the anal canal are described later.

HISTOLOGY OF COLON

Mucous Membrane

It shows only invagination to form deep crypts of Lieberkuhn. Lining epithelium is of columnar cells with intervening goblet cells. Muscularis mucosae is well defined.

Submucosa

Contains solitary lymphoid follicles with the Meissner's plexus of nerves.

Muscularis Externa

Outer longitudinal coat is thickened at three places to form taenia coli. Inner coat is of circular fibres. Outermost layer is serous/adventitia.

DEVELOPMENT

Duodenum

During rotation of stomach, the C-shaped duodenum falls to the right. At the same time it lies against posterior abdominal wall and gets retroperitoneal. Duodenum develops partly from foregut and partly from midgut. Till the origin of hepatic bud it develops from foregut, i.e. first and upper half of second part. The remaining two and a half parts arise from midgut.

Duodenum is supplied both by branches of coeliac axis (artery of foregut) and by branches of superior mesenteric artery (artery of midgut).

Midgut

It gives rise to the part of duodenum distal to the opening of bile duct, jejunum, ileum, caecum, vermiform appendix, ascending colon, hepatic flexure and right two-thirds of transverse colon.

Midgut is in the form of primary intestinal loop. At the apex of the loop it is connected to the yolk sac and grows very rapidly during 6th week, so much so that it protrudes into the umbilical cord. This is called *physiological herniation*. After an interval of 4 weeks, i.e. at 10th week it returns back into the enlarged abdominal cavity. During this herniation and return the midgut loop rotates by 270° in a counter clockwise direction.

Hindgut

Its cranial part gives rise to left one-third of transverse colon, descending colon, pelvic colon, proximal part of

rectum. The distal part of hindgut is dilated to form the cloaca, which gets separated by urorectal septum into a posterior part—the anorectal canal and an anterior part—the primitive urogenital sinus. The anorectal canal forms distal part of rectum and proximal part of anal canal. Distal part of anal canal is formed from an invagination of surface ectoderm called the proctodeum.

Mnemonics

Meckel's diverticulum details

(Note: "di-" means "two", so *diverticulum* is the thing with all the twos.)

- 2 inches long
- 2 feet from end of ileum
- 2 times more common in men
- 2% occurrence in population
- 2 types of tissues may be present



FACTS TO REMEMBER

- Small intestine is characterized by the evaginations called the *villi*.
- Most of the duodenum is fixed and retroperitoneal
- 2nd part of duodenum contains the openings of bile and pancreatic ducts
- 3rd part of duodenum is crossed anteriorly by superior mesenteric vessels
- Duodenal cap is triangular shadow of its first part seen in Ba meal (X-ray). Transverse colon is the most mobile part of large intestine.
- Meckel's diverticulum is the proximal persistent part of vitellointestinal duct.
- Caecum is broader than longer.
- The commonest position of vermiform appendix is retrocaecal.
- Pain of early appendicitis is referred to the region of umbilicus. The visceral peritoneum of appendix receives supply from lesser splanchnic nerve, arising from T10 sympathetic ganglion and T10 segment of spinal cord. Same segment receives sensation from the umbilical area. Later appendicitis pain is localized to right iliac fossa.
- McBurney's point is a point at the junction of medial 2/3rd and lateral 1/3rd of a line joining umbilicus to the right anterior superior iliac spine.
- Ileocaecal junction is the commonest site of TB of intestines.
- Cancer of colon mostly occurs at rectosigmoid junction.



CLINICOANATOMICAL PROBLEM

A young male felt pain in the region of umbilicus. He also had nausea, temperature and increased pulse rate with leucocytosis. Later on the pain was localised in right iliac fossa.

- Discuss the referred pain of appendicitis?
- Where is his appendix likely to be located?
- What is McBurney's point?

Ans: Initially the pain of acute appendicitis is referred to the skin in the region of umbilicus. Afferent nerve fibres from appendix are carried in lesser splanchnic nerve to T10 segment of spinal cord. The afferent

impulses from the skin of umbilicus also reach T10 segment through 10th intercostal nerve. Since both the somatic and visceral impulses reach the same segment, and somatic impulses being appreciated better by brain, the pain is referred to the skin of the umbilicus. The most common position of appendix is retrocaecal, and since the patient's pain is in right iliac fossa, the position of the appendix is likely to be retrocaecal.

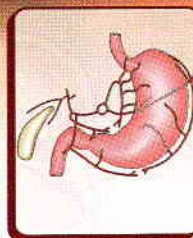
McBurney's point lies at the junction of lateral one-third and medial two-thirds of a line joining anterior superior iliac spine to the umbilicus.

MULTIPLE CHOICE QUESTIONS

- Which of the following is not a characteristic feature of large intestine?
 - Sacculations
 - Villi
 - Taenia coli
 - Appendices epiploicae
- Which of the following is true about Meckel's diverticulum?
 - Length is about 5 cm
 - Occurs in 2% subjects
 - 2 feet proximal to ileocaecal valve
 - Attached to mesenteric border of the ileum
- Peyer's patches are present in:
 - Duodenum
 - Jejunum
 - Ileum
 - Transverse colon
- Appendices epiploicae are seen in:
 - Stomach
 - Ileum
 - Duodenum
 - Colon
- False fact regarding vermiform appendix is:
 - Is covered by peritoneum
 - Commonest site is retrocaecal
 - Supplied by appendicular artery
 - Superior to caecum
- Most common position of vermiform appendix is:
 - Pelvic
 - Retrocaecal
 - Preileal
 - Postileal
- First 2.5 cm of 1st part of duodenum is not supplied by:
 - Superior pancreaticoduodenal artery
 - Right gastroepiploic artery
 - Right gastric artery
 - Hepatic artery
- Meckel's diverticulum is a remnant of:
 - Mullerian duct
 - Wolfian duct
 - Mesonephric duct
 - Vitellointestinal duct
- Mesentery of small intestine crosses following structures *except*:
 - Inferior vena cava
 - Right psoas major
 - Abdominal aorta
 - Right kidney
- Which part of intestine contains Brunner's glands?
 - Ileum
 - Duodenum
 - Jejunum
 - Colon

ANSWERS

1. b 2. d 3. c 4. d 5. d 6. b 7. d 8. d 9. d 10. b



Large Blood Vessels of the Gut

Give me blood, I will give you Azadi
—Netaji Subhash Chandra Bose

INTRODUCTION

The three ventral branches of the abdominal aorta are coeliac trunk, superior mesenteric and inferior mesenteric arteries. These are the arteries of the foregut, midgut and hindgut, respectively. There is anastomoses between the branches of these three main arteries.

In this chapter the coeliac trunk, the superior and inferior mesenteric vessels, and the portal vein will be studied.

BLOOD VESSELS

DISSECTION

Identify the short trunk of coeliac axis artery at the level of the intervertebral disc between T12 and L1 vertebrae arising from the aorta. Dissect its relations especially with the coeliac ganglion and identify its three branches and their further divisions.

Clean the superior mesenteric vessels with its branches both from its right and left surfaces. Dissect these branches and trace them till the organs of their supply.

Identify the inferior mesenteric artery arising at the L3 vertebra. Trace its course and branches.

Identify the large portal vein formed by the union of superior mesenteric and splenic vein posterior to the neck of pancreas. Trace it upwards towards the remains of free margin of lesser omentum till the porta hepatis where it divides into two branches. Identify the veins taking part in portosystemic anastomoses.

COELIAC TRUNK

The coeliac trunk is the artery of the foregut (Figs 21.1 and 21.2). It supplies all derivatives of the foregut that lie in the abdomen namely:

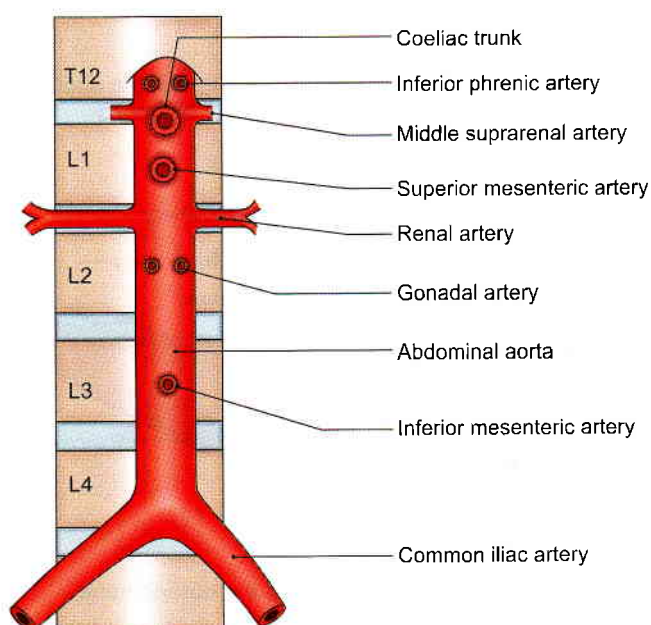


Fig. 21.1: Ventral and lateral branches of the abdominal aorta with their levels of origin

- 1 The lower end of the oesophagus, the stomach and upper part of the duodenum up to the opening of the bile duct.
- 2 Liver
- 3 Spleen
- 4 Greater part of the pancreas.

Origin and Length

The coeliac trunk arises from the front of the abdominal aorta just below the aortic opening of the diaphragm at the level of the disc between thoracic twelve and first lumbar vertebrae. The trunk is only about 1.25 cm long. It ends by dividing into its three terminal branches, namely the left gastric, common hepatic and splenic arteries (Figs 21.3 to 21.5).

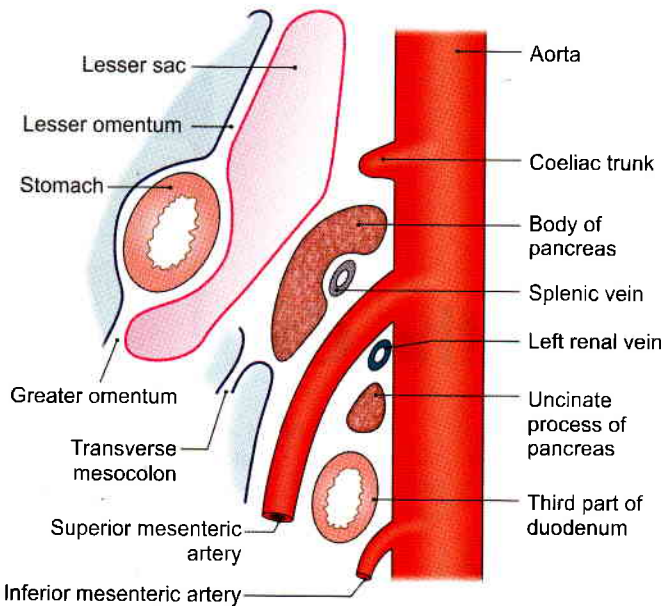


Fig. 21.2: Left view of a sagittal section through the abdominal aorta showing the origin of its three ventral branches

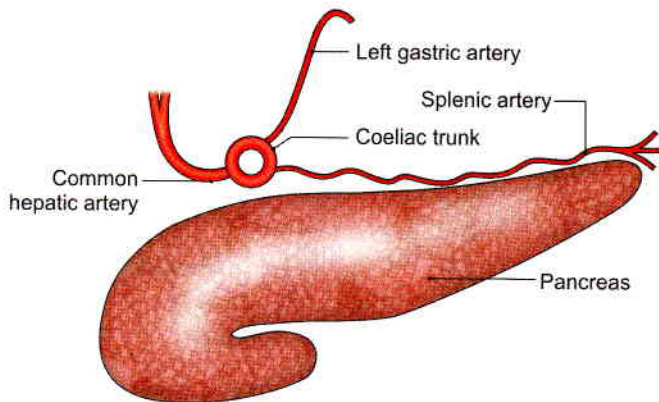


Fig. 21.3: Three branches of the coeliac trunk

Relations

- 1 It is surrounded by the coeliac plexus of nerves (see Fig. 27.6).
- 2 Anteriorly, it is related to the lesser sac and to the lesser omentum (Fig. 21.2).
- 3 To its right, there are the right crus of the diaphragm, the right coeliac ganglion and the caudate process of the liver.
- 4 To its left, there are the left crus of the diaphragm, the left coeliac ganglion and the cardiac end of the stomach.
- 5 Inferiorly, it is related to the body of the pancreas and to the splenic vein (Fig. 21.2).

Branches

Left Gastric Artery

The *left gastric artery* is the smallest of the three branches of the coeliac trunk. It runs upwards to the left behind

the lesser sac to reach the cardiac end of the stomach where it turns forwards and enters the lesser omentum to run downwards along the lesser curvature of the stomach. It ends by anastomosing with the right gastric artery.

It gives off:

- a. Two or three *oesophageal branches* at the cardiac end of the stomach.
- b. Numerous *gastric branches* along the lesser curvature of the stomach (Fig. 21.4).

Common Hepatic Artery

The *common hepatic artery* runs downwards, forwards and to the right, behind the lesser sac to reach the upper border of the duodenum. Here it enters the lesser omentum. It then run upwards as proper hepatic artery in the right free margin of the lesser omentum, in front of the portal vein, and to the left of the bile duct (see Figs 18.10 and 21.3). Reaching the porta hepatis it terminates by dividing into right and left hepatic branches.

Branches

- 1 The *gastroduodenal artery* is a large branch which arises at the upper border of the first part of the duodenum. The part of the hepatic artery till the origin of the gastroduodenal artery is called the *common hepatic artery*. The part distal to it is the *proper hepatic artery*.

The *gastroduodenal artery* runs downwards behind the first part of the duodenum and divides at its lower border into the right gastroepiploic and superior pancreaticoduodenal arteries.

The *right gastroepiploic artery* enters the greater omentum, follows the greater curvature of the stomach, and anastomoses with the left gastroepiploic artery.

The *superior pancreaticoduodenal artery* (often represented by two arteries anterior and posterior) runs downwards in the pancreaticoduodenal groove, and ends by anastomosing with the inferior pancreaticoduodenal artery, a branch of the superior mesenteric.

- 2 The *right gastric artery* is a small branch which arises from the proper hepatic artery close to the gastroduodenal artery. It runs to the left along the lesser curvature and ends by anastomosing with the left gastric artery.
- 3 The *cystic artery* is a branch of the right hepatic artery. It passes behind the common hepatic and cystic ducts to reach the upper surface of the neck of the gall bladder where it divides into superficial and deep branches for the inferior and superior surfaces of the gallbladder, respectively.

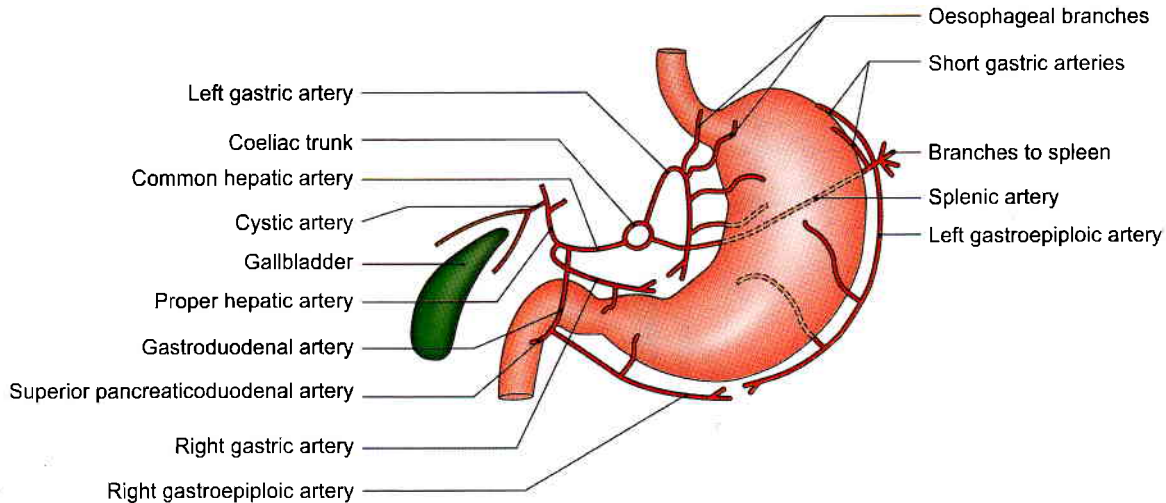


Fig. 21.4: Arteries arising from the branches of the coeliac trunk

Splenic Artery

The *splenic artery* is the largest branch of the coeliac trunk. It runs horizontally to the left along the upper border of the pancreas behind the lesser sac. It crosses the left suprarenal gland and the upper part of the left kidney to enter the lienorenal ligament, through which it reaches the hilum of spleen where it divides into 5 to 7 splenic branches (see Figs 19.10, 21.3 and 21.4).

Branches

It gives off the following branches:

- 1 Numerous *pancreatic branches* which supply the body and tail of the pancreas. One of the branches to the body of the pancreas is large and is known as the *arteria pancreatic magna*. Another large branch to the tail is known as the *arteria caudae pancreatis*. These large arteries anastomose (on the back of the pancreas) with the left branch of a *dorsal artery* which may arise from one of the following arteries: superior mesenteric, middle colic, hepatic, or coeliac.
- 2 Five to seven *short gastric arteries* arise from the terminal part of the splenic artery, run in the gastrosplenic ligament, and supply the fundus of the stomach.
- 3 The *left gastroepiploic artery* also arises from the terminal part of the splenic artery, runs downwards in the greater omentum, follows the greater curvature of the stomach, and ends by anastomosing with the right gastroepiploic artery. As the name suggests the gastroepiploic arteries supply both the stomach and greater omentum.

SUPERIOR MESENTERIC ARTERY

The superior mesenteric artery is the artery of the midgut. It supplies all derivatives of the midgut, namely:

- 1 Lower part of the duodenum below the opening of the bile duct (Fig. 21.5).
- 2 Jejunum
- 3 Ileum
- 4 Appendix
- 5 Caecum
- 6 Ascending colon
- 7 Right two-thirds of the transverse colon
- 8 Lower half of the head of the pancreas (Figs 21.2 and 21.5).

Origin, Course and Termination

The superior mesenteric artery arises from the front of the abdominal aorta, behind the body of the pancreas, at the level of vertebra L1, one centimeter below the coeliac trunk (Fig. 21.5). It runs downwards and to the right, forming a curve with its convexity towards the left.

At its origin it lies first behind the body of the pancreas and then in front of the uncinat process. Next it crosses the third part of the duodenum, enters the root of mesentery, and runs between its two layers. It terminates in the right iliac fossa by anastomosing with a branch of the ileocolic artery.

Relations

Above the Root of the Mesentery

- 1 *Anteriorly*, it is related to the body of the pancreas and to the splenic vein.
- 2 *Posteriorly*, to the aorta, the left renal vein, the uncinat process and the third part of the duodenum (Fig. 21.6a).

Within the Root of the Mesentery

It *crosses* the inferior vena cava, and the right psoas. Throughout its course it is accompanied by the superior

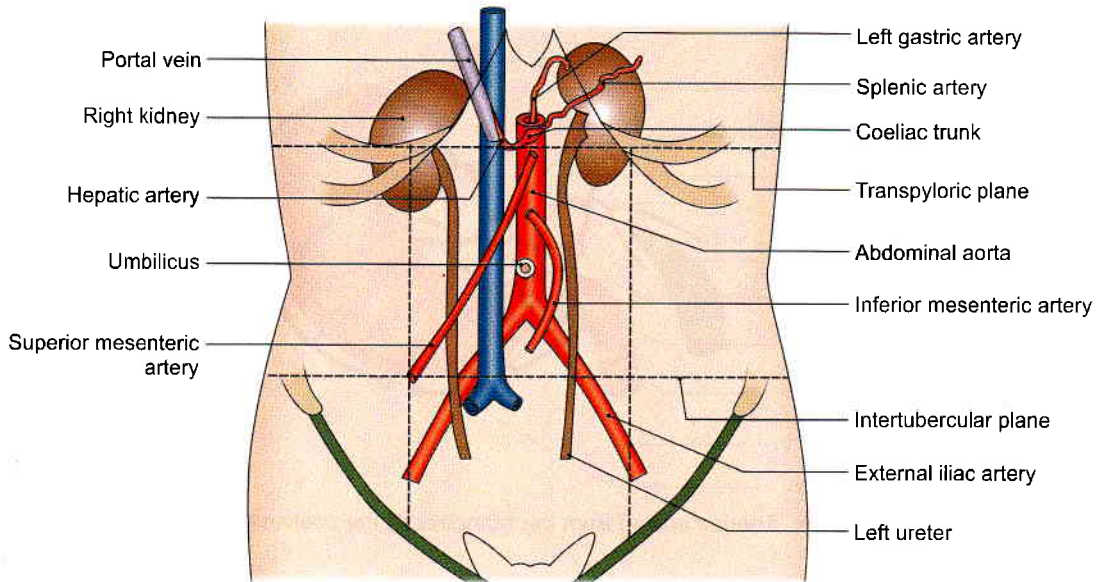


Fig. 21.5: Position of various blood vessels and kidneys

mesenteric vein which lies on its right side. The artery is surrounded by the superior mesenteric plexus of nerves (Figs 21.6b and c).

Branches

The superior mesenteric artery gives off five sets of branches both from its right and left sides (Fig. 21.7).

- 1 Those arising from its *right side* are:
 - a. Inferior pancreaticoduodenal
 - b. Middle colic
 - c. Right colic
 - d. Ileocolic.
- 2 Those arising from its *left side* are 12–15 jejunal and ileal branches.

Inferior Pancreaticoduodenal Artery

Inferior pancreaticoduodenal artery arises from the superior mesenteric artery at the upper border of the third part of the duodenum. The artery soon divides into anterior and posterior branches which run in the pancreaticoduodenal groove, supply the head of the pancreas and the duodenum, and ends by anastomosing with the superior pancreaticoduodenal artery.

Middle Colic Artery

Middle colic artery arises from the right side of the superior mesenteric artery just below the pancreas. It runs downwards and forwards in the transverse mesocolon. It divides into a right branch, which anastomoses with the right colic artery, and a left branch, which anastomoses with the left colic artery. Further branches arising from these, form arcades and supply the transverse colon.

Right Colic Artery

Right colic artery arises near the middle of the concavity of the superior mesenteric artery. It passes to the right behind the peritoneum, and at the upper part of the ascending colon it divides into a descending branch, which anastomoses with the ileocolic artery, and an ascending branch, which anastomoses with the middle colic artery. The branches form an arch, from the convexity of which smaller branches are distributed to the upper two-thirds of the ascending colon and the right flexure of the colon.

Ileocolic Artery

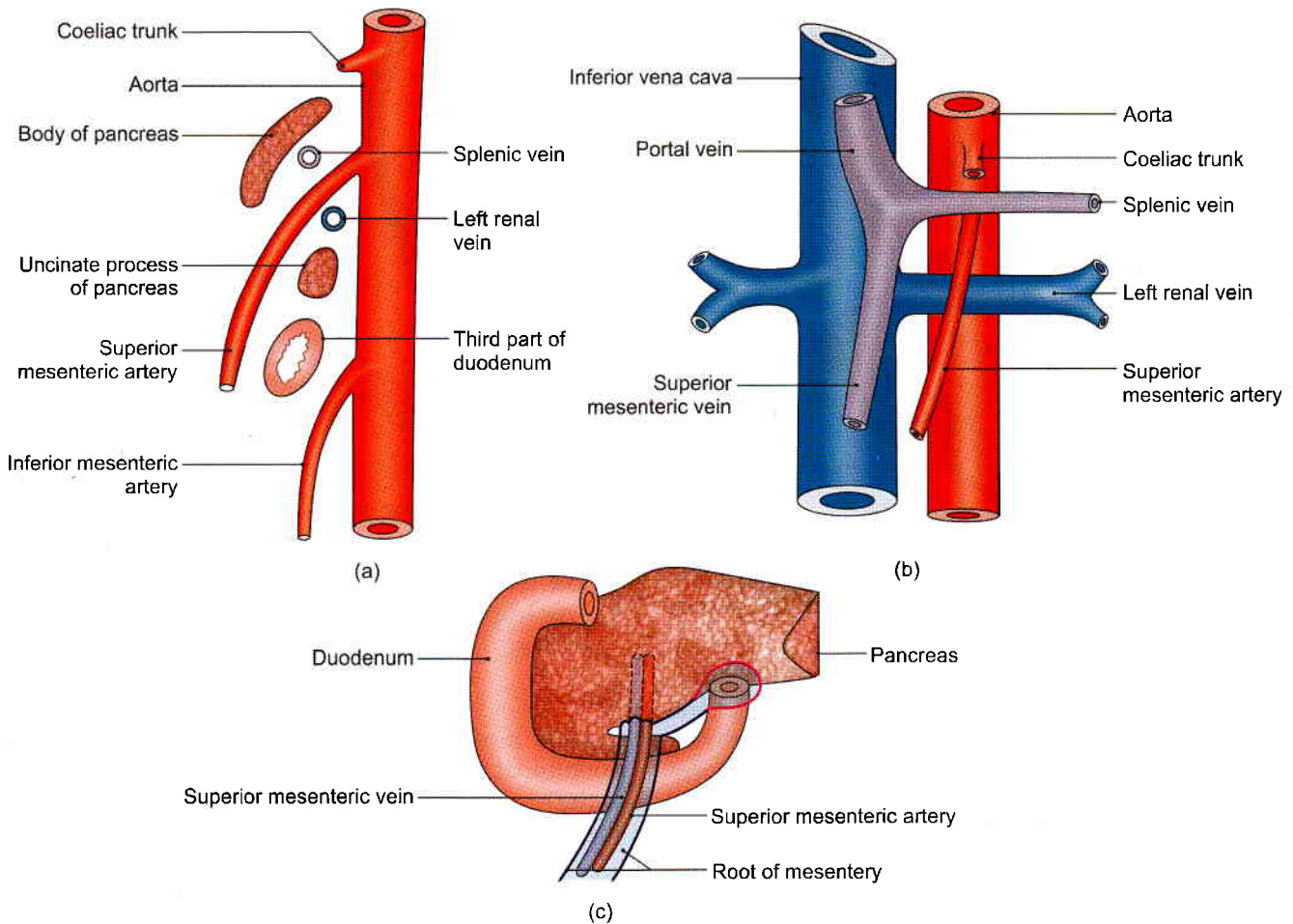
Ileocolic artery arises from the right side of the superior mesenteric artery. It runs downwards and to the right, and divides into superior and inferior branches. The superior branch anastomoses with the right colic artery, and the inferior branch anastomoses with the termination of the superior mesenteric artery.

The inferior branch of the ileocolic artery gives off:

- a. An ascending colic branch to the ascending colon.
- b. Anterior and posterior caecal branches to the caecum (*see* Fig. 20.26).
- c. An appendicular branch which passes behind the ileum and reaches the appendix through its mesentery (*see* Fig. 20.26).
- d. The ileal branch to the terminal portion of the ileum.

Jejunal and Ileal Branches

Jejunal and ileal branches are about 12 to 15 in number and arise from the left side of the superior mesenteric artery. They run between the two layers of the



Figs 21.6a to c: Relation of the superior mesenteric artery: (a) Left view of a sagittal section through the aorta, (b) anterior view of the vessel after removal of the duodenum and pancreas, and (c) anterior view of the vessel with the duodenum and pancreas in place

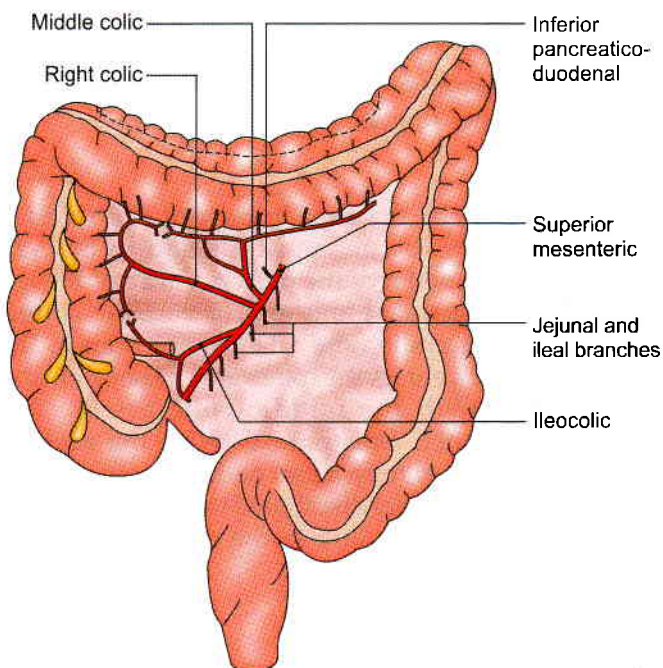


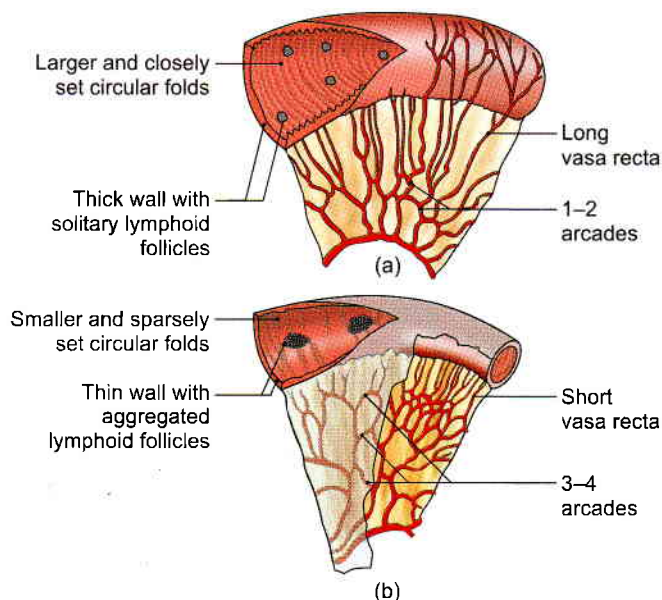
Fig. 21.7: Branches of the superior mesenteric artery

mesentery towards the gut. They anastomose with one another to form arterial arcades which give off straight branches or vasa recta to the gut. These branches supply the jejunum (Fig. 21.8a) and most of ileum (Fig. 21.8b). The terminal part of the ileum is supplied by the ileocolic artery.

On passing from jejunum to ileum, the number of arterial arcades increases from one to as many as five. The vasa recta are longer and less numerous in the jejunum than in the ileum. These are distributed alternately to opposite surfaces of the gut, and the neighbouring vessels do not anastomose with one another.

SUPERIOR MESENTERIC VEIN

- 1 Superior mesenteric vein is a large vein which drains blood from the small intestine, the appendix, the caecum, the ascending colon and the transverse colon (Fig. 21.9).
- 2 It begins in the right iliac fossa by the union of tributaries from the ileocaecal region. It accompanies



Figs 21.8a and b: Arterial arcades and vasa recta of: (a) Jejunum, and (b) ileum

the superior mesenteric artery. The vein lies on the right side of the artery. It terminates, behind the neck of the pancreas, by joining the splenic vein to form the portal vein.

- 3 Its *tributaries* are as follows.
 - a. Veins corresponding to the branches of the superior mesenteric artery.
 - b. Right gastroepiploic vein.
 - c. Inferior pancreaticoduodenal vein.

CLINICAL ANATOMY

- Sudden occlusion of the superior mesenteric artery, vein or both may occur due to embolism or thrombosis. It is usually followed by a rapidly spreading form of intestinal obstruction due to the haemorrhagic infarction of the involved gut.
- Superior mesenteric artery crosses third part of duodenum (*see* Fig. 20.15). This part of duodenum may get obstructed as it lies between abdominal aorta and superior mesenteric artery. Duodenum behaves like a nut between the two tongs formed by these two arteries.

INFERIOR MESENTERIC ARTERY

The inferior mesenteric artery is the artery of the hindgut. It supplies the parts of the gut that are derivatives of the hindgut and posterior part of cloaca, the anorectal canal, namely:

- 1 The left one-third of the transverse colon
- 2 The descending colon (Fig. 21.9)
- 3 The sigmoid colon

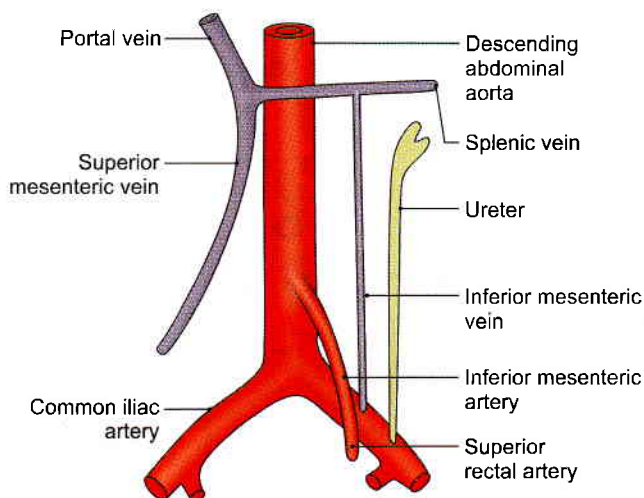


Fig. 21.9: Course of the inferior mesenteric vessels

- 4 The rectum
- 5 The upper part of the anal canal, above the anal valves.

Origin

Inferior mesenteric artery arises from the front of the abdominal aorta behind the third part of the duodenum, at the level of third lumbar vertebra, and 3 to 4 cm above the bifurcation of the aorta.

Course and Termination

It runs downwards and to the left, behind the peritoneum, crosses the common iliac artery medial to the left ureter, and continues in the sigmoid mesocolon as the superior rectal artery (Fig. 21.9).

Branches

The inferior mesenteric artery gives off the left colic, sigmoid branches (Fig. 21.10).

Left Colic Artery

Left colic artery is the first branch of the inferior mesenteric artery. It runs upwards and to the left, behind the peritoneum of the posterior wall of the left infracolic compartment and after a variable course divides into an ascending and a descending branch. The ascending branch enters the transverse mesocolon and anastomoses with the middle colic artery. The descending branch anastomoses with the highest sigmoid artery. They form a part of the marginal artery from which branches are distributed to the left one-third of the transverse colon and to the descending colon (Fig. 21.10).

Sigmoid Arteries

Sigmoid arteries are 2 to 4 in number. They pass downwards and to the left, and anastomose with each

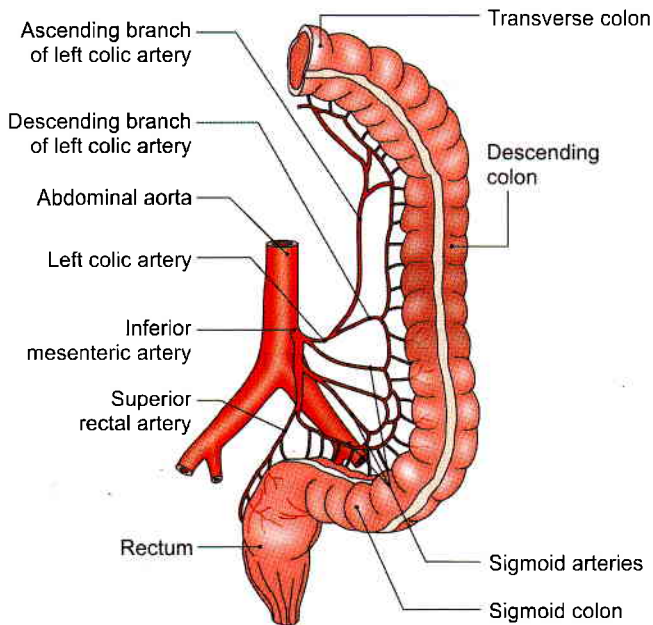


Fig. 21.10: Branches of the inferior mesenteric artery

other to form the lower part of the marginal artery. The uppermost branch anastomoses with the descending branch of the left colic artery, whereas the lowest sigmoid artery sends a branch to anastomose with the superior rectal artery. They supply the descending colon in the iliac fossa and the sigmoid colon.

Superior Rectal Artery

Superior rectal artery is the continuation of the inferior mesenteric artery beyond the root of the sigmoid mesocolon, i.e. over the left common iliac vessels. It descends in the sigmoid mesocolon to reach the rectum. Opposite third sacral vertebra it divides into right and left branches which descend one on each side of the rectum. They pierce the muscular coat of the rectum and divide into several branches, which anastomose with one another at the level of the anal sphincter to form loops around the lower end of the rectum. These branches communicate with the middle and inferior rectal arteries in the submucosa of the anal canal (Figs 21.10 and 21.16).

INFERIOR MESENTERIC VEIN

- 1 The inferior mesenteric vein drains blood from the rectum, the anal canal, the sigmoid colon and the descending colon.
- 2 It begins as the *superior rectal vein* from the upper part of the internal rectal venous plexus. In the plexus it communicates with the middle and inferior rectal veins. The superior rectal vein crosses the left common iliac vessels medial to the left ureter and continues upwards as the inferior mesenteric vein.

This vein lies lateral to the inferior mesenteric artery. The vein ascends behind the peritoneum, passes lateral to the duodenojejunal flexure and behind the body of the pancreas. It opens into the splenic vein (Fig. 21.9).

- 3 Its *tributaries* correspond to the branches of the inferior mesenteric artery.

CLINICAL ANATOMY

Inferior mesenteric vein lies in the free margin of paraduodenal fold before draining into splenic vein. In case of strangulated internal hernia in duodenojejunal recess these folds may be cut to enlarge the space. One needs to remember that inferior mesenteric vein (not the artery) lies in the fold, and it needs to be ligated (*see* Fig. 18.32).

MARGINAL ARTERY OF DRUMMOND

Marginal artery was described by von Haller in 1803 and its present name was given by Sudeck in 1907. The marginal artery is an arterial arcade situated along the concavity of the colon. It is formed by anastomoses between the main arteries supplying the colon, namely the ileocolic, right colic, middle colic, left colic and sigmoid arteries. It lies at a distance of 2.5 to 3.8 cm from the colon. It is closest to the colon in its descending and sigmoid parts. Vasa recta arise from the marginal artery and supply the colon (Fig. 21.11).

The marginal artery is capable of supplying the colon even in the absence of one of the main feeding trunks. This fact is utilized in surgery. However, at the junctional points between the main vessels, there may be variations in the competence of the anastomoses.

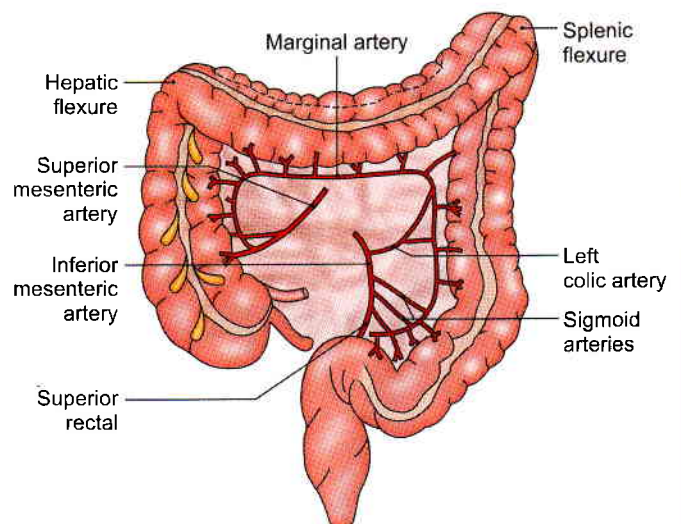


Fig. 21.11: The marginal artery



PORTAL VEIN

Portal vein is a large vein which collects blood from:

- 1 The abdominal part of the alimentary tract
- 2 The gallbladder
- 3 The pancreas
- 4 The spleen, and conveys it to the liver. In the liver, the portal vein breaks up into sinusoids which are drained by the hepatic veins to the inferior vena cava (Figs 21.12 and 21.13).

It is called the portal vein because its main tributary, the superior mesenteric vein, begins in one set of capillaries (in the gut) and the portal vein ends in another set of capillaries in the liver.

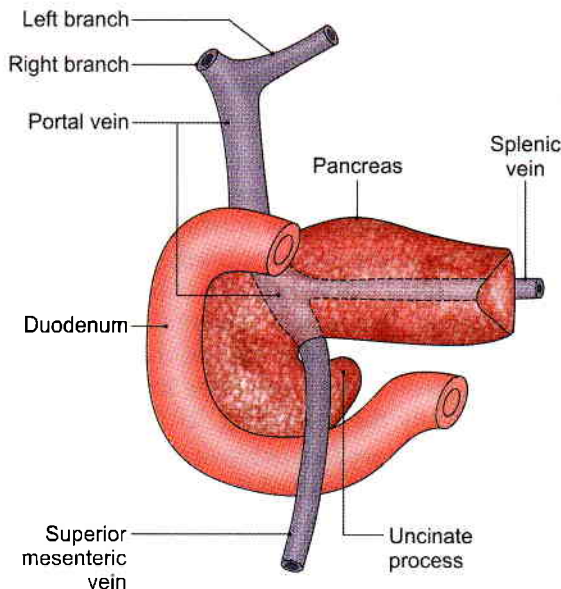


Fig. 21.12: Formation and course of the portal vein

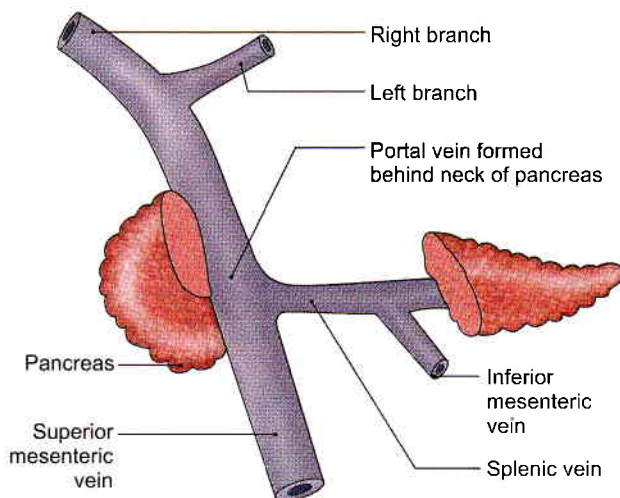


Fig. 21.13: Formation of portal vein

Formation

The portal vein is about 8 cm long. It is formed by the union of the superior mesenteric and splenic veins behind the neck of the pancreas at the level of second lumbar vertebra. Inferior mesenteric vein drains into splenic vein.

Course

It runs upwards and a little to the right, first behind the neck of the pancreas, next behind the first part of the duodenum, and lastly in the right free margin of the lesser omentum.

The blood flow in portal vein is slow. Blood of superior mesenteric vein drains into right lobe. Blood of splenic and inferior mesenteric vein drains into left lobe. This is called "streamline flow".

The portal vein can thus be divided into infra-duodenal, retroduodenal and supraduodenal parts.

Termination

The vein ends at the right end of the porta hepatis by dividing into right and left branches which enter the liver.

Relations

Infraduodenal Part

Anteriorly: Neck of pancreas.

Posteriorly: Inferior vena cava (see Figs 20.8a and 21.14).

Retroduodenal Part

Anteriorly

- 1 First part of duodenum
- 2 Bile duct
- 3 Gastroduodenal artery.

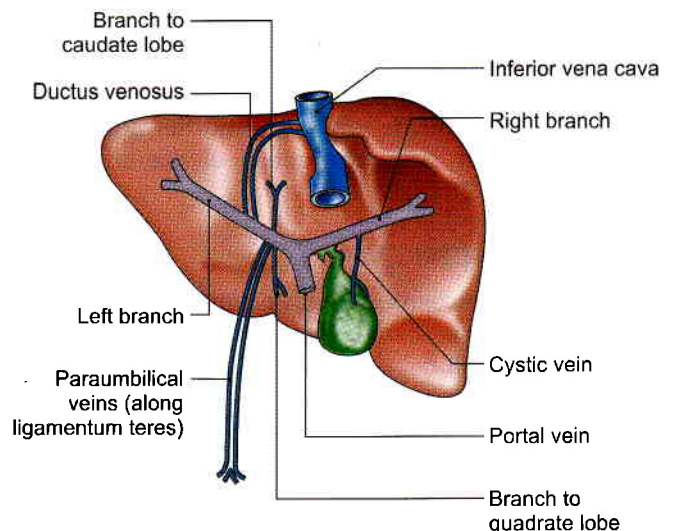


Fig. 21.14: The portal vein, its communications and branches



Posteriorly

Inferior vena cava (see Fig. 20.8b).

Supraduodenal Part

Anteriorly

- 1 Hepatic artery
- 2 Bile duct (within free margin of the lesser omentum).

Posteriorly

Inferior vena cava, separated by epiploic foramen (see Fig. 18.10).

Intrahepatic Course

After entering the liver, each branch divides and redivides along with the hepatic artery to end ultimately in the hepatic sinusoids, where the portal venous blood mixes with the hepatic arterial blood.

Branches

- 1 The *right branch* is shorter and wider than the left branch. After receiving the cystic vein, it enters the right lobe of the liver (Fig. 21.16).
- 2 The *left branch* is longer and narrower than the right branch. It traverses the porta hepatis from its right end to the left end, and furnishes branches to the caudate and quadrate lobes. Just before entering the left lobe of the liver, it receives:
 - a. Paraumbilical veins along the ligamentum teres.
 - b. Ligamentum venosum.

Tributaries

Portal vein receives the following veins.

- 1 Left gastric
- 2 Right gastric (Fig. 21.15)
- 3 Superior pancreaticoduodenal
- 4 Cystic vein in its right branch
- 5 Paraumbilical veins in its left branch

The left gastric vein accompanies the corresponding artery. At the cardiac end of the stomach it receives a few oesophageal veins. The right gastric vein accompanies the corresponding artery. It receives the prepyloric vein.

The paraumbilical veins are small veins that run in the falciform ligament, along the ligamentum teres, and establish anastomoses between the veins of the anterior abdominal wall present around the umbilicus and the portal vein (Fig. 21.16).

PORTOSYSTEMIC COMMUNICATIONS (PORTOCAVAL ANASTOMOSES)

These communications form important routes of collateral circulation in portal obstruction. The tributaries of portal and systemic system are put in Table 21.1. Various sites of portosystemic anastomoses are put in Table 21.2 and Fig. 21.17.

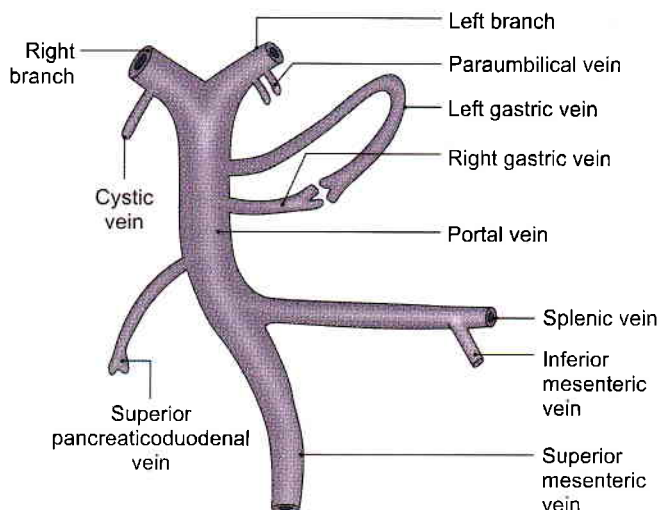


Fig. 21.15: Tributaries of the portal vein

CLINICAL ANATOMY

- **Portal pressure:** Normal pressure in the portal vein is about 5–15 mm Hg. It is usually measured by splenic puncture and recording the intrasplenic pressure.
- **Portal hypertension** (pressure above 40 mm Hg): It can be caused by the following.
 - a. Cirrhosis of liver, in which the vascular bed of liver is markedly obliterated.
 - b. Banti's disease
 - c. Thrombosis of portal vein.
 The effects of portal hypertension are as follows.
 - a. Congestive splenomegaly
 - b. Ascites
 - c. Collateral circulation through the portosystemic communications. It forms
 - i. Caput medusae around the umbilicus, which is of diagnostic value to the clinician (see Fig. 16.5b).
 - ii. Oesophageal varices at the lower end of oesophagus which may rupture and cause dangerous or even fatal haematemesis (see Fig. 19.4).
 - iii. Haemorrhoids in the anal canal may be responsible for repeated bleeding felt per rectum (see Fig. 33.9).

In cases of cirrhosis of liver, sometimes a shunt operation is done, where one of the main portal channels (splenic, superior mesenteric, or portal vein) is directly anastomosed with either inferior vena cava or the left renal vein (Fig. 21.18).

- Since the blood flow in portal vein is slow, and streamlined, the toxic infective substances absorbed from small intestine pass via the superior mesenteric vein into the right lobe of liver leading



to toxic changes or amoebic abscess in right lobe. The blood lacking in amino acids, etc. which is absorbed via the inferior mesenteric vein affect the left lobe, leading to its fibrosis or cirrhosis (Fig. 21.19).

- The lower end oesophagus is one of the sites of portocaval anastomoses. Some oesophageal veins drain into left gastric vein and then into portal vein. Other oesophageal veins drain into hemiazygos and then into vena azygos and superior vena cava. In liver cirrhosis portal vein pressure is raised, leading to oesophageal varices, which may rupture leading to haematemesis (see Fig. 19.4).

DEVELOPMENT

Portal vein develops from the following sources.

- 1 Infraduodenal part, from a part of the left vitelline vein distal to the dorsal anastomosis.

- 2 Retroduodenal part, from the dorsal anastomosis between the two vitelline veins.
- 3 Supraduodenal part, from the cranial part of the right vitelline vein.

FACTS TO REMEMBER

- Coeliac trunk is the first short unpaired ventral visceral branch of the abdominal aorta which supplies structures derived from the foregut.
- Superior mesenteric and inferior mesenteric arteries supply structures derived from midgut and hindgut respectively.
- Inferior mesenteric vein lies in the free margin of paraduodenal recess and is not accompanied by its artery in this region.
- Branches of portal vein anastomose with the branches of systemic circulation at few places.
- Portal vein supplies 80% blood to liver, while hepatic artery gives 20%.

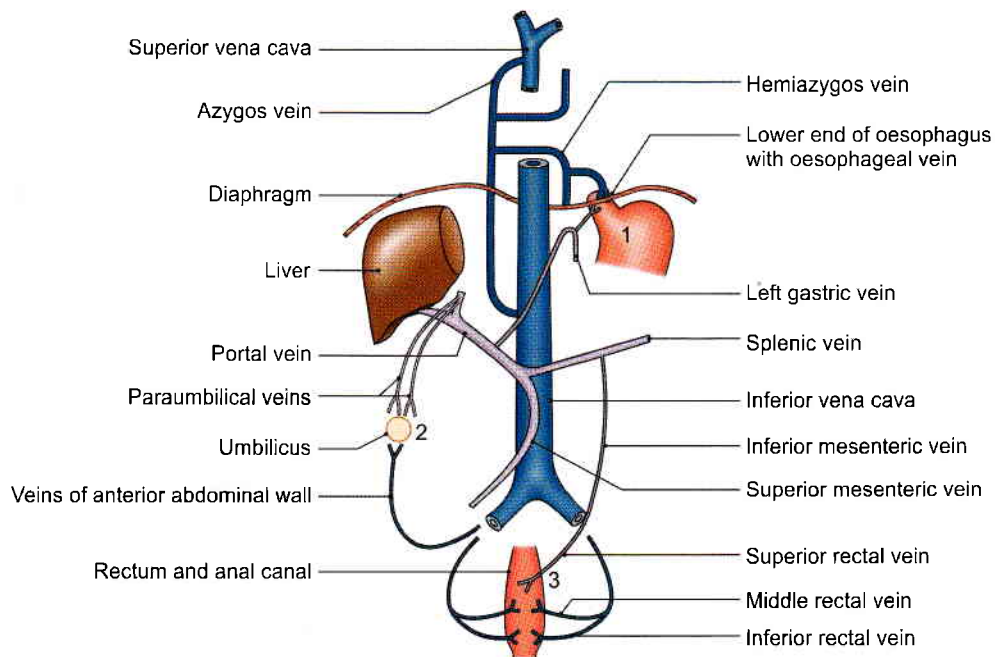


Fig. 21.16: Important sites of communication of portal and systemic veins: (1) Lower end of oesophagus, (2) around umbilicus, and (3) anal canal

Table 21.1: Tributaries of portal and systemic system

S.no.	Tributaries	Clinical conditions
1.	Abdominal part of oesophagus Some oesophageal veins drain via left gastric vein into the portal vein. Some oesophageal veins drain into hemiazygos → vena azygos → superior vena cava.	In liver cirrhosis, these tributaries anastomose, giving rise to <i>oesophageal varices</i> . These varices may rupture to cause haematemesis (see Fig. 19.4).

(Contd...)



Table 21.1: Tributaries of portal and systemic system (Contd...)

S.no.	Tributaries	Clinical conditions
2. Umbilicus	Few paraumbilical veins run along ligamentum teres and left branch of portal vein (Fig. 21.16). Veins around umbilicus drain via superior and inferior epigastric veins into superior and inferior vena cava respectively.	In liver cirrhosis the paraumbilical veins open up to transfer portal venous blood into systemic circulation. It results in caput medusae (see Fig. 16.5b)
3. Anal canal	Superior rectal vein continues up as inferior mesenteric vein which drains into portal vein. The middle and inferior rectal veins drain into inferior vena cava (Figs 21.16 and 21.17).	Liver cirrhosis causes anastomoses between superior rectal and other rectal veins. These anastomosing veins result in piles or haemorrhoids
4. Bare area of liver	Central veins and sublobular veins are part of portal circulation. Intercostal veins and phrenic veins end in systemic circulation.	There is some anastomoses between portal vein and systemic veins. No significance.
5. Veins of ascending and descending colon	Veins of colon end in the portal circulation. Veins of posterior abdominal wall end up in systemic veins	There is some anastomoses between these 2 sets of tributaries. These may get injured in procedures done in these areas
6. Patent ductus venosus of liver	It joins left branch of portal vein to inferior vena cava.	It may be accompanied by other congenital anomalies.

Table 21.2: Sites of portocaval/portosystemic anastomoses

S.no	Position	Portal vein	Systemic vein
1.	Lower end of oesophagus	Left gastric	Oesophageal veins
2.	Lower end of rectum	Superior rectal	Middle and inferior rectal veins
3.	Umbilicus	Paraumbilical	Above – Superior epigastric lateral thoracic Below – Superficial epigastric inferior epigastric
			Sides – Posterior intercostal and lumbar
4.	Posterior abdominal wall	Splenic	Left renal vein
5.	Bare area of liver	Portal radicles	Diaphragmatic
6.	Falciform ligament	Paraumbilical	Diaphragmatic
7.	Ligamentum venosum	Left branch of portal	Inferior vena cava

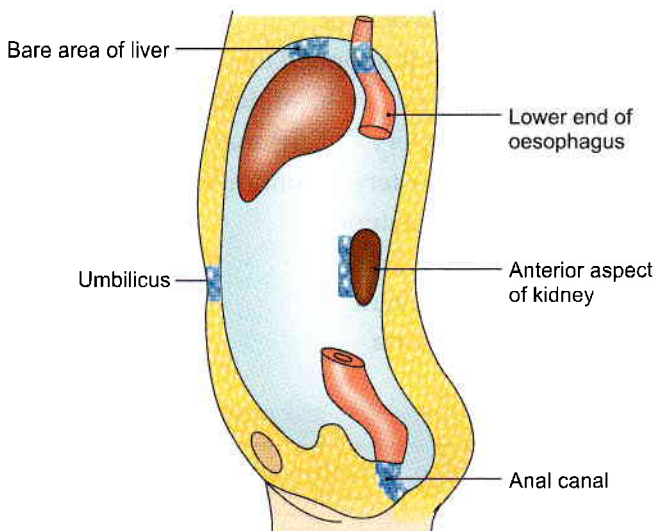


Fig. 21.17: Sites of portosystemic anastomoses

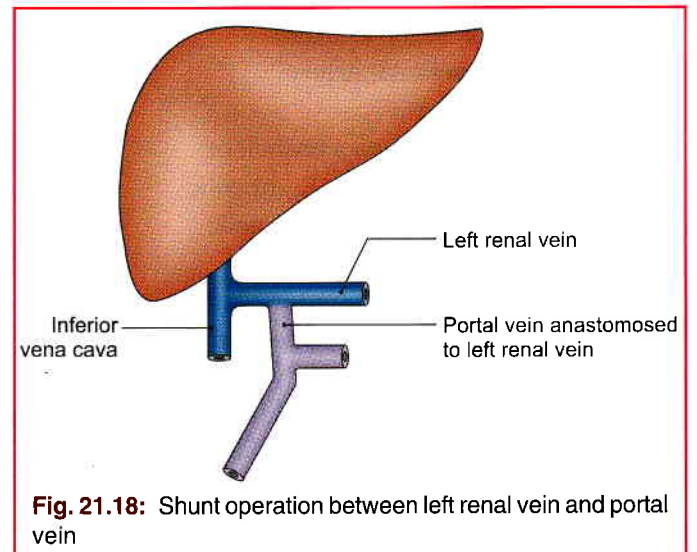


Fig. 21.18: Shunt operation between left renal vein and portal vein

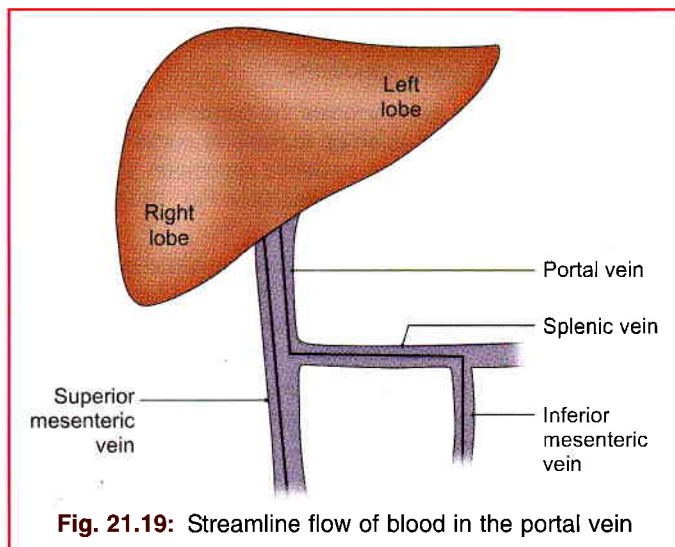


Fig. 21.19: Streamline flow of blood in the portal vein

CLINICOANATOMICAL PROBLEM

A middle aged alcoholic patient complained of lot of blood in his vomit.

- What causes haematemesis?

Ans: The lower end of oesophagus is one of the sites of portocaval anastomoses. Some oesophageal veins drain into left gastric vein and then into portal vein. Other oesophageal veins drain into hemiazygos and then into vena azygos and superior vena cava.

In liver cirrhosis, portal vein pressure is raised, leading to oesophageal varices, which may rupture leading to blood in the vomit.

Normally the anastomoses between tributaries of portal vein and those of superior vena cava is very little. These anastomotic channels develop in an attempt to take portal blood into caval blood.

MULTIPLE CHOICE QUESTIONS

- Inferior mesenteric vein opens into:
 - Portal vein
 - Inferior vena cava
 - Splenic vein
 - Superior mesenteric vein
- Which of the following is not a direct branch of coeliac trunk?
 - Left gastric
 - Common hepatic
 - Splenic
 - Inferior pancreaticoduodenal
- Cystic artery is a branch of:
 - Right hepatic
 - Left hepatic
 - Coeliac trunk
 - Common hepatic
- Jejunal and ileal branches for small intestine arise from:
 - Coeliac trunk
 - Superior mesenteric artery
 - Inferior mesenteric artery
 - Abdominal aorta
- Appendicular artery is a branch of:
 - Middle colic
 - Right colic
 - Ileocolic
 - Left colic
- Portal vein is formed by:
 - Union of inferior mesenteric and splenic vein
 - Union of superior mesenteric and splenic vein
 - Union of superior mesenteric and inferior mesenteric vein
 - Union of splenic, superior mesenteric and inferior mesenteric vein
- Ligamentum venosum is attached to:
 - Right branch of portal vein
 - Left branch of portal vein
 - Both the branches of portal vein
 - None of the above
- Portocaval anastomoses occurs at the following sites *except*:
 - Umbilicus
 - Lower end of oesophagus
 - Stomach
 - The bare area of liver
- Hepatic flexure is supplied by:
 - Ileocolic artery
 - Middle colic artery
 - Right colic artery
 - Jejunal branches
- Superior rectal artery is continuation of:
 - Superior mesenteric
 - Coeliac trunk
 - Inferior mesenteric
 - Abdominal aorta

ANSWERS

1. c 2. d 3. a 4. b 5. c 6. b 7. b 8. c 9. c 10. c



Extrahepatic Biliary Apparatus

Gallstones if threaded would make a beautiful emerald necklace

INTRODUCTION

The extrahepatic biliary apparatus collects bile from the liver, stores it in the gallbladder, and transmits it to the 2nd part of duodenum.

The apparatus consists of:

- Right and left hepatic ducts,
- Common hepatic duct,
- Gallbladder,
- Cystic duct, and
- Bile duct (Fig. 22.1).

HEPATIC DUCTS

DISSECTION

Locate the porta hepatis on the inferior surface of liver. Look for two hepatic ducts there. Follow them till these join to form common hepatic duct. Identify cystic duct and usually green-coloured gallbladder.

See the point of junction of cystic duct with common hepatic duct and the formation of bile duct. Trace the bile duct in relation to the duodenum. Its opening has been seen in dissection of the duodenum.

Trace the cystic artery supplying gallbladder, cystic duct, hepatic ducts and upper part of bile duct.

RIGHT AND LEFT HEPATIC DUCTS

The right and left hepatic ducts emerge at the porta hepatis from the right and left lobes of the liver. The arrangement of structures at the porta hepatis from behind forwards is:

- Branches of the portal vein,
- Proper hepatic artery, and
- Hepatic ducts (Fig. 22.2).

COMMON HEPATIC DUCT

It is formed by the union of the right and left hepatic ducts near the right end of the porta hepatis. It runs

downwards for about 3 cm and is joined on its right side at an acute angle by the cystic duct to form the bile duct.

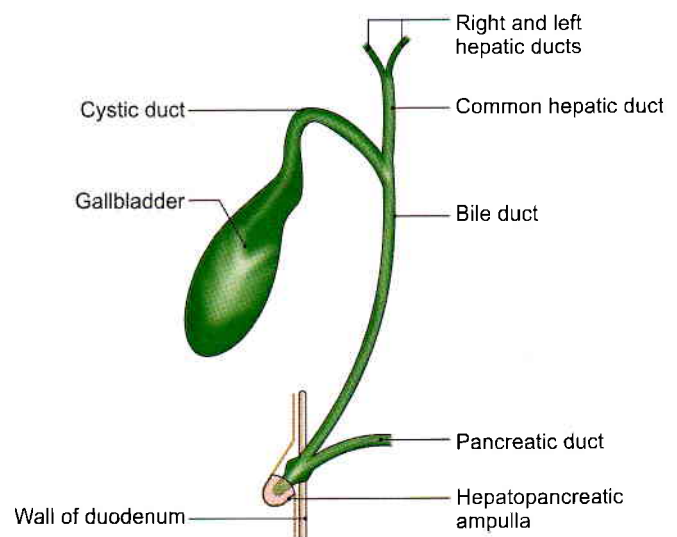


Fig. 22.1: Parts of the extrahepatic biliary apparatus

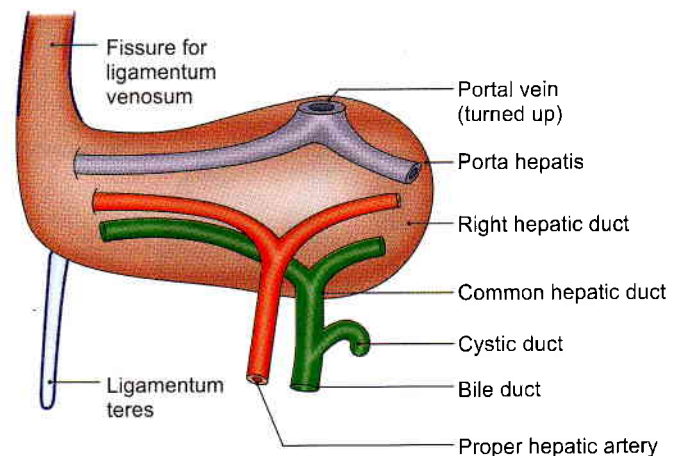


Fig. 22.2: Arrangement of structures in the porta hepatis



Accessory hepatic ducts are present in about 15% of subjects. They usually issue from the right lobe of the liver, and terminate either in the gallbladder, or in the common hepatic duct anywhere in its course, or even in the upper part of the bile duct (Fig. 22.3).

They are responsible for oozing of bile from the wound after cholecystectomy. Therefore, it is always better to use a drain to avoid retention of bile in the depths of the wound.

GALLBLADDER

Gallbladder is a pear-shaped reservoir of bile situated in a fossa on the inferior surface of the right lobe of the liver. The fossa for the gallbladder extends from the right end of the porta hepatis to the inferior border of the liver (Figs 22.1 and 22.4).

Dimensions and Capacity

The gallbladder is 7 to 10 cm long, 3 cm broad at its widest part, and about 30 to 50 ml in capacity.

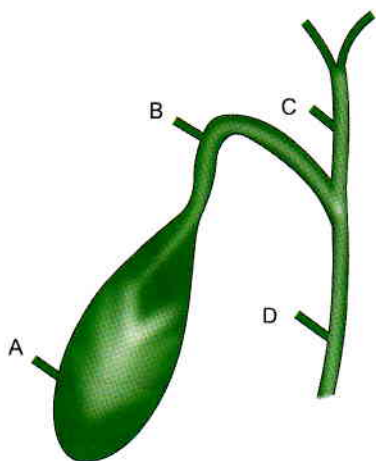


Fig. 22.3: The accessory hepatic ducts may open:

- (A) directly into the gallbladder
- (B) into the cystic duct
- (C) into the common hepatic duct
- (D) into the bile duct

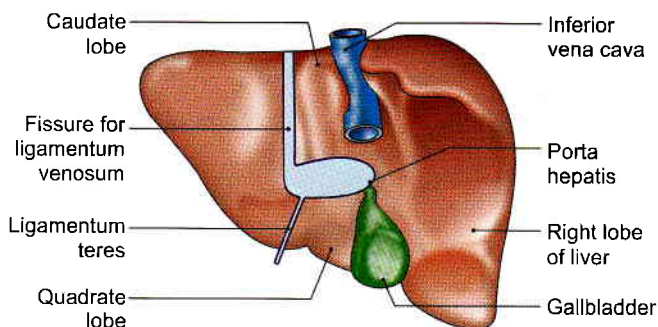


Fig. 22.4: Location of the gallbladder on the inferior surface of the right lobe of the liver

Parts

The gallbladder is divided into:

- 1 The fundus,
- 2 The body, and
- 3 The neck.

The *fundus* projects beyond the inferior border of the liver, in the angle between the lateral border of the right rectus abdominis and the ninth costal cartilage. It is entirely surrounded by peritoneum, and is related anteriorly to the anterior abdominal wall, and posteriorly to the beginning of the transverse colon.

The *body* lies in the fossa for the gallbladder on the liver. The upper narrow end of the body is continuous with the neck at the right end of the porta hepatis. The superior surface of the body is devoid of peritoneum, and is adherent to the liver. The inferior surface is covered with peritoneum, and is related to the beginning of the transverse colon and to the first and second parts of the duodenum (Fig. 22.5a).

The *neck* is the narrow upper end of the gallbladder. It is situated near the right end of the porta hepatis. It first curves anterosuperiorly and then posteroinferiorly to become continuous with the cystic duct. Its junction with the cystic duct is marked by a constriction (Fig. 22.5a).

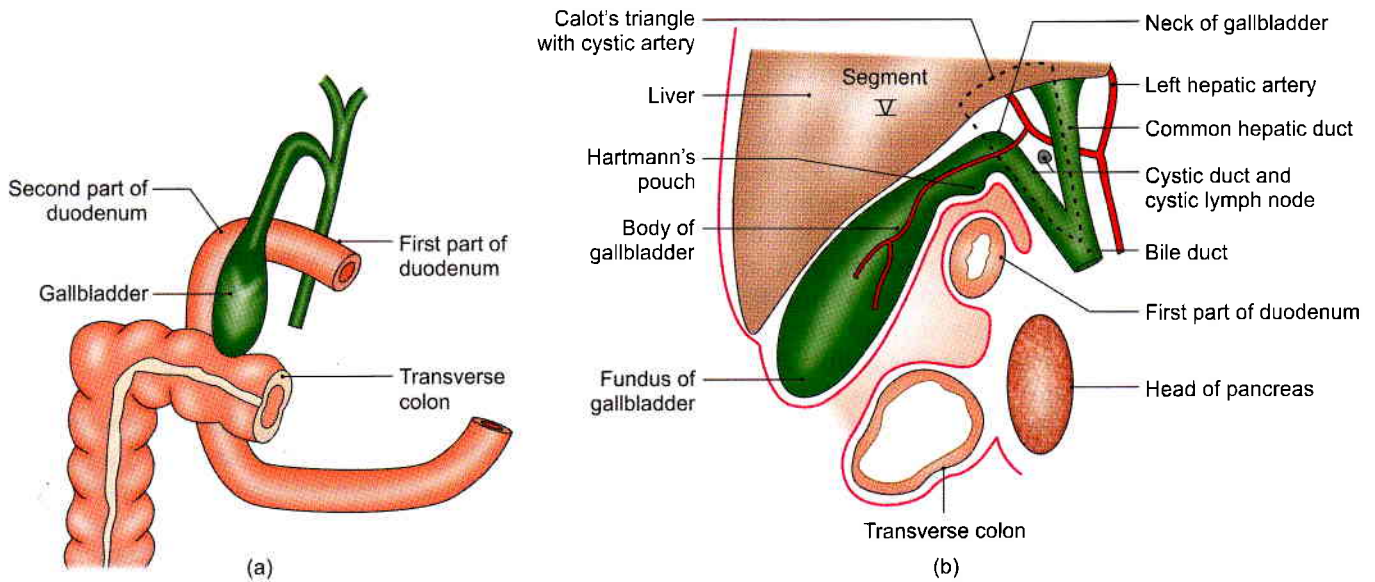
Superiorly, the neck is attached to the liver by areolar tissue in which the cystic vessels are embedded. Inferiorly, it is related to the first part of the duodenum. The mucous membrane of the neck is folded spirally to prevent any obstruction to the inflow or outflow of bile. The posteromedial wall of the neck is dilated outwards to form a pouch called the *Hartmann's pouch* which is directed downwards and backwards. Gallstones may lodge in this pouch (Fig. 22.5b).

CYSTIC DUCT

Cystic duct is about 3 to 4 cm long. It begins at the neck of the gallbladder, runs downwards, backwards and to the left, and ends by joining the common hepatic duct at an acute angle to form the bile duct. The mucous membrane of the cystic duct forms a series of 5 to 12 crescentic folds, arranged spirally to form the so-called *spiral valve* of Heister. This is not a true valve (Fig. 22.6).

Functions of Gallbladder

- 1 Storage of bile, and its release into the duodenum when required.
- 2 Absorption of water, and concentration of bile. Bile may be concentrated as much as ten times.
- 3 The normal gallbladder also absorbs small amounts of a loose bile salt-cholesterol compound. When the gallbladder is inflamed, the concentration function becomes abnormal and the bile salts alone are absorbed leaving cholesterol behind. Bile salts have



Figs 22.5a and b: Relations of the gallbladder: (a) Anterior view after removal of the liver, and (b) left view of sagittal section through the gallbladder fossa including the Calot's triangle

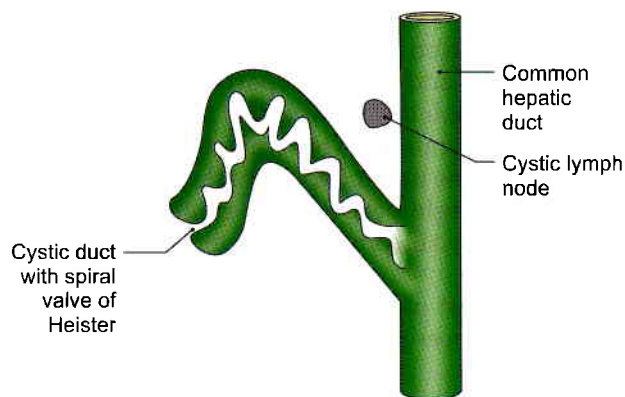


Fig. 22.6: The spiral valve of the cystic duct

a powerful solvent action on cholesterol which tends to be precipitated. This can lead to the formation of the gallstones.

- 4 It regulates pressure in the biliary system by appropriate dilatation or contraction. Thus the normal, choledochoduodenal mechanism is maintained.

BILE DUCT

Bile duct is formed by the union of the cystic and common hepatic ducts near the porta hepatis. It is 8 cm long and has a diameter of about 6 mm.

Course

- 1 The bile duct runs downwards and backwards, first in the free margin of the lesser omentum, *supraduodenal part*;
- 2 Behind the first part of the duodenum the *retroduodenal part*;

- 3 Then it lies behind, or embedded in, the head of pancreas *intraduodenal part*;
- 4 Near the middle of the left side of the second part of the duodenum it comes in contact with the pancreatic duct and accompanies it through the wall of the duodenum, the *intraduodenal part*.

Relations

Supraduodenal Part

Supraduodenal part in the free margin of lesser omentum.

- 1 *Anteriorly:* Liver.
- 2 *Posteriorly:* Portal vein and epiploic foramen.
- 3 *To the left:* Hepatic artery (Fig. 22.2).

Retroduodenal Part

- 1 *Anteriorly:* First part of duodenum (Fig. 22.5).
- 2 *Posteriorly:* Inferior vena cava.
- 3 *To the left:* Gastroduodenal artery.

Intraduodenal Part

- 1 *Anteriorly:* A groove in the upper and lateral parts of the posterior surface of the head of the pancreas.
- 2 *Posteriorly:* Inferior vena cava.

Intraduodenal Part

The course of the duct through the duodenal wall is very oblique. Within the wall the two ducts usually unite to form the *hepatopancreatic ampulla*, or *ampulla of Vater*. The distal constricted end of the ampulla opens at the summit of the *major duodenal papilla* 8 to 10 cm distal to the pylorus (see Fig. 23.16).



Sphincters Related to the Bile and Pancreatic Ducts

The terminal part of the bile duct is surrounded just above its junction with the pancreatic duct by a ring of smooth muscle that forms the *sphincter choledochus* (*choledochus* = bile duct). This sphincter is always present. It normally keeps the lower end of the bile duct closed (Fig. 22.7). As a result, bile formed in the liver keeps accumulating in the gallbladder and also undergoes considerable concentration. When food enters the duodenum, specially a fatty meal, the sphincter opens and bile stored in the gallbladder is poured into the duodenum. Another less developed sphincter, which is usually but not always present around the terminal part of the pancreatic duct is the *sphincter pancreaticus*. A third sphincter surrounds the hepatopancreatic ampulla and is called the *sphincter ampullae* or *sphincter of Oddi*.

Arteries Supplying the Biliary Apparatus

1 The cystic artery is the chief source of the blood supply, and is distributed to the gallbladder, the cystic duct, the hepatic ducts and the upper part of the bile duct (Fig. 22.8).

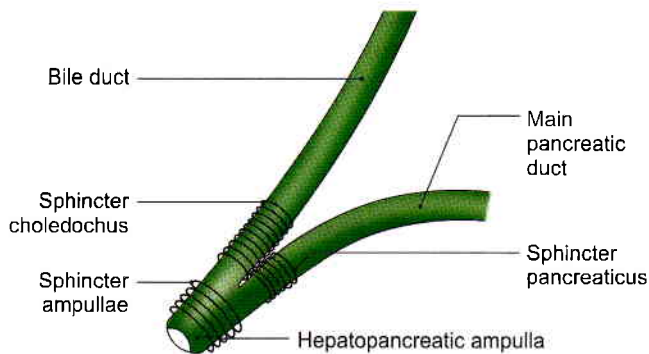


Fig. 22.7: Sphincters in the region of the junction of the bile duct and the main pancreatic duct with the duodenum

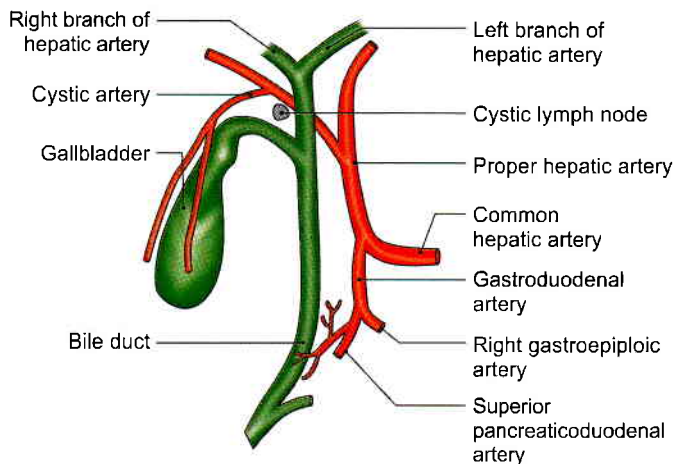


Fig. 22.8: Blood supply of the gallbladder and bile ducts

2 Several branches from the posterior superior pancreaticoduodenal artery supply the lower part of the bile duct.

3 The right hepatic artery forms a minor source of supply to the middle part of the bile duct.

The *cystic artery* usually arises from the right hepatic artery, passes behind the common hepatic and cystic ducts, and reaches the upper surface of the neck of the gallbladder, where it divides into superficial and deep branches.

Venous Drainage

1 The superior surface of the gallbladder is drained by veins which enter the liver through the fossa for the gallbladder and join tributaries of hepatic veins.

2 The rest of the gallbladder is drained by one or two cystic veins which open into the right branch of the portal vein (see Fig. 21.15).

3 The lower part of the bile duct drains into the portal vein.

Lymphatic Drainage

1 Lymphatics from the gallbladder, the cystic duct, the hepatic ducts and the upper part of the bile duct pass to the *cystic node* and to the *node of the anterior border of the epiploic foramen*. These are the most constant members of the upper hepatic nodes. The cystic node lies in the angle between the cystic and common hepatic ducts; it is constantly enlarged in cholecystitis (Fig. 22.5b).

2 The lower part of the bile duct drains into the *lower hepatic and upper pancreaticosplenic nodes*.

Nerve Supply

The *cystic plexus* of nerves, supplying the territory of the cystic artery, is derived from the hepatic plexus, which receives fibres from the coeliac plexus, the left and right vagi and the *right phrenic nerves*. The lower part of the bile duct is supplied by the nerve plexus over the superior pancreaticoduodenal artery.

Parasympathetic nerves are motor to the musculature of the gallbladder and bile ducts, but inhibitory to the sphincters. *Sympathetic nerves* from thoracic seven to nine are vasomotor and motor to the sphincters.

Pain from the gallbladder may travel along the vagus, the sympathetic nerves, or along the phrenic nerves. It may be referred to different sites through these nerves as follows.

- Through vagus to the stomach (epigastrium).
- Through the sympathetic nerves to the inferior angle of the right scapula. Lateral horn of thoracic 7 segment of spinal cord gives sympathetic fibres to coeliac ganglion through greater splanchnic nerve. T7 segment receives pain fibres from skin



over inferior angle of scapula. So visceral pain is referred to somatic area.

- c. Through the phrenic nerve to the right shoulder (C4 gives fibres to phrenic nerve and supraclavicular nerves).

CLINICAL ANATOMY

- Biliary obstruction arises when passage of bile into the duodenum is blocked either completely or partially.

Obstruction may be intrahepatic or extrahepatic. Causes are:

- a. The gallstones which slip down into the bile duct and block it (Fig. 22.10).
- b. Cancer of the head of pancreas which compresses the bile duct.

In these cases since bile pigments will not reach the duodenum, faeces will be light-colored. Instead bile pigments reach the blood, causing jaundice and as these are excreted in urine, cause it to be dark-coloured. Combination of light-coloured stools with dark-coloured urine implies obstructive jaundice. If it is associated with episodes of pain, it is likely to be due to gallstones. If it is associated with loss of weight, etc. it is likely to be due to cancer of head of pancreas.

- Bile duct can be assessed from the duodenum by a procedure—endoscopic retrograde cholangiography (ERCP).
- *Referred pain*: Pain of stretch of CBD or gallbladder is referred to epigastrium. It is also referred to right shoulder and inferior angle of right scapula (Fig. 22.9).
- *Humoral control of the gallbladder*: The gallbladder contracts when food rich in fat enters the duodenum. The fat causes certain cells in duodenum to liberate a hormone called *cholecystokinin-pancreozymmin*. The hormone is carried to the gallbladder and causes its contraction. It also causes dilatation of the sphincters.
- Gallbladder function can be investigated by ultrasound.
- Inflammation of the gallbladder is called *cholecystitis*. The patient complains of pain over the right hypochondrium radiating to the inferior angle of the right scapula, or to right shoulder. When a finger is placed just below the costal margin, at the tip of the 9th costal cartilage, the patient feels sharp pain on inspiration. He winces with a “catch” in his breath. This is referred to as *Murphy’s sign* (Fig. 22.11).
- Stones may form in the gallbladder. The condition is called *cholelithiasis* (Fig. 22.12). They typically

occur in fat, fertile, female of forty (but also in males). The stones are responsible for the time to time spasmodic pain called biliary colic. In these cases, Murphy’s sign is of great diagnostic value. Gallstones never develop in dog, cat, sheep, rabbit because of high fatty acid content of their bile. Stones are common in man, ox and hog because of low fatty acid in them. They can give rise to severe spasmodic pain which is called *biliary colic*.

- The region of the gallbladder is frequently operated upon. It is, therefore, necessary for the surgeon to be aware of the numerous variations that may exist in the extrahepatic biliary apparatus, and in the related blood vessels. The operation for removal of the gallbladder is called *cholecystectomy*.
- The most significant lesions of typhoid fever occur in lymphoid tissue, bone marrow and gallbladder. Gallbladder is invariably infected in these cases, and the carrier state may be due to persistence of typhoid bacilli in this organ.
- *Courvoisier’s law*: Dilatation of the gallbladder occurs only in extrinsic obstruction of the bile duct like pressure by carcinoma of head of pancreas. Intrinsic obstruction by stones do not cause any dilatation because of associated fibrosis.
- Gallbladder is related to duodenum. The gallstones may penetrate wall of gallbladder and duodenum to get into the lumen of duodenum. These stones travel through the coils of small intestine and may block the narrow ileocaecal junction leading to intestinal obstruction.
- *Calot’s triangle*: Triangular space formed by cystic duct, common hepatic duct and segment-V of right hemiliver forms *Calot’s triangle*. This space contains cystic artery, cystic lymph node and autonomic fibres reaching the gallbladder (Fig. 22.5b)

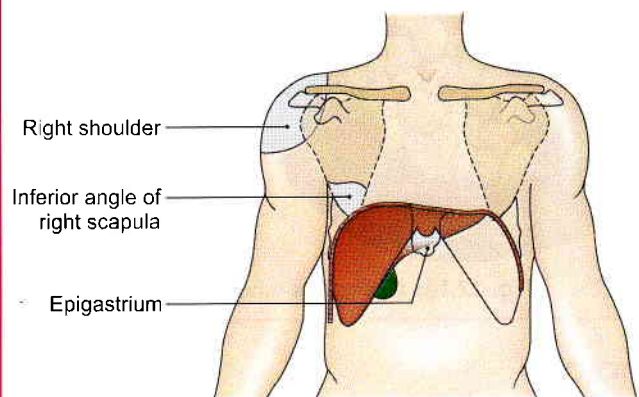


Fig. 22.9: Sites of referred pain due to stretch of bile duct or gallstone

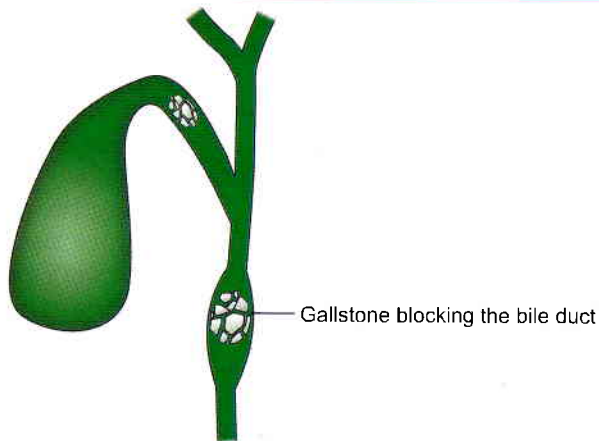


Fig. 22.10: Gallstones blocking the bile duct

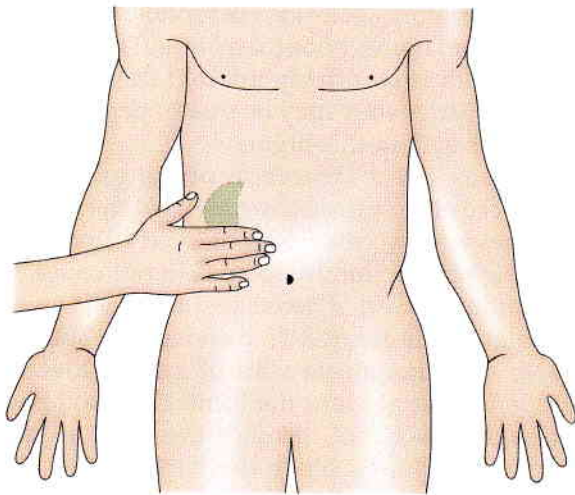


Fig. 22.11: Murphy's sign (cholecystitis)

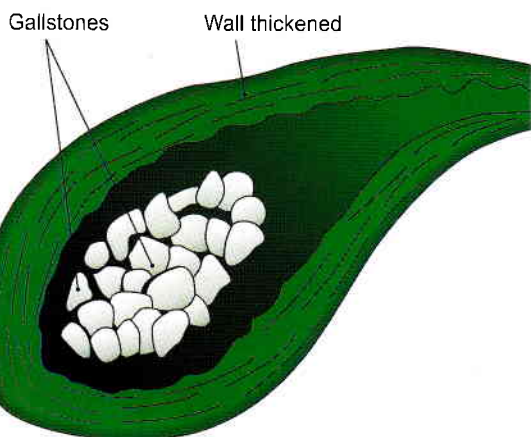


Fig. 22.12: Gallstones (cholelithiasis)

HISTOLOGY

Mucous membrane: It is projected to form folds. Epithelium consists of a single layer of tall columnar cells. Lamina propria contains loose connective tissue.

The fibromuscular coat: It consists of smooth muscle fibres and collagen fibres which rests on an outer fibroareolar coat.

DEVELOPMENT

Hepatic bud arises from the endoderm of caudal part of foregut. The bud elongates cranially. It gives rise to a small bud on its right side. This is called *pars cystica* and the main part is *pars hepatica*. *Pars cystica* forms the gallbladder and the cystic duct, which drains into the common hepatic duct (CHD). *Pars hepatica* forms CHD and divides into right and left hepatic ducts. These ducts reach *septum transversum* and proliferate to form the *hepatic parenchyma*. The entire epithelium is endodermal and other layers are of splanchnic origin.



FACTS TO REMEMBER

- Gallbladder stores as well as concentrates bile. So it is more liable to have gallstones.
- There is lot of variability in the origin of cystic artery as well as in the pattern of joining of cystic duct. This has to be kept in mind during surgery of this region.
- Pain of cholecystitis may be referred to epigastrium, right shoulder and inferior angle of right scapula.

CLINICOANATOMICAL PROBLEMS

Case 1

A fat fair fertile female complains of spasmodic pain in her right hypochondrium radiating to epigastrium and right shoulder.

- What is the reason for pain in right hypochondrium?
- Why does pain radiate to epigastrium and right shoulder?

Ans: The reason for pain is cholecystitis which may or may not be associated with multiple gallstones.

Pain of foregut derived structures is referred to epigastric region, so pain of cholecystitis is referred there. Epigastric region is supplied by T7–T9 nerves. The same nerves gives white ramus communicans to T7–T9 sympathetic ganglia. From these ganglia fibres of greater splanchnic nerve arise, which relay in coeliac ganglion to supply extrahepatic biliary apparatus. Since sympathetic and spinal fibres arise from same segments and reach same segments, pain impulses of viscera is referred to somatic areas.

Right coeliac plexus is joined by right phrenic nerve (C3, C4). It supplies the peritoneum overlying gallbladder. Since peritoneum is inflamed, the impulses are carried to supraclavicular nerves also (C3, C4). So pain is referred to right shoulder.

**Case 2**

During cholecystectomy by open surgery, the surgeon noticed severe bleeding. The bleeding was quickly stopped by treating the bleeding vessel by electrocautery.

- How can one stop bleeding vessel without using clamps?
- What other surgical procedures are available to remove the gallbladder?

Ans: The bleeding of cystic artery can be stopped by compressing the proper hepatic artery between the thumb and index finger, as it lies in the anterior wall of the epiploic foramen.

Cystic artery is a branch of the proper hepatic artery and was treated by electrocautery.

Gallbladder can also be removed by laparoscopic surgery.

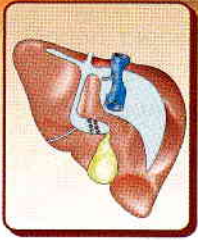
MULTIPLE CHOICE QUESTIONS

1. Cystic artery is a branch of:
a. Right hepatic b. Left hepatic
c. Coeliac trunk d. Common hepatic
2. Range of capacity of gallbladder is:
a. 50–150 ml b. 30–50 ml
c. 150–300 ml d. 350–500 ml
3. Cystic duct mostly joins:
a. Common hepatic duct
b. Right hepatic duct
c. Left hepatic duct
d. None of the above
4. Pain of gallstones is referred to following areas *except*:
a. Tip of right shoulder
b. Epigastric region
c. Inferior angle of left scapula
d. Inferior angle of right scapula
5. Bile duct runs in relation to which part of the duodenum?
a. First part b. Second part
c. Third part d. Fourth part

ANSWERS

1. a 2. b 3. a 4. c 5. a

23



Spleen, Pancreas and Liver

Man may be the captain of his fate, but is also the victim of his blood sugar
—Wilfrid G Oakley

INTRODUCTION

Spleen (Greek *splen* and Latin *Lien*) is a lymphatic organ connected to the blood vascular system. It acts as a filter for blood and plays an important role in the immune responses of the body.

SPLEEN

DISSECTION

Locate the spleen situated deep in the left hypochondrium. The gastrophrenic ligament has already been cut during removal of stomach. Now cut through the posteriorly placed lienorenal ligament taking care of the splenic vessels contained therein. See the close relation of spleen to the left costodiaphragmatic recess and the left lung.

Identify the viscera related to the spleen, e.g. stomach, tail of pancreas, left kidney and splenic flexure of colon.

Trace the branches of splenic artery into the substance of spleen as far as possible.

Cut the phrenicocolic ligament of peritoneum and deliver the spleen from the abdominal cavity.

Location

The spleen (Latin *low spirits*) is a wedge-shaped organ lying mainly in the left hypochondrium, and partly in the epigastrium. It is wedged in between the fundus of the stomach and the diaphragm. The spleen is tetrahedral in shape (Figs 23.1a and b).

Dimensions

The spleen is soft, highly vascular and dark purple in colour. The size and weight of the spleen are markedly variable. On an average the spleen is 1 inch or 2.5 cm thick, 3 inches or 7.5 cm broad, 5 inches or 12.5 cm long,

7 ounces in weight, and is related to 9th to 11th ribs. The odd numbers are 1, 3, 5 are 7, 9, 11. Normally, the spleen is not palpable.

Position (Axis of Spleen)

The spleen lies obliquely along the long axis of the 10th rib. Thus it is directed downwards, forwards and laterally, making an angle of about 45 degrees with the horizontal plane (Fig. 23.2).

EXTERNAL FEATURES

The spleen has two ends, three borders and two surfaces (Fig. 23.3) and 2 angles and hilum.

Two Ends

The *anterior or lateral end* is expanded and is more like a border. It is directed downwards and forwards, and reaches the midaxillary line.

The *posterior or medial end* is rounded. It is directed upwards, backwards and medially, and rests on the upper pole of the left kidney.

Three Borders

The *superior border* is characteristically notched near the anterior end.

The *inferior border* is rounded.

The *intermediate border* is also rounded and is directed to the right.

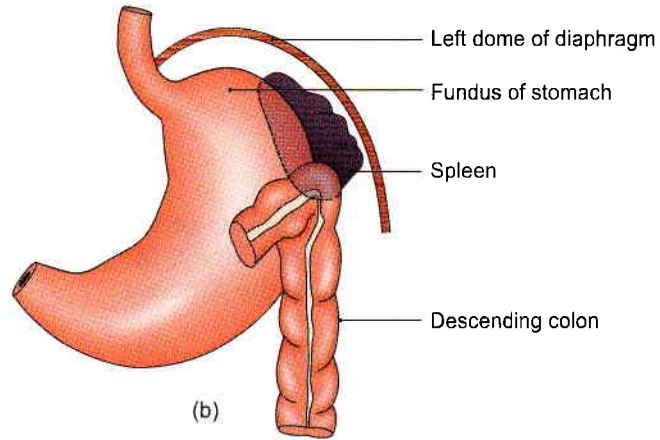
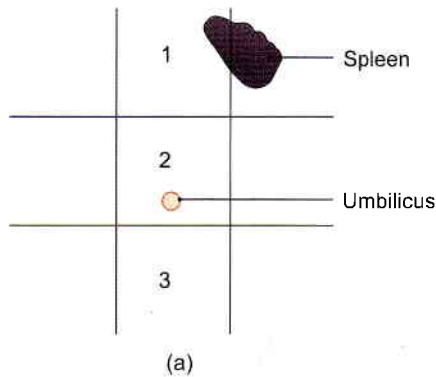
Two Surfaces

The *diaphragmatic surface* is convex and smooth.

The *visceral surface* is concave and irregular.

Two Angles

Anterobasal angle: It is the junction of superior border with lateral or anterior end. It is the most forward projecting part of spleen. When spleen is enlarged, this



Figs 23.1a and b: Location of the spleen: (a) In relation to the nine regions of the abdomen: (1) Epigastrum; (2) umbilical region; and (3) hypogastrum, and (b) in relation to the fundus of the stomach and the diaphragm

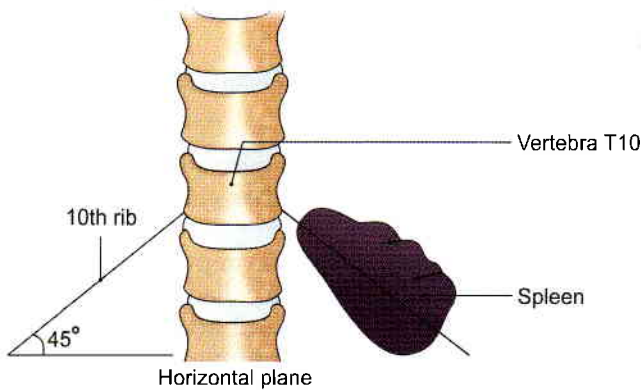


Fig. 23.2: The axis of the spleen corresponds to the long axis of the 10th rib of the left side; it makes an angle of about 45° with the horizontal plane

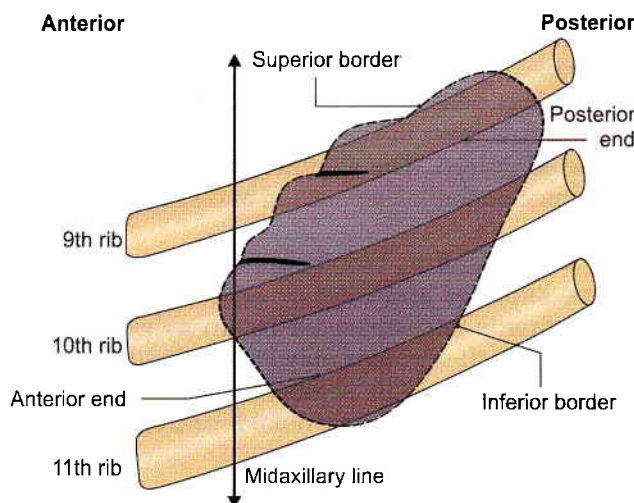


Fig. 23.3: Position of spleen in relation to left 9th–11th ribs—diaphragmatic surface

is felt first, so this is called as “clinical angle of spleen. Posterobasal angle: Junction of inferior border with lateral or anterior end of spleen.

Hilum

Hilum lies between superior and intermediate borders. It is pierced by branches and tributaries of splenic vessels.

Relations

Peritoneal Relations

The spleen is surrounded by peritoneum, and is suspended by following ligaments.

- 1 The *gastrosplenic ligament* extends from the hilum of the spleen to the greater curvature of the stomach. It contains the short gastric vessels and associated lymphatics and sympathetic nerves (see Figs 18.18 and 23.4).
- 2 The *lienorenal ligament* extends from the hilum of the spleen to the anterior surface of the left kidney. It contains the tail of the pancreas, the splenic vessels, and associated pancreaticosplenic lymph nodes, lymphatics and sympathetic nerves.
- 3 The *phrenicocolic ligament* is not attached to the spleen, but supports its anterior end. It is a horizontal fold of peritoneum extending from the splenic flexure of

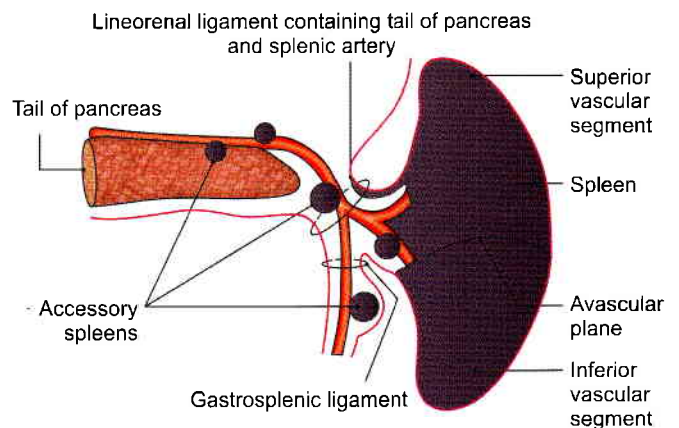


Fig. 23.4: Peritoneal ligaments attached to the spleen, and common sites of accessory spleen



colon to the diaphragm opposite the 11th rib in the midaxillary line. It limits the upper end of the left paracolic gutter (see Fig. 18.28).

Visceral Relations

Visceral surface

The visceral surface is related to the fundus of the stomach, the anterior surface of the left kidney, the splenic flexure of the colon and the tail of the pancreas (Fig. 23.5).

The *gastric impression*, for the fundus of the stomach, lies between the superior and intermediate borders. It is the largest and most concave impression on the spleen (Fig. 23.5).

The *renal impression*, for the left kidney, lies between the inferior and intermediate borders.

The *colic impressions*, for the splenic flexure of the colon, occupies a triangular area adjoining the anterior end of the spleen. Its lower part is related to the *phrenicocolic ligament*.

The *pancreatic impression*, for the tail of the pancreas, lies between the hilum and the colic impression.

The *hilum* lies on the inferomedial part of the gastric impression along the long axis of the spleen. It transmits the splenic vessels and nerves, and provides attachment to the *gastrosplenic and lienorenal ligaments*.

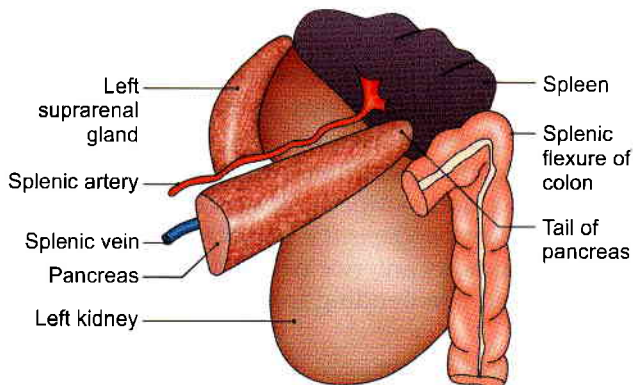


Fig. 23.5: Visceral relations of the spleen

Diaphragmatic surface

The diaphragmatic surface is related to the diaphragm which separates the spleen from the costodiaphragmatic recess of pleura, lung and 9th, 10th and 11th ribs of the left side (Fig. 23.6).

Arterial Supply

The spleen is supplied by the splenic artery which is the largest branch of the coeliac trunk. The artery is tortuous in its course to allow for movements of the spleen. It passes through the lienorenal ligament to

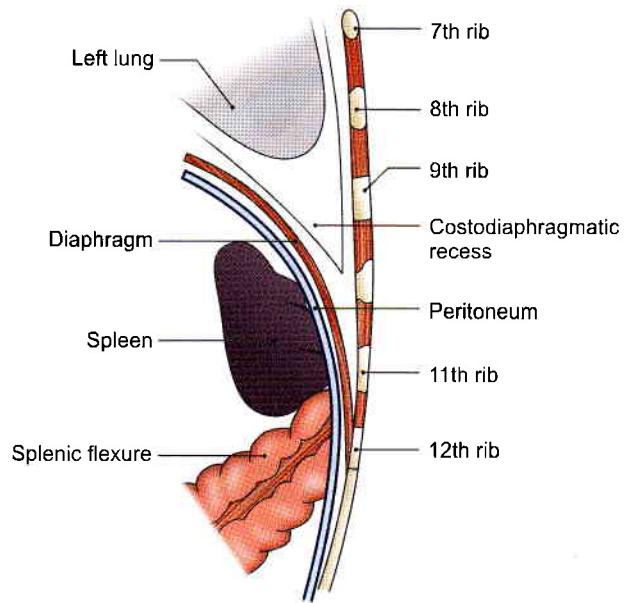


Fig. 23.6: Relations of diaphragmatic surface

reach the hilum of the spleen where it divides into five or more branches. These branches enter the spleen to supply it.

Within the spleen it divides repeatedly to form successively the straight vessels called penicilli, which further divide into ellipsoids and arterial capillaries. Further course of the blood is controversial. According to *closed* theory of splenic circulation, the capillaries are continuous with the venous sinusoids that lie in the red pulp; the sinusoids join together to form veins.

However, according to *open* theory of splenic circulation, the capillaries end by opening into the red pulp from where the blood enters the sinusoids through their walls.

Still others believe in a *compromise* theory, where the circulation is *open* in distended spleen and *closed* in contracted spleen. The splenic circulation is adapted for the mechanism of separation and storage of the red blood cells.

On the basis of its blood supply, the spleen is said to have superior and inferior *vascular segments*. The two segments are separated by an avascular plane (Fig. 23.4). Each segment may be subdivided into one to two disc-like middle segments and a cap-like pole segment. Apart from its terminal branches, the splenic artery gives off:

- Numerous branches to the pancreas;
- 5 to 7 short gastric branches, and
- The left gastroepiploic artery (see Fig. 19.10).

Venous Drainage

The splenic vein is formed at the hilum of the spleen. It runs a straight course behind the pancreas. It joins the

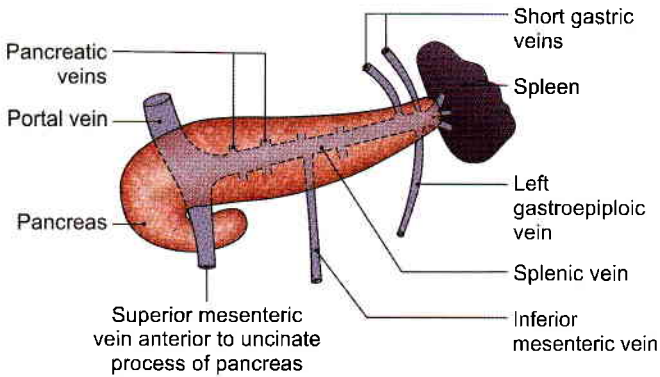


Fig. 23.7: Splenic vein and tributaries

superior mesenteric vein behind the neck of the pancreas to form the portal vein. Its tributaries are the short gastric, left gastroepiploic, pancreatic and inferior mesenteric veins (Fig. 23.7).

Lymphatic Drainage

Splenic tissue proper has no lymphatics. A few lymphatics arise from the connective tissue of the capsule and trabeculae and drain into the *pancreatico-splenic* lymph nodes situated along the splenic artery.

Nerve Supply

Sympathetic fibres are derived from the coeliac plexus. They are vasomotor in nature. They also supply some smooth muscle present in the capsule.

Functions of the Spleen

- 1 **Phagocytosis:** The spleen is an important component of the reticuloendothelial system. The splenic phagocytes include:
 - a. The reticular cells and free macrophages of the red pulp.
 - b. Modified reticular cells of the ellipsoids.
 - c. Free macrophages and endothelial cells of the venous sinusoids, and
 - d. Surface reticular cells of the lymphatic follicle. The phagocytes present in the organ remove cell debris and old and effete RBCs, other blood cells and microorganisms, and thus filter the blood. Phagocytosis of circulating antigens initiates humoral and cellular immune responses.
- 2 **Haemopoiesis:** The spleen is an important haemopoietic organ during foetal life. Lymphopoiesis continues throughout life. The lymphocytes manufactured in it take part in immune responses of the body.

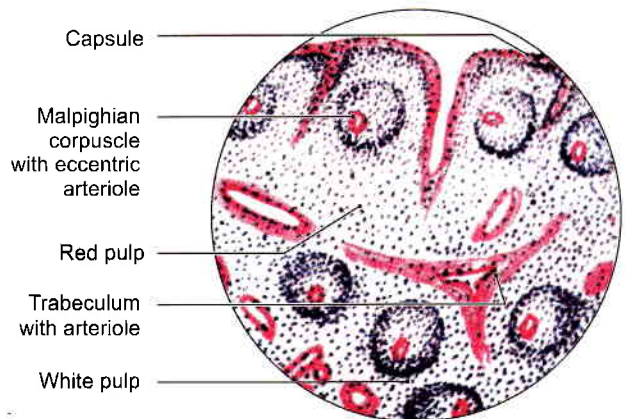
In the adult spleen, haemopoiesis can restart in certain diseases, like chronic myeloid leukaemia and myelosclerosis.

- 3 **Immune responses:** Under antigenic stimulation, there occurs increased lymphopoiesis for cellular responses, and increased formation of plasma cells for the humoral responses.
- 4 **Storage of RBCs:** Red blood cells can be stored in the spleen and released into the circulation when needed. This function is better marked in animals than in man.

HISTOLOGY

Histologically, spleen is made up of the following four component parts.

- 1 Supporting fibroelastic tissue, forming the capsule, coarse trabeculae and a fine reticulum. In human, the smooth muscle cells in the capsule and trabeculae are few, and the contraction and distension of spleen are attributed to constriction or relaxation of the blood vessels, which regulate the blood flow in the organ.
- 2 White pulp consisting of lymphatic nodules arranged around an arteriole called Malpighian corpuscle (Fig. 23.8).
- 3 Red pulp is formed by the collection of cells in the interstices of reticulum, in between the sinusoids. The cell population includes:
 - a. All types of lymphocytes (small, medium and large),
 - b. All three types of blood cells (RBC, WBC and platelets), and
 - c. The fixed and free macrophages. Lymphocytes are freely transformed into plasma cells which can produce large amounts of antibodies the immunoglobulins.
- 4 Vascular system transverses the organ and permeates it thoroughly.



- Peritoneal squamous cells form outer covering
- No differentiation into cortex and medulla
- Red pulp and white pulp seen

Fig. 23.8: Histology of spleen



DEVELOPMENT

Spleen develops in the mesoderm in the cephalic part of left layer of dorsal mesogastrium. The development occurs during sixth week of intrauterine life. Number of nodules develop which soon fuse to form a lobulated spleen (see Fig. 18.6). Notching of the superior border of the adult spleen is an evidence of its multiple origin. These nodules which fail to fuse, form accessory spleens. Figure 23.4 shows the usual sites of accessory spleens.

Accessory Spleens or Spleniculi

These may be found:

- 1 In the derivatives of the dorsal mesogastrium, i.e. gastrosplenic ligament, lienorenal ligament, gastrophrenic ligament and greater omentum.
- 2 In the broad ligament of the uterus.
- 3 In the spermatic cord.

CLINICAL ANATOMY

- *Palpation of the spleen:* A normal spleen is not palpable. An enlarged spleen can be felt under the left costal margin during inspiration. Palpation is assisted by turning the patient to his right side. Note that the spleen becomes palpable only after it has enlarged to about twice its normal size.
- *Splenomegaly:* Enlargement of the spleen is called *splenomegaly* (Fig. 23.9). It may occur in a number of diseases. Sometimes the spleen becomes very large. It then projects towards the right iliac fossa in the direction of the axis of the tenth rib.
- *Splenectomy:* Surgical removal of the spleen is called *splenectomy*. During this operation damage to the tail of the pancreas has to be carefully avoided, as the tail of pancreas is very rich in islets of Langerhans. Spleen has 2 pedicles, gastrosplenic and lienorenal. Their contents are separated carefully before the ligaments are cut (Fig. 23.10).
- *Splenic puncture:* Spleen can be punctured through the 8th or 9th intercostal space in the midaxillary line using a lumbar puncture needle. When enlarged, it can be punctured through the midaxillary line. To avoid laceration of spleen, the patient must hold his breath during the procedure. Intrasplenic pressure is an indirect record of the portal pressure. Splenic venography reveals and confirms the enlarged portosystemic communications in cases of portal hypertension.
- *Splenic infarction:* The smaller branches of splenic artery are end arteries. Their obstruction (embolism) therefore, results in splenic infarction which causes referred pain in the left shoulder (Kehr's sign) (Fig. 23.9).
- Spleen is in danger of trauma to the left lower thoracic cage especially 9, 10, 11th ribs. A ruptured

spleen may cause severe haemorrhage, as it has a rich blood supply.

- *Referred pain:* Pain of splenic tissue is poorly localised. It is also referred to the epigastrium. Stretch of the splenic capsule produces localized pain in the posterior part of left upper quadrant (hypochondrium).
- *Spleen:* If there is a small tear in the spleen, it can be sutured with catgut and the greater omentum can be wrapped round the sutured tear.
- *Partial splenectomy:* Since there are segmental branches of the splenic artery, only one segment can be removed according to the state of spleen.
- After splenectomy, spleen can be cut into small pieces and these can be implanted within the greater omentum. Because of vascularization, spleen survives and does its function of producing the antibodies.

PANCREAS

DISSECTION

Identify the pancreas—a retroperitoneal organ lying transversely across the posterior abdominal wall.

Head is easily identifiable in the concavity of duodenum. Uncinate process of the head is the part behind the upper part of superior mesenteric artery.

Portal vein is formed behind its neck. Rest of the part extending to the left is its body and tail reaching till the hilum of spleen.

Turn the descending part of the duodenum and the head of the pancreas to the left. Look for the posterior pancreaticoduodenal vessels and the bile duct on the head of the pancreas.

Expose the structures posterior to pancreas. Turn the tail and body of the pancreas to the right stripping the splenic artery and vein from its posterior surface and identify the vessels passing to the gland from them.

On the posterior surface of the pancreas, make a cut into the gland parallel to and close to the superior and inferior margins of the body. Pick away the lobules of the gland between the cuts to expose the greyish white duct and the interlobular ducts draining into the main duct.

Features

The pancreas (*pan* = all; *kreas* = flesh) is a gland that is partly exocrine and partly endocrine. The exocrine part secretes the digestive pancreatic juice; and the endocrine part secretes hormones, e.g. insulin. It is soft, lobulated and elongated organ.

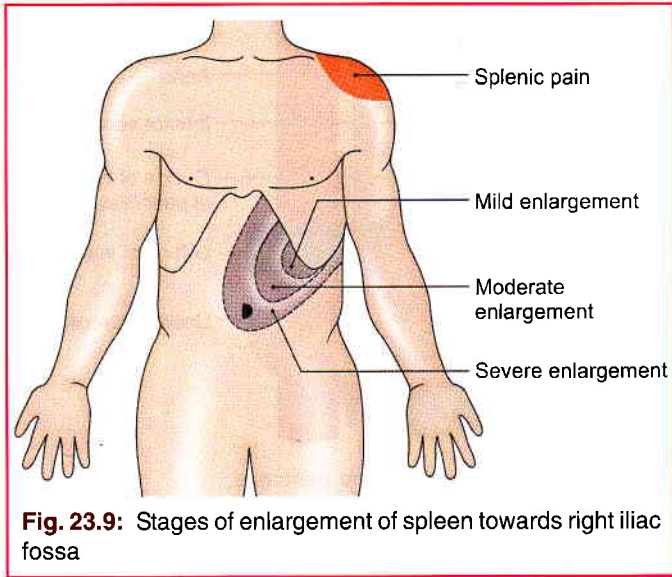


Fig. 23.9: Stages of enlargement of spleen towards right iliac fossa

Location

The pancreas lies more or less transversely across the posterior abdominal wall, at the level of first and second lumbar vertebrae.

Size and Shape

It is J-shaped or retort-shaped, set obliquely. The bowl of the retort represents its head, and the stem of the retort, its neck, body and tail. It is about 15–20 cm long, 2.5–3.8 cm broad and 1.2–1.8 cm thick and weighs about 90 g.

The pancreas is divided (from right to left) into head, neck, body and the tail. The head is enlarged and lies within the concavity of the duodenum. The tail reaches the hilum of the spleen (Fig. 23.11). The entire organ lies posterior to the stomach separated from it by the lesser sac (see Figs 18.17 and 18.18).

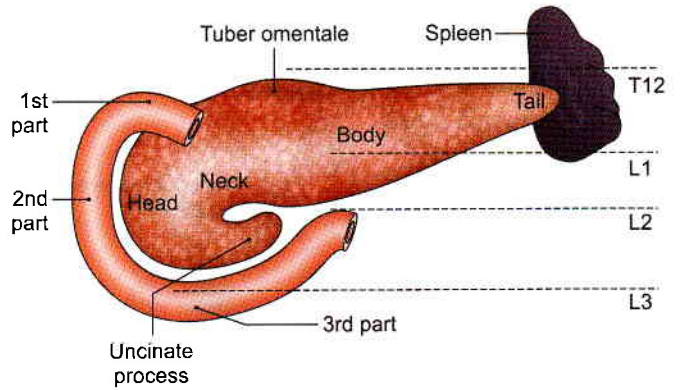


Fig. 23.11: Location of the pancreas and parts of pancreas

HEAD OF THE PANCREAS

Head is the enlarged flattened right end of pancreas, situated within the “C-shaped” curve of the duodenum.

External Features

The head has three *borders*, superior, inferior and right lateral; two *surfaces*, anterior and posterior; and one *process*, called the uncinata process, which projects from the lower and left part of the head towards the left (Fig. 23.11).

Relations

Three Borders

The *superior border* is overlapped by the first part of the duodenum and is related to the superior pancreaticoduodenal artery (Fig. 23.11). The *inferior border* is related to the third part of the duodenum and to the inferior pancreaticoduodenal artery. The *right lateral border* is related to the second part of the duodenum, the terminal part of the bile duct and the anastomosis between the two pancreaticoduodenal arteries.

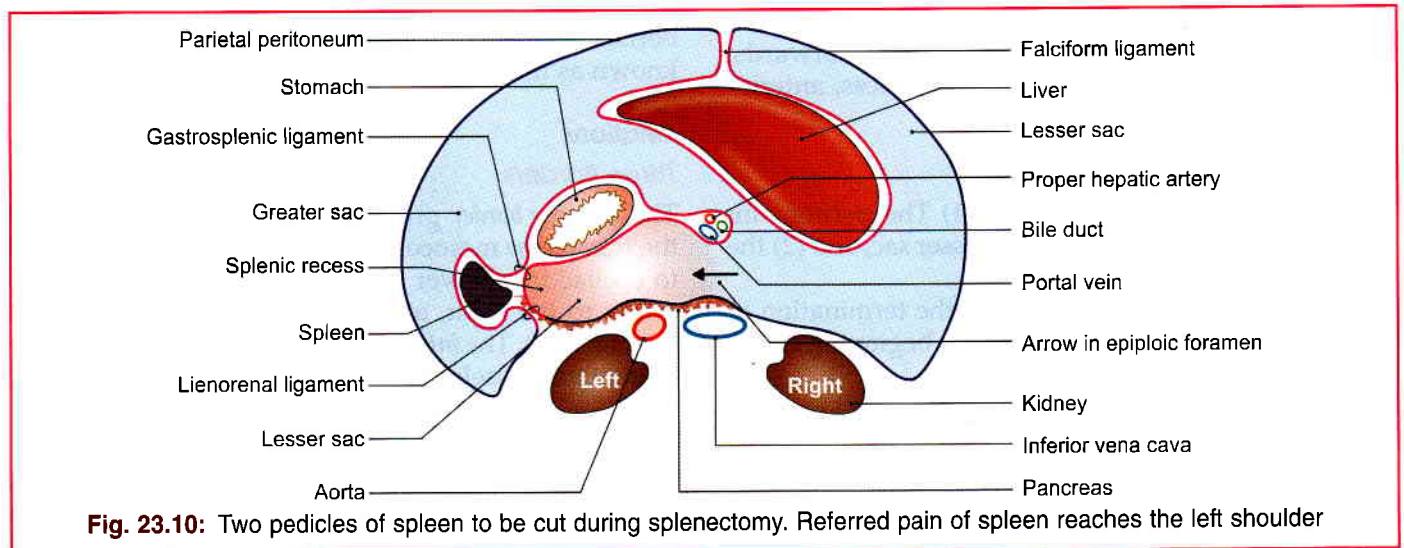
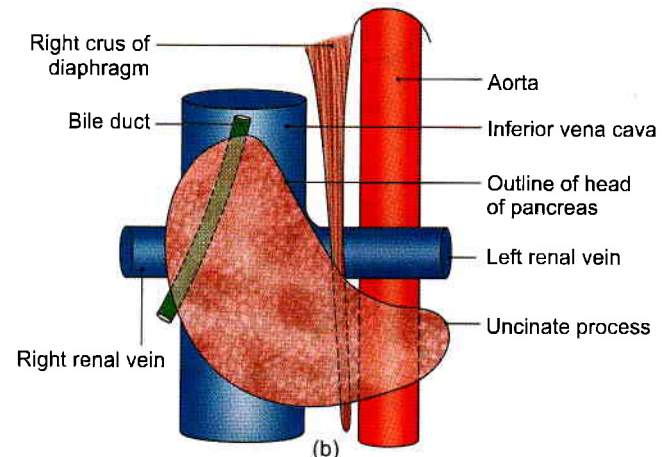
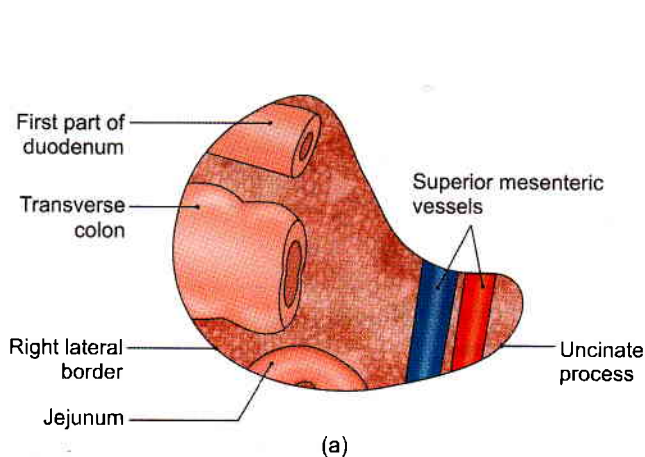


Fig. 23.10: Two pedicles of spleen to be cut during splenectomy. Referred pain of spleen reaches the left shoulder



Figs 23.12a and b: (a) Anterior, and (b) posterior relations of the head of the pancreas

Two Surfaces

The *anterior surface* is related, from above downwards, to:

- 1 The first part of duodenum.
- 2 Transverse colon.
- 3 Jejunum which is separated from it by peritoneum (Fig. 23.12a).

The *posterior surface* is related to:

- 1 Inferior vena cava.
- 2 Terminal parts of the renal veins.
- 3 Right crus of the diaphragm.
- 4 Bile duct which runs downwards and to the right and is often embedded in the substance of pancreas (Fig. 23.12b).

Uncinate Process

It is related anteriorly to the superior mesenteric vessels, and posteriorly to the aorta (Fig. 23.12a).

NECK OF THE PANCREAS

This is the slightly constricted part of the pancreas between its head and body. It is directed forwards, upwards and to the left. It has two surfaces, anterior and posterior.

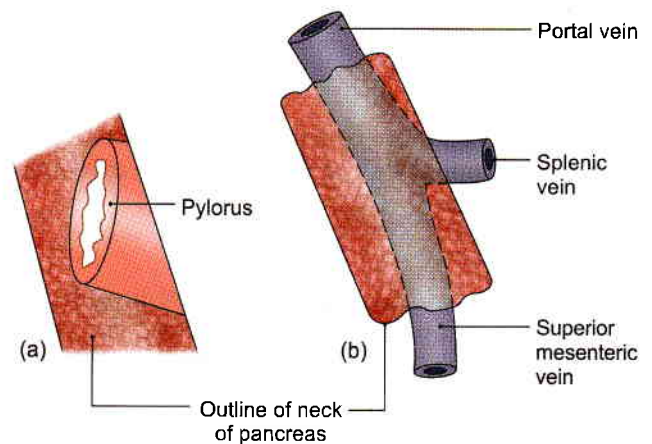
Relations

The *anterior surface* is related to: (1) The peritoneum covering the posterior wall of the lesser sac, and (2) the pylorus (Fig. 23.13a).

The *posterior surface* is related to the termination of the superior mesenteric vein and the beginning of the portal vein (Fig. 23.13b).

BODY OF THE PANCREAS

The body of the pancreas is elongated. It extends from its neck to the tail. It passes towards the left with a slight upward and backward inclination.



Figs 23.13a and b: Relations of the neck of the pancreas: (a) Anterior, and (b) posterior relations

External Features

It is triangular on cross-section, and has three *borders* (anterior, superior and inferior). A part of the body projects upwards beyond the rest of the superior border, a little to the left of the neck. This projection is known as the *tuber omentale*.

Relations

Three Borders

The *anterior border* provides attachment to the root of the transverse mesocolon. The *superior border* is related to coeliac trunk over the tuber omentale, the hepatic artery to the right, and the splenic artery to the left (see Fig. 21.3). The *inferior border* is related to the superior mesenteric vessels at its right end (Fig. 23.14).

Three Surfaces

The *anterior surface* is concave and is directed forwards and upwards. It is covered by peritoneum, and is related to the lesser sac and to the stomach.

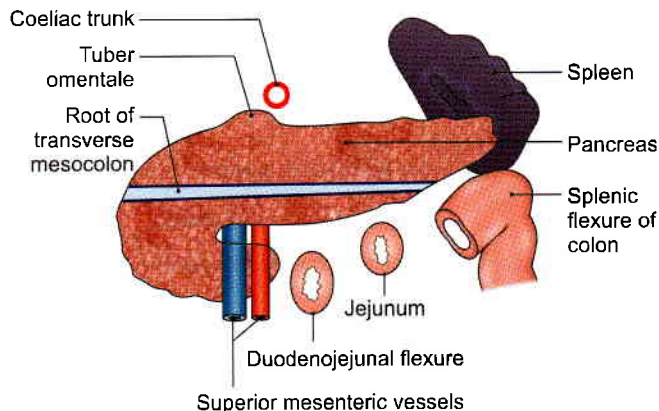


Fig. 23.14: Anterior and inferior relations of the body of the pancreas

The *posterior surface* is devoid of peritoneum, and is related to:

- a. The aorta with the origin of the superior mesenteric artery.
- b. Left crus of the diaphragm.
- c. Left suprarenal gland.
- d. Left kidney.
- e. Left renal vessels.
- f. Splenic vein (Fig. 23.15).

The *inferior surface* is covered by peritoneum, and is related to the duodenojejunal flexure, coils of jejunum and the left colic flexure (Fig. 23.14).

TAIL OF THE PANCREAS

This is the left end of the pancreas. It lies in the lienorenal ligament together with the splenic vessels. It comes into contact with the lower part of the gastric surface of the spleen (Figs 23.4 and 23.5).

DUCTS OF THE PANCREAS

The exocrine pancreas is drained by two ducts, main and accessory (Fig. 23.16).

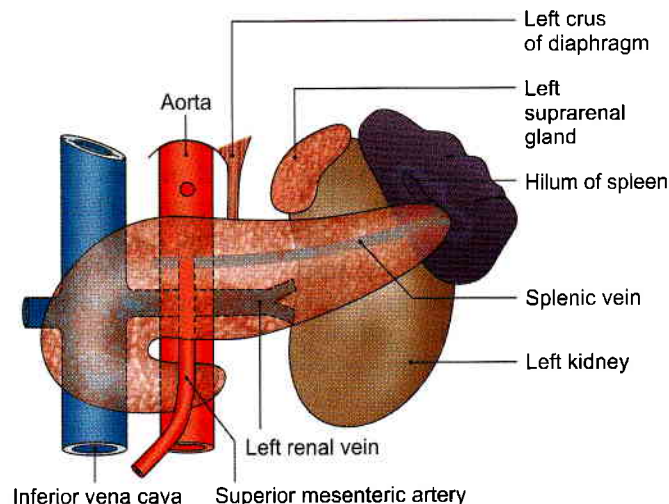


Fig. 23.15: Posterior relations of the body of the pancreas

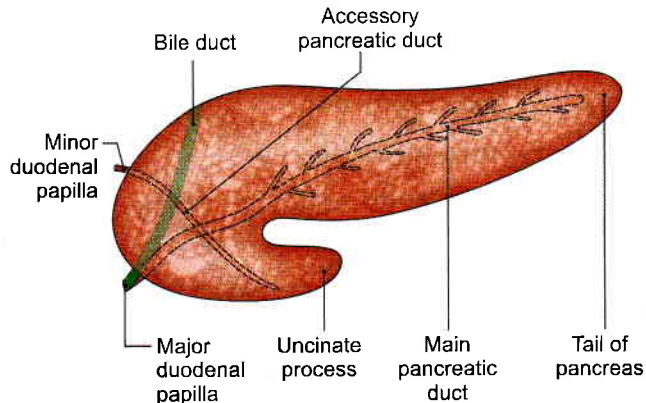


Fig. 23.16: The pancreatic ducts

- 1 The *main pancreatic duct* of Wirsung lies near the posterior surface of the pancreas and is recognised easily by its white colour. It begins at the tail; runs towards the right through the body; and bends at the neck to run downwards, backwards and to the right in the head.
- 2 Its lumen is about 3 mm in diameter.
- 3 It receives many small tributaries which join it at right angles to its long axis forming what has been described as a *herring bone pattern*.
- 4 Within the head of the pancreas the pancreatic duct is related to the bile duct which lies on its right side. The two ducts enter the wall of the second part of the duodenum, and join to form the *hepatopancreatic ampulla* of Vater which opens by a narrow mouth on the summit of the *major duodenal papilla*, 8 to 10 cm distal to the pylorus.
- 5 The *accessory pancreatic duct of Santorini* begins in the lower part of the head, crosses the front of the main duct with which it communicates and opens into the duodenum at the *minor duodenal papilla*. The papilla of accessory pancreatic duct is situated 6 to 8 cm distal to the pylorus. The opening of the accessory duct lies cranial and ventral to that of the main duct. The two ducts remind the double origin of pancreas from the ventral and dorsal pancreatic buds.

Arterial Supply

The pancreas is supplied:

- 1 Mainly by pancreatic branches of the splenic artery,
- 2 The superior pancreaticoduodenal artery, and
- 3 The inferior pancreaticoduodenal artery (Fig. 23.17).

Like the duodenum the pancreas develops at the junction of the foregut and midgut, and is supplied by branches derived from both the coeliac and superior mesenteric arteries.

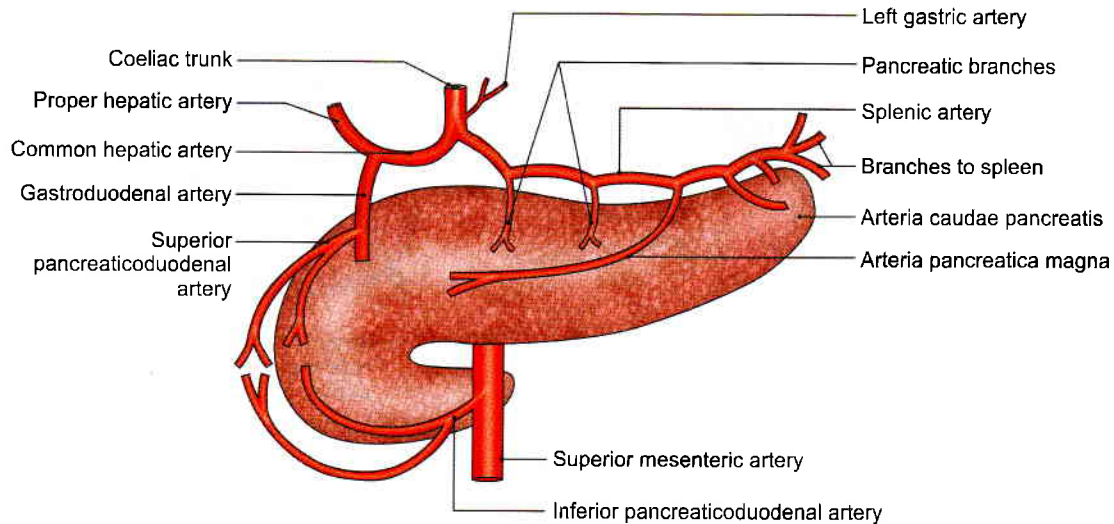


Fig. 23.17: Arterial supply of the pancreas

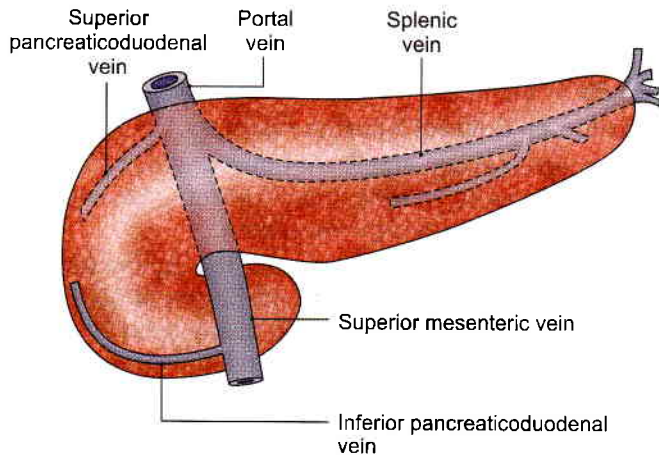


Fig. 23.18: Venous drainage of the pancreas

Venous Drainage

Veins drain into splenic, superior mesenteric and portal veins (Fig. 23.18).

Lymphatic Drainage

Lymphatics follow the arteries and drain into the pancreaticosplenic, coeliac and superior mesenteric groups of lymph nodes.

Nerve Supply

The vagus or parasympathetic and splanchnic sympathetic nerves supply the pancreas through the plexuses around its arteries.

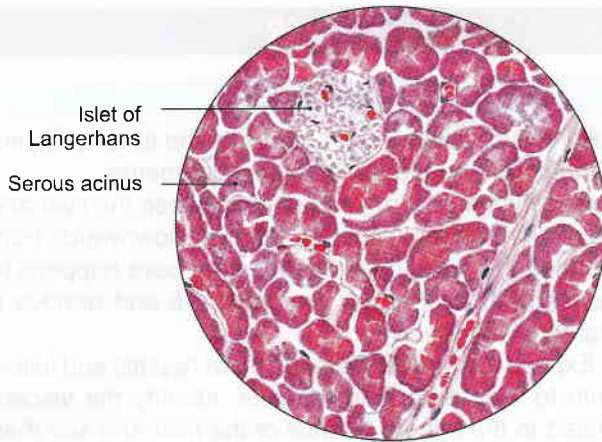
Sympathetic nerves are vasomotor. Parasympathetic nerves control pancreatic secretion. Secretion is also influenced by the hormone cholecystinin produced by cells in the duodenal epithelium. The pancreatic juice contains various enzymes that help in the digestion of proteins, carbohydrates and fats.

Functions

- Digestive:** Pancreatic juice contains many digestive enzymes of which the important ones are as follows: Trypsin breaks down proteins to lower peptides. Amylase hydrolyses starch and glycogen to disaccharides. Lipase breaks down fat into fatty acids and glycerol.
- Endocrine:** Carbohydrates are the immediate source of energy. Insulin helps in utilizations of sugar in the cells. Deficiency of insulin results in hyperglycaemia. The disease is called *diabetes mellitus*. *There appears to be poverty in plenty.*
- Pancreatic juice:** It provides appropriate alkaline medium (pH 8) for the activity of the pancreatic enzymes.

HISTOLOGY

- The exocrine part is a serous gland, made up of tubular acini lined by pyramidal cells with basal round nuclei, containing zymogen granules. It secretes the digestive pancreatic juice.
- The endocrine part of pancreas is made up of microscopic elements called the pancreatic *islets of Langerhans*. These are small isolated masses of cells distributed throughout the pancreas. They are most numerous in the tail. The islets have various types of cells the most important of which are the *beta cells* which are granular and basophilic, forming about 80% of the cell population. They produce insulin. Other types of cells are *alpha cells* with subtype A1 and A2. These are granular and acidophilic and form about 20% of the cell population. A1 cells belong to enterochromaffin group and secrete pancreatic gastrin and serotonin. A2 cells secrete glucagon (Fig. 23.19).



- Acini lined by pyramidal cells
- Lighter islets of Langerhans surrounded by acini
- Islet contains number of capillaries

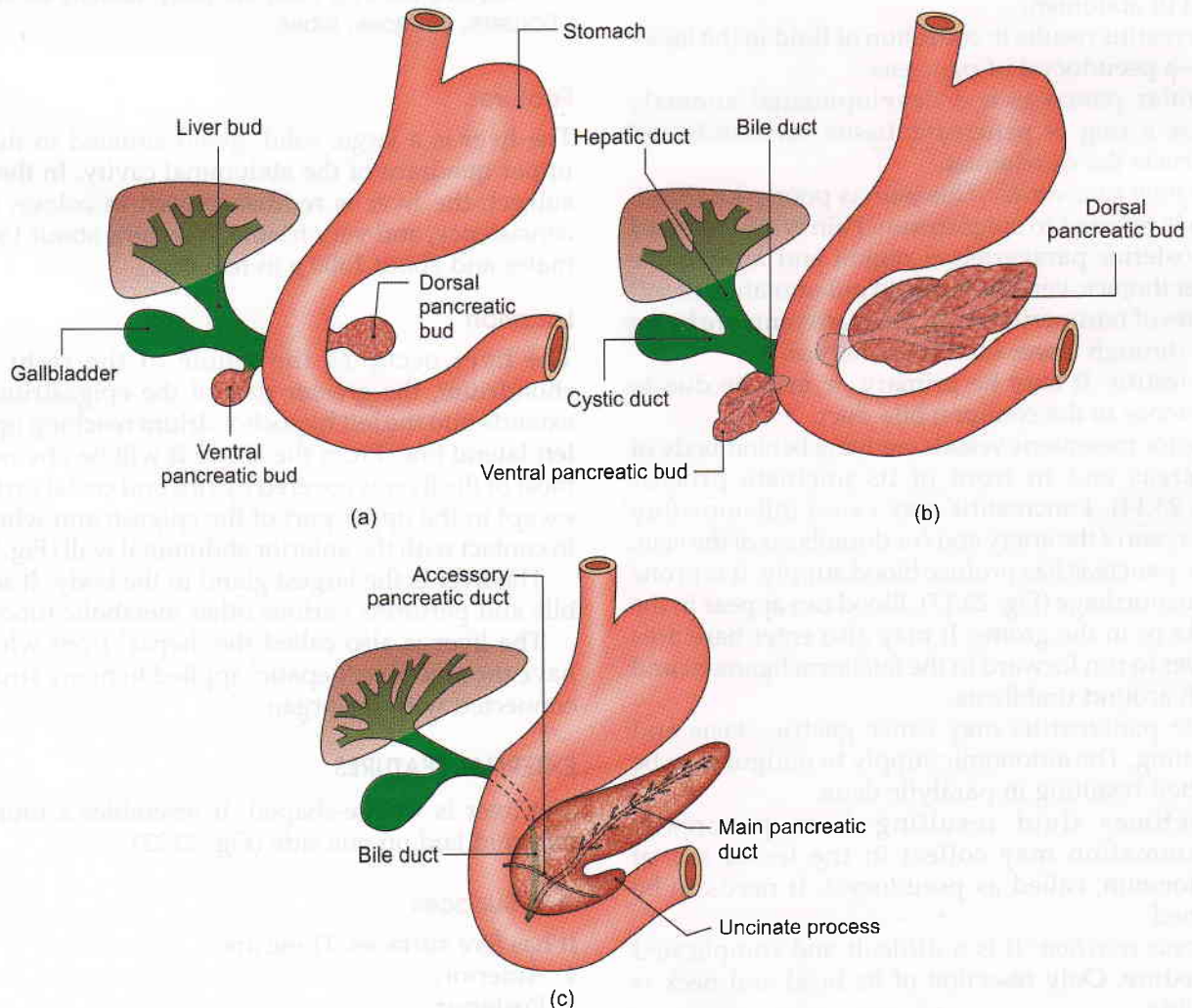
Fig. 23.19: Histology of pancreas**DEVELOPMENT**

It arises as a larger dorsal bud and a smaller ventral bud. These soon fuse to form the pancreas. Ventral bud forms uncinete process and an inferior part of head of pancreas. The dorsal bud forms part of the head, whole of neck, body and tail of pancreas.

The duct of ventral bud taps the duct of dorsal pancreatic bud near its neck and opens into the duodenum as the main pancreatic duct. The proximal part of duct of dorsal pancreatic bud forms the accessory pancreatic duct (Figs 23.20a to c).

Developmental anomalies of the pancreas include the following.

- An *annular pancreas* encircling the second part of the duodenum. An annular pancreas may be the cause of duodenal obstruction.
- Accessory pancreatic tissue* may be present at various sites. These include the wall of the duodenum, the jejunum, the ileum, or of Meckel's diverticulum.

**Figs 23.20a to c:** Stages (a, b and c) of development of pancreas



- c. *Inversion of pancreatic ducts*: In this condition, the accessory duct is larger than the main duct, and the main drainage of the pancreas is through the minor duodenal papilla.

CLINICAL ANATOMY

- Deficiency of insulin causes the disease *diabetes mellitus*.
- Deficiency of pancreatic enzymes causes digestive disturbances.
- *Carcinoma* is common in the head of the pancreas. Pressure over the posteriorly placed bile duct leads to persistent obstructive jaundice. It may press upon the portal vein, causing ascites; or may involve the stomach, causing pyloric obstruction.
- Acute pancreatitis is a serious disease. It may be a complication of mumps.
- Pancreatic cyst presents as a large fixed tumour in the upper part of abdomen along the median plane. They are often symptomless.
- Pancreatic pain is felt in the back as well as in the front of abdomen.
- Pancreatitis results in collection of fluid in the lesser sac—a pseudocyst of pancreas.
- Annular pancreas is a developmental anomaly where a ring of pancreatic tissue surrounds and obstructs the duodenum.
- *Pain from pancreatitis*: This pain is poorly localized. Pain is referred to epigastrium. Pain is also referred to posterior paravertebral region and around the lower thoracic vertebrae, due to inflammation of soft tissues of retroperitoneum. Their afferents are being sent through lower intercostal nerves.
- *Pancreatitis*: It may be primary or may be due to gallstones in the common bile duct.
- Superior mesenteric vessels are lying behind body of pancreas and in front of its uncinata process (Fig. 23.14). Pancreatitis may cause inflammatory aneurysm of the artery and/or thrombosis of the vein.
- Since pancreas has profuse blood supply, it is prone to haemorrhage (Fig. 23.17). Blood can appear in the flanks or in the groins. It may also enter bare area of liver to run forward in the falciform ligament and reach around umbilicus.
- Acute pancreatitis may cause gastric stasis and vomiting. The autonomic supply to midgut may be affected resulting in paralytic ileus.
- Sometimes fluid resulting from pancreatic inflammation may collect in the lesser sac of peritoneum, called as pseudocyst. It needs to be drained.
- *Pancreas resection*: It is a difficult and complicated procedure. Only resection of its head and neck is possible.

LIVER

DISSECTION

Pull the liver downwards and divide the anterior layers of the coronary and left triangular ligaments.

Identify the inferior vena cava between the liver and the diaphragm and separate the liver downwards from inferior vena cava. If the inferior vena cava happens to be deeply buried in the liver, divide it and remove a segment with the liver.

Expose the structures in the porta hepatis and follow them to their entry into the liver. Identify the viscera related to the inferior surface of the liver and see their demarcations on the liver.

Explore the extent of right and left pleural cavities and pericardium related to the superior and anterior surfaces of liver, though separated from it by the diaphragm.

Cut the structures close to the porta hepatis and separate all the peritoneal ligaments and folds of the liver.

Remove the liver from the body. Identify its various borders, surfaces, lobes.

Features

The liver is a large, solid, gland situated in the right upper quadrant of the abdominal cavity. In the living subject, the liver is reddish brown in colour, soft in consistency, and very friable. It weighs about 1600 g in males and about 1300 g in females.

Location

The liver occupies the whole of the right hypochondrium, the greater part of the epigastrium, and extends into the left hypochondrium reaching up to the left lateral line. From the above it will be obvious that most of the liver is covered by ribs and costal cartilages, except in the upper part of the epigastrium where it is in contact with the anterior abdominal wall (Fig. 23.21).

The liver is the largest gland in the body. It secretes bile and performs various other metabolic functions.

The liver is also called the 'hepar' from which we have the adjective 'hepatic' applied to many structures connected with the organ.

EXTERNAL FEATURES

The liver is wedge-shaped. It resembles a four-sided pyramid laid on one side (Fig. 23.22).

Five Surfaces

It has five surfaces. These are:

- 1 Anterior,
- 2 Posterior,
- 3 Superior,

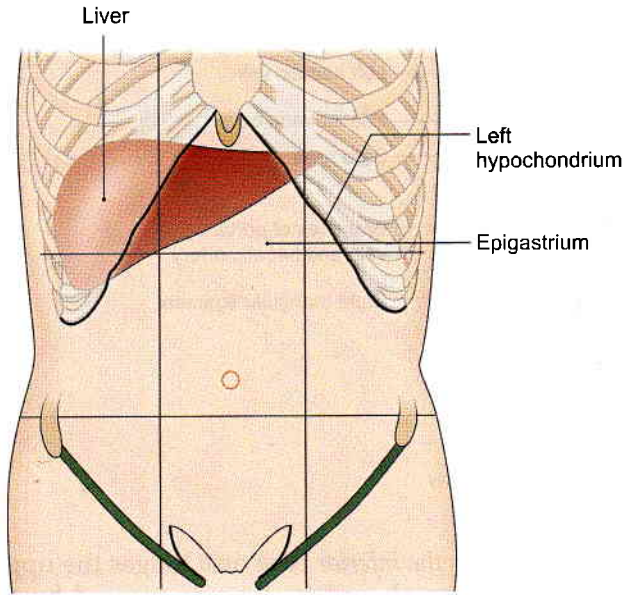


Fig. 23.21: Location of the liver

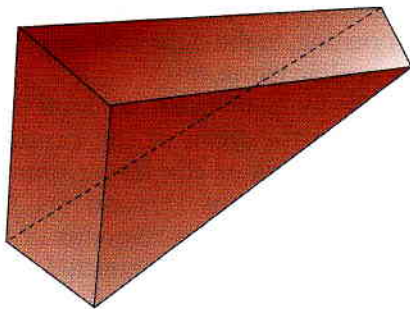


Fig. 23.22: Comparison of the orientation of the surfaces of the liver to those of a four-sided pyramid

- 4 Inferior, and
- 5 Right.

Out of these the inferior surface is well defined because it is demarcated, anteriorly, by a sharp inferior border. The other surfaces are more or less continuous with each other and are imperfectly separated from one another by ill-defined, rounded borders.

One Prominent Border

The *inferior border* is sharp anteriorly where it separates the anterior surface from the inferior surface. It is somewhat rounded laterally where it separates the right surface from the inferior surface. The sharp anterior part is marked by:

- a. An *interlobar notch* or the notch for the *ligamentum teres*.
- b. A *cystic notch* for the fundus of the gallbladder (Fig. 23.23).

In the epigastrium, the inferior border extends from the left 8th costal cartilage to the right 9th costal cartilage.

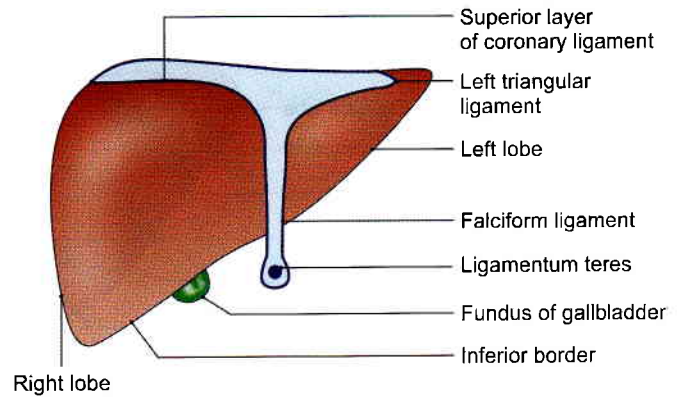


Fig. 23.23: Liver seen from the front

Two Lobes

The liver is divided into right and left lobes by the attachment of the *falciform ligament* anteriorly and superiorly; by the *fissure for the ligamentum teres* inferiorly; and by the *fissure for the ligamentum venosum* posteriorly.

The *right lobe* is much larger than the left lobe, and forms five sixth of the liver. It contributes to all the five surfaces of the liver, and presents the caudate and quadrate lobes.

The *caudate lobe* is situated on the posterior surface. It is bounded on the right by the groove for the *inferior vena cava*, on the left by the fissure for the *ligamentum venosum*, and inferiorly by the *porta hepatis*. Above it is continuous with the superior surface. Below and to the right, just behind the *porta hepatis*, it is connected to the right lobe of the liver by the *caudate process* (Fig. 23.24). Below and to the left it presents a small rounded elevation called the *papillary process*.

The *quadrate lobe* is situated on the inferior surface, and is rectangular in shape. It is bounded anteriorly by the *inferior border*, posteriorly by the *porta hepatis*, on the right by the *fossa for the gallbladder*, and on the left by the *fissure for the ligamentum teres* (Fig. 23.24).

The *porta hepatis* is a deep, transverse fissure about 5 cm long, situated on the inferior surface of the right lobe of the liver. It lies between the caudate lobe above and the quadrate lobe below and in front. The *portal vein*, the *hepatic artery* and the *hepatic plexus of nerves* enter the liver through the *porta hepatis*, while the *right and left hepatic ducts* and a few lymphatics leave it. The relations within; the *porta hepatis* are from behind forwards are the portal vein, the hepatic artery and the hepatic ducts. The lips of the *porta hepatis* provide attachment to the lesser omentum (Fig. 23.24).

The *left lobe* of the liver is much smaller than the right lobe and forms only one-sixth of the liver. It is flattened from above downwards. Near the fissure for the *ligamentum venosum*, its inferior surface presents a rounded elevation, called the *omental tuberosity* or *tuber omentale*.

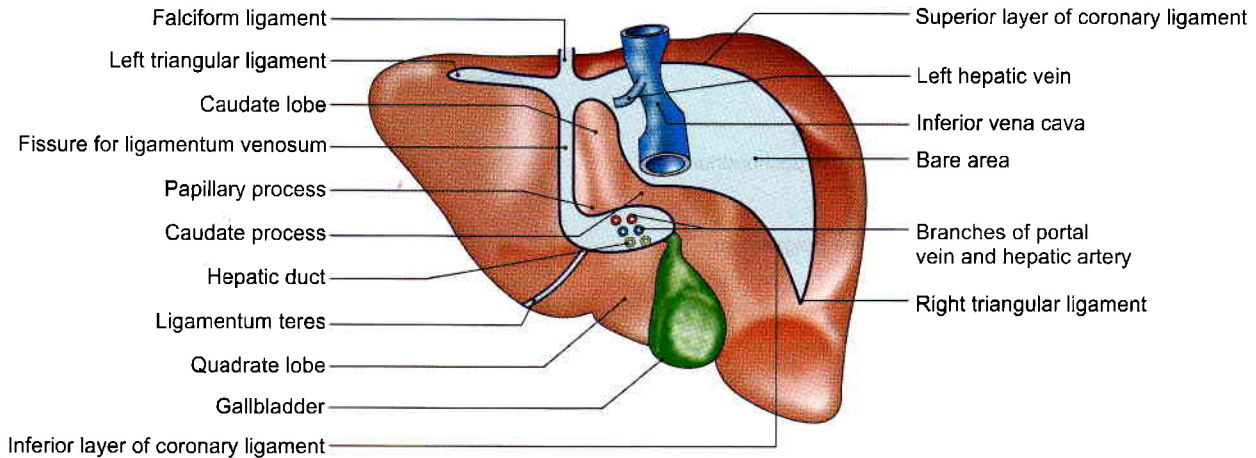


Fig. 23.24: Liver seen from behind and below

Relations

Peritoneal Relations

Most of the liver is covered by peritoneum. The areas not covered by peritoneum are as follows.

- 1 A triangular *bare area*, on the posterior surface of the right lobe, limited by the superior and inferior layers of the coronary ligament and by the right triangular ligament.
- 2 The *groove for the inferior vena cava*, on the posterior surface of the right lobe of the liver, between the caudate lobe and the bare area.
- 3 The *fossa for the gallbladder* which lies on the inferior surface of the right lobe to the right of the quadrate lobe.
- 4 The *lesser omentum* (Fig. 23.23).

Visceral Relations

Anterior Surface

The anterior surface is triangular and slightly convex. It is related to the xiphoid process and to the anterior abdominal wall in the median plane; and to diaphragm on each side. The diaphragm separates this surface from the pleura above the level of a line drawn from the xiphisternal joint to the 10th rib in the midaxillary line; and from the lung above the level of a line from the same joint to the 8th rib. The *falciform ligament* is attached to this surface a little to the right of the median plane (Figs 23.23 and 23.31).

Posterior Surface

The posterior surface is triangular. Its middle part shows a deep concavity for the vertebral column. Other relations are as follows.

- 1 The *bare area* is related to the diaphragm; and to the right suprarenal gland near the lower end of the groove for the inferior vena cava.

- 2 The *groove for the inferior vena cava* lodges the upper part of the vessel, and its floor is pierced by the hepatic veins.
- 3 The *caudate lobe* lies in the superior recess of the lesser sac. It is related to the crura of the diaphragm above the aortic opening, to the right inferior phrenic artery, and to the coeliac trunk.
- 4 The *fissure for the ligamentum venosum* is very deep and extends to the front of the caudate lobe. It contains two layers of the lesser omentum. The ligamentum venosum lies on its floor. The ligamentum venosum is a remnant of the ductus venosus of foetal life; it is connected below to the left branch of the portal vein, and above to the left hepatic vein near its entry into the inferior vena cava (Fig. 23.24).
- 5 The *posterior surface of the left lobe* is marked by the oesophageal impression (Fig. 23.25).

Superior Surface

The superior surface is quadrilateral and shows a concavity in the middle. This is the cardiac impression. On each side of the impression the surface is convex to fit the dome of the diaphragm. The diaphragm separates this surface from the pericardium and the heart in the middle; and from pleura and lung on each side (Fig. 23.30).

Inferior Surface

The inferior surface is quadrilateral and is directed downwards, backwards and to the left. It is marked by impressions for neighbouring viscera as follows.

- 1 On the inferior surface of the left lobe there is a large concave *gastric impression* (Fig. 23.25). The left lobe also bears a raised area that comes in contact with the lesser omentum: it is called the *omentale tuber*.
- 2 The *fissure for the ligamentum teres* passes from the inferior border to the left end of the porta hepatis.

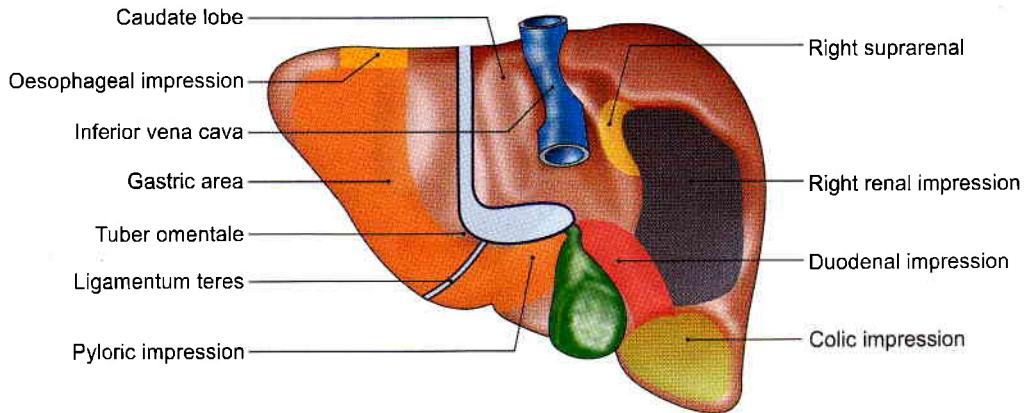


Fig. 23.25: Relations of the inferior surface of the liver

The ligamentum teres represents the obliterated left umbilical vein.

- 3 The *quadrate lobe* is related to the lesser omentum, the pylorus, and the first part of the duodenum. When the stomach is empty the quadrate lobe is related to the first part of the duodenum and to a part of the transverse colon.
- 4 The *fossa for the gallbladder* lies to the right of the quadrate lobe (Fig. 23.25).
- 5 To the right of this fossa the inferior surface of the right lobe bears the *colic impression* for the hepatic flexure of the colon, the renal impression for the right kidney, and the duodenal impression for the second part of the duodenum.

Right Surface

The right surface is quadrilateral and convex. It is related to the diaphragm opposite the 7th to 11th ribs in the midaxillary line. It is separated by the diaphragm from the pleura up to the 10th rib, and from the lung up to the 8th rib. Thus, the upper one-third of the surface is related to the diaphragm, the pleura and the lung; the middle one-third, to the diaphragm and the costodiaphragmatic recess of the pleura; and the lower one-third to the diaphragm alone (Fig. 23.30).

Blood Supply

The liver receives 20% of its blood supply through the hepatic artery, and 80% through the portal vein. Before entering the liver, both the hepatic artery and the portal vein divide into right and left branches. Within the liver, they redivide to form segmental vessels which further divide to form interlobular vessels which run in the portal canals. Further ramifications of the interlobular branches open into the hepatic sinusoids. Thus the hepatic arterial blood mixes with the portal venous blood in the sinusoids. There are no anastomoses between adjoining hepatic arterial territories and hence each branch is an end artery.

Venous Drainage

Hepatic sinusoids drain into interlobular veins, which join to form sublobular veins. These in turn unite to form the hepatic veins which drain directly into the inferior vena cava. These veins provide great support to the liver, besides the intra-abdominal pressure.

The *hepatic veins* are arranged in two groups, upper and lower. The *upper group* consists of three large veins right, left and middle, which emerge through the upper part of the groove for the inferior vena cava, and open directly into the vena cava. These veins keep the liver suspended. The *lower group* consists of a variable number of small veins from the right lobe and the caudate lobe which emerge through the lower part of the caval groove and open into the vena cava.

Microscopically the tributaries of hepatic veins, i.e. central veins are seen as separate channels from those of the portal radicles.

Lymphatic Drainage

The superficial lymphatics of the liver run on the surface of the organ beneath the peritoneum, and terminate in caval, hepatic, paracardial and coeliac lymph nodes. Some vessels from the coronary ligament may directly join the thoracic duct.

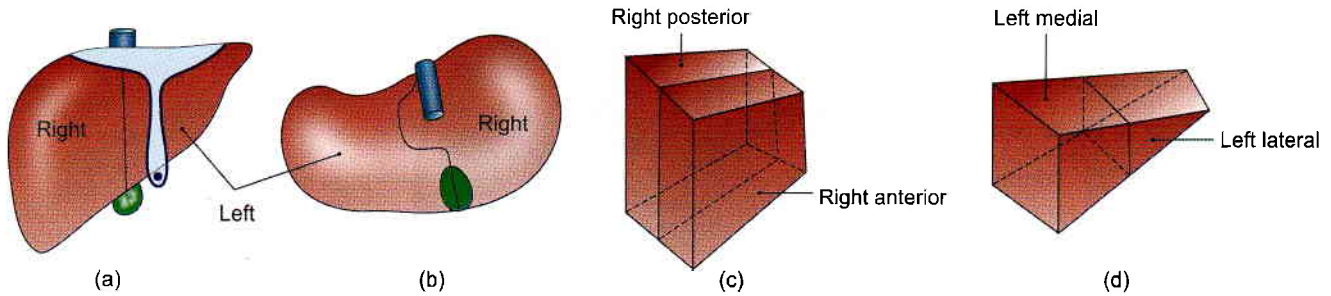
The deep lymphatics end partly in the nodes around the end of the inferior vena cava, and partly in the hepatic nodes.

Nerve Supply

The liver receives its nerve supply from the hepatic plexus which contains both sympathetic and parasympathetic or vagal fibres. Nerves also reach the liver through its various peritoneal ligaments.

HEPATIC SEGMENTS

On the basis of the intrahepatic distribution of the hepatic artery, the portal vein and the biliary ducts, the liver can be divided into the right and left functional



Figs 23.26a to d: The segments (physiological lobes) of the liver. (a) Anterior aspect, (b) inferior aspect, (c) scheme of the right lobe, and (d) scheme of the left lobe

lobes. These do not correspond to the anatomical lobes of the liver. The physiological lobes are separated by a plane passing on the anterosuperior surface along a line joining the cystic notch to the groove for the inferior vena cava. On the inferior surface the plane passes through the fossa for the gallbladder; and on the posterior surface it passes through the middle of the caudate lobe (Figs 23.26a to d).

The right lobe is subdivided into anterior and posterior segments, and the left lobe into medial and lateral segments. Thus there are four segments (Fig. 23.27) in the liver.

- a. Right anterior (V and VIII),
- b. Right posterior (VI and VII),
- c. Left lateral (II and III) and
- d. Left medial (I and IV).

The hepatic segments are of surgical importance. The hepatic veins tend to be intersegmental in their course.

FUNCTIONS

Liver is an indispensable gland of the body.

- 1 *Metabolism* of carbohydrates, fats and proteins;
- 2 *Synthesis* of bile and prothrombin;

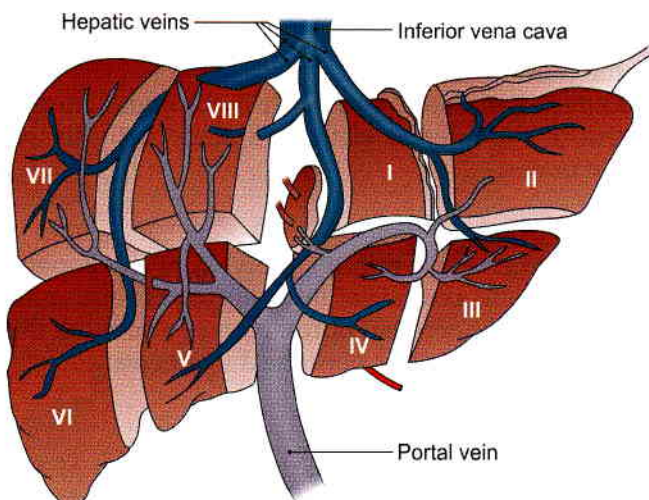


Fig. 23.27: The segments of liver

- 3 *Excretion* of drugs, toxins, poisons, cholesterol, bile pigments and heavy metals;
- 4 *Protective* by conjugation, destruction, phagocytosis, antibody formation and excretion; and
- 5 *Storage* of glycogen, iron, fat, vitamin A and D.

HISTOLOGY

Liver is covered by Glisson's capsule. In the pig there are hexagonal lobules with portal radicles at 3–5 corners. Each radicle contains bile ductule, branch each of portal vein and hepatic artery. Central vein lies in the centre and all around the central vein are the hepatocytes in form of laminae. On one side of the lamina is the sinusoid and on the other side is a bile canaliculus.

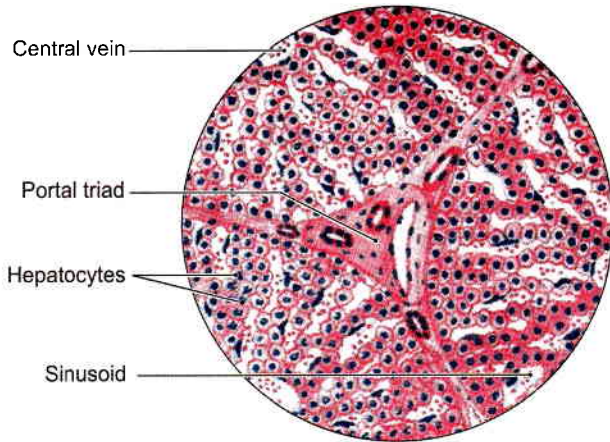
Portal lobule seen in human is triangular in shape with three central veins at the sides and portal tract in the centre.

The liver acinus is defined as the liver parenchyma around a preterminal branch of hepatic arteriole between two adjacent central veins. The liver acinus is the functional unit of liver. Blood reaches the acinus via branches of portal vein and hepatic artery to open into the sinusoids to reach the central vein. On the other hand, the flow of bile is along bile canaliculi, bile ductules and the interlobular bile ducts. Hepatocytes in zone I close to preterminal branch are better supplied by oxygen, nutrients and toxins. The liver cells in zone III close to central veins are relatively hypoxic while cells in zone II are intermediate in oxygen supply.

Histology of the liver can be studied by liver biopsy (Figs 23.28a and b) which is done from right lateral surface.

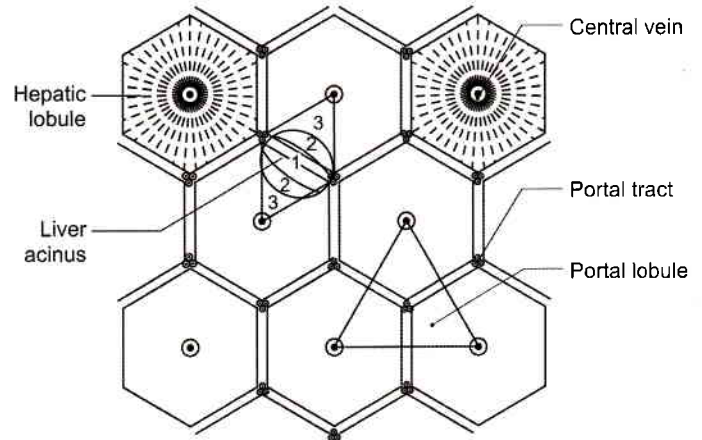
DEVELOPMENT

From the caudal end of foregut, an endodermal hepatic bud arises during 3rd week of development. The bud elongates cranially. It gives rise to a small bud on its right side. This is called *pars cystica* and the main part is *pars hepatica*. *Pars cystica* forms the gallbladder and the cystic duct which drains into common hepatic duct (CHD).



- Numerous hepatocytes with prominent central nuclei
- Portal tract contains branches of hepatic artery, portal vein and bile ductule
- Liver sinusoids lined by Kupffer's cells

(a)



- Hepatic lobule
- Portal lobule
- Three parts of liver acinus(1,2,3)

(b)

Figs 23.28a and b: Histology of liver. (a) Portal lobule, and (b) liver acinus

The epithelial cells of pars hepatica proliferate to form the *parenchyma*. These cells mix up with umbilical and vitelline veins to form *hepatic sinusoids*.

Kupffer's cells and blood cells are formed from the mesoderm of septum transversum.

CLINICAL ANATOMY

- In the infrasternal angle, the liver is readily accessible to examination on percussion, though it is *normally not palpable* due to the normal tone of the recti muscles and the softness of the liver. Normally in the median plane the inferior border of the liver lies on the transpyloric plane, about a hand's breadth below the xiphisternal joint. In women and children this border usually lies at a slightly lower level and tends to project downwards for a short distance below the right costal margin. It enlarges towards right iliac fossa (Fig. 23.29). Spleen also enlarges towards right iliac fossa.
- Inflammation of the liver is referred to as *hepatitis*. It may be infective hepatitis or amoebic hepatitis.
- Under certain conditions, e.g. malnutrition, liver tissue undergoes fibrosis and shrinks. This is called *cirrhosis* of the liver.
- Liver biopsy needs to be done in certain clinical conditions. Liver biopsy needle is passed through right 9th intercostal space. It traverses both pleural and peritoneal cavities (Fig. 23.30).
- Liver is the common site of metastatic tumours. Venous blood from GIT with primary tumour drains via portal vein into the liver.

- Liver receives blood from hepatic artery and portal vein. Both these vessels lie in the free margin of lesser omentum. Bleeding from the liver can be stopped by compressing the free edge of lesser omentum. This is called *Pringles manoeuvre*. If bleeding still continues it is likely that inferior vena cava is also injured.

- *Liver resection:* Liver resection for primary and secondary tumours is done commonly. 80% of liver mass can be removed safely. Liver can regrow to its original size within 6–12 months after resection. Major resections follow the planes between segments and are anatomical.

- *Liver transplantation:* It can be done in patients with end stage liver disease. The implant of the graft requires an inferior caval anastomoses, followed by anastomosis of the portal vein. Finally the arterial and biliary anastomoses are performed.

- Sometimes a right hemiliver comprising segments V to segments VIII can be removed from a healthy donor and transplanted into the needy patient.

- Transjugular intraparenchymal portosystemic shunt (TIPS) for portal hypertension.

In severe portal hypertension, balloon catheters are introduced from internal jugular vein → superior vena cava → inferior vena cava → hepatic veins → liver tissue → portal vein branch.

- Liver cirrhosis causes "caput medusae" at the umbilicus (Fig. 23.31).

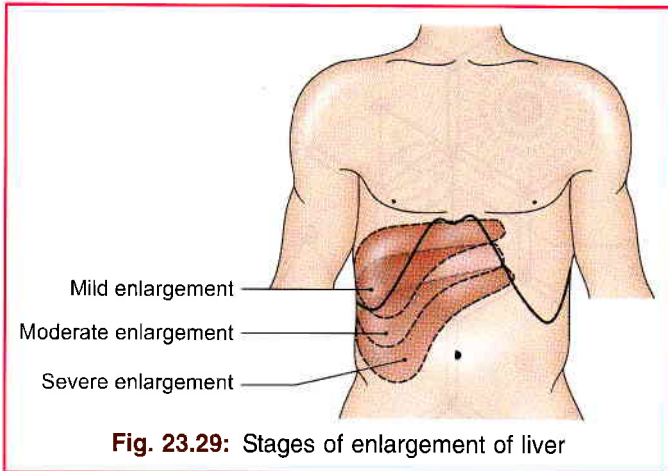


Fig. 23.29: Stages of enlargement of liver

Mnemonics

Spleen: dimensions, weight, surface anatomy

"1, 3, 5, 7, 9, 11"

Spleen dimensions are 1 inch thick, 3 inches wide, 5 inches long.

Weight is 7 ounces.

It underlies ribs 9 to 11.

Structures at porta hepatis

From posterior to anterior side—VAD

V – Portal vein

A – Hepatic artery

D – Hepatic duct



FACTS TO REMEMBER

- Spleen is a collection of lymphoid tissue with lot of blood vessels.
- In case of rupture of spleen it may be removed. Before cutting the lineorenal ligament, the tail of pancreas and splenic vessels need to be identified and not be injured.
- Spleen moves up and down with respiration. It is mesodermal in origin.
- Pancreas mainly develops from dorsal pancreatic bud. Only a part of head and its uncinat process develops from the ventral pancreatic bud.
- Islets of Langerhans are maximum in tail of a pancreas
- Portal vein is formed by the union of splenic and superior mesenteric veins behind the neck of pancreas.
- Liver is the largest gland of the body. Liver is kept in position by the upper and lower groups hepatic veins which drain into the inferior vena cava.
- The bare area of liver is one of the sites of porto-systemic anastomoses.
- There are 8 hepatic segment.
- Liver enlarges downwards right iliac fossa.
- The spleen also enlarges downwards and obliquely towards right iliac fossa. It is prevented from descending to left side by phrenico-colic ligament.

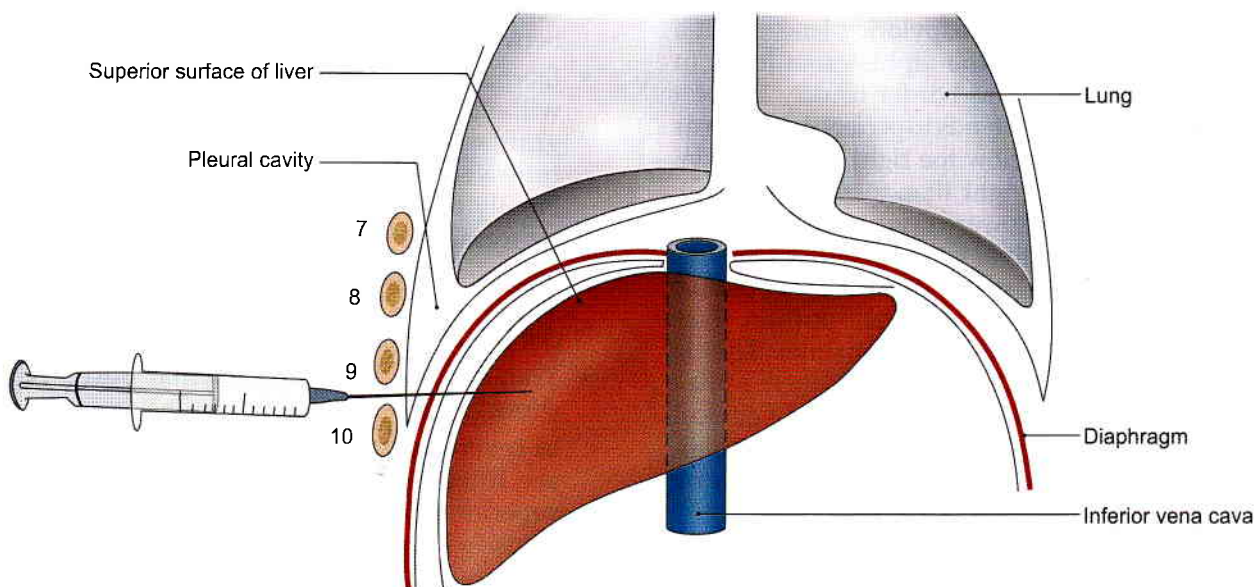


Fig. 23.30: Procedure for liver biopsy (7–10 ribs)

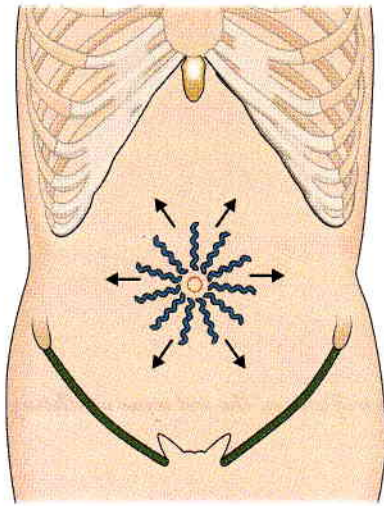


Fig. 23.31: Caput medusae

CLINICOANATOMICAL PROBLEM

A young boy is kicked by his class mate in left upper abdomen. The boy faints due to internal bleeding.

- What organ is likely to be ruptured?
- What precaution is necessary during its removal?

Ans: The young boy's spleen got ruptured leading to internal bleeding. The treatment is to remove the spleen, known as splenectomy.

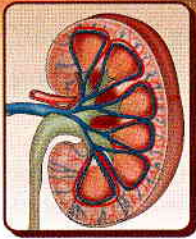
The surgeon has to free the spleen from the ligaments. These being gastrosplenic and lienorenal ligaments. The lienorenal ligament contains splenic artery, splenic vein and tail of pancreas. These structures have to be identified, pulled out of the ligament, before incising the ligament for removal of spleen. The gastrosplenic ligament contains short gastric vessels which also have to be separated before incising the ligament.

MULTIPLE CHOICE QUESTIONS

- Blood supply of liver is:
 - 80% arterial, 20% venous
 - 70% arterial, 30% venous
 - 80% venous, 20% arterial
 - 60% arterial, 40% venous
- Accessory pancreatic duct is also called as:
 - Wirsung duct
 - Santorini duct
 - Henson's duct
 - Hoffmann's duct
- Statements about the bare area of liver are true *except*:
 - It is situated between two layers of coronary ligament
 - Apex is formed by the left triangular ligament
 - It is a site of portosystemic anastomoses
 - There is no visceral peritoneum in this area
- Which of the following structures is not present in the free margin of lesser omentum?
 - Proper hepatic artery
 - Hepatic vein
 - Bile duct
 - Portal vein
- Lineorenal ligament contains all the following structures *except*:
 - Tail of pancreas
 - Splenic vein
 - Splenic artery
 - Renal vein
- Uncinate process of pancreas lies:
 - In front of superior mesenteric vessels
 - Behind superior mesenteric vessels
 - In front of gastroduodenal artery
 - Behind gastroduodenal artery
- Which of the following glands has the presence of centro-acinar cells?
 - Pancreas
 - Parotid
 - Prostate
 - Mammary
- Liver occupies all the following quadrants *except*:
 - Left lumbar
 - Right lumbar
 - Right hypochondriac
 - Left hypochondriac
- Fissure for ligamentum venosum contain two layers of:
 - Greater omentum
 - Falciform ligament
 - Lesser omentum
 - Ligamentum teres
- Ligamentum teres is attached to one of the following veins:
 - Left hepatic
 - Left branch of portal
 - Right branch of portal
 - Right hepatic

ANSWERS

1. c 2. b 3. b 4. b 5. d 6. b 7. a 8. a 9. c 10. b



Kidney and Ureter

What is man but an ingenious machine designed to turn with infinite artfulness, the red wine of Shiraz into urine. ”?

INTRODUCTION

The closely packed structure and numerous functions of the kidney illustrate the beautiful workmanship of our *Creator*. It not only applies to the kidney but to each and every part of our body.

KIDNEY

DISSECTION

Remove the fat and fascia from the anterior surface of left and right kidneys and suprarenal glands. Find left suprarenal vein and left testicular or ovarian vein and trace both to left renal vein. Follow this vein from the left kidney to inferior vena cava and note its tributaries. Displace the vein and expose left renal artery, follow its branches to the left suprarenal gland and ureter. Follow the ureter in abdomen.

Identify the structures related to the anterior surface of both the kidneys. Turn the left kidney medially to expose its posterior surface and note the relation of its vessels and the ureter. Identify the muscles, vessels and nerves which are posterior to the kidneys.

Carry out the same dissection on the right side. Note that the right testicular or ovarian and suprarenal veins drain directly into the inferior vena cava.

Cut through the convex border of the kidney till the hilus. Look at its interior. Identify the cortex, pyramids and calyces.

Follow the ureters in the renal pelvis, in the abdomen, in the pelvic cavity and finally through the wall of urinary bladder.

Synonyms

The kidneys are also called *renes* from which we have the derivative *renal*; and *nephros* from which we have the terms *nephron*, *nephritis*, etc.

Definition

Kidneys are a pair of excretory organs situated on the posterior abdominal wall, one on each side of the vertebral column, behind the peritoneum. They remove waste products of metabolism and excess of water and salts from the blood, and maintain its pH.

Location

The kidneys occupy the epigastric, hypochondriac, lumbar and umbilical regions (Fig. 24.1). Vertically they extend from the upper border of twelfth thoracic vertebra to the centre of the body of third lumbar vertebra. The right kidney is slightly lower than the left, and the left kidney is a little nearer to the median plane than the right.

The transpyloric plane passes through the upper part of the hilus of the right kidney, and through the lower part of the hilus of the left kidney.

Shape, Size, Weight and Orientation

Each kidney is about 11 cm long, 6 cm broad, and 3 cm thick. The left kidney is a little longer and narrower

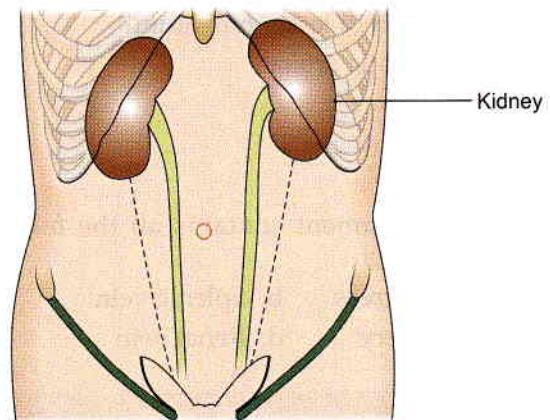
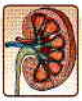

Fig. 24.1: Location of the kidneys



than the right kidney. On an average the kidney weighs 150 g in males and 135 g in females. The kidneys are reddish brown in colour.

The long axis of the kidney is directed downwards and laterally, so that the upper poles are nearer to the median plane than the lower poles (Fig. 24.2). The transverse axis is directed laterally and backwards.

In the foetus the kidney is lobulated and is made up of about 12 lobules. After birth the lobules gradually fuse, so that in adults the kidney is uniformly smooth. However, the evidence of foetal lobulation may persist.

EXTERNAL FEATURES

Each kidney is bean-shaped. It has upper and lower poles, medial and lateral borders, and anterior and posterior surfaces.

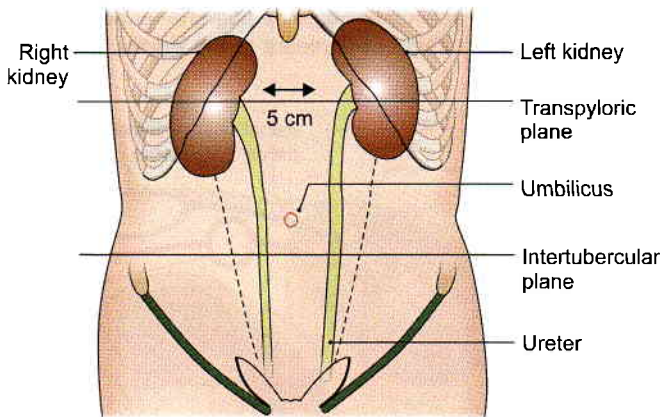


Fig. 24.2: Position of kidneys from anterior aspect

Two Poles of the Kidney

The upper pole is broad and is in close contact with the corresponding suprarenal gland. The lower pole is pointed.

Two Surfaces

The anterior surface is said to be irregular and the posterior surface flat, but it is often difficult to recognize the anterior and posterior aspects of the kidney by looking at the surfaces. The proper way to do this is to examine the structures present in the hilum as described below.

Two Borders

The lateral border is convex. The medial border is concave. Its middle part shows a depression, the hilus or hilum.

Hilum

The following structures are seen in the hilum from anterior to posterior side.

- 1 The renal vein
- 2 The renal artery, and
- 3 The renal pelvis, which is the expanded upper end of the ureter.

Examination of these structures enables the anterior and posterior aspects of the kidney to be distinguished from each other. As the pelvis is continuous inferiorly with the ureter, the superior and inferior poles of the kidney can also be distinguished by examining the hilum. So it is possible to determine the side to which a kidney belongs by examining the structures in the hilum. Commonly, one of the branches of the renal artery enters the hilus behind the renal pelvis, and a tributary of the renal vein may be found in the same plane.

RELATIONS OF THE KIDNEYS

The kidneys are retroperitoneal organs and are only partly covered by peritoneum anteriorly.

Relations Common to the Two Kidneys

- 1 The upper pole of each kidney is related to the corresponding suprarenal gland. The lower poles lie about 2.5 cm above the iliac crests.
- 2 The medial border of each kidney is related to:
 - a. The suprarenal gland, above the hilus, and
 - b. To the ureter below the hilus (Fig. 24.3).
- 3 Posterior relations: The posterior surfaces of both kidneys are related to the following:
 - a. Diaphragm
 - b. Medial and lateral arcuate ligaments
 - c. Psoas major
 - d. Quadratus lumborum
 - e. Transversus abdominis
 - f. Subcostal vessels; and
 - g. Subcostal, iliohypogastric and ilioinguinal nerves (Fig. 24.4).

In addition, the right kidney is related to twelfth rib, and the left kidney to eleventh and twelfth ribs.

- 4 The structures related to the hilum have been described earlier.

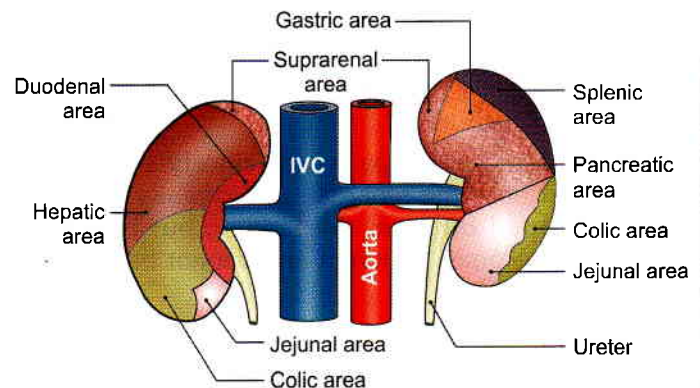


Fig. 24.3: Anterior relations of the kidneys. Areas covered by peritoneum are shaded

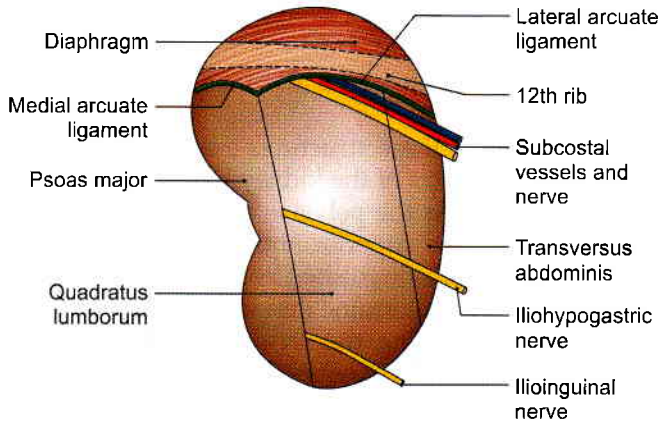


Fig. 24.4: Posterior relations of the right kidney

Other Relations of the Right Kidney

Anterior Relations

- 1 Right suprarenal gland
- 2 Liver
- 3 Second part of duodenum
- 4 Hepatic flexure of colon
- 5 Small intestine.

Out of these the hepatic and intestinal surfaces are covered by peritoneum.

The lateral border of the right kidney is related to the right lobe of the liver and to the hepatic flexure of the colon (Fig. 24.3).

Other Relations of the Left Kidney

Anterior Relations

- 1 Left suprarenal gland
- 2 Spleen
- 3 Stomach
- 4 Pancreas
- 5 Splenic vessels
- 6 Splenic flexure and descending colon
- 7 Jejunum.

Out of these the gastric, splenic and jejunal surfaces are covered by peritoneum.

The lateral border of the left kidney is related to the spleen and to the descending colon.

CAPSULES OR COVERINGS OF KIDNEY

The Fibrous Capsule

This is a thin membrane which closely invests the kidney and lines the renal sinus. Normally it can be easily stripped off from the kidney, but in certain diseases it becomes adherent and cannot be stripped (Figs 24.5 and 24.6).

Perirenal or Perinephric Fat

This is a layer of adipose tissue lying outside the fibrous capsule. It is thickest at the borders of the kidney and fills up the extra space in the renal sinus.

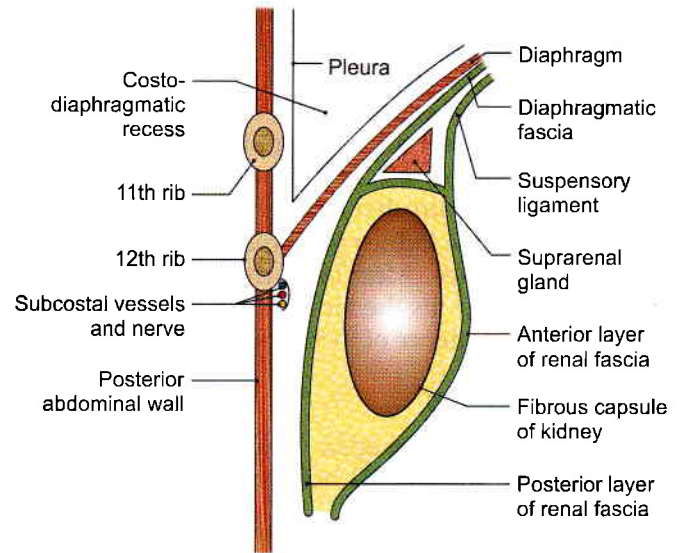


Fig. 24.5: Vertical section through the posterior abdominal wall showing the relationship of the pleura to the kidney

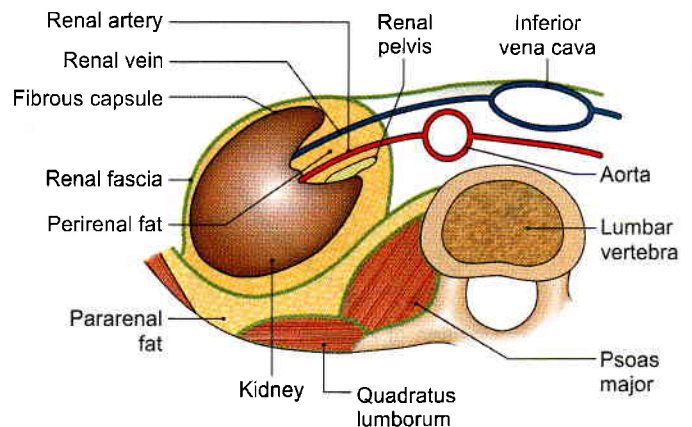


Fig. 24.6: Transverse section through the lumbar region showing the capsules of the kidney

Renal Fascia

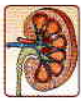The perirenal fascia was originally described as being made up of two separate layers.

Posterior layer was called fascia of Zuckerkandall and anterior layer as fascia of Gerota.

These two fasciae fused laterally to form lateral conal fascia. According to this view, lateral conal fascia continued anterolaterally behind colon to blend with parietal peritoneum.

But lately it has been researched that the fascia is not made up of fused fasciae, but of a single multi-laminated structure which is fused posteromedially with muscular fasciae of psoas major and quadratus lumborum muscles.

The fascia then extends anteromedially behind the kidney as bilaminated sheet, which divides at a variable point into thin layer which courses around the front of



kidney as anterior perirenal fascia and a thicker posterior layer which continues anterolaterally as the lateral conal fascia.

It was believed earlier that above the suprarenal gland the anterior and posterior perirenal fasciae fuse with each other and then get fused to the diaphragmatic fascia, but research presently demonstrates that superior aspect of perirenal space is “open” and is in continuity to the bare area of liver on the right side and with subphrenic extraperitoneal space on the left side.

On the right side at the level of upper pole of kidney, anterior fascia blends with inferior coronary layer and bare area of liver.

On the left side, anterior layer fuses with gastrophrenic ligament.

Posterior layer on both right and left sides fuses with fasciae of muscles of posterior abdominal wall, i.e. psoas major and quadratus lumborum as well as with fascia on the inferior aspect of thoracoabdominal diaphragm.

Medially the anterior layer is continuous from one to the other kidney and the posterior layer is attached either side of vertebra.

Below both the layer extend along the ureter and fuse with iliac fascia.

Pararenal or Paranephric Body (Fat)

It consists of a variable amount of fat lying outside the renal fascia. It is more abundant posteriorly and towards the lower pole of the kidney. It fills up the paravertebral gutter and forms a cushion for the kidney.

STRUCTURE

Naked eye examination of a coronal section of the kidney shows:

- 1 An outer, reddish brown cortex.
- 2 An inner, pale medulla.
- 3 A space, the renal sinus (Fig. 24.7).

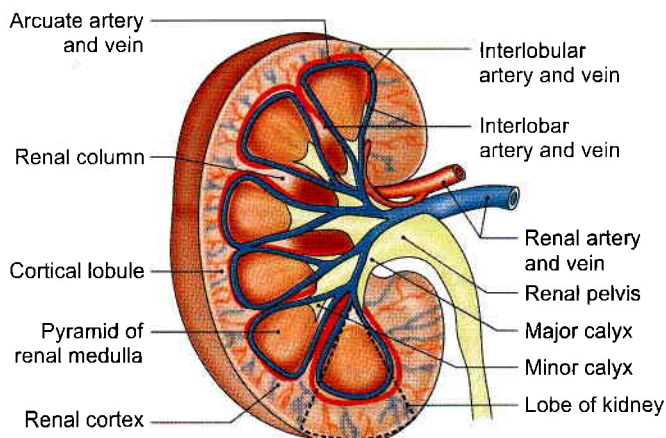


Fig. 24.7: A coronal section through the kidney showing the naked eye structure including the blood supply of the kidney (Fig. 24.9)

The *renal medulla* is made up of about 10 conical masses, called the *renal pyramids*. Their apices form the *renal papillae* which indent the minor calyces.

The *renal cortex* is divisible into two parts.

- a. *Cortical arches* or *cortical lobules*, which form caps over the bases of the pyramids.
- b. Renal columns, which dip in between the pyramids.

Each pyramid along with the overlying cortical arch forms a *lobe* of the kidney.

The *renal sinus* is a space that extends into the kidney from the hilus. It contains:

- a. Branches of the renal artery.
- b. Tributaries of the renal vein.
- c. The renal pelvis. The pelvis divides into 2 to 3 major calyces, and these in their turn divide into 7 to 13 minor calyces. Each minor calyx (*kalyx* = cup of a flower) ends in an expansion which is indented by one to three renal papillae.

Structure of Uriniferous Tubule

Each kidney is composed of one to three million uriniferous tubules. Each tubule consists of two parts which are embryologically distinct from each other. These are as follows.

The *excretory part*, called the *nephron*, which elaborates urine. Nephron is the functional unit of the kidney, and comprises:

- a. *Renal corpuscle* or *Malpighian corpuscle*, (for filtration of substances from the plasma) made up of glomerulus (Latin *ball*) a tuft of capillaries and Bowman’s capsule (Fig. 24.8).
- b. *Renal tubule*, (for selective resorption of substances from the glomerular filtrate) made up of the proximal convoluted tubule, loop of Henle with its descending and ascending limbs, and the distal convoluted tubule (Fig. 24.8).

The *collecting part* begins as a junctional tubule from the distal convoluted tubule. Many tubules unite together to form the ducts of Bellini which open into the minor calyces through the renal papillae.

Juxtaglomerular apparatus is formed at the vascular pole of glomerulus which is intimately related to its own ascending limb of the Henle’s loop near the distal convoluted tubule. The apparatus consists of:

- a. *Macula densa*, formed by altered cells of the tubule.
- b. *Juxtaglomerular cells*, formed by the epithelioid cells in the media of the afferent arteriole.
- c. *Some agranular cells* between macula densa and the glomerulus proper.

VASCULAR SEGMENTS

The renal artery gives 5 segmental branches, 4 from its anterior division and one from its posterior division (Fig. 24.9)

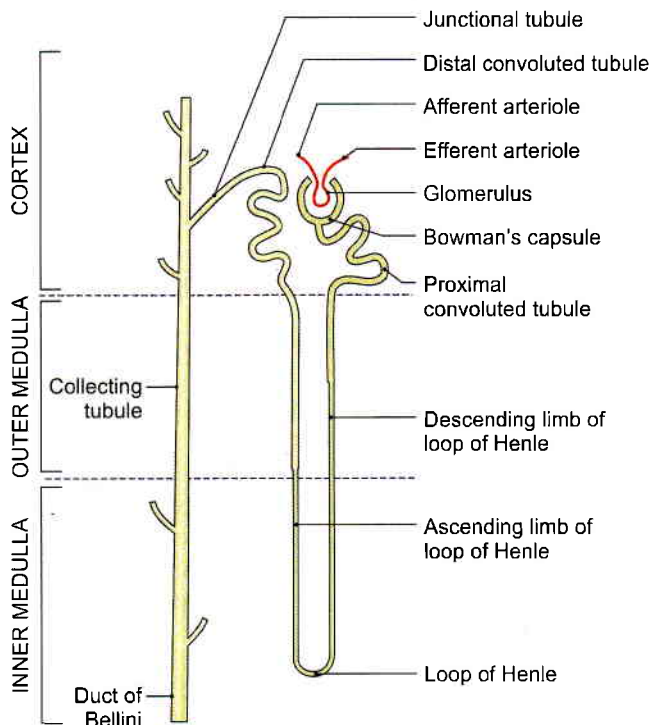


Fig. 24.8: Placement of the uriniferous tubule/nephron in various zones of kidney

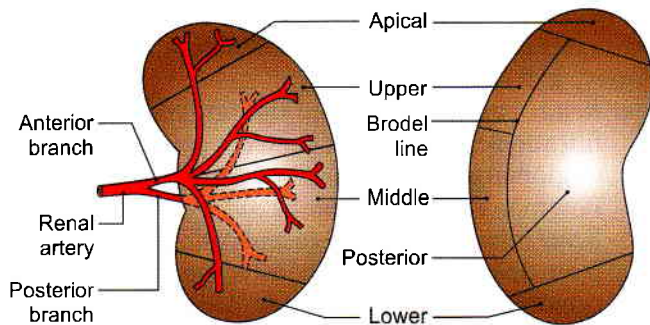


Fig. 24.9: Vascular segments of the kidney as seen in a sagittal section. Big anterior branch supplies four segments and posterior branch supplies only one segment

The segments are apical, upper, middle and lower on anterior aspect. On posterior aspect segments seen are posterior and parts of apical and lower segments.

Blood Supply of Kidney

The blood supply of kidney shown in Flow chart 24.1 and Figs 24.7 and 24.10.

Lymphatic Drainage

The lymphatics of the kidney drain into the lateral aortic nodes located at the level of origin of the renal arteries (L2).

Nerve Supply

The kidney is supplied by the renal plexus, an off shoot of the coeliac plexus. It contains sympathetic (T10–L1)

Flow chart 24.1: Blood supply of kidney

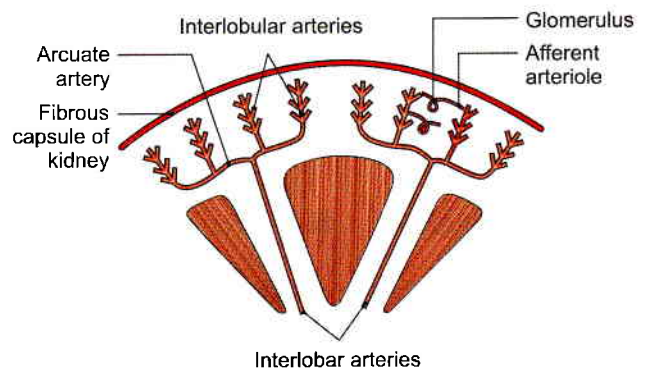
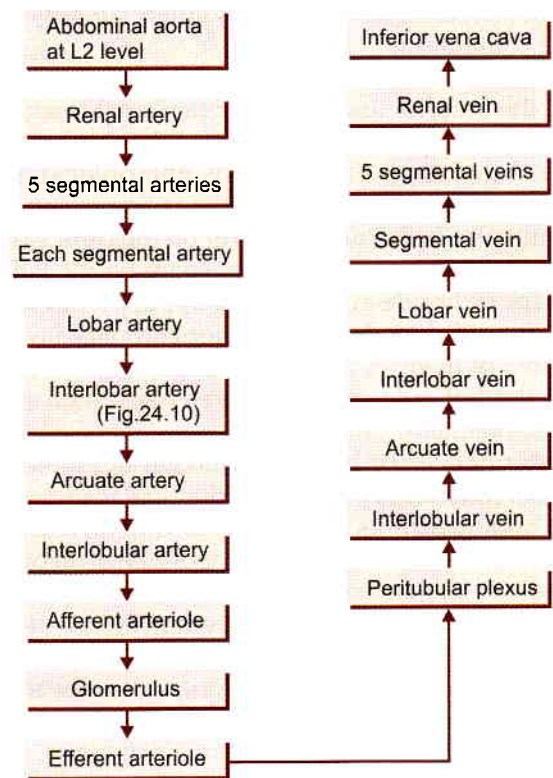


Fig. 24.10: Arrangement of the arteries in the kidney

fibres which are chiefly vasomotor. The afferent nerves of the kidney belong to segments T10 to T12.

EXPOSURE OF THE KIDNEY FROM BEHIND

In exposing the kidney from behind, the following layers have to be reflected one by one (Fig. 24.11).

- 1 Skin
- 2 Superficial fascia
- 3 Posterior layer of thoracolumbar fascia with latissimus dorsi and serratus posterior inferior
- 4 Erector spinae, which can be removed for convenience
- 5 Middle layer of thoracolumbar fascia
- 6 Quadratus lumborum
- 7 Anterior layer of thoracolumbar fascia in which the related nerves are embedded.

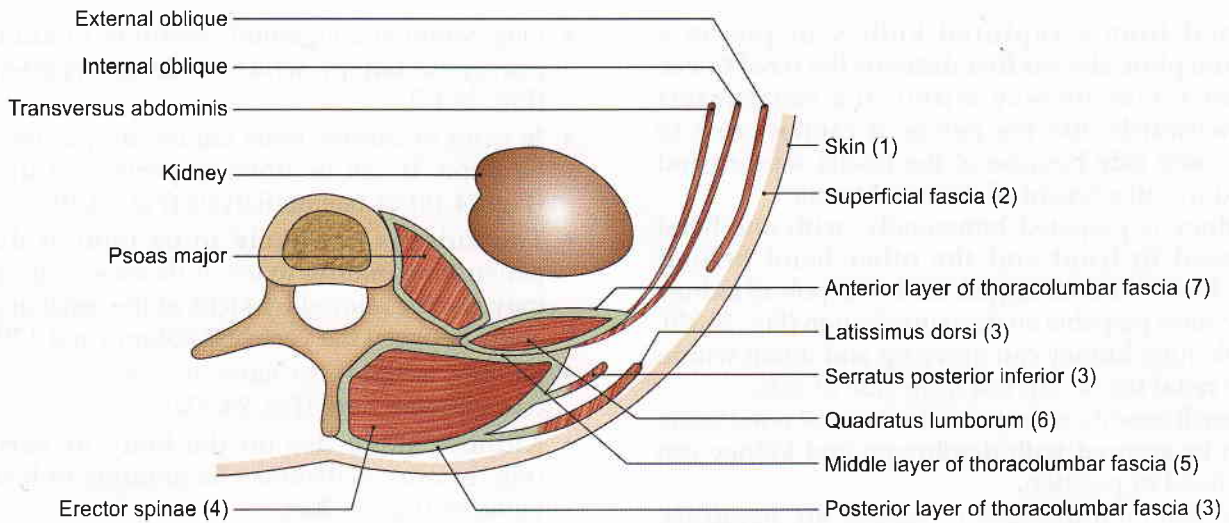
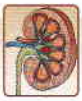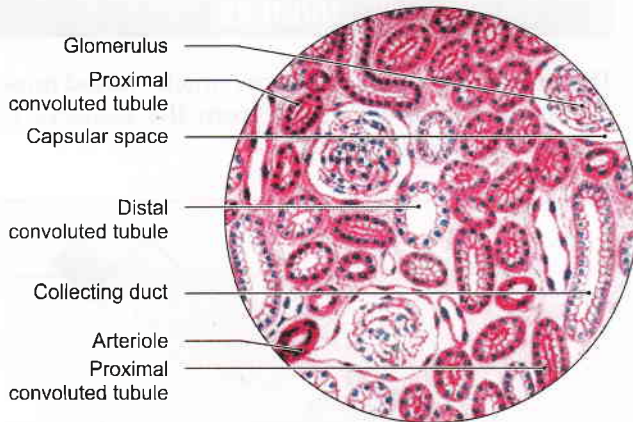
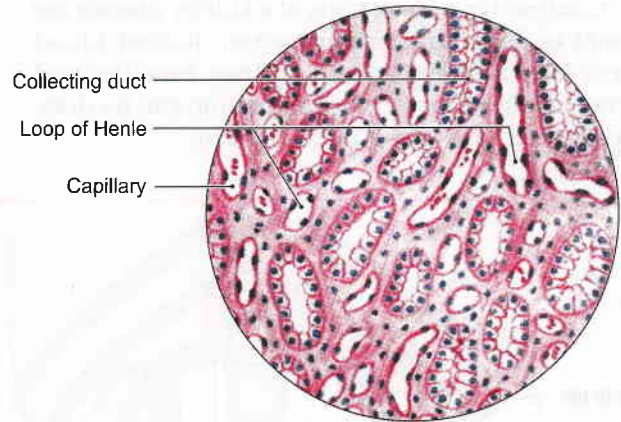


Fig. 24.11: Transverse section through the upper lumbar region showing the layers of thoracolumbar fascia encountered during exposure of the kidney from behind



- Glomerulus is a characteristic feature
- Proximal and distal convoluted tubules
- Collecting ducts

(a)



- Section of renal medulla
- Lots of section of loop of Henle
- Numerous capillaries

(b)

Figs 24.12a and b: Histology of the kidney: (a) Cortex, and (b) medulla

HISTOLOGY

The cortex of kidney shows cut sections of glomeruli, many sections of proximal convoluted tubule, some sections of distal convoluted tubule and few collecting ducts.

Section through the pyramid of the medulla shows light staining collecting ducts, sections of loop of Henle, thick and thin segments of descending and ascending limbs, capillaries and connective tissue (Figs 24.12a and b).

CLINICAL ANATOMY

- In surgical exposures of the kidney, when sometimes the 12th rib is resected for easier delivery of the kidney, *danger of opening the pleural*

cavity must be borne in mind. The lower border of the pleura lies in front of the 12th rib and behind the diaphragm. The order of structures from anterior to posterior side being diaphragm, pleura and rib. When the 12th rib is absent or is too short to be felt, the 11th rib may be mistaken for the 12th, and the chances of opening the pleural cavity are greatly increased (Fig. 24.13). Lithotripsy has replaced conventional method to some degree.

- The angle between the lower border of the 12th rib and the outer border of the erector spinae is known as the *renal angle*. It overlies the lower part of the kidney. Tenderness in the kidney is elicited by applying pressure over this angle, with the thumb (Fig. 24.14).



- Blood from a ruptured kidney or pus in a perinephric abscess first distends the renal fascia, then forces its way within the renal fascia downwards into the pelvis. It cannot cross to opposite side because of the fascial septum and midline attachment of the renal fascia.
- Kidney is palpated bimanually, with one hand placed in front and the other hand behind the flank. When enlarged, the lower pole of kidney becomes palpable on deep inspiration (Fig. 24.15).
- A floating kidney can move up and down within the renal fascia, but not from side to side.
- In such condition the posterior layer of renal fascia can be sutured with diaphragm and kidney can be fixed in position.
- The common diseases of kidney are nephritis, pyelonephritis, tuberculosis of kidney, renal stones and tumours.

Common manifestations of a kidney disease are renal oedema and hypertension. Raised blood urea indicates suppressed kidney function and renal failure. Kidney transplantation can be done in selected cases (Figs 24.16a and b).

- One common congenital condition of kidney is polycystic kidney which leads to hypertension (Fig. 24.17).
- In cases of chronic renal failure dialysis needs to be done. It can be done as peritoneal dialysis (Fig. 24.18) or haemodialysis (Fig. 24.19).
- The kidneys are likely to be injured due to penetrating injuries to lower thoracic cage. These may also be injured by kicks in the renal angle—angle between the vertebral column and 12th rib.
- Kidney is likely to have stones as urine gets concentrated here (Fig. 24.20a).
- Kidneys stone lies on the body of vertebra (Fig. 24.20b). Gallstones lie anterior to body of vertebra (Fig. 24.20c).

URETERS

The ureters are a pair of narrow, thick-walled muscular tubes which convey urine from the kidneys to the urinary bladder (Fig. 24.21).

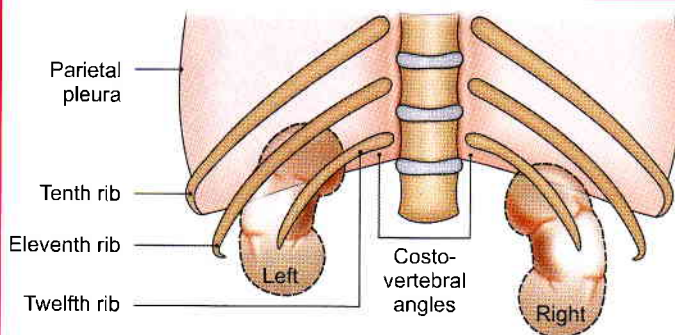


Fig. 24.13: Relation of twelfth rib to pleural cavity, diaphragm and kidney

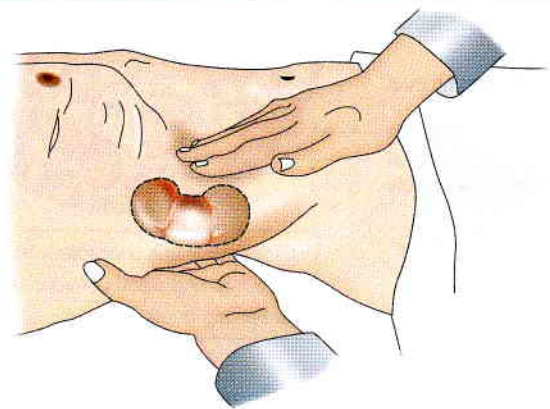


Fig. 24.15: Bimanual palpation of the kidney

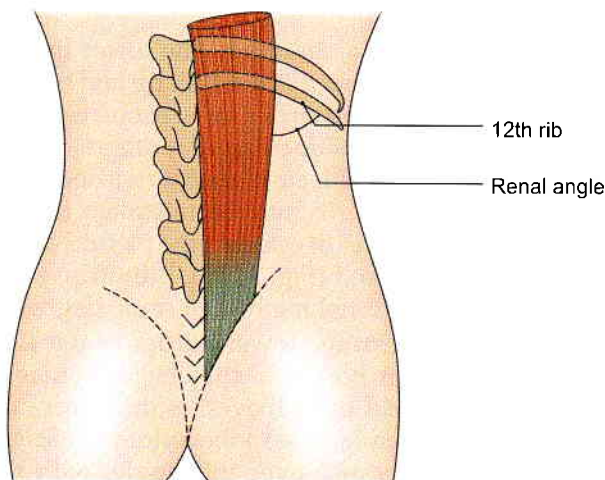
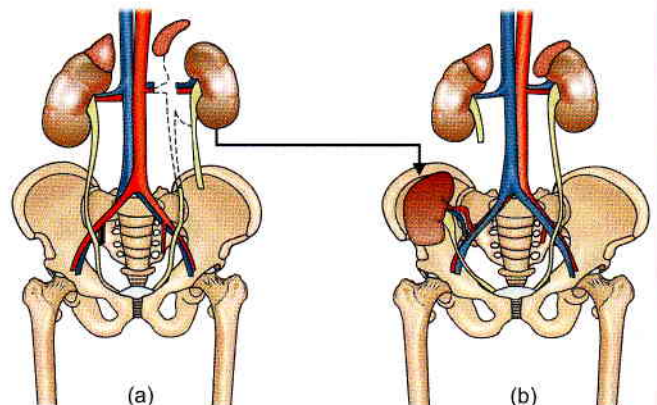


Fig. 24.14: Renal angle



Figs 24.16a and b: (a) Donor's left kidney transplanted, and (b) recipient's right kidney

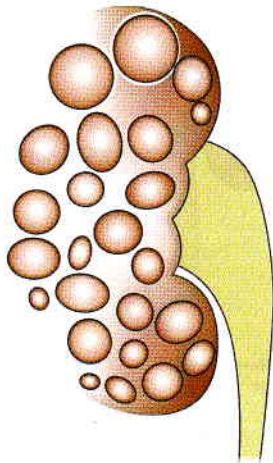


Fig. 24.17: Polycystic kidney

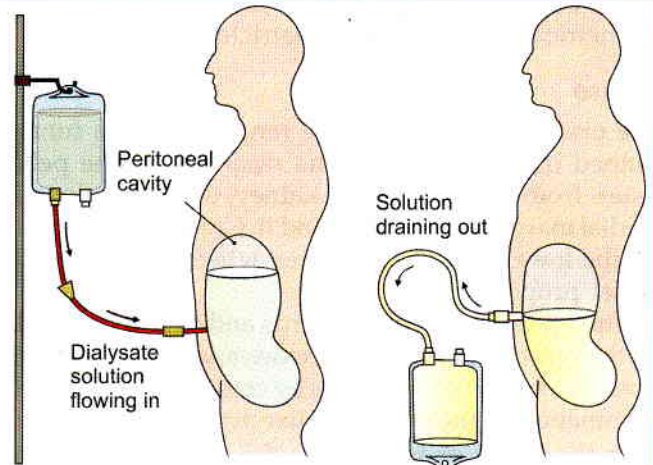


Fig. 24.18: Peritoneal dialysis

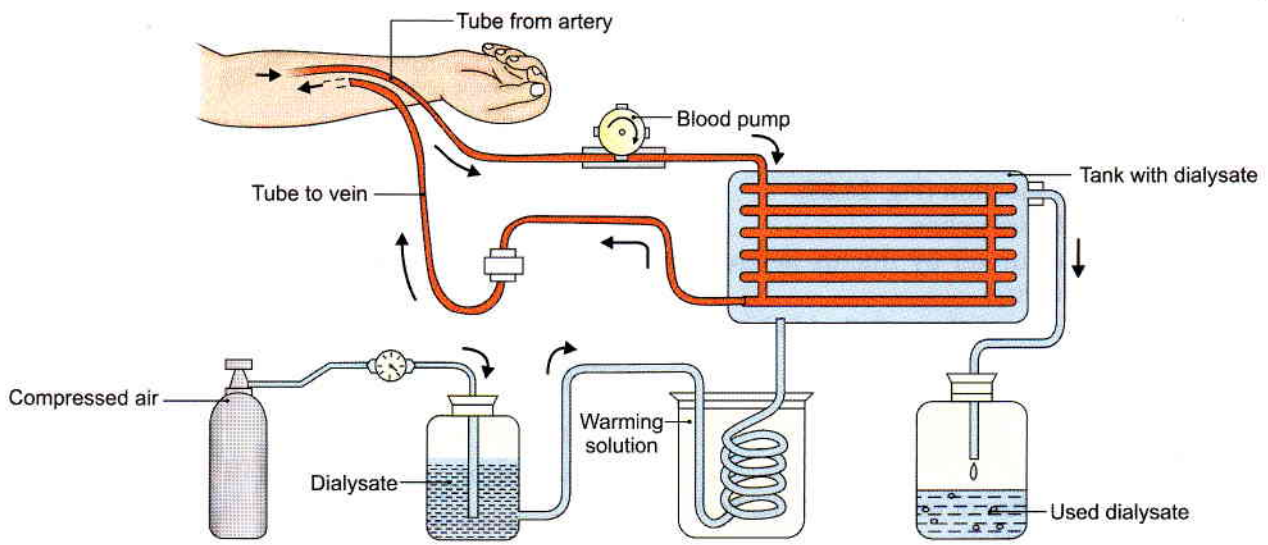
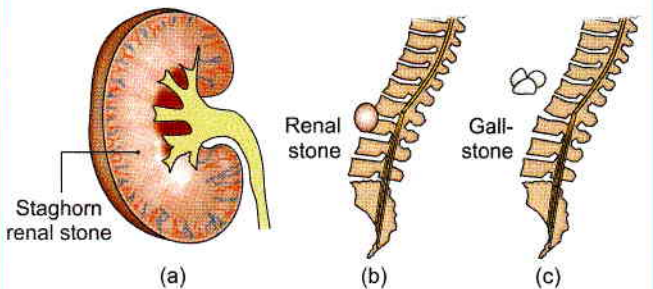


Fig. 24.19: Haemodialysis



Figs 24.20a to c: (a) Staghorn renal stone, (b) renal stone on the body of vertebra, and (c) gallstone anterior to the vertebra

They lie deep to the peritoneum, closely applied to the posterior abdominal wall in the upper part, and to the lateral pelvic wall in the lower part.

DIMENSIONS

Each ureter is about 25 cm (10 inches) long, of which the upper half (5 inches) lies in the abdomen, and the lower

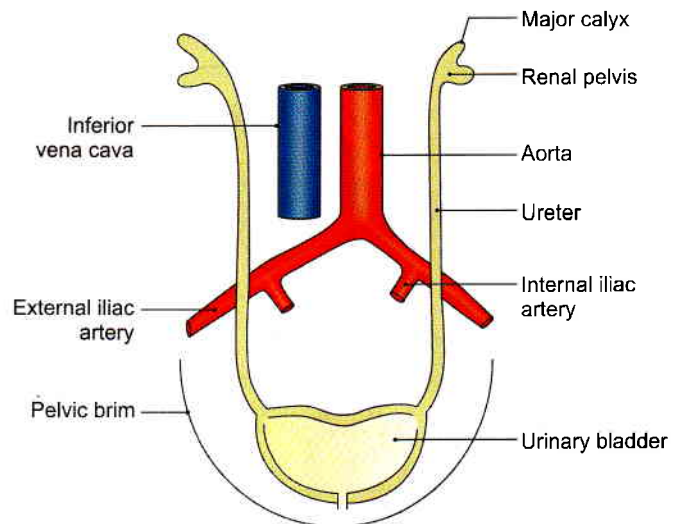


Fig. 24.21: The location of the ureters on the posterior abdominal and lateral pelvic walls



half (5 inches) in the pelvis. It measures about 3 mm in diameter, but it is slightly constricted at five places.

Course

The ureter begins within the renal sinus as a funnel-shaped dilatation, called the *renal pelvis*. The pelvis issues from the hilus of the kidney, descends along its medial margin, or partly behind it. Gradually it narrows till the lower end of the kidney where it becomes the ureter proper.

The ureter passes downwards and slightly medially on the tips of transverse processes and the psoas major muscle, and enters the pelvis by crossing in front of the termination of the common iliac artery (Fig. 24.22).

In the lesser or true pelvis the ureter at first runs downwards, and slightly backwards and laterally, following the anterior margin of the greater sciatic notch. Opposite the ischial spine it turns forwards and medially to reach the base of the urinary bladder.

Normal Constrictions

The ureter is slightly constricted at five places.

- 1 At the pelviureteric junction (Fig. 24.23).
- 2 At the brim of the lesser pelvis.
- 3 Point of crossing of ureter by ductus deferens or broad ligament of uterus.
- 4 During its oblique passage through the bladder wall.
- 5 At its opening in lateral angle of trigone.

Relations

Renal Pelvis

In the renal sinus, branches of renal vessels lie both in front and behind it (Fig. 24.7).

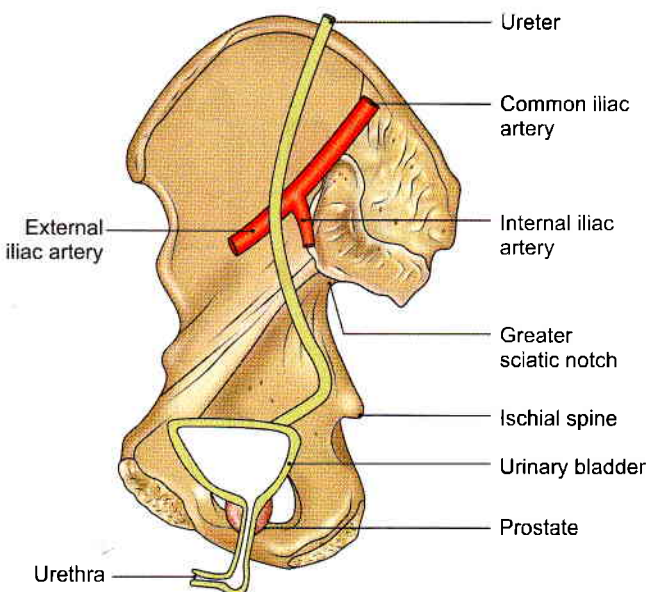


Fig. 24.22: General course of the ureter in the pelvis

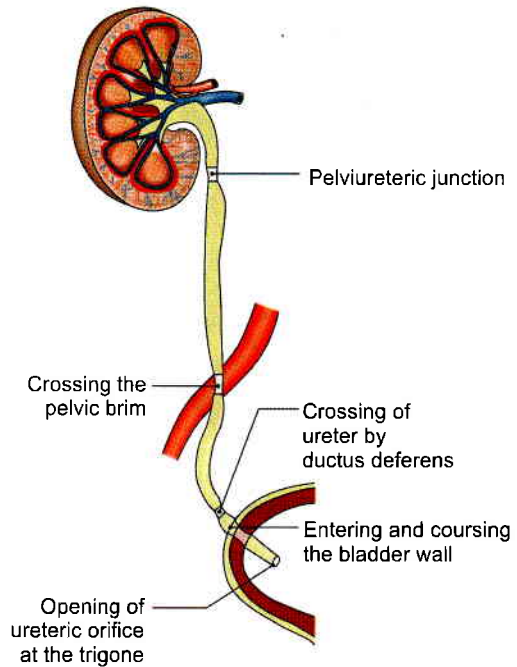


Fig. 24.23: Constrictions in the course of ureter

Outside the Kidney

Anteriorly

On the *right side*, there are the renal vessels and the second part of the duodenum. On the *left side*, there are the renal vessels, the pancreas, the peritoneum and the jejunum (Fig. 24.3).

Posteriorly

Psoas major muscle (Fig. 24.4).

Abdominal Part of Ureter

Anteriorly

On the *right side*, the ureter is related to:

- 1 Third part of the duodenum (Fig. 24.24)
- 2 Peritoneum
- 3 Right colic vessels
- 4 Ileocolic vessels
- 5 Gonadal vessels
- 6 Root of the mesentery
- 7 Terminal part of the ileum.

On the *left side* (Fig. 24.25) the ureter is related to:

- 1 Peritoneum
- 2 Gonadal artery
- 3 Left colic vessels
- 4 Sigmoid colon
- 5 Sigmoid mesocolon.

Posteriorly

The ureter lies on

- 1 Psoas major
- 2 Tips of transverse processes (Fig. 24.26)
- 3 Genitofemoral nerve.

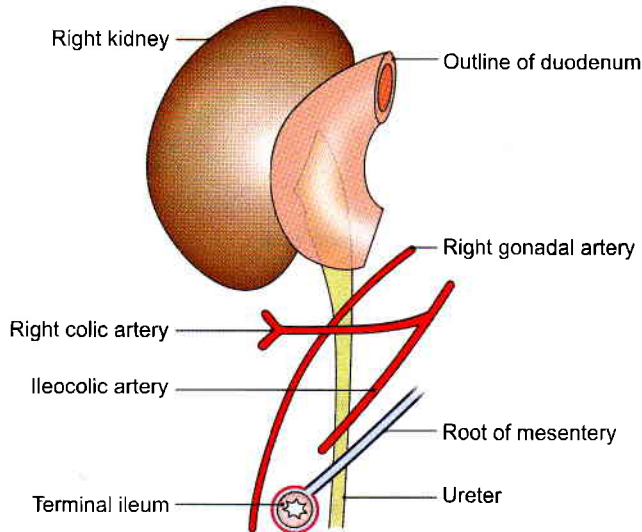


Fig. 24.24: Anterior relations of the abdominal part of the right ureter

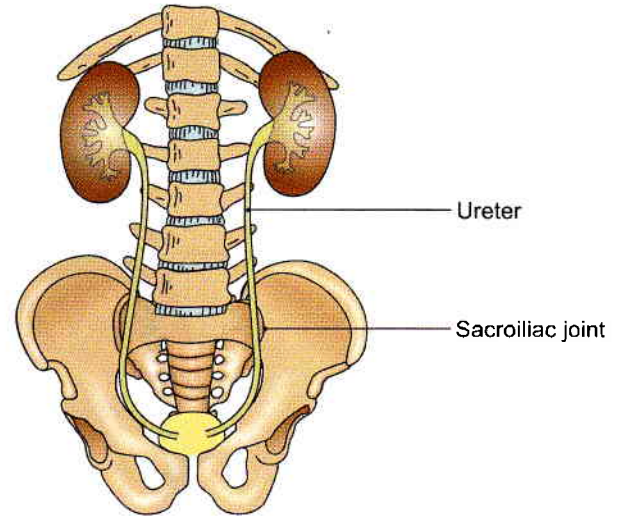


Fig. 24.26: Relations of the ureter to the transverse processes of lumbar vertebrae and the ischial spine

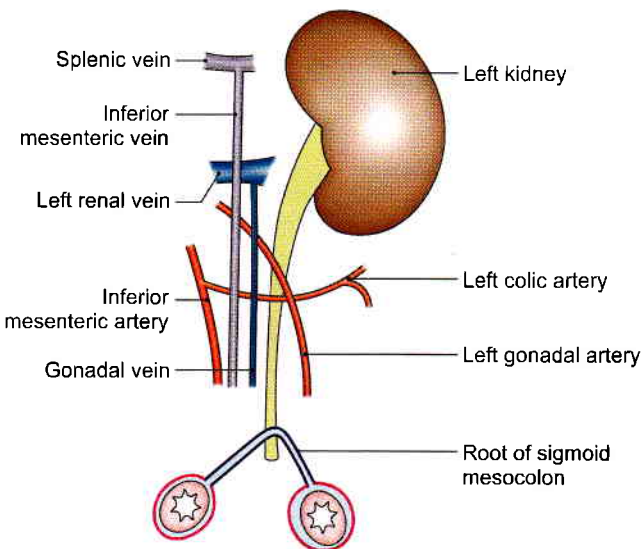


Fig. 24.25: Anterior relations of the abdominal part of the left ureter

Medially

On the *right side* there is the inferior vena cava; on the *left side*, there is the left gonadal vein, and still further medially, the inferior mesenteric vein.

Pelvic Part of Ureter

In its downward course the relations are:

Posteriolry

- 1 Internal iliac artery (Fig. 24.27)
- 2 Commencement of the anterior trunk of the internal iliac artery
- 3 Internal iliac vein
- 4 Lumbosacral trunk
- 5 Sacroiliac joint.

Laterally

- 1 Fascia covering the obturator internus,
- 2 Superior vesical artery
- 3 Obturator nerve (Fig. 24.27)
- 4 Obturator artery
- 5 Obturator vein
- 6 Inferior vesical vein
- 7 Middle rectal artery
- 8 In the female, it forms the posterior boundary of the ovarian fossa.

In its forward course:

In Males

- 1 *Ductus deferens* crosses the ureter superiorly from lateral to medial side.
- 2 *Seminal vesicle* lies below and behind the ureter (Fig. 24.28).
- 3 Vesical veins surround the terminal part of ureter.

In Females

- 1 The ureter lies in the extraperitoneal connective tissue in the lower and medial part of the *broad ligament of the uterus* (Fig. 24.29).
- 2 *Uterine artery* lies first above and in front of the ureter for a distance of about 2.5 cm and then crosses it superiorly from lateral to medial side.
- 3 The ureter lies about 2 cm lateral to the *supravaginal portion of the cervix*. It runs slightly above the *lateral fornix of the vagina*.
- 4 The terminal portion of the ureter lies anterior to the *vagina*.

Intravesical Part

The intravesical oblique course of the ureter has a valvular action, and prevents regurgitation of urine

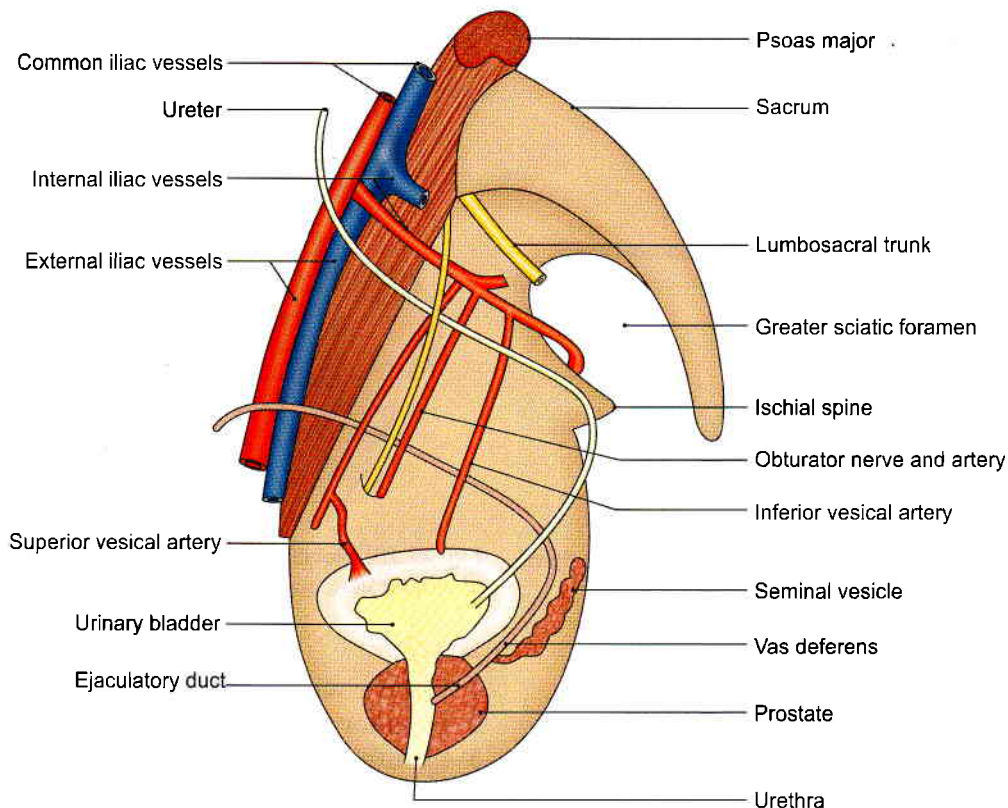


Fig. 24.27: Relations of the pelvic part of the ureter

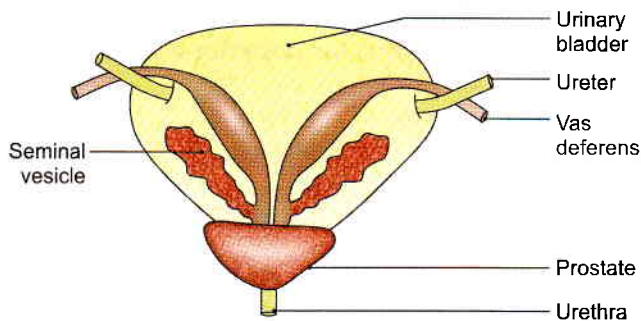


Fig. 24.28: Posterior view of the male urinary bladder showing the relations of the ureter to the vas deferens and the seminal vesicle

from the bladder to the ureter. The ureteric openings lie about 5 cm apart in a distended bladder, and only 2.5 cm apart in an empty bladder.

Blood Supply

The ureter is supplied by three sets of long arteries:

- 1 The *upper part* receives branches from the renal artery. It may also receive branches from the gonadal, or colic vessels.
- 2 The *middle part* receives branches from the aorta. It may also receive branches from the gonadal, or iliac vessels.
- 3 The *pelvic part* is supplied by branches from the vesical, middle rectal, or uterine vessels. The arteries

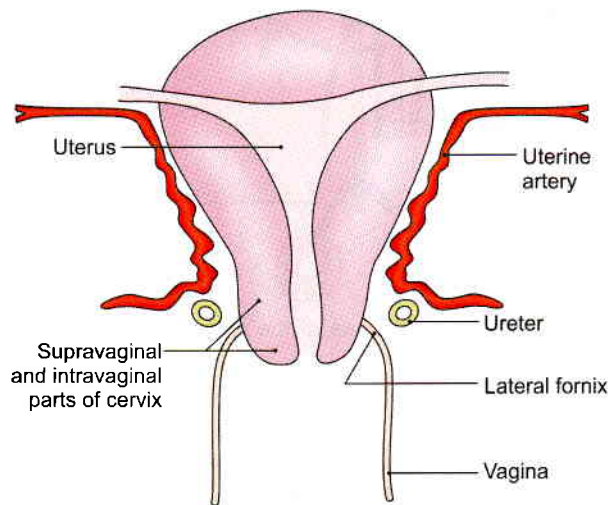
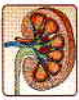

Fig. 24.29: Anterior view of the uterus and vagina showing the relation of the ureter to the uterine artery, the cervix of the uterus, and the vagina

to the ureter lie closely attached to peritoneum. They divide into ascending and descending branches which first form a plexus on the surface of the ureter, and then supply it.

The upper and middle parts receive branches from medial side, while the pelvic part gets its arterial supply from lateral side.



Nerve Supply

The ureter is supplied by sympathetic from T10–L1 segments and parasympathetic from S2–S4 nerves. They reach the ureter through the renal, aortic and hypogastric plexuses. All the nerves appear to be sensory in function.

Histology

Ureter is composed of:

- 1 The innermost mucous membrane.
- 2 Middle layer of well developed smooth muscle layer.
- 3 Outer tunica adventitia.

The epithelial lining is of transitional epithelium. Muscle coat in upper two-thirds has inner longitudinal and outer circular fibres. Lower one-third comprises an additional outer longitudinal layer. Connective tissue forms the outer layer (Fig. 24.30).

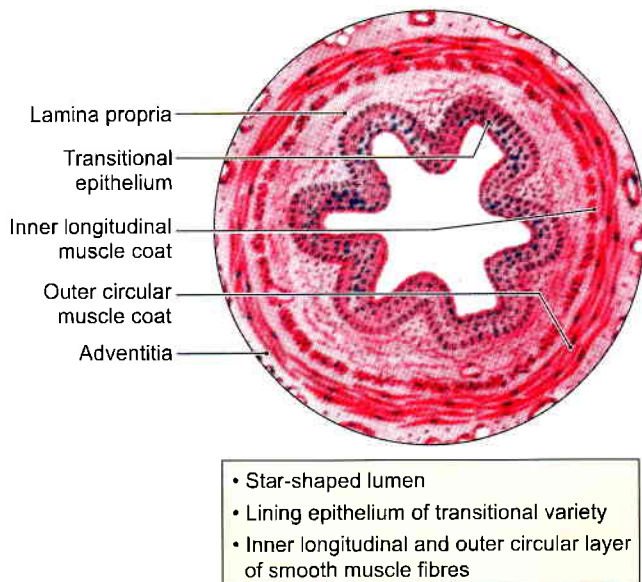


Fig. 24.30: Histology of the ureter

DEVELOPMENT OF KIDNEY AND URETER

Kidney develops from metanephros, though pronephros and mesonephros appear to disappear. Only the duct of mesonephros, the mesonephric duct persists.

Thus the nephrons of the kidney arise from the metanephros. Parts of nephron formed are Bowman's capsule, proximal convoluted tubule, loop of Henle, distal convoluted tubule. Tuft of capillaries form the glomeruli.

Collecting part of kidney develops from ureteric bud, which is an outgrowth of the mesonephric duct. Ureteric bud gets capped by the metanephric tissue, the ureteric bud forms ureter. Soon it dilates to form renal pelvis and divides and subdivides to form major and minor calyces and 1–3 million collecting tubules.

Kidney starts developing in the sacral region, then it ascends to occupy its lumbar position (Figs 24.31a to e and 24.32a to e).

Anomalies of the Kidney and Ureter

- 1 Nonunion of the excretory and collecting parts of the kidney results in the formation of *congenital polycystic kidney*.
- 2 Fusion of the lower poles may occur, resulting in a *horseshoe kidney*. In these cases the ureters pass anterior to the isthmus of the kidney.
- 3 The early *pelvic position* of the kidney may persist. The renal artery then arises from the common iliac artery.
- 4 Unilateral *aplasia* or *hypoplasia* of the kidney may occur. Sometimes both kidneys may lie on any one side of the body.
- 5 The ureteric bud may divide into two, forming double ureter partly or completely.

CLINICAL ANATOMY

- **Ureteric colic:** This term is used for severe pain due to a ureteric stone or calculus which causes spasm of the ureter. The pain starts in the loin and radiates down the groin, the scrotum or the labium majus and the inner side of the thigh. Note that the pain is referred to the cutaneous areas innervated by segments, mainly T11 to L2, which also supply the ureter (Fig. 24.33).
- **Ureteric stone:** A ureteric stone is liable to become impacted at one of the sites of normal constriction of the ureter, e.g. pelviureteric junction, brim of the pelvis and intravesical course (Fig. 24.23).
- **Duplex ureter:** 2 ureters drain renal pelvis on one side called as duplex system.
- **Ectopic ureter:** Single ureter and longer ureter insert more caudally and medially than normal one.
- **Ureterocele:** Cystic dilatation of lower end of ureter.
- **Blood supply:** Upper and middle parts of ureter are supplied by branches from its medial side. Pelvic part is supplied by branches from its lateral side.

Mnemonics

Ureter to uterine artery: "Water under the bridge"

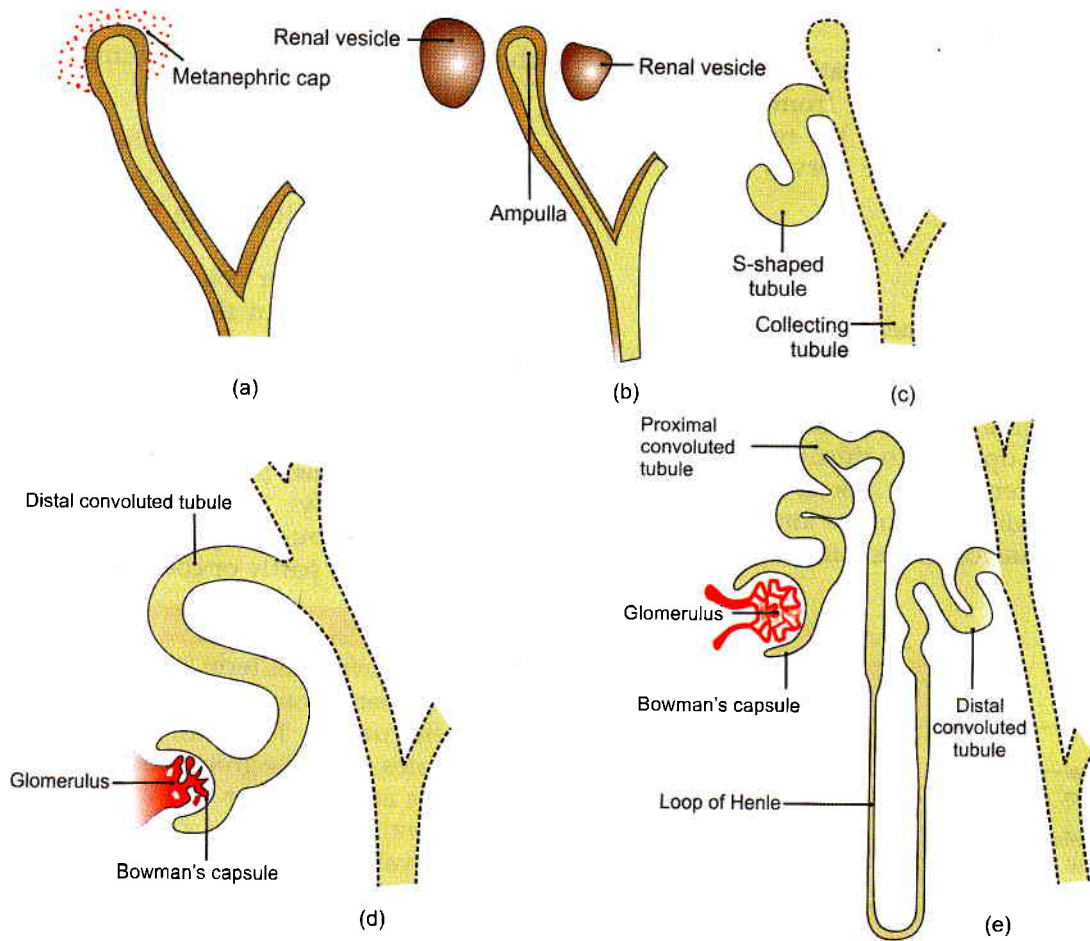
The ureters (which carry **water**), are posterior to the **uterine artery**.

A common surgical error could be to ligate and cut ureter with uterine artery while removing uterus.

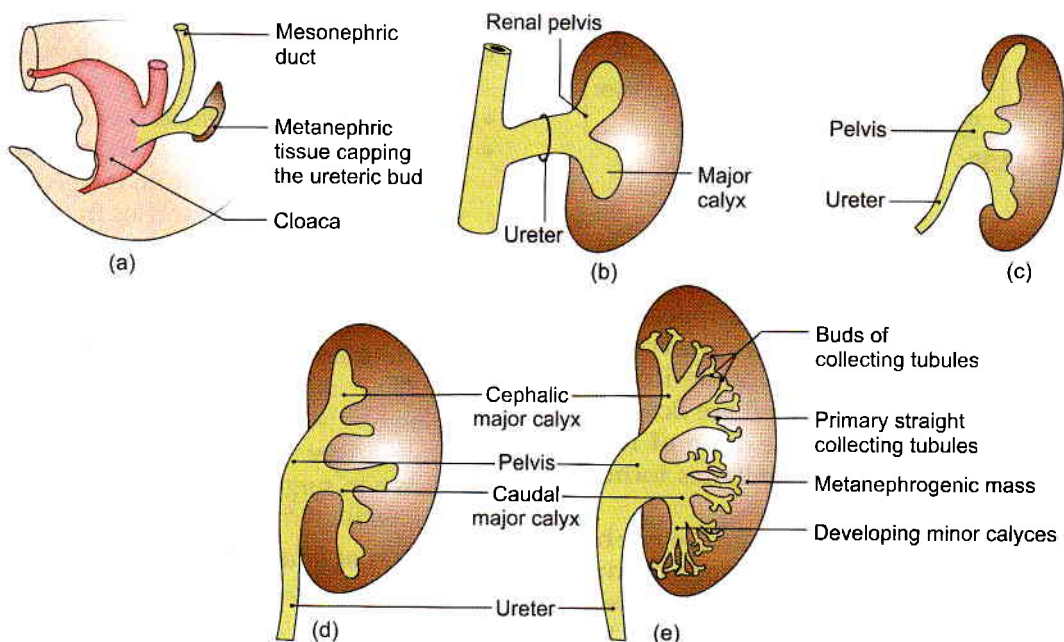
Structures at hilum of kidney

From anterior to posterior aspect—VAU

- V – Renal vein
- A – Renal artery
- U – Pelvis of ureter



Figs 24.31a to e: Development of excretory system of permanent kidney: (a) Metanephric cap, (b) renal vesicles, (c) s-shaped tubule, (d) Bowman's capsule and glomerulus, and (e) differentiation and growth of parts of nephron, loop of Henle, proximal and distal convoluted tubules



Figs 24.32a to e: Development of collecting system of permanent kidney: (a) Formation of ureteric buds, (b) capping of ureteric bud by metanephros, and (c to e) formation of ureter, renal pelvis, major calyces, minor calyces and collecting tubules

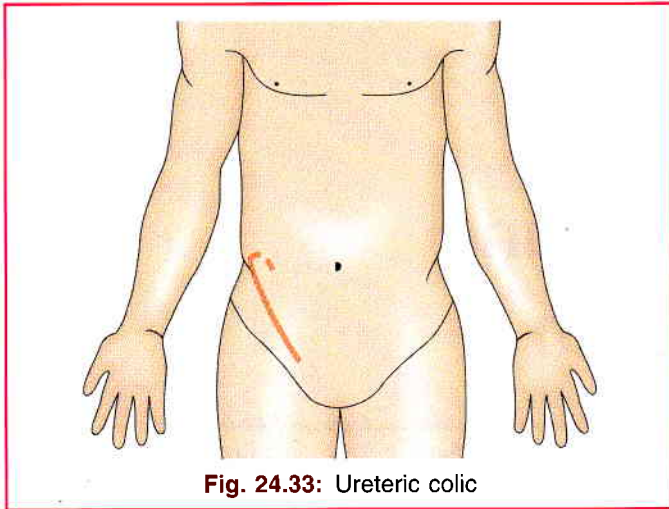


Fig. 24.33: Ureteric colic

FACTS TO REMEMBER

- Order of structures at the hilum of kidney is renal vein, renal artery and pelvis of ureter from before backwards.
- Kidney is kept in position by intra-abdominal pressure, pararenal, fat, renal fascia, perirenal fat, renal capsule.
- There are 5 renal segments. These are apical, upper, middle, lower and posterior.

- Ureter shows 5 constrictions. These are at pelviureteric junction, at the brim of pelvis, at crossing with ductus deferens or broad ligament, intravesical course and at its termination at the trigone of the urinary bladder.
- Most of the renal stones are radiopaque while most of the gallstones non-radiopaque.
- Excretory part of kidney-develops from metanephros; collecting part of kidney develops from ureteric bud, arising from mesonephric duct.

CLINICOANATOMICAL PROBLEM

A patient of chronic renal failure needs a kidney transplant

- Where will the new kidney be put?
- Will the diseased kidney be removed?
- How will the new ureter and blood vessels be connected?

Ans: The new kidney is put in the right or left iliac fossa. The diseased kidney cut off from blood vessels and ureter is left within the patient's body


The new ureter is connected to the urinary bladder. The renal blood vessels are connected to internal iliac vessels. With proper precautions and medications, life gets sustained.

MULTIPLE CHOICE QUESTIONS

- All of the following are related to the anterior surface of left kidney *except*:
 - Spleen
 - Pancreas
 - Duodenum
 - Left colic flexure
- Which of the following muscles is not forming posterior relation of kidney?
 - Latissimus dorsi
 - Transversus abdominis
 - Psoas major
 - Quadratus lumborum
- Structure not lying anterior to left ureter is:
 - Gonadal artery
 - Left colic artery
 - Pelvic colon
 - Internal iliac artery
- All the following areas on the anterior surface of right kidney are not covered by peritoneum, *except*:
 - Suprarenal
 - Hepatic
 - Duodenal
 - Colic
- Order of structures in the hila of kidney from before backwards is:
 - Pelvis, vein, artery
 - Vein, pelvis, artery
 - Vein, artery, pelvis
 - Artery, vein, pelvis
- Number of minor calyces in a kidney is about:
 - 7–14
 - 14–24
 - 2–4
 - 25–28
- Where is the perirenal fat thickest?
 - At the poles
 - Along the borders
 - Along posterior surface
 - Along anterior surface
- What forms the lobe of the kidney?
 - Two renal pyramids with intervening renal column
 - Two renal columns with intervening pyramid
 - A renal pyramid with the cortex overlying it
 - Two renal columns plus the adjoining cortex

ANSWERS

1. c 2. a 3. d 4. b 5. c 6. a 7. b 8. c



Suprarenal Gland and Chromaffin System

The two parts of the suprarenal gland are different from embryology and histology points of view, still these work in unison to keep up the body during adversity

INTRODUCTION

The suprarenal or adrenal glands are endocrine glands which help to maintain water and electrolyte balance. These also prepare the body for any emergency. These are subjected to hyper- or hypofunctioning. Lack of secretion of the cortical part leads to Addison's disease. Excessive secretion causes retention of salts and fluids.

Tumour of adrenal medulla or pheochromocytoma causes persistent severe hypertension.

SUPRARENAL GLAND

DISSECTION

Locate the suprarenal glands situated along the upper pole and medial border of the two kidneys. Identify the structures related to the right and left suprarenal glands.

Subdivisions

The suprarenal glands are a pair of important endocrine glands situated on the posterior abdominal wall over the upper pole of the kidneys behind the peritoneum (Fig. 25.1). They are made up of two parts.

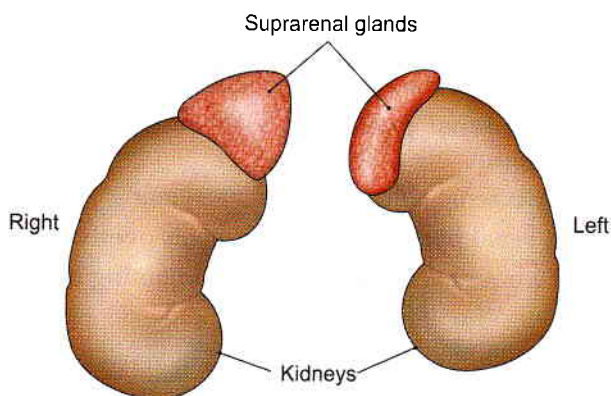


Fig. 25.1: The suprarenal glands

- 1 An outer cortex of mesodermal origin, which secretes a number of steroid hormones.
- 2 An inner medulla of neural crest origin, which is made up of chromaffin cells and secretes adrenaline and noradrenalin or catecholamines.

Location

Each gland lies in the epigastrium, at the upper pole of the kidney, in front of the crus of the diaphragm, opposite the vertebral end of the 11th intercostal space and the 12th rib.

Size, Shape and Weight

Each gland measures 50 mm in height, 30 mm in breadth and 10 mm in thickness. It is approximately one-third of the size of kidney at birth and about one-thirtieth of it in adults. It weighs about 5 g, the medulla forming one-tenth of the gland. Right suprarenal is triangular or pyramidal in shape and the left is semilunar in shape.

Sheaths

The suprarenal glands are immediately surrounded by areolar tissue containing considerable amount of fat.

Outside the fatty sheath, there is the perirenal fascia. Between the two layers lies the suprarenal gland (Fig. 25.2). The two layers are not fused above the suprarenal. The perirenal space is open and is in continuity with bare area of liver on the right side and with subphrenic extraperitoneal space on the left side.

The gland is separated from the kidney by a septum.

RIGHT SUPRARENAL GLAND

The right suprarenal gland is triangular to pyramidal in shape. It has:

- 1 An apex
- 2 A base

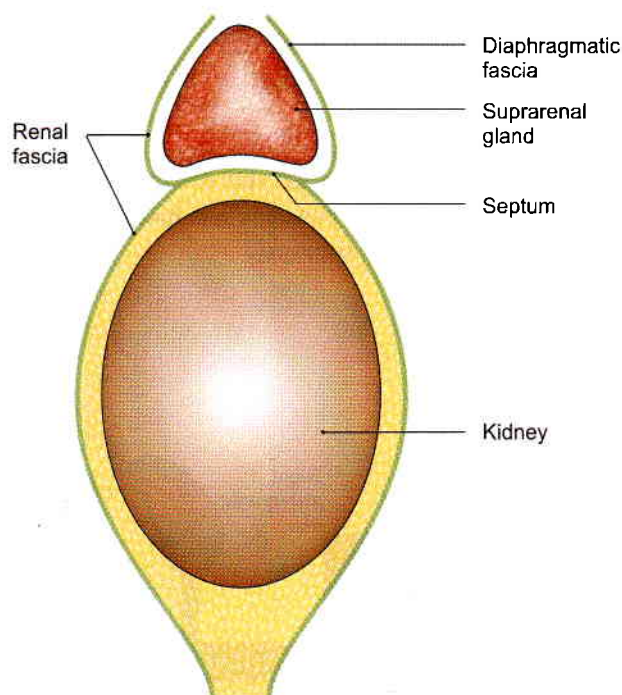


Fig. 25.2: The kidney and suprarenal glands enclosed in the renal fascia with a septum intervening

- 3 Two surfaces—anterior and posterior.
- 4 Three borders—anterior, medial and lateral (Figs 25.3a to d).

LEFT SUPRARENAL GLAND

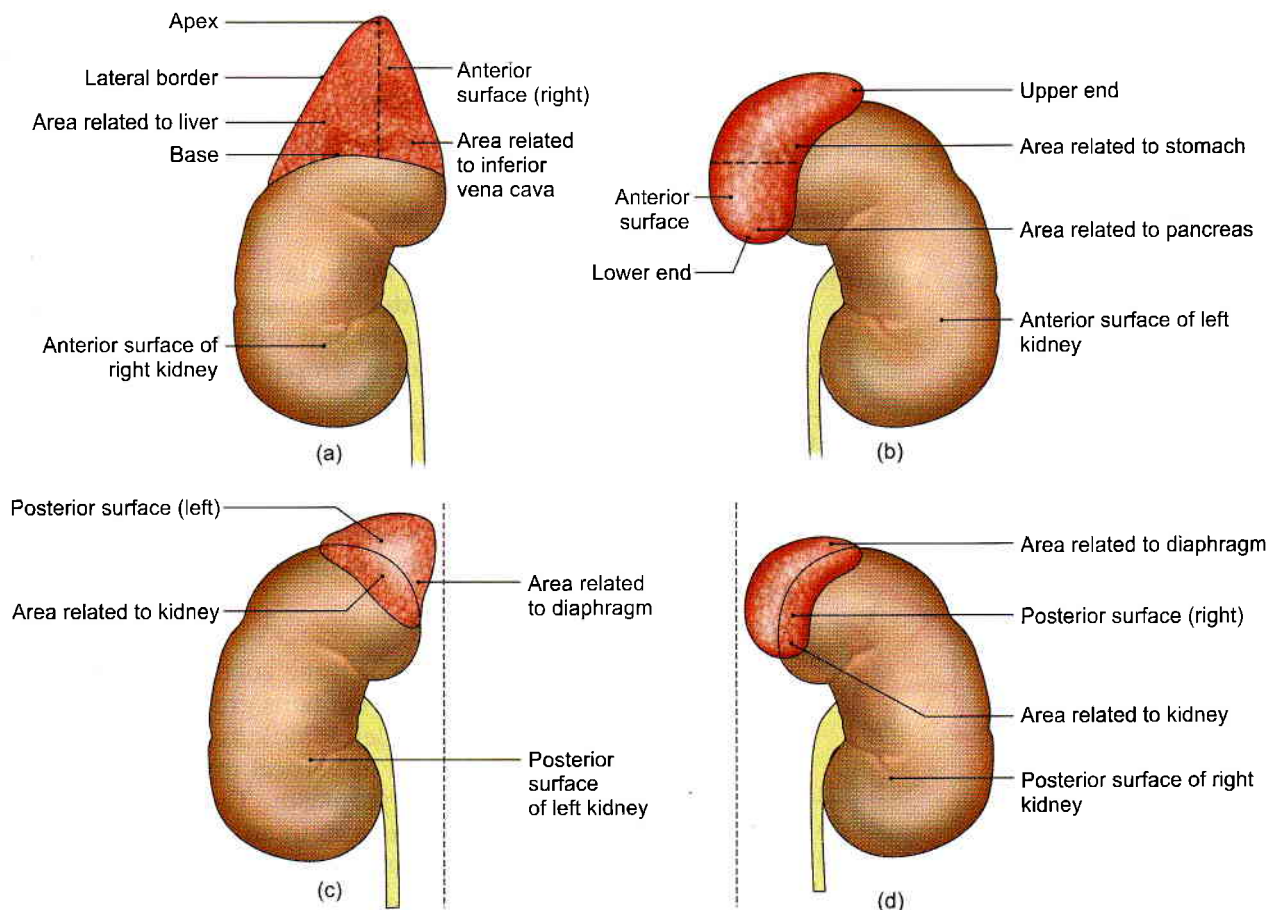
The *left gland* is semilunar. It has:

- 1 Two ends—upper (narrow end) and lower (rounded end).
- 2 Two borders—medial convex and lateral concave.
- 3 Two surfaces—anterior and posterior (Figs 25.3b and c).

Comparison of right and left suprarenal glands is given in Table 25.1.

Structure and Function

Naked eye examination of a cross-section of the suprarenal gland shows an outer part, called the *cortex*, which forms the main mass of the gland, and a thin inner part, called the *medulla*, which forms only about one-tenth of the gland. The two parts are absolutely distinct from each other structurally, functionally and developmentally.



Figs 25.3a to d: Relations of the suprarenal glands: (a) Anterior view of right suprarenal gland, (b) anterior view of left suprarenal gland, (c) posterior view of left suprarenal gland, and (d) posterior view of right suprarenal gland



Table 25.1: Comparison of right and left suprarenal glands

	Right suprarenal gland	Left suprarenal gland
Shape	Pyramidal	Semilunar
Parts and relations	Apex: Bare area of liver Base: Upper pole of right kidney	Upper end: Close to spleen Lower end: Presents hilum, left vein emerges from here
Anterior surface	Inferior vena cava, bare area of liver	Cardiac end of stomach, pancreas with splenic artery
Posterior surface	Right crus of diaphragm, right kidney	Left crus of diaphragm, left kidney
Anterior border	Presents hilum, right vein emerges	—
Medial border	Coeliac ganglion	Coeliac ganglion
Lateral border	Liver	Stomach

The cortex is composed of three zones.

- The outer, zona glomerulosa which produces mineralocorticoids that affect electrolyte and water balance of the body.
- The middle, zona fasciculata which produces glucocorticoids.
- The inner, zona reticularis which produces sex hormones.

The medulla is composed of chromaffin cells that secrete adrenaline and noradrenalin. It contains cells in groups with lots of capillaries. Autonomic ganglion cells are also seen.

Arterial Supply

Each gland is supplied by:

- The *superior suprarenal artery*, a branch of the inferior phrenic artery.
- The *middle suprarenal artery*, a branch of the abdominal aorta.
- The *inferior suprarenal artery*, a branch of the renal artery (Fig. 25.4).

Venous Drainage

Each gland is drained by one vein (Fig. 25.5). The right suprarenal vein drains into the inferior vena cava, and the left suprarenal vein into the left renal vein.

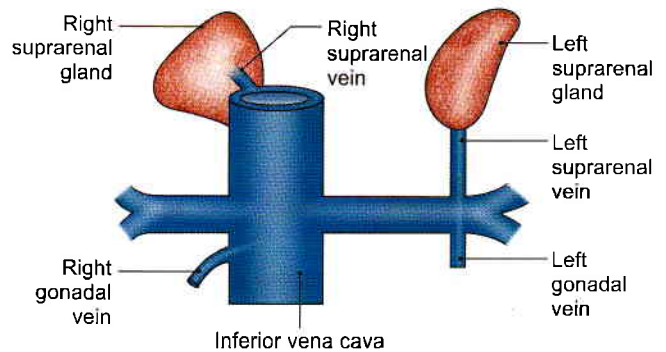


Fig. 25.5: Venous drainage of the suprarenal glands

Lymphatic Drainage

Lymphatics from the suprarenal glands drain into the lateral aortic nodes.

Nerve Supply

The suprarenal medulla has a rich nerve supply through myelinated *preganglionic* sympathetic fibres. The chromaffin cells in it are considered homologous with postganglionic sympathetic neurons.

Accessory Suprarenal Glands

These are small masses of cortical tissue often found in the areolar tissue around the main glands and sometimes in the spermatic cord, the epididymis, and the broad ligament of the uterus.

HISTOLOGY

Cortex: It consists of three zones. Outer zone is zona glomerulosa which contains groups of columnar cells with spherical nuclei. Middle zone or zona fasciculata has cells arranged in vertical rows. Cells have lots of vacuoles in the cytoplasm. The inner zone or zona reticularis contains cells in an anastomosing network. These cells are less vacuolated.

Medulla: It is composed of chromaffin cells, arranged in small groups, surrounded by capillaries. In between these cells are autonomic ganglion cells (Fig. 25.6).

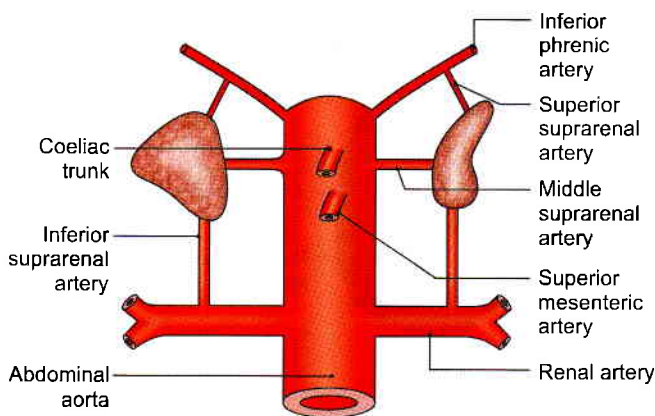
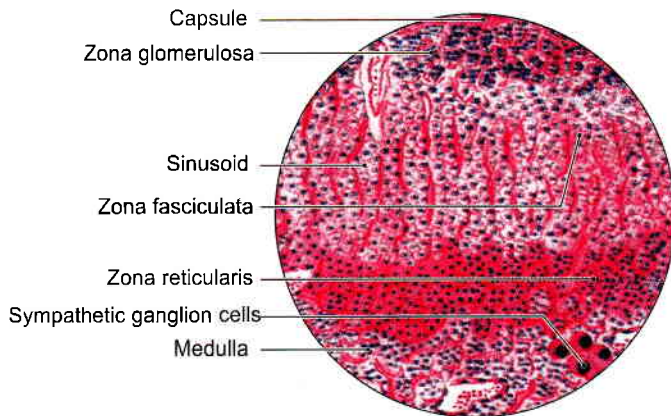


Fig. 25.4: Arterial supply of the suprarenal glands



- Outer covering is the cortex and inside is the medulla
- Cortex comprises zona glomerulosa (outermost zone fasciculata (middle zone), and zona reticularis (innermost zone))
- Medulla comprises chromaffin cells and sympathetic ganglion cells

Fig. 25.6: Histology of suprarenal gland

DEVELOPMENT OF SUPRARENAL GLAND

The cortex of the gland develops from mesoderm of coelomic epithelium while the medulla is derived from the neural crest cells (neuroectoderm).

CHROMAFFIN SYSTEM

Chromaffin system is made up of cells which have an affinity for certain salt of chromic acid. Such cells are called chromaffin cells or pheochromocytes. These are situated close to sympathetic ganglia because both of them develop from the cells of the neural crest. Chromaffin cells secrete adrenaline and noradrenaline. This system includes the following groups of cells.

- 1 Suprarenal medulla (described above).
- 2 Paraganglia.
- 3 Para-aortic bodies.
- 4 Coccygeal body.
- 5 Small masses of chromaffin cells scattered irregularly amongst ganglia of sympathetic chain, splanchnic nerves, autonomic plexuses, and may be closely related to various organs like heart, liver, kidney, ureter, prostate, epididymis, etc.

PARAGANGLIA

These are rounded nodules of chromaffin tissue, about 2 mm in diameter, situated inside or closely related to the ganglia of the sympathetic chain. In adults they are generally represented by microscopic remnants only.

PARA-AORTIC BODIES

Two para-aortic bodies, each about 1 cm long, lie on each side of the origin of the inferior mesenteric artery. They are connected together above the artery to form

an inverted horseshoe, or an H-shaped body. They develop during foetal life, attain their maximum size in the first three years of life, and gradually atrophy to disappear by the age of 14 years. The chromaffin cells of the para-aortic bodies secrete noradrenaline.

Other small chromaffin bodies are found in the foetus in all parts of the prevertebral sympathetic plexuses of the abdomen and pelvis. They reach their maximum size between the 5th and 8th months of foetal life. In adults, they can be made out only in the vicinity of the coeliac and superior mesenteric arteries.

COCCYGEAL BODY (GLOMUS COCCYGEUM)

Also known as glomus coccygeum, it is a small oval body about 2.5 cm in diameter situated in front of the coccyx. It is closely connected to the termination of the *median sacral artery* and to the *ganglion impar*. It is made up of epithelioid cells grouped around a sinusoidal capillary. Thus it does not clearly belong to the chromaffin system.

CLINICAL ANATOMY

- Suprarenal gland can be *demonstrated radiologically* by computerised tomography (CT scan).
- Insufficiency of cortical secretion due to atrophy or tuberculosis of the cortex results in *Addison's disease*. It is characterized by muscular weakness, low blood pressure, anaemia, pigmentation of skin and terminal circulatory and renal failure.
- Excessive cortical secretion due to hyperplasia of the cortex may produce various effects:
 - a. In adults, hyperglucocorticism causes *Cushing's syndrome*, which is characterized by obesity, hirsutism, diabetes and hypogonadism.
 - b. In women, excessive androgens may cause *masculinization (virilism)*.
 - c. In men, excessive oestrogens may cause *feminization* and breast enlargement.
 - d. In children, excessive sex hormones cause *adrenogenital syndrome*, cortical hyperplasia. In female foetus excessive androgens cause *female pseudohermaphroditism*; in the male foetus, it causes excessive development of external genital organs.
- Bilateral removal of adrenal glands (*adrenalectomy*) is done as a treatment of some advanced and inoperable cases of disseminated carcinoma of the breast and prostate which do not respond to radiotherapy and which are considered to be dependent on hormonal control.
- Benign tumours of the suprarenal medulla (*pheochromocytoma*) cause attacks of hypertension associated with palpitation, headache, excessive sweating and pallor of skin.



FACTS TO REMEMBER

- Suprarenal gland sustains the body during stress by its cortical and medullary hormones.
- Suprarenal is drained by one vein which ends in inferior vena cava on the right side and in left renal vein on the left side.
- Each suprarenal is supplied by 3 arteries.

CLINICOANATOMICAL PROBLEM

A patient has bouts of severe high blood pressure with headache and palpitation. The diagnosis is pheochromocytoma.

- How is the diagnosis finalised?
- Where does the blood supply to suprarenal gland come from?

Ans: The diagnosis is done by history, biochemical tests and CT scans.

There are three arteries supplying blood to the gland. These are superior suprarenal from inferior phrenic; middle suprarenal from abdominal aorta and inferior suprarenal from the renal artery.

Vein of suprarenal is only one. On the right side, the vein drains into inferior vena cava.

On the left side the suprarenal vein drains into the left suprarenal vein.

MULTIPLE CHOICE QUESTIONS

1. Right suprarenal vein drains into:
 - a. Right renal vein
 - b. Inferior vena cava
 - c. Left renal vein
 - d. Lumbar vein
2. Suprarenal gland does not receive blood supply from:
 - a. Inferior phrenic artery
 - b. Renal artery
 - c. Superior mesenteric artery
 - d. Abdominal aorta
3. Left suprarenal vein drains into:
 - a. Left renal vein
 - b. Right renal vein
 - c. Inferior vena cava
 - d. Lumbar vein

ANSWERS

1. b 2. c 3. a



Diaphragm

Nerves are most loyal. As the diaphragm descends from the neck to the thoraco-abdominal junction the phrenic nerve follows it

INTRODUCTION

The diaphragm is the chief muscle of quiet respiration. Though it separates the thoracic and abdominal cavities, it gives passage to a number of structures passing in both the directions. Since it develops in the region of the neck, it continues to be innervated by the same *loyal* nerve despite its descent to a much lower level.

During inspiration, the central tendon is pulled by the contracting muscle fibres, so that inferior vena caval opening is enlarged helping in venous return to the heart. This venous blood is pumped to the lungs. The air also gets into the lungs during inspiration. So both the venous blood in the capillaries and air in the alveoli *come close by* in the lung tissue, separated by the lining of the alveoli. The exchange of gases takes place, carbon dioxide is expelled in expiration and purified blood is returned to the left atrium.

GROSS ANATOMY

DISSECTION

Strip the peritoneum from the under aspect of the diaphragm and expose its crura on the anterior surfaces of the upper 2 or 3 lumbar vertebrae. Find the arcuate ligaments.

Expose the slips of diaphragm arising from the internal surfaces of the remaining costal cartilages and identify the intercostal vessels and nerves entering the abdominal wall between them.

Locate the main openings in the diaphragm and identify the structures passing through each one of them. Explore the other minor openings and the structures traversing these.

Definition

The diaphragm is a dome-shaped muscle forming the partition between the thoracic and abdominal cavities. It is the chief muscle of respiration.

Muscle fibres form the periphery of the partition. They arise from circumference of the thoracic outlet and are inserted into a central tendon (Fig. 26.1).

Origin

The muscle fibres may be grouped into three parts, sternal, costal and lumbar.

The *sternal part* arises by two fleshy slips from the back of the xiphoid process.

The *costal part* arises from the inner surfaces of the cartilages and the adjacent parts of the lower six ribs on each side, interdigitating with the transversus abdominis.

The *lumbar part* arises from the medial and lateral lumbocostal arches and from the lumbar vertebrae by right and left *crura*.

- The *medial lumbocostal arch* or medial arcuate ligament is a tendinous arch in the fascia covering the upper part of the psoas major. Medially, it is attached to the side of the body of vertebra L1 and is continuous with the lateral margin of the corresponding crus. Laterally, it is attached to the front of the transverse process of vertebra L1.
- The *lateral lumbocostal arch* or lateral arcuate ligament is a tendinous arch in the fascia covering the upper part of the quadratus lumborum. It is attached medially to the front of the transverse process of vertebra L1, and laterally to the lower border of the 12th rib.
- The *right crus* is larger and stronger than the left crus, because it has to pull down the liver during

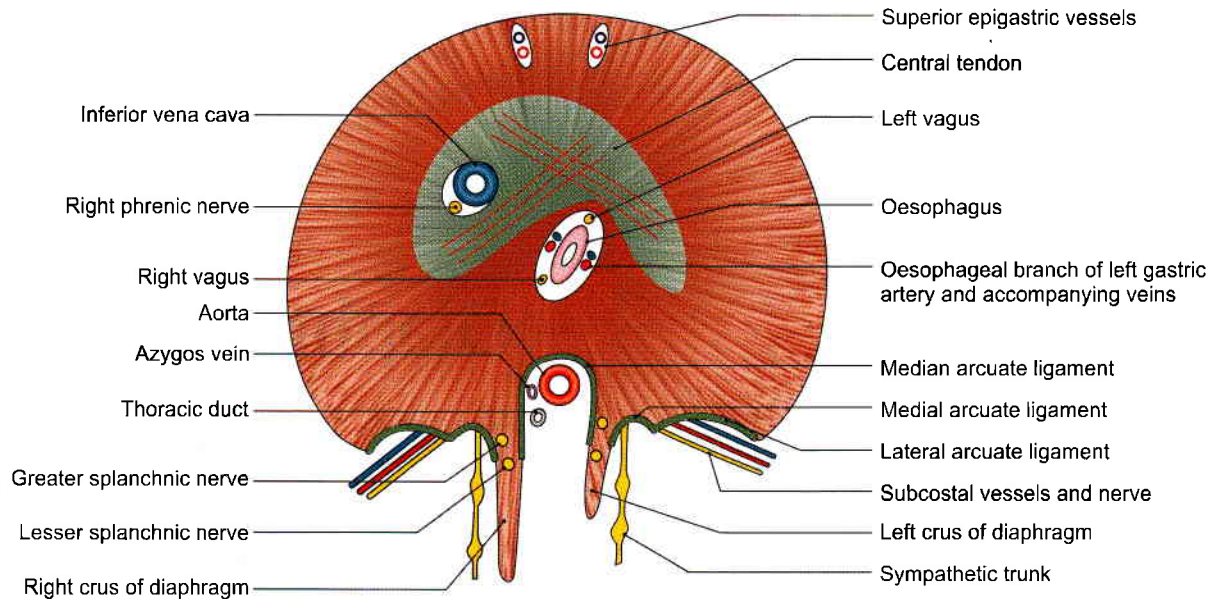


Fig. 26.1: The diaphragm as seen from below

each inspiration. It arises from the anterolateral surfaces of the bodies of the upper three lumbar vertebrae and the intervening intervertebral discs.

d. The *left crus* arises from the corresponding parts of the upper two lumbar vertebrae. The medial margins of the two crura form a tendinous arc across the front of the aorta, called the *median arcuate ligament*.

Muscle Fibres

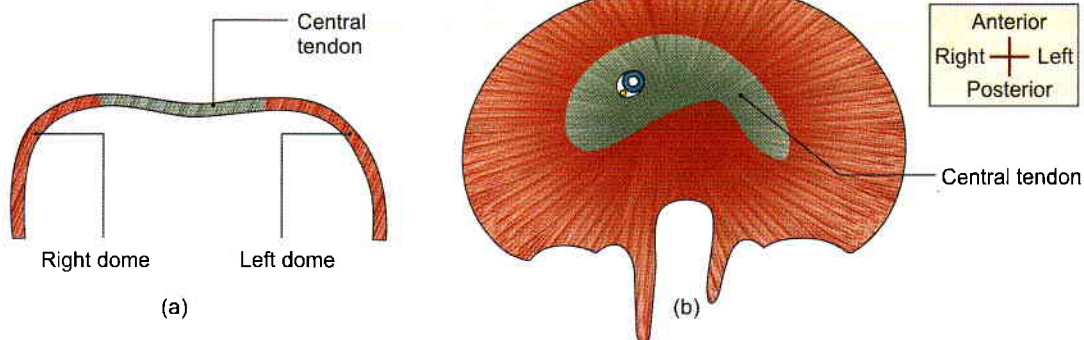
1 From the circumferential origin described above, the fibres arch upwards and inwards to form the right and left domes. The right dome is higher than the left dome (Fig. 26.2a). In full expiration, it reaches the level of the fourth intercostal space. The left dome reaches the fifth rib. The central tendon lies at the level of the lower end of the sternum at 6th costal cartilage. The downward concavity of the dome is

occupied by the liver on the right side and by the fundus of the stomach on the left side.

- 2 The medial fibres of the right crus run upwards and to the left, and encircle the oesophagus.
- 3 In general, all fibres converge towards the central tendon for their insertion (Fig. 26.2b).

Insertion

The *central tendon* of the diaphragm lies below the pericardium and is fused to the latter. The tendon is *trilobar* in shape, made up of three leaflets. The middle leaflet is triangular in shape with its apex directed towards the xiphoid process. The right and left leaflets are tongue-shaped and curve laterally and backwards, the left being a little narrower than the right. The central area consists of four well-marked *diagonal bands* which fan out from a central point of decussation located in front of the opening for the oesophagus (Fig. 26.1).



Figs 26.2a to c: Shape of the diaphragm: (a) Anteroposterior view shows the right and left domes, and (b) in superior view, it is kidney-shaped



OPENINGS IN THE DIAPHRAGM

Large or Main Openings in the Diaphragm

The *aortic opening* is osseoaponeurotic. It lies at lower border of the 12th thoracic vertebra. It transmits:

- a. Aorta
- b. Thoracic duct
- c. Azygos vein (Fig. 26.3).

The *oesophageal opening* lies in the muscular part of the diaphragm, at the level of the 10th thoracic vertebra. It transmits:

- a. Oesophagus (Table 26.1)
- b. Gastric or vagus nerves
- c. Oesophageal branches of the left gastric artery, with some oesophageal veins that accompany the arteries.

The *vena caval opening* lies in the central tendon of the diaphragm at the level of the 8th thoracic vertebra. It transmits:

- a. The inferior vena cava
- b. Branches of the right phrenic nerve.
- c. Lymphatics of liver.

Small Openings in the Diaphragm

- 1 Each crus of the diaphragm is pierced by the greater and lesser splanchnic nerves. The left crus is pierced in addition by the hemiazygos vein.

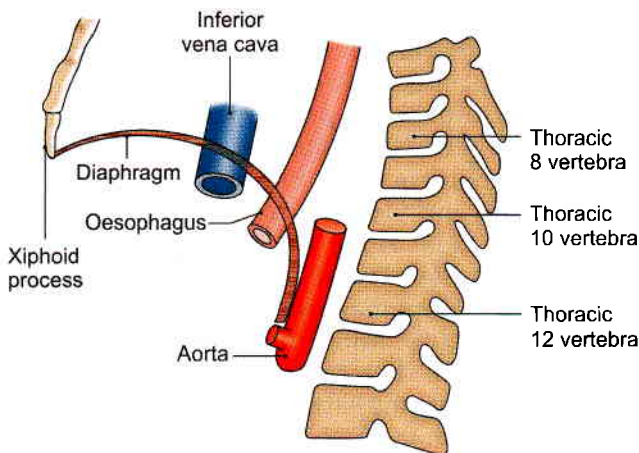


Fig. 26.3: Main openings in the diaphragm

- 2 The sympathetic chain passes from the thorax to the abdomen behind the medial arcuate ligament or medial lumbocostal arch.
- 3 The subcostal nerve and vessels pass behind the lateral arcuate ligament or lateral lumbocostal arch (Fig. 26.1).
- 4 The superior epigastric vessels and some lymphatics pass between the origins of the diaphragm from the xiphoid process and the 7th costal cartilage. This gap is known as Larry’s space or foramen of Morgagni.
- 5 The musculophrenic vessels pierce the diaphragm at the level of 9th costal cartilage.

Relations

Superiorly

- 1 Pleurae, and
- 2 Pericardium.

Inferiorly

- 1 Peritoneum,
- 2 Liver,
- 3 Fundus of the stomach,
- 4 Spleen,
- 5 Kidneys, and
- 6 Suprarenals.

Nerve Supply

Motor

The phrenic nerves are the sole motor nerves to the diaphragm (ventral rami C3, C4, C5).

Sensory

The phrenic nerves are sensory to the central part, and the lower six thoracic nerves are sensory to the peripheral part of the diaphragm.

In addition to the diaphragm, the phrenic nerves also supply sensory fibres to the mediastinal and diaphragmatic pleurae, the fibrous pericardium, the parietal layer of serous pericardium, and the part of the parietal peritoneum lying below the central part of the diaphragm. Through its communications with the phrenic branches of the coeliac plexus, the phrenic

Table 26.1: Major openings

	<i>Situation</i>	<i>Shape</i>	<i>Structures passing</i>	<i>Effect of contraction</i>
Vena caval	T8, junction of right and median leaflet of central tendon	Quadrilateral	IVC, right phrenic nerve, lymphatics of liver	Dilatation
Oesophageal	T10, splitting of right crus	Elliptical	Oesophagus, gastric nerves oesophageal vessels	Constriction
Aortic	T12, behind median arcuate ligament	Rounded	Aorta, thoracic duct azygos vein	No change



nerve is also distributed to the falciform and coronary ligaments of the liver, the inferior vena cava, the suprarenal glands, and the gallbladder.

Actions

- 1 The diaphragm is the *principal muscle of inspiration*. On contraction, the diaphragm descends increasing the vertical diameter of the thorax. The excursion of the diaphragm is about 1.5 cm during quiet breathing. In deep inspiration, it may be from 6 to 10 cm.
- 2 The diaphragm acts in all *expulsive acts* to give additional power to each effort. Thus before sneezing, coughing, laughing, crying, vomiting, micturition, defaecation, or parturition, a deep inspiration takes place. This is followed by closure of the glottis and powerful contraction of the trunk muscles.
- 3 The sphincteric action in lower end of oesophagus is due to the contraction of the intrinsic muscle in the lower 2 cm of the oesophagus.

The position of the diaphragm in the thorax depends upon three main factors. These are as follows.

- a. The elastic recoil of lung tissue tends to pull the diaphragm upwards.
- b. On lying down, the pressure exerted by the abdominal viscera pushes the diaphragm upwards. On standing or sitting, the viscera tend to pull the diaphragm downwards.
- c. While standing, the muscles in the abdominal wall contract, increasing the intra-abdominal pressure. This pressure tends to push the diaphragm upwards. In sitting or lying down, the muscles are relaxed (see Chapter 13, Volume 1).

Because of these factors the level of the diaphragm is highest in the supine position, lowest while sitting, and intermediate while standing. The higher is the position of the diaphragm, the greater respiratory excursion.

DEVELOPMENT

Diaphragm develops from the following sources.

- 1 Septum transversum forms the central tendon.
- 2 Pleuroperitoneal membranes form the dorsal paired portion.
- 3 Lateral thoracic wall contributes to the circumferential portion of the diaphragm.
- 4 Dorsal mesentery of oesophagus forms the dorsal unpaired portion.

CLINICAL ANATOMY

- *Hiccough* or *hiccup* is the result of spasmodic contraction of the diaphragm. It may be:
 - a. Peripheral, due to local irritation of the diaphragm or its nerve.

b. Central, due to irritation of the hiccough centre in the medulla. Uraemia is an important cause of hiccough.

- *Shoulder tip pain*: Irritation of the diaphragm may cause referred pain in the shoulder because the phrenic and supraclavicular nerves have the same root values (C3, C4, C5) (see Figs 22.9 and 23.9).
- *Unilateral paralysis of the diaphragm*, due to a lesion of the phrenic nerve anywhere in its long course, is a common occurrence. The paralysed side moves opposite to the normal side, i.e. paradoxical movements. This can be seen both clinically and fluoroscopically.
- *Eventration* is a condition in which diaphragm is pushed upwards due to a congenital defect in the musculature of its left half which is represented only by a fibrous membrane containing a few scattered muscle fibres.
- *Diaphragmatic hernia* may be congenital or acquired:

Congenital hernia

- a. *Retrosternal hernia*: It occurs through the space between the xiphoid and costal origins of the diaphragm, or foramen of Morgagni, or space of Larrey. It is more common on the right side and lies between the pericardium and the right pleura. Usually it causes no symptoms (Fig. 26.4).
- b. *Posterolateral hernia*: This is by far the commonest type of congenital diaphragmatic hernia. It occurs through the pleuro-peritoneal hiatus or *foramen of Bochdalek* situated at the periphery of the diaphragm in the region of attachments to the 10th and 11th ribs. It is more common on the left side. There is a free communication between the pleural and peritoneal cavities. Such a hernia may cause death of the infant within a few hours of birth due to acute respiratory distress caused by abdominal viscera filling the left chest. This hernia requires operation in the first few hours of life.
- c. *Posterior hernia*: This is due to failure of development of the posterior part of the diaphragm. One or both crus may be absent. The aorta and oesophagus lie in the gap, but there is no hernial sac.
- d. *Central hernia*: It is rare, left-sided, and is supposed to be the result of rupture of the foetal membranous diaphragm in the region of the left dome.

Acquired hernia

- a. *Traumatic hernia*: It is due to bullet injuries of the diaphragm.

b. *Hiatal hernia*: It may be congenital or acquired.

– A *congenital hiatal hernia* is due to persistence of an embryonic peritoneal process in the posterior mediastinum in front of the cardiac end of the stomach. The stomach can 'roll' upwards until it lies upside down in the posterior mediastinum. It is, therefore, called a rolling type of hernia. It is a rare type of hernia where the normal relationship of the cardio-oesophageal junction to the diaphragm is undisturbed, and, therefore, the mechanics of the cardio-oesophageal junction usually remains unaltered (Fig. 26.5a).

– An *acquired hiatal hernia* or sliding type (Fig. 26.5b) is the commonest of all internal hernia. It is due to weakness of the phrenico-oesophageal membrane which is formed by the reflection of diaphragmatic fascia to the lower end of the oesophagus. It is often caused by obesity, or by operation in this area. The cardiac end can slide up through the hiatus. In this way the valvular mechanism at the cardio-oesophageal junction is disturbed causing reflux of gastric contents into the oesophagus.

• Summary of diaphragmatic hernia:

a. *Congenital*

- i. Retrosternal,
- ii. Posterolateral,
- iii. Posterior, and
- iv. Central.

b. *Acquired*:

- i. Traumatic
- ii. Hiatal
 - Congenital hiatal rolling hernia
 - Acquired hiatal sliding hernia (commonest).

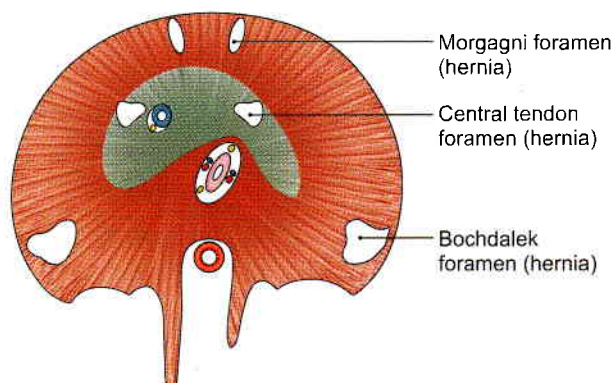
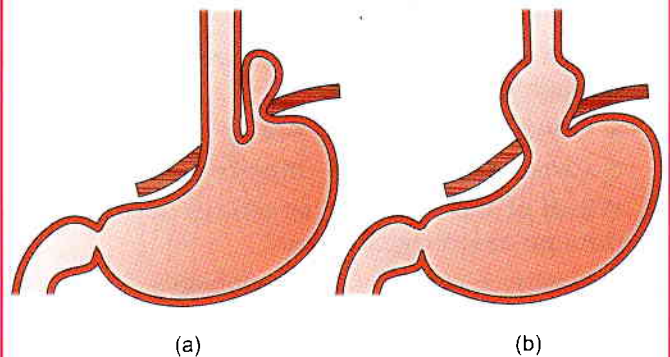


Fig. 26.4: Sites of diaphragmatic hernia



Figs 26.5a and b: Types of hiatal hernia: (a) Congenital rolling, and (b) acquired sliding

Mnemonics

Diaphragm apertures: spinal levels "1 8 10 Eggs at 12"

- Inferior vena cava (8)
- Oesophagus (10)
- Aorta (12)

FACTS TO REMEMBER

- The sole motor nerve supply of the diaphragm is phrenic nerve (C4). It develops in the neck, but is carried downwards due to developmental factors.
- Inferior vena caval opening is in the central tendon. During inspiration the opening gets dilated allowing increased venous return.
- Right crus of diaphragm acts as a sphincter at the gastro-oesophageal junction.
- Hiatal hernia may be of rolling or sliding type. The rolling type is usually congenital while the sliding type is usually acquired.

CLINICOANATOMICAL PROBLEM

A busy obese businessman complains of acidity. He has been diagnosed as having sliding diaphragmatic hernia

- Why does this hernia occur?
- What is the relation of cardiac end of stomach to cardio-oesophageal junction?

Ans: This type of hernia occurs in busy executives or businessmen. It occurs due to weakness of phrenico-oesophageal membrane, which is formed by the reflection of diaphragmatic fascia to the lower end of oesophagus. The cardiac end may slide up through the hiatus. In this way the valvular mechanism at the cardio-oesophageal junction is disturbed, causing reflux of gastric contents up to the oesophagus.

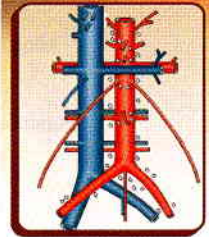


MULTIPLE CHOICE QUESTIONS

1. Which of the following structures does not pass through the diaphragm?
 - a. Oesophagus
 - b. Aorta
 - c. Cisterna chyli
 - d. Inferior vena cava
2. Which of the following structures does not pass through oesophageal hiatus?
 - a. Gastric nerve
 - b. Oesophagus
 - c. Left gastric artery
 - d. Thoracic duct
3. Which of the following apertures lies in the central tendon of diaphragm?
 - a. Oesophagus
 - b. Inferior vena cava
 - c. Thoracic duct
 - d. Abdominal aorta
4. Which of the following structures form proper sphincter at the lower end of oesophagus?
 - a. Left crus of diaphragm
 - b. Intrinsic muscle of oesophagus
 - c. Right crus of diaphragm
 - d. Phrenico-oesophageal ligament
5. Patients with difficulty in breathing are comfortable in:
 - a. Sitting up
 - b. Lying down prone
 - c. Lying down supine
 - d. Standing up

ANSWERS

1. c 2. d 3. b 4. c 5. a



Posterior Abdominal Wall

Inferior vena cava is the largest vein of the body

INTRODUCTION

Posterior abdominal wall includes the study of the following structures.

- 1 Abdominal aorta.
- 2 Inferior vena cava.
- 3 Abdominal parts of the azygos and hemiazygos veins.
- 4 Lymph nodes of posterior abdominal wall and cisterna chyli.
- 5 Muscles of the posterior abdominal wall and thoracolumbar fascia.
- 6 Nerves of the posterior abdominal wall including lumbar plexus and the abdominal part of autonomic nervous system.

BLOOD VESSELS, MUSCLES AND NERVES

DISSECTION

Expose the centrally placed abdominal aorta and inferior vena cava to the right of aorta. Trace the ventral, lateral, posterior and terminal branches of abdominal aorta and the respective tributaries of inferior vena cava. Remove the big lymph nodes present in the posterior abdominal wall.

Identify the muscles of the posterior abdominal wall by removing their fascial coverings. These are psoas major, quadratus lumborum, and iliacus. Avoid injury to the vessels and nerves related to the muscles.

Detach psoas major from the intervertebral discs and vertebral bodies and trace the lumbar vessels and the rami communicans posteriorly deep to the tendinous arches from which psoas major arises. Dissect the genitofemoral nerve seen on the anterior surface of psoas major.

Trace the various branches of lumbar plexus, e.g. iliohypogastric, ilioinguinal, lateral cutaneous nerve of thigh and femoral nerve. These exit from the lateral

border of psoas major. Identify obturator and lumbosacral trunk seen on the medial aspect of the muscle.

Locate the lumbar part of the right and left sympathetic chains. Trace their branches into the coeliac and superior mesenteric plexuses of nerves in addition to giving rami communicans to the lumbar spinal nerves.

ABDOMINAL AORTA

Beginning Course and Termination

The abdominal aorta begins in the midline at the aortic opening of the diaphragm, opposite the lower border of vertebra T12. It runs downwards and slightly to the left in front of the lumbar vertebrae, and ends in front of the lower part of the body of vertebra L4, about 1.25 cm to the left of the median plane, by dividing into the right and left common iliac arteries (Fig. 27.1). Due to the forward convexity of the lumbar vertebral column, aortic pulsations can be felt in the region of the umbilicus, particularly in slim persons.

Relations

Anteriorly

From above downwards, the aorta is related to:

- 1 Coeliac and aortic plexuses.
- 2 Body of the pancreas, with the splenic vein embedded in its posterior surface (*see* Fig. 23.15).
- 3 Third part of the duodenum (*see* Fig. 21.2).

Posteriorly

The aorta is related to:

- 1 The bodies of upper four lumbar vertebrae and the corresponding intervertebral discs (*see* Fig. 21.1).
- 2 Anterior longitudinal ligament.

To the right side of the aorta there are:

- 1 Inferior vena cava.
- 2 Right crus of the diaphragm.
- 3 Cisterna chyli and the azygos vein in the upper part.

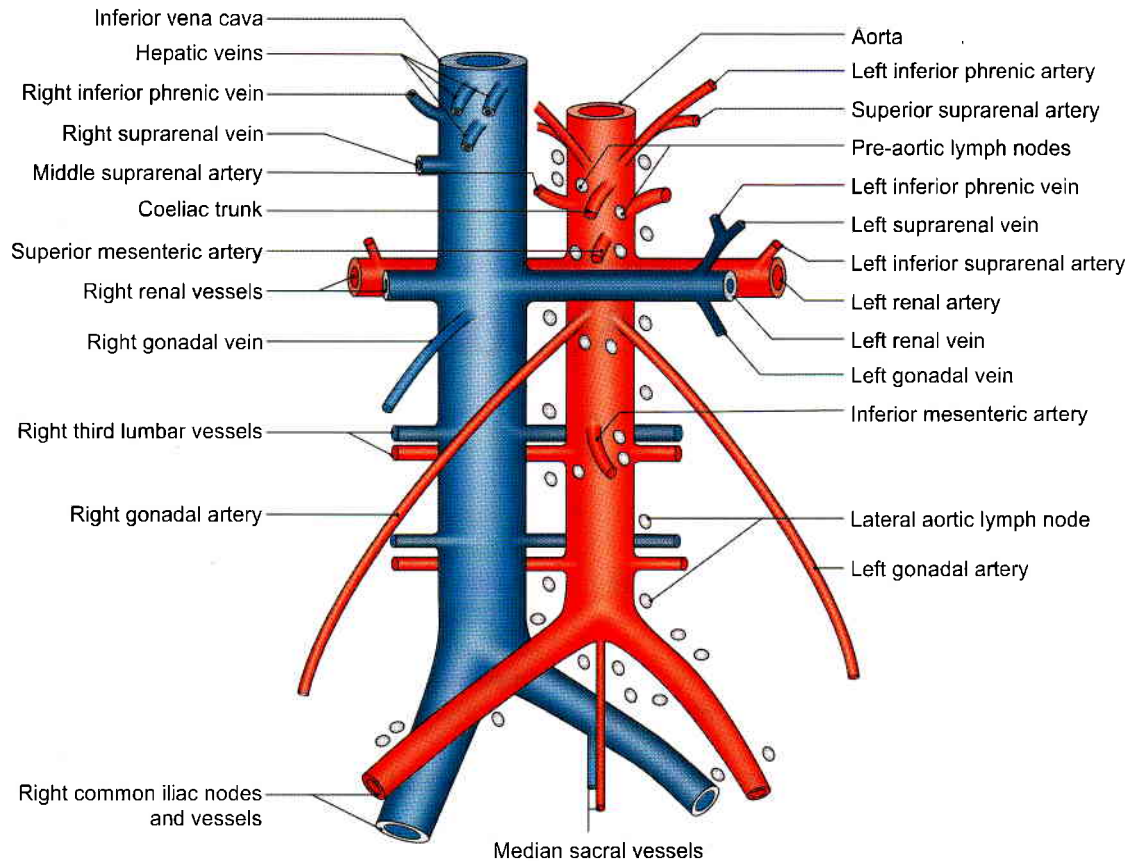


Fig. 27.1: The abdominal aorta, inferior vena cava and associated lymph nodes

To the left side of the aorta there are from above downwards:

- Left crus of the diaphragm.
- Pancreas.
- Fourth part of the duodenum.

Branches

The branches of the abdominal aorta are classified as given below (Fig. 27.1).

Ventral branches, which develop from *ventral splanchnic* or *vitelline arteries* and supply the gut. These are as follows.

- Coeliac trunk (see Chapter 21) gives left gastric, common hepatic and splenic branches.
- Superior mesenteric artery (see Chapter 21) gives inferior pancreaticoduodenal, middle colic, right colic, ileocolic and 12–15 jejunal and ileal branches.
- Inferior mesenteric artery (see Chapter 21) gives left colic, sigmoid arteries and continues as superior rectal.

Lateral branches, which develop from the *lateral splanchnic* or *mesonephric arteries* and supply the viscera derived from the intermediate mesoderm. These are right and left:

- Inferior phrenic arteries.
- Middle suprarenal arteries.

c. Renal arteries.

d. Testicular or ovarian arteries.

Dorsal branches represent the *somatic intersegmental arteries* and are distributed to the body wall. These are:

- Lumbar arteries—four pairs.
- Median sacral artery—unpaired.

Terminal branches are a pair of common iliac arteries. They supply the pelvis and lower limbs.

Inferior Phrenic Arteries

Inferior phrenic arteries arise from the aorta just above the coeliac trunk. Each artery runs upwards and laterally on the corresponding crus of the diaphragm, medial to the suprarenal gland. Each artery gives off two to three superior suprarenal arteries, and is then distributed to the diaphragm.

Middle Suprarenal Arteries

Middle suprarenal arteries arise at the level of the superior mesenteric artery. Each passes laterally and slightly upwards over the corresponding crus of the diaphragm, to reach the gland (see Fig. 25.4).

Renal Arteries

Renal arteries are large arteries which arise from the abdominal aorta just below the level of origin of the



superior mesenteric artery. The *right renal artery* passes laterally behind the inferior vena cava to reach the hilum of the right kidney. The *left renal artery* runs behind the left renal vein, and the splenic vein. Each artery gives off the inferior suprarenal and ureteral branches, and is then distributed to the kidney (Fig. 27.1).

Gonadal: Testicular or Ovarian Arteries

Gonadal arteries are small and arise from the front of the aorta a little below the origin of the renal arteries. Each artery runs downwards and slightly laterally on the psoas major. On the right side the artery crosses in front of the inferior vena cava, the ureter and the genitofemoral nerve. It passes deep to the ileum. On the left side the artery crosses in front of the ureter and the genitofemoral nerve; and passes deep to the colon (see Figs 24.24 and 24.25).

The *testicular artery* joins the spermatic cord at the deep inguinal ring, and traverses the inguinal canal. Within the cord, it lies anterior to the ductus deferens. At the upper pole of the testis, it breaks up into branches which supply the testis and the epididymis.

The *ovarian artery* crosses the external iliac vessels at the pelvic brim to enter the suspensory or infundibulopelvic ligament of the ovary. It thus enters the broad ligament and runs below the uterine tube to reach the ovary through the mesovarium. The artery gives a branch which continues medially to anastomose with the uterine artery, and supplies twigs to the uterine tube and to the pelvic part of the ureter (see Fig. 31.4).

Lumbar Arteries

Four pairs of lumbar arteries arise from the aorta opposite the bodies of the upper four lumbar vertebrae. The small, fifth pair is usually represented by the lumbar branches of the iliolumbar arteries.

The upper four lumbar arteries run across the sides of the bodies of the upper four lumbar vertebrae, passing deep to the crura (upper arteries only), deep to the psoas major and the quadratus lumborum to end in small branches between the transversus and internal oblique muscles. Each artery gives off a dorsal branch, which arises at the root of the transverse process. The dorsal branch gives off a spinal branch to the vertebral canal, and then runs backwards to supply the muscles and skin of the back.

Median Sacral Artery

Median sacral artery represents the continuation of the primitive dorsal aorta. It arises from the back of the aorta just above the bifurcation of the latter, and runs downwards to end in front of the coccyx. It supplies the rectum and anastomoses with the iliolumbar and lateral sacral arteries.

COMMON ILIAC ARTERIES

Course

These are the terminal branches of the abdominal aorta, beginning in front of vertebra L4, 1.25 cm to the left of the median plane. On each side it passes downwards and laterally and ends in front of the sacroiliac joint, at the level of the lumbosacral intervertebral disc, by dividing into the external and internal iliac arteries.

The *right common iliac artery* passes in front of the commencement of the inferior vena cava. The right common iliac vein is posterior to the vena cava above, and medial to it below (Fig. 27.1).

The *left common iliac artery* is shorter than the right artery. It is crossed at its middle by the inferior mesenteric vessels. The left common iliac vein is medial to it. The structures lying on the left ala of the sacrum, i.e. sympathetic trunk, lumbosacral trunk, into lumbar artery and obturator nerve are deep to it.

INFERIOR VENA CAVA

The inferior vena cava is formed by the union of the right and left common iliac veins on the right side of the body of vertebra L5. It ascends in front of the vertebral column, on the right side of the aorta, grooves the posterior surface of the liver, pierces the central tendon of the diaphragm at the level of vertebra T8, and opens into the lower and posterior part of the right atrium (see Fig. 26.1).

Relations

Anteriorly

From above downwards, inferior vena cava is related to:

- 1 Posterior surface of the liver.
- 2 Epiploic foramen (see Fig. 18.22).
- 3 First part of the duodenum and the portal vein.
- 4 Head of the pancreas along with the bile duct.
- 5 Third part of duodenum (see Fig. 20.10a).

Posteriorly

Above, the right crus of the diaphragm is separated from the inferior vena cava by the right renal artery, the right coeliac ganglion, and the medial part of the right suprarenal gland. Below, it is related to the right sympathetic chain and to the medial border of the right psoas.

Tributaries

- 1 The *common iliac veins* formed by the union of the external and internal iliac veins unite to form the inferior vena cava. Each vein receives an iliolumbar vein. The median sacral vein joins the left common iliac vein (Fig. 27.1).
- 2 The *third and fourth lumbar veins* run along with the corresponding arteries and open into the posterior



aspect of the inferior vena cava. The veins of the left side cross behind the aorta to reach the vena cava. The first and second lumbar veins end in the ascending lumbar vein, on the right and the left sides.

The ascending lumbar vein is an anastomotic channel which connects the lateral sacral, iliolumbar, and the subcostal veins. It lies within the psoas muscle, in front of the roots of the transverse processes of the lumbar vertebrae. On joining the subcostal vein it forms the azygos vein on the right side, and the hemiazygos vein on the left side.

- 3 The *right testicular or ovarian vein* opens into the inferior vena cava just below the entrance of the renal veins. The *left gonadal vein* drains into the left renal vein (Fig. 27.1).
- 4 The *renal veins* join the inferior vena cava just below the transpyloric plane. Each renal vein lies in front of the corresponding artery. The right vein is shorter than the left and lies behind the second part of the duodenum. The left vein crosses in front of the aorta, and lies behind the pancreas and the splenic vein. It receives the left suprarenal and gonadal veins (Fig. 27.1).
- 5 The *right suprarenal vein* is extremely short. It emerges from the hilum of the gland and soon opens into the inferior vena cava. The left suprarenal vein opens into the left renal vein.
- 6 The *hepatic veins* are three large and many small veins which open directly into the anterior surface of the inferior vena cava just before it pierces the diaphragm. These act as important support of liver (see Fig. 23.27).

CLINICAL ANATOMY

Thrombosis in the inferior vena cava causes oedema of the legs and back. The collateral venous circulation between the superior and inferior venae cavae is established through the superficial or deep veins, or both. The participating main superficial veins include the (i) superficial epigastric, (ii) lateral thoracic, (iii) thoracoepigastric. Other veins are internal thoracic, posterior intercostal, external pudendal and lumbo-vertebral veins (Fig. 27.2). The deep veins are the azygos, hemiazygos and lumbar veins. The vertebral venous plexus may also provide an effective collateral circulation between the two venae cavae.

Abdominal aneurysm's (dilatation of the vessel) most common site is between the renal arteries and bifurcation of the abdominal aorta).

ABDOMINAL PARTS OF AZYGOS AND HEMIAZYGOS VEINS

These veins usually begin in the abdomen. The *azygos vein* arise from the posterior surface of the inferior vena

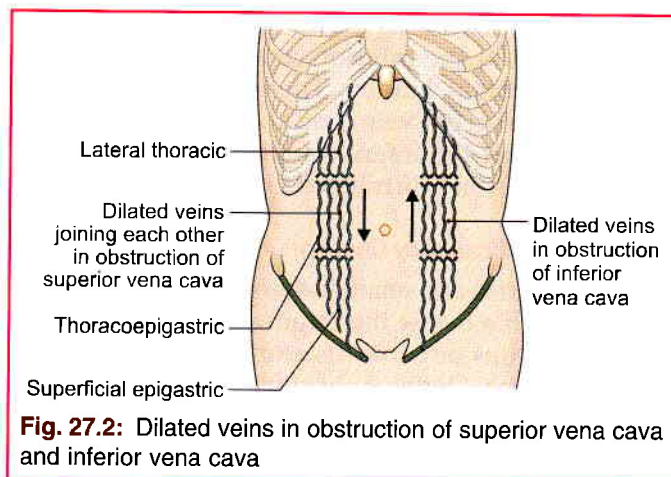


Fig. 27.2: Dilated veins in obstruction of superior vena cava and inferior vena cava

cava near the renal veins; may be formed by the union of the right ascending lumbar vein and the right subcostal vein. It enters the thorax by passing through the aortic opening of the diaphragm.

The *hemiazygos vein* is the mirror image of the lower part of the azygos vein. It arise from the posterior surface of the left renal vein, or may be formed by the union of the left ascending lumbar vein and the left subcostal vein. It enters the thorax by piercing the left crus of the diaphragm.

LYMPH NODES OF POSTERIOR ABDOMINAL WALL

These are the external iliac, common iliac and lumbar or aortic nodes.

The *external iliac nodes* 8 to 10 lie along the external iliac vessels, being lateral, medial and anterior to them. They receive afferents from:

- 1 Inguinal lymph nodes
- 2 Deeper layers of the infraumbilical part of the anterior abdominal wall
- 3 Adductor region of the thigh
- 4 Glans penis or clitoris
- 5 Membranous urethra
- 6 Prostate
- 7 Fundus of the urinary bladder
- 8 Cervix uteri
- 9 Part of the vagina.

Their efferents pass to common iliac nodes. The inferior epigastric and circumflex iliac nodes are outlying members of the external iliac group.

The *common iliac nodes*, 4 to 6 in number lie along the common iliac artery below the bifurcation of the aorta in front of vertebra L5 or in front of the sacral promontory. They receive afferents from the external and internal iliac nodes, and send their efferents to the lateral aortic nodes (Fig. 27.1).

The *lumbar or aortic nodes* are divided into preaortic and lateral aortic groups. The *preaortic nodes* lie directly



anterior to the abdominal aorta, and are divisible into coeliac, superior mesenteric and inferior mesenteric groups. They receive afferents from intermediate nodes associated with the subdiaphragmatic part of the gastrointestinal tract, the liver, the pancreas and the spleen (Fig. 27.1). Their efferents form the *intestinal trunks* which enter the cisterna chyli.

The *lateral aortic nodes* lie on each side of the abdominal aorta. They receive afferents from the structures supplied by the lateral and dorsal branches of the aorta and form the common iliac nodes. Their efferents from a *lumbar trunk* on each side, both of which terminate in the cisterna chyli (Fig. 27.1).

CISTERNA CHYLI

This is an elongated lymphatic sac, about 5 to 7 cm long. It is situated in front of the first and second lumbar vertebrae, immediately to the right of the abdominal aorta. It is overlapped by the right crus of the diaphragm. Its upper end is continuous with the thoracic duct. It is joined by the right and left lumbar and intestinal lymph trunks.

The lumbar trunks arise from the lateral aortic nodes, and bring lymph from the lower limbs, the pelvic wall

and viscera, the kidneys, the suprarenal glands, the testes or ovaries, and the deeper parts of the abdominal wall. The intestinal trunks bring lymph from the stomach, the intestine, the pancreas, the spleen, and the anteroinferior part of the liver.

MUSCLES OF THE POSTERIOR ABDOMINAL WALL

These are the psoas major, the psoas minor, the iliacus and the quadratus lumborum. Their attachments are given in Table 27.1 and their nerve supply and actions are given in Table 27.2. Some additional facts about the psoas major (Fig. 27.3) are given below.

Relations of the Psoas Major

In the Posterior Mediastinum

The uppermost part of the psoas major lies in the posterior mediastinum, and is related anteriorly to the diaphragm and pleura.

In the Abdomen

Its *anterolateral surface* is related to:

- 1 Medial lumbocostal arch or medial arcuate ligament and psoas fascia (see Fig. 24.4).
- 2 Peritoneum and extraperitoneal connective tissue.

Table 27.1: Attachments of muscles of the posterior abdominal wall

Muscle	Origin	Insertion
1. Psoas major This is a fusiform muscle placed on the side of the lumbar spine and along the brim of the pelvis. The psoas and the iliacus are together known as the iliopsoas, due to their common insertion and actions (Fig. 27.3)	a. From anterior surfaces and lower borders of transverse process of all lumbar vertebrae (see Fig. 15.3) b. By 5 slips, one each from the bodies of two adjacent vertebrae and their intervertebral discs, from vertebrae, T12 to L5 c. From 4 tendinous arches extending across the constricted parts of the bodies of lumbar vertebrae, between the preceding slips. The origin is a continuous one from the lower border of T12 to upper border of L5	The muscle passes behind the inguinal ligament and in front of the hip joint to enter the thigh. It ends in a tendon which receives the fibres of the iliacus on its lateral side. It is then inserted into the tip and medial part of the anterior surface of the lesser trochanter of the femur
2. Psoas minor This is a small muscle which lies in front of the psoas major. It is frequently absent	Sides of the bodies of vertebrae T12 and L1 and the disc between them	The muscle ends in a long, flat tendon which is inserted into the pecten pubis and the iliopubic eminence
3. Iliacus This is a triangular muscle (Fig. 27.3)	a. Upper 2/3rd of iliac fossa (see Fig. 2.5) b. Inner lip of the iliac crest and the ventral sacroiliac and iliolumbar ligaments c. Upper surface of the lateral part of the sacrum	Lateral part of anterior surface of the lesser trochanter. The insertion extends for 2.5 cm below the trochanter
4. Quadratus lumborum This is a quadrate muscle lying in the lumbar region. Its origin lies below and the insertion is above (see Fig. 24.4)	a. Transverse process of vertebra L5 b. Iliolumbar ligament c. Adjoining 5 cm of the inner lip of the iliac crest (see Fig. 2.3)	a. Transverse processes of upper 4 lumbar vertebrae b. Medial half of the lower border of anterior surface of the 12th rib



Table 27.2: Nerve supply and actions of muscles of the posterior abdominal wall

Muscle	Nerve supply	Actions
1. Psoas major	Branches from the roots of spinal nerve L2, L3 and sometimes L4.	<ol style="list-style-type: none"> 1. With the iliacus, it acts as a powerful flexor of the hip, joint as in raising the trunk from recumbent to sitting posture 2. Helps in maintaining stability at the hip. Balances the trunk while sitting 3. When the muscle of one side acts alone, it brings about lateral flexion of the trunk on that side 4. It is a weak medial rotator of the hip. After fracture of the neck of the femur, the limb rotates laterally
2. Psoas minor	Branches from spinal nerve L1	Weak flexor of the trunk
3. Iliacus	Branches from femoral nerve (L2, 3)	With the psoas, it flexes the hip joint
4. Quadratus lumborum	Ventral rami of spinal nerves T12 to L4	<ol style="list-style-type: none"> 1. Fixes the last rib during inspiration so that the contraction of the diaphragm takes place more effectively 2. When the pelvis is fixed, it may cause lateral flexion of the vertebral column 3. The muscles of both sides acting together can extend the lumbar vertebral column

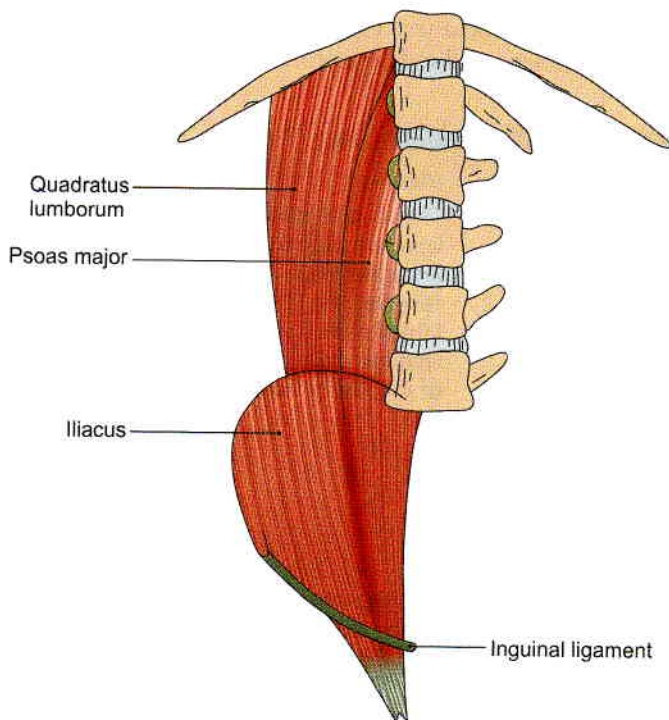


Fig. 27.3: Muscles of the posterior abdominal wall

- 3 Kidney and ureter (*see Fig. 24.6*).
- 4 Renal and gonadal vessels.
- 5 Genitofemoral nerve.
- 6 Psoas minor.
- 7 Inferior vena cava and the terminal ileum on the right side.
- 8 Colon on the left side.

The *posterior surface* is related to:

- 1 Transverse processes of lumbar vertebrae.
- 2 Lumbar plexus lies in substance of the muscle.

The *medial surface* is related to:

- 1 Bodies of the lumbar vertebrae (*see Fig. 24.6*).
- 2 Lumbar vessels.

The *medial (anterior) margin* is related to:

- 1 Sympathetic chain (*Fig. 27.5*).
- 2 Aortic lymph nodes.
- 3 Inferior vena cava on the right side.
- 4 Aorta on the left side.
- 5 External iliac vessels along the pelvic brim.

In the Thigh

Anteriorly: Femoral artery and fascia lata.

Posteriorly: Capsule of hip joint separated by a bursa.

Medially: Pectineus and femoral vein.

Laterally: Femoral nerve and iliacus (*see Fig. 3.10b*).

CLINICAL ANATOMY

Psoas abscess: The psoas is enclosed in the psoas sheath, a part of the lumbar fascia. Pus from tubercular infection of the thoracic and lumbar vertebrae may track down through the sheath into the thigh, producing a soft swelling in the femoral triangle (*Fig. 27.4*).

The typical posture of a laterally rotated lower limb following fracture of the neck of the femur is produced by contraction of the psoas muscle.

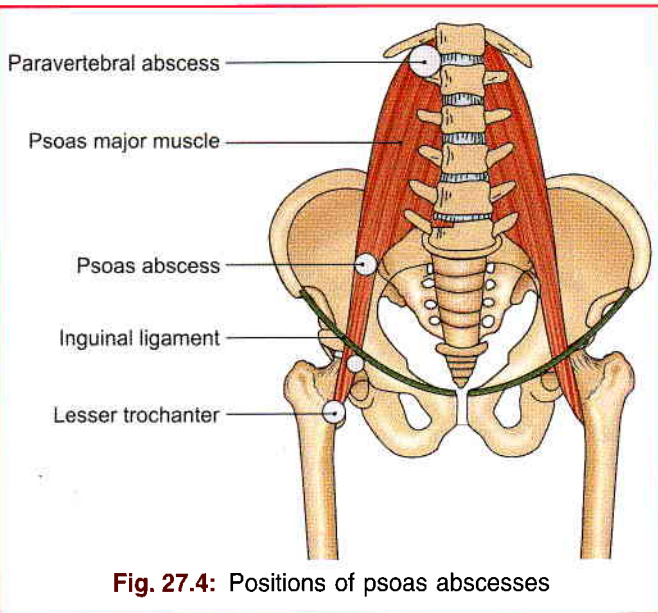


Fig. 27.4: Positions of psoas abscesses

THORACOLUMBAR FASCIA (LUMBAR FASCIA)

Lumbar fascia is the fascia enclosing the deep muscles of the back (see Fig. 24.11). It is made up of three layers—posterior, middle and anterior. The posterior layer is thickest and the anterior layer thinnest.

Extent

The posterior layer covers the loin and is continued upwards on the back of the thorax and neck. The middle and anterior layers are confined to the lumbar region.

Attachments

Posterior Layer

- *Medially*, the posterior layer is attached to the tips of the lumbar and sacral spines and the interspinous ligaments.
- *Laterally*, it blends with the middle layer at the lateral border of the erector spinae.
- *Superiorly*, it continues on to the back of the thorax where it is attached to the vertebral spines and the angles of the ribs.
- *Inferiorly*, it is attached to the posterior one-fourth of the outer lip of the iliac crest.

Middle Layer

- *Medially*, the middle layer is attached to the tips of the lumbar transverse processes and the intertransverse ligaments.
- *Laterally*, it blends with the anterior layer at the lateral border of the quadratus lumborum.
- *Superiorly*, it is attached to the lower border of the 12th rib and to the lumbocostal ligament.
- *Inferiorly*, it is attached to the posterior part of the intermediate area of the iliac crest.

Anterior Layer

- *Medially*, the anterior layer is attached to the vertical ridges on the anterior surface of the lumbar transverse processes.
- *Laterally*, it blends with the middle layer at the lateral border of the quadratus lumborum.
- *Superiorly*, it forms the lateral arcuate ligament, extending from the tip of the first lumbar transverse process to the 12th rib.
- *Inferiorly*, it is attached to the inner lip of the iliac crest and the iliolumbar ligament (see Fig. 24.11).

NERVES OF THE POSTERIOR ABDOMINAL WALL

Lumbar Plexus

The lumbar plexus lies in the posterior part of the substance of the psoas major muscle. It is formed by the ventral rami of the upper four lumbar nerves (see Fig. 3.3). The first lumbar nerve receives a contribution from the subcostal nerve, and the fourth lumbar nerve gives a contribution to the lumbosacral trunk; which takes part in the formation of the sacral plexus. The branches of the lumbar plexus are summarized.

Iliohypogastric Nerve (L1)

The *iliohypogastric nerve* (L1) emerges at the lateral border of the psoas, runs downwards and laterally in front of the quadratus lumborum, and behind the kidney and colon, pierces the transversus abdominis a little above the iliac crest, and runs in the abdominal wall supplying the anterolateral muscles.

Ilioinguinal Nerve (L1)

The *ilioinguinal nerve* (L1) has the same course as the iliohypogastric nerve, but on a slightly lower level. It exits through superficial inguinal ring.

Genitofemoral Nerve

The *genitofemoral nerve* (L1, L2 ventral divisions) emerges on the anterior surface of the psoas muscle near its medial border and runs downwards in front of the muscle. Near the deep inguinal ring it divides into femoral and genital branches. The *femoral branch* passes through the arterial compartment of the femoral sheath and is distributed to the skin of the upper part of the front of the thigh. The *genital branch* pierces the psoas sheath and enters the inguinal canal through the deep inguinal ring. In the male, it supplies the cremaster muscle, and in the female, it gives sensory branches to the round ligament of the uterus and to the skin of the labium majus (see Fig. 16.18).

Lateral Cutaneous Nerve of the Thigh

The *lateral cutaneous nerve of the thigh* (L2, L3; dorsal divisions) emerges at the lateral border of the psoas,



runs downwards and laterally across the right iliac fossa, over the iliacus and reaches the anterior superior iliac spine. Here it enters the thigh by passing behind the lateral end of the inguinal ligament (see Fig. 3.3).

Femoral Nerve

The *femoral nerve* (L2, L3, L4; dorsal divisions) emerges at the lateral border of the psoas below the iliac crest, and runs downwards and slightly laterally in the furrow between the psoas and iliacus. It lies under cover of the fascia iliaca. It passes deep to the inguinal ligament to enter the thigh lying on the lateral side of the femoral sheath. Before entering the thigh it supplies the iliacus and pectineus. In thigh it supplies quadriceps femoris and sartorius (see Fig. 3.26).

Obturator Nerve

The *obturator nerve* (L2, L3, L4; ventral divisions) emerges on the medial side of the psoas muscle and runs forwards and downwards on the pelvic wall, below the pelvic brim. Near its commencement it is crossed by the internal iliac vessels and the ureter. It enters the thigh by passing through the obturator canal. It supplies 3 adductor muscles, obturator externus and gracilis (see Fig. 4.4).

Lumbosacral Trunk

The *lumbosacral trunk* (L4, L5; ventral rami) is formed by union of the descending branch of nerve L4 with nerve L5. It enters the lesser pelvis by passing over and grooving the lateral part of the ala of the sacrum, posterior to the common iliac vessels and the medial part of the psoas. It is related medially to the sympathetic chain; and laterally to the iliolumbar artery and the obturator nerve (see Fig. 15.11). In the pelvis, it takes part in the formation of the sacral plexus.

ABDOMINAL PART OF THE AUTONOMIC NERVOUS SYSTEM

The abdomen is supplied by both sympathetic and parasympathetic nerves. The *sympathetic nerves* are derived from two sources.

- 1 The lumbar sympathetic trunk supplies somatic branches to the lower abdominal wall and the lower limb; and visceral branches for the pelvic organs (Fig. 27.5).
- 2 The coeliac plexus, formed by splanchnic nerves from the thorax, supplies all the abdominal organs, including the gonads.

The *parasympathetic nerves* are also derived from two sources.

- a. The vagus joins the coeliac plexus.
- b. The pelvic splanchnic nerves join the inferior hypogastric plexus.

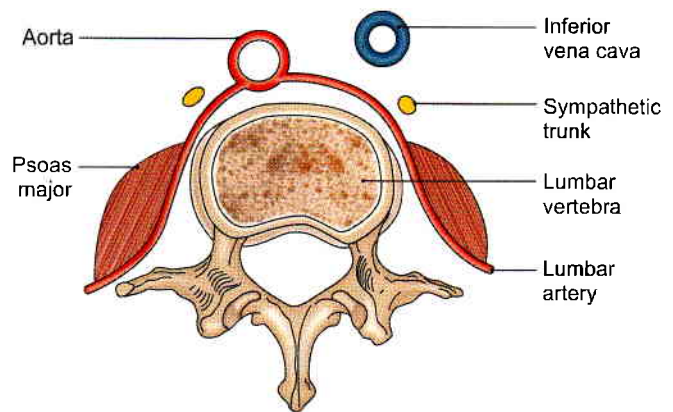


Fig. 27.5: Transverse section through the lumbar region showing location of the lumbar sympathetic chain

Lumbar Sympathetic Chain

This is ganglionated chain situated on either side of the bodies of the lumbar vertebrae containing five ganglia.

The lumbar sympathetic chain is continuous with the thoracic part deep to the medial arcuate ligament. It runs vertically downwards along the medial margin of the psoas major, and across the lumbar vessels. On the right side, it is overlapped by the inferior vena cava, and on the left by the lateral aortic lymph nodes.

The lumbar chain ends by becoming continuous with the sacral part of the sympathetic chain behind the common iliac vessels.

The anterior primary rami of the first and second lumbar nerves send white rami communicans to the corresponding ganglia.

Branches

Lateral

All the five lumbar nerves receive grey rami communicans from the corresponding lumbar ganglia. The grey rami carry fibres which are distributed to the lower abdominal wall and to the lower limb (Fig. 27.6).

Medial

The lumbar splanchnic nerves are generally four in number. The upper two join the coeliac and aortic plexuses, and the lower two join the superior hypogastric plexus.

Coeliac Ganglia and Coeliac Plexus

The *coeliac ganglion* (Fig. 27.7) is the largest ganglion in the body, situated one on each side of the coeliac trunk. Each ganglion is irregular in shape and is usually divided into a larger upper part which receives the greater splanchnic nerve, and a smaller lower part; aorticorenal ganglion which receives the lesser splanchnic nerve.

The *coeliac plexus* or solar plexus (Fig. 27.7) is closely related to the coeliac ganglion. The plexus is situated on

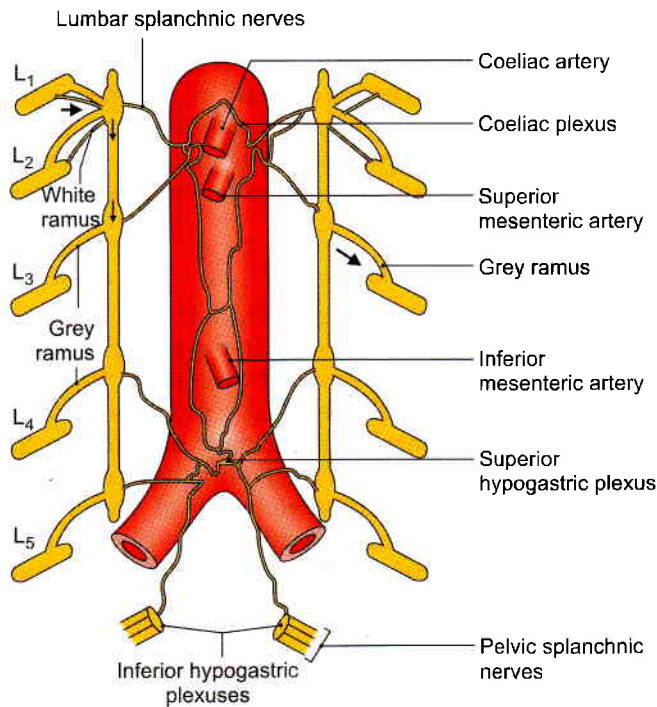


Fig. 27.6: The lumbar sympathetic chain and its branches. L1–L5 = lumbar spinal nerves; and G = lumbar sympathetic ganglion

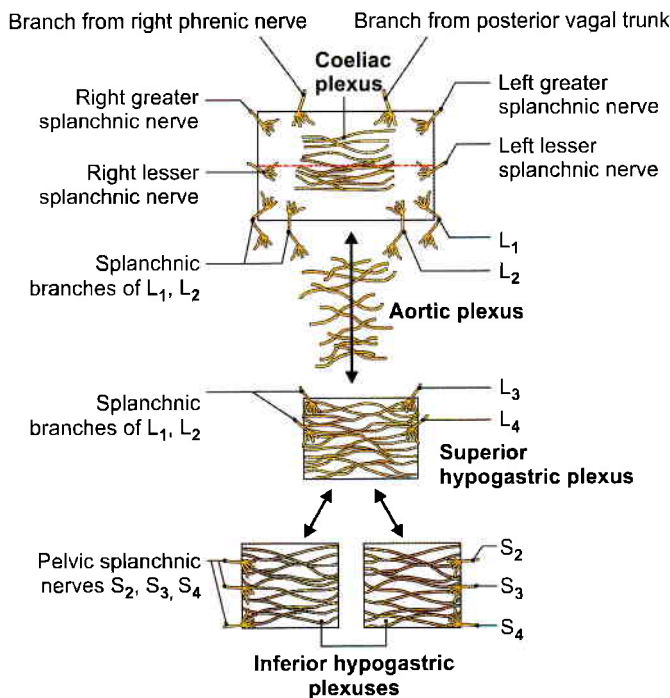


Fig. 27.7: Scheme to show the connections of the coeliac, superior hypogastric and inferior hypogastric plexuses

the aorta around the coeliac trunk and around the root of the superior mesenteric artery. The plexus extends on to the crura of the diaphragm. It is overlapped by the

inferior vena cava and by the pancreas. The fibres making up the plexus are as follows:

- a. Preganglionic sympathetic fibres reach it through the greater and lesser splanchnic nerves.
- b. Postganglionic sympathetic fibres arising in the coeliac ganglion.
- c. Preganglionic vagal fibres are derived from the posterior vagal trunk containing fibres from both the right and left vagal nerves. The fibres from the right vagus predominate.
- d. Sensory fibres from the diaphragm reach the coeliac plexus along the inferior phrenic arteries.

Branches

The coeliac plexus forms a number of secondary plexuses which surround branches of the aorta.

- 1 The *phrenic plexus* passes along the inferior phrenic artery to the suprarenal gland. The right phrenic plexus contains a right phrenic ganglion.
- 2 The *hepatic plexus* is distributed to the liver, the gallbladder and the bile ducts.
- 3 The *left gastric plexus* passes to the stomach.
- 4 The *splenic plexus* supplies the vessels and smooth muscle of the spleen.
- 5 The *suprarenal plexus* contains *preganglionic fibres*, that end in relation to the chromaffin cells of the suprarenal gland. These cells are homologous with postganglionic sympathetic neurons.
- 6 The *renal plexus* is formed by filaments from the coeliac plexus, the aorticorenal ganglion, the lowest thoracic splanchnic nerve, the first lumbar splanchnic nerve and the aortic plexus. It supplies the kidney and the upper part of the ureter.
- 7 The *testicular plexus* supplies the testis, the epididymis and the vas deferens.
- 8 The *ovarian plexus* supplies the ovary and the uterine tube.
- 9 The *superior mesenteric plexus* contains a superior mesenteric ganglion, and supplies the territory of the superior mesenteric artery.
- 10 The *abdominal aortic plexus* or intermesenteric plexus is formed by the coeliac plexus and filaments from the first and second lumbar splanchnic nerves (Fig. 27.8). It is situated on the sides and the front of the aorta, between the origins of the superior and inferior mesenteric arteries. Actually it is made up of four to twelve intermesenteric nerves connected by oblique filaments. It is continuous above with the coeliac plexus and below with the superior hypogastric plexus. Its branches form parts of the testicular, inferior mesenteric, iliac and superior hypogastric plexuses, and supply the inferior vena cava.

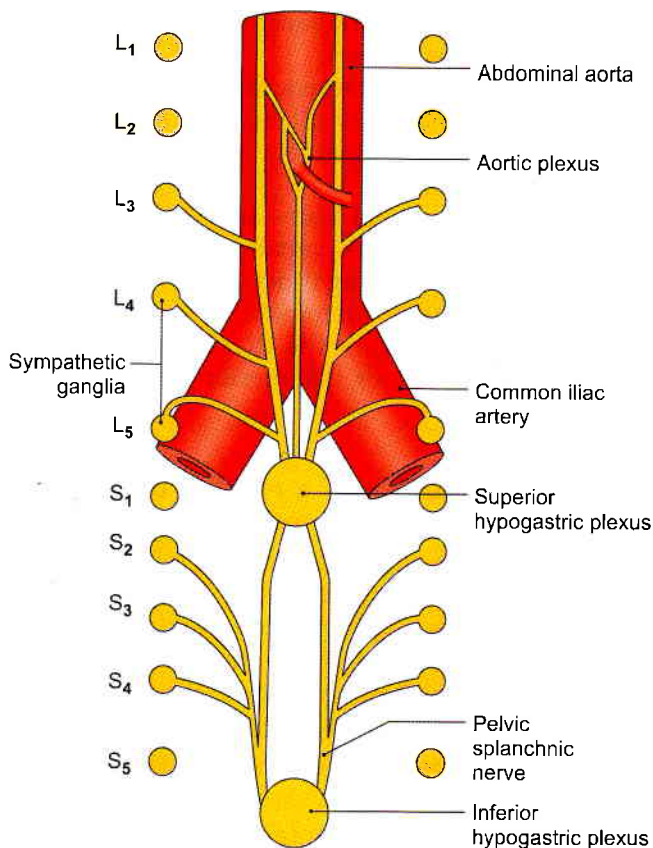


Fig. 27.8: Formation of plexuses

The *inferior mesenteric plexus* is formed chiefly by fibres from the aortic plexus. It is distributed to the territory of the inferior mesenteric artery.

Superior Hypogastric Plexus (Presacral Nerve)

The superior hypogastric plexus lies in front of the bifurcation of the abdominal aorta, the left common iliac vein, the median sacral vessels, the body of fifth lumbar vertebra, the promontory of the sacrum, and between the two common iliac arteries. Though it is often called the *presacral nerve*, it is neither a single nerve nor presacral in position. The plexus lies more towards the left, and contains scattered nerve cells (Fig. 27.8).

The plexus is formed by fibres from the following sources.

Sympathetic Nerves

- 1 Descending fibres from the aortic plexus.
- 2 Third and fourth lumbar splanchnic nerves.

Parasympathetic Nerves

Fibres from the pelvic splanchnic nerves reach it through the inferior hypogastric plexus. Usually these fibres ascend through the left part of the superior hypogastric plexus, cross the sigmoid and left colic vessels, and are distributed along the vessels as well as independently to the derivatives of the hindgut.

Branches

- 1 Inferiorly, the plexus divides into the right and left hypogastric nerves which descend into the pelvis and form the two inferior hypogastric plexuses.
- 2 Superiorly, the hypogastric plexus also gives off branches to the ureteric, testicular or ovarian, and the common iliac plexuses.

Inferior Hypogastric Plexuses

There are two plexuses, right and left. Each inferior hypogastric or pelvic plexus lies in the extraperitoneal connective tissue of the pelvis. In the male, it lies on the side of the rectum, the seminal vesicle, the prostate and the posterior part of the urinary bladder. In the female, it lies on the side of the rectum, the cervix, the vaginal fornix and the posterior part of the urinary bladder; and also extends into the base of the broad ligament of the uterus. The plexus contains numerous small ganglia. The fibres forming the inferior hypogastric plexuses are as follows:

Sympathetic nerves (T10 to L2)

- 1 These are chiefly derived from the hypogastric nerve which is represented either by a single nerve or by a plexus.
- 2 A few sympathetic fibres come from sympathetic ganglia.

Parasympathetic nerves (S2, S3, S4)

These are derived from the pelvic splanchnic nerves. They relay in the walls of the viscera supplied.

Branches

Branches from the inferior hypogastric plexus are distributed to the pelvic viscera and some abdominal viscera, either directly or along the branches of the internal iliac artery.

Parasympathetic System

As already noted the parasympathetic supply of the abdomen proper, comes from the vagi, and of the pelvis and hindgut from the pelvic splanchnic nerves or *nervi erigentes* (S2, S3, S4). These fibres are distributed through the coeliac and inferior hypogastric plexuses respectively.

Functional Considerations

In general, the *sympathetic nerves* are vasomotor, motor to sphincters, inhibitory to peristalsis, and sensory to all the viscera supplied. The *parasympathetic nerves*, on the other hand, are motor and secretomotor to the gut and the glands associated with it.

LAYERS OF THE ABDOMEN

The following 6 layers in the abdomen are shown in Figs 27.9 to 27.14.



Layer 1

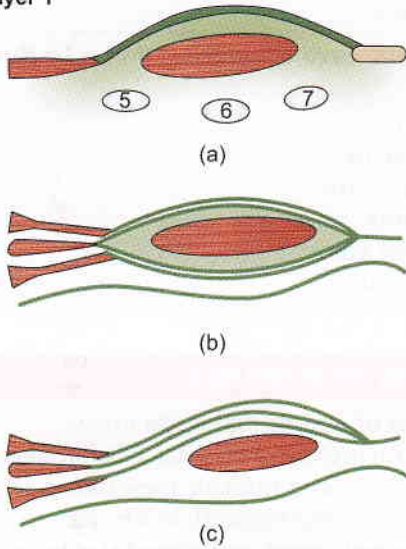


Fig. 27.9: Anterior abdominal wall

Layer 2

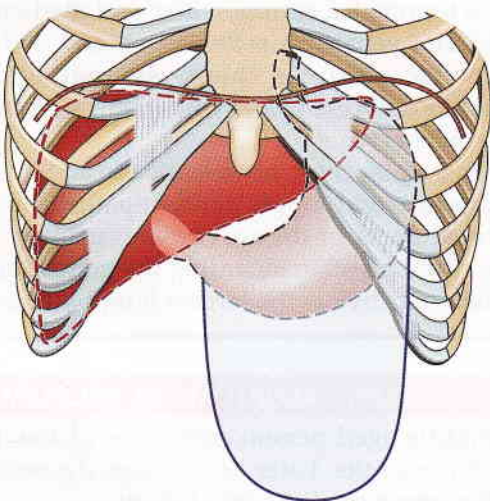


Fig. 27.10: Liver, stomach and greater omentum

Layer 3

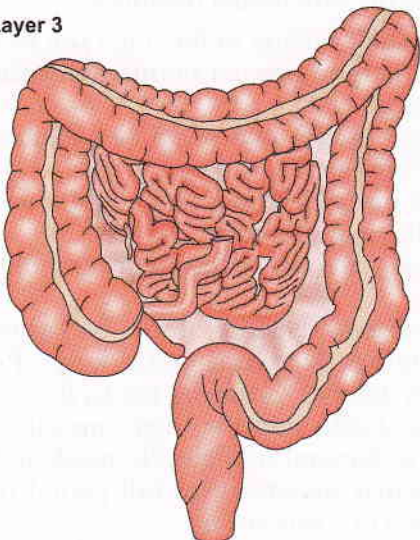


Fig. 27.11: Most of small intestine appendix, caecum and colon

Layer 4

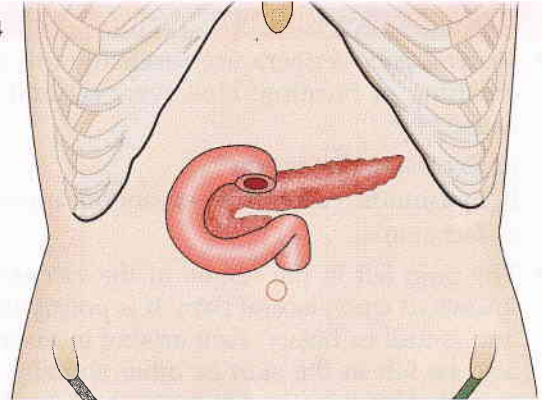


Fig. 27.12: Duodenum with pancreas

Layer 5

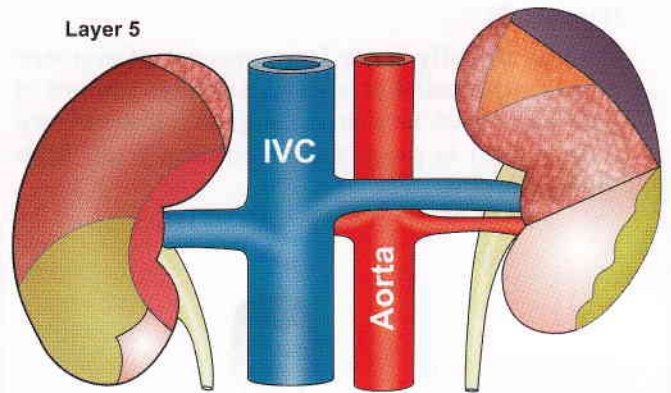


Fig. 27.13: Kidneys with large blood vessels

Layer 6

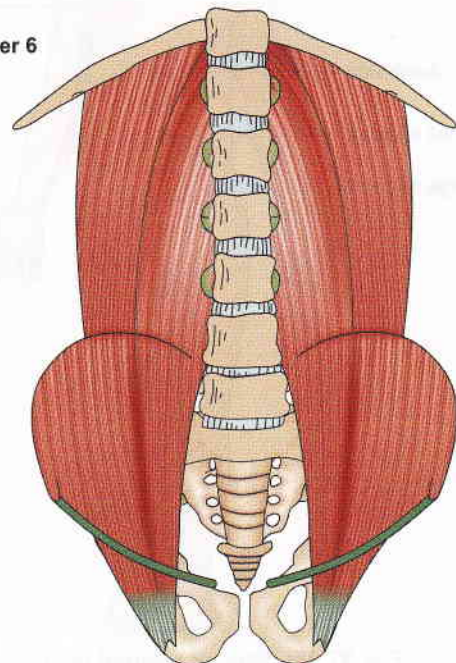


Fig. 27.14: Muscles of posterior abdominal wall



CLINICAL ANATOMY

- **Visceral pain:** Viscera are insensitive to cutting, crushing or burning. However, visceral pain is caused by:
 - Excessive distension
 - Spasmodic contraction of smooth muscle
 - Ischaemia.
- The pain felt in the region of the viscus itself is known as true visceral pain. It is poorly localized and is dull or heavy. Pain arising in viscera may also be felt in the skin or other somatic tissues, supplied by somatic nerves arising from the same spinal segment. This kind of pain is called *referred pain*. If the inflammation spreads from a diseased viscus to the parietal peritoneum it causes *local somatic pain* in the overlying body wall (Fig. 27.15).

Viscera usually have low amount of sensory output, whereas skin is an area of high amount of sensory output. So pain arising from low sensory output area is projected as coming from high sensory output area.

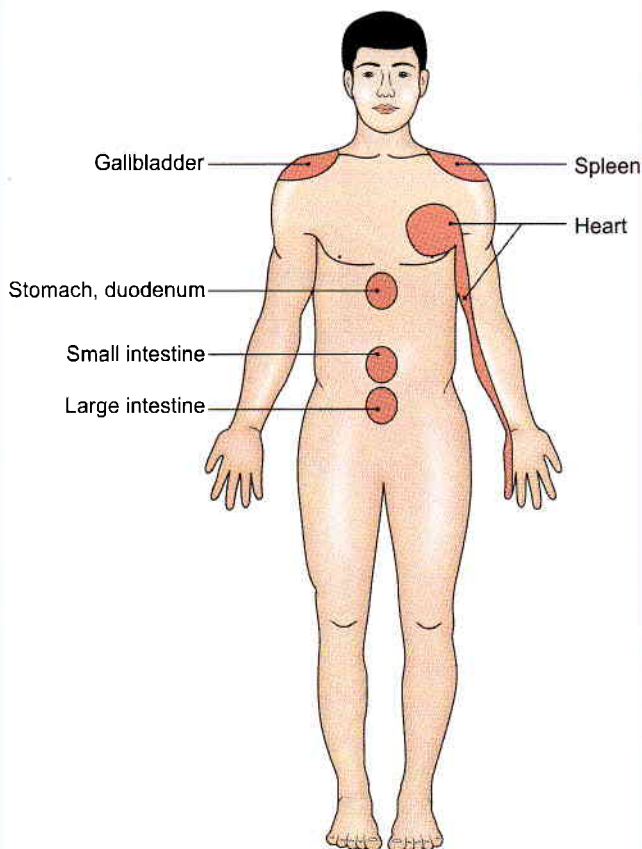


Fig. 27.15: Sites of referred pain

Mnemonics

Inferior vena cava tributaries "I like To Rise So High"

Iliac veins
Lumbar veins
Testicular veins
Renal veins
Suprarenal veins
Hepatic veins

FACTS TO REMEMBER

- Branches of abdominal aorta are:
 - 3 ventral unpaired visceral: Coeliac axis, superior mesenteric and inferior mesenteric arteries
 - 4 lateral paired visceral: Inferior phrenic, middle suprarenal, renal and gonadal arteries
 - 4 dorsal paired: 4 pairs of lumbar arteries
 - 3 terminal: 2 common iliac and median sacral
- Inferior vena cava is the largest and widest vein.
- Coeliac plexus is chiefly sympathetic. It also contains fibres of parasympathetic system through vagus nerve.
- Pelvic splanchnic nerves arise from S2, S3 and S4 segments and supply parasympathetic fibres to the distal parts of digestive tube, urinary bladder, urethra, prostate including the genital organs.
- Cisterna chyli is the largest lymphatic sac.

CLINICOANATOMICAL PROBLEM

A middle aged person complains of low backache for few months. Later he developed a soft swelling in the upper medial part of thigh

- What is this swelling likely to be?
- What is the differential diagnosis?

Ans: The soft swelling in the thigh can be enlarged inguinal lymph nodes, a hernia, varicose vein or psoas abscess.

Enlarged lymph nodes can be excluded after a course of antibiotics.

Hernia protrudes only on coughing as it raises intra-abdominal pressure.

Varicose veins can be seen in the rest of the lower limb.

Psoas abscess: History of low backache with X-ray showing vertebral pathology. Pus from tubercular lumbar vertebrae tracks down through the psoas sheath into the thigh, producing a soft swelling in femoral triangle. He needs to be given antitubercular treatment for full period under the supervision of a physician.



MULTIPLE CHOICE QUESTIONS

1. Ovarian artery is a branch of:
a. Abdominal aorta b. Common iliac artery
c. Internal iliac d. External iliac
2. Left gonadal vein drains into:
a. Internal iliac vein b. Inferior vena cava
c. Left renal vein d. Vena azygos
3. Following are ventral branches of aorta *except*:
a. Coeliac axis
b. Superior mesenteric artery
c. Inferior mesenteric artery
d. Gonadal artery
4. Following are lymph nodes of posterior abdominal wall *except*:
a. Deep inguinal b. External iliac
c. Common iliac d. Aortic group
5. Layers of thoracolumbar fascia are following *except*:
a. Anterior layer b. Middle layer
c. Medial layer d. Posterior layer

ANSWERS

1. a 2. c 3. d 4. a 5. c



Perineum

Women must not depend upon the protection of men, but must be taught to protect themselves

—SAnthony

INTRODUCTION

Perineum is the region at the lower end of the trunk, in the interval between the two thighs. The external genitalia are located, in the perineum. The perineum forms the lower division of the pelvis that lies below the pelvic diaphragm, formed by the levator ani and coccygeus, and fills in the pelvic outlet or inferior aperture of the pelvis.

In males there are two openings, one of the gastrointestinal system and the other being the common opening of urinary and genital system. In females there are three separate openings, one each of the gastrointestinal, genital and urinary systems. The perineal body supports the reproductive system. Its injury without repair, may lead to prolapse of the uterus. Pudendal nerve supplies muscles, skin, mucous membrane of both anal and urogenital triangles comprising the perineum. Pudendum means "to be ashamed of".

SUPERFICIAL BOUNDARIES

Anteriorly: The scrotum in males, and the mons pubis in females (Figs 28.1 and 28.2).

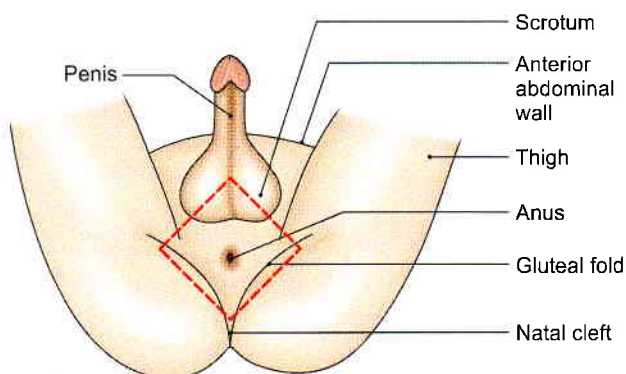


Fig. 28.1: The male perineum. Interrupted lines indicate the outlines of pelvic outlet

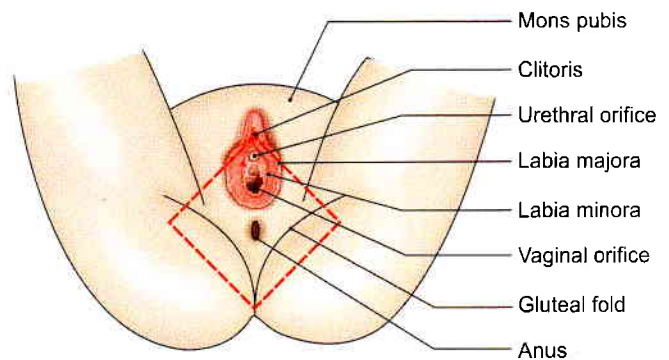


Fig. 28.2: The female perineum. Interrupted lines indicate the position of pelvic outlet

Posteriorly: The buttocks.

On each side: The upper part of the medial side of the thigh.

DEEP BOUNDARIES OF THE PERINEUM

The deep boundaries of the perineum are the same as those of the pelvic outlet.

Anteriorly: Upper part of the pubic arch and the arcuate or inferior pubic ligament (Fig. 28.3).

Posteriorly: Tip of the coccyx.

On each side

- Conjoined ischiopubic rami.
- Ischial tuberosity.
- Sacrotuberous ligament.

Divisions of the Perineum

A transverse line joining the anterior parts of the ischial tuberosities, and passing immediately anterior to the anus, divides the perineum into two triangular areas, a posterior, *anal region* or triangle, and an anterior, *urogenital region* or triangle (Fig. 28.3).

The *anal region* contains the termination of the anal canal in the median plane and an ischioanal fossa on each side.

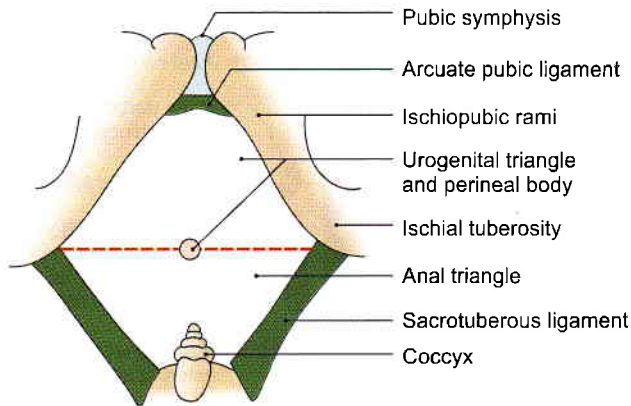


Fig. 28.3: Boundaries of perineum. Interrupted line shows the division of perineum into urogenital and anal regions

Urogenital region contains the external urogenital organs. In males, the urethra enclosed in the root of penis, partly hidden anteriorly by the scrotum; and in females, the female external genital organs.

In the urogenital region, there are the superficial perineal space or pouch and the deep perineal space or pouch.

The chief neurovascular bundle of the perineum occupies a fascial tunnel, the *pudendal canal*, and contains the pudendal nerve and the internal pudendal vessels. The pudendal canal lies in the lateral wall of the ischioanal fossa.

ANAL REGION

DISSECTION

Clean the sacrotuberous and sacrospinous ligaments. Identify coccyx in the midline posteriorly and locate the ischial tuberosity. Define the ischiopubic rami till the lower margins of pubic symphysis anteriorly.

Identify the openings of urethra, anal canal and vagina if it is a female cadaver. Define perineal body in the centre of perineum. Dissect the parts of external anal sphincter.

Pass a forceps downwards and backwards deep to the membranous layer of the superficial fascia of the anterior abdominal wall.

In the male, expose the membranous layer in the perineum. Make an incision in the membranous layer on one side and dissect the ischiocavernosus, bulbospongiosus and superficial transverse perineal muscles, nerves, blood vessels present in the superficial perineal space. The posterior scrotal/labial vessels and nerves pierce the posterolateral corner of perineal membrane to enter the superficial perineal space (Fig. 28.4).

In the female, remove the fat from the labium majus and expose the membranous layer. Incise it and expose the posterior part of this space and all its contents both in the male and female cadavers. Note the posterior limit where the membranous layer passes superiorly to fuse with the perineal membrane. Identify the various female external genital organs.

Identify the structures piercing the perineal membrane in both male and female. Note the ill-defined nature of the perineal membrane in female as it is pierced by vagina in addition to urethra.

Dissect the inferior rectal vessels and nerve and follow them to the lateral wall of the ischioanal fossa. Remove the fat from the ischioanal fossa. Identify and trace the pudendal nerve and vessels in the fascial pudendal canal on the lateral wall of the ischioanal fossa.

Cutaneous Innervation

The *inferior rectal nerve* (S2, S3, S4) supplies the skin around the anus and over the ischioanal fossa. The *perineal branch of the fourth sacral nerve* supplies the skin posterior to the anus.

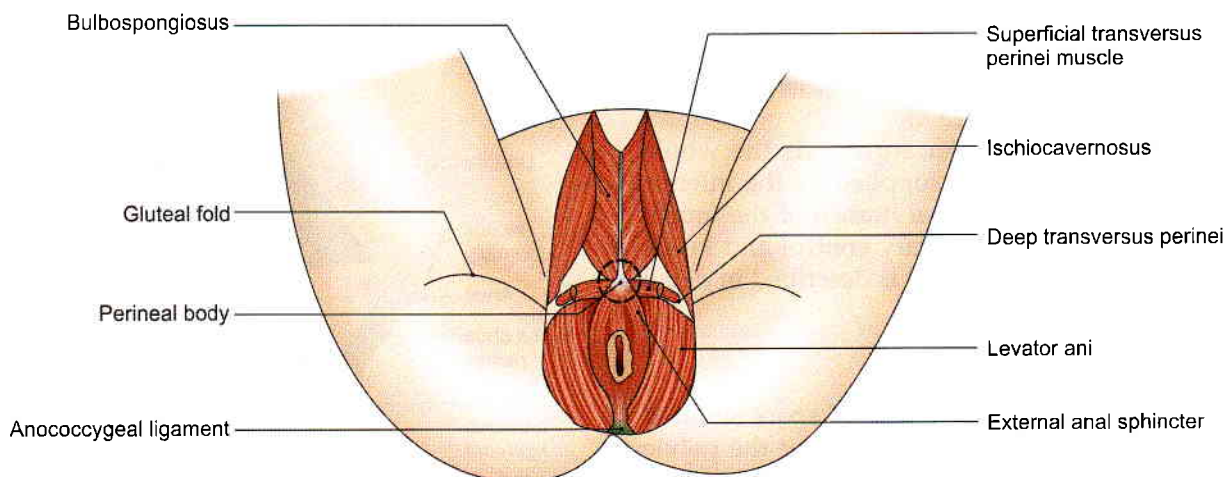


Fig. 28.4: Perineal body and the anococcygeal ligament in male



Superficial Fascia

It contains a large amount of fat which fills the ischioanal fossa.

Deep Fascia

It is formed by the inferior fascia of the pelvic diaphragm and the fascia covering the obturator internus below the attachment of the levator ani.

Anococcygeal Ligament

It is a fibrofatty mass permeated with muscle fibres derived from the levator ani and the external anal sphincter. It extends from the anus to the tip of the coccyx, and supports the rectum (Fig. 28.4).

PERINEAL BODY

The perineal body, or the central point of the perineum, is a fibromuscular node situated in the median plane, about 1.25 cm in front of the anal margin and close to the bulb of the penis. Ten muscles of the perineum converge and interlace in the perineal body.

Two unpaired:

- External anal sphincter.
- Fibres of longitudinal muscle coat of anal canal.

Paired:

- Bulbospongiosus.
- Superficial and deep transversus perinei.
- Levator ani.

All these converge and interlace in the perineal body. Nine are visible in Fig. 28.4. Last one is unstriated fibres of longitudinal muscle coat of the anal canal.

The perineal body is very important in the female for support of the pelvic organs. Sphincter urethrovaginalis in female is also attached here. It may be damaged during parturition or childbirth. This may result in prolapse of the urinary bladder, the uterus, the ovaries and even of the rectum.

EXTERNAL ANAL SPHINCTER

Anal canal is surrounded in its upper three-fourths by the internal anal sphincter which ends below at the level of white line of Hilton (Fig. 28.5).

The external anal sphincter surrounds the whole length of the anal canal. It is supplied by the inferior rectal nerve and by the perineal branch of the fourth sacral nerve. It is under voluntary control and keeps the anus and anal canal closed. It is described in detail in Chapter 33.

ISCHIOANAL FOSSA

The ischioanal fossa is a wedge-shaped space situated one on each side of the anal canal below the pelvic diaphragm. Its base is directed downwards, towards the surface. The apex is directed upwards.

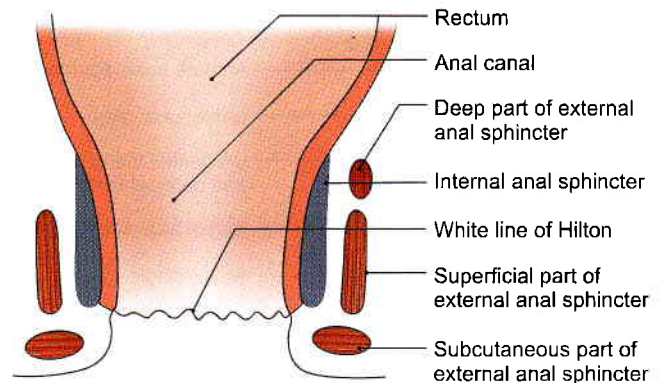


Fig. 28.5: The external and internal anal sphincters

Dimensions

Length (anteroposteriorly), 5 cm; width (side to side), 2.5 cm; and depth (vertically), 5 to 6.2 cm.

Boundaries

The *base* is formed by the skin.

The *apex* is formed by the line where the obturator fascia meets the inferior fascia of the pelvic diaphragm or anal fascia. The line corresponds to the origin of the levator ani from the lateral pelvic wall.

Anteriorly, the fossa is limited by the posterior border of the perineal membrane (but for the anterior recess of the fossa) (Fig. 28.6).

Posteriorly, the fossa reaches:

- a. Lower border of the gluteus maximus.
- b. Sacrotuberous ligament.

The *lateral wall* is vertical, and is formed by:

- a. Obturator internus with the obturator fascia.
- b. Medial surface of the ischial tuberosity, below the attachment of obturator fascia (Fig. 28.7).

The *medial wall* slopes upwards and laterally, and is formed by:

- a. The external anal sphincter, with the fascia covering it in the lower part.
- b. The levator ani with the anal fascia in the upper part (Fig. 28.7).

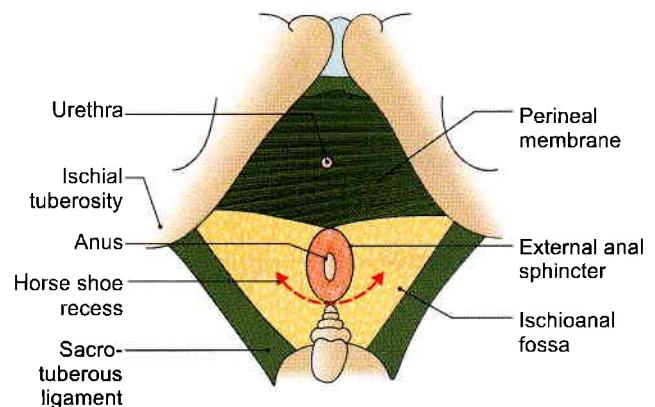


Fig. 28.6: Surface view of the ischioanal fossa, and perineal membrane

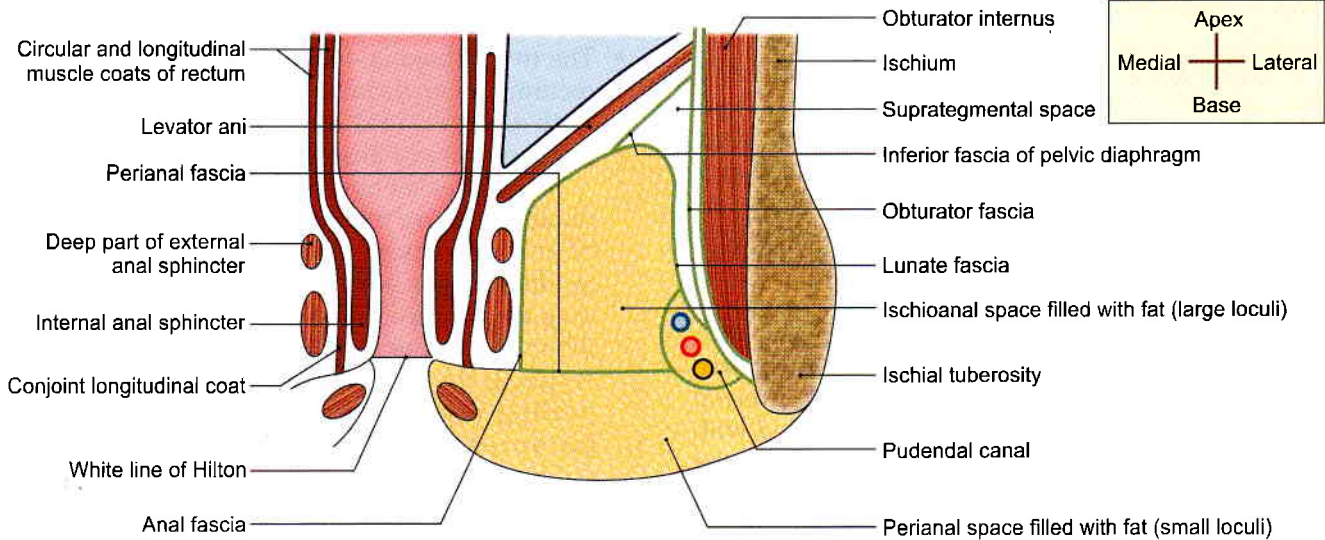


Fig. 28.7: Coronal section through the ischioanal fossa

Recesses

These are narrow extensions of the fossa beyond its boundaries.

- 1 The *anterior recess* extends forwards above the perineal membrane, reaching almost up to the posterior surface of the body of the pubis. It is closely related to the prostate or the vagina (Fig. 28.8).
- 2 The *posterior recess* is smaller than the anterior. It extends deep to sacrotuberous ligament.
- 3 The *horseshoe recess* connects the two ischioanal fossae behind the anal canal (Fig. 28.6).

Spaces and Canals of the Fossa

The arrangement of the fascia in this region forms the following spaces.

Perianal Space

The perianal fascia is in the form of a septum that passes laterally from the lower end of the longitudinal coat of the anal canal. It extends medially from the white line of Hilton to the pudendal canal laterally. It separates a shallow subcutaneous *perianal space* from the deep *ischioanal space*. The fat in the perianal space is tightly arranged in small loculi formed by complete septa. The infections of this space are, therefore, very painful due to the tension caused by swelling.

Ischioanal Space

This is large and deep. The fat in this space is loosely arranged in large loculi formed by incomplete delicate septa. The infections of this space are, therefore, least

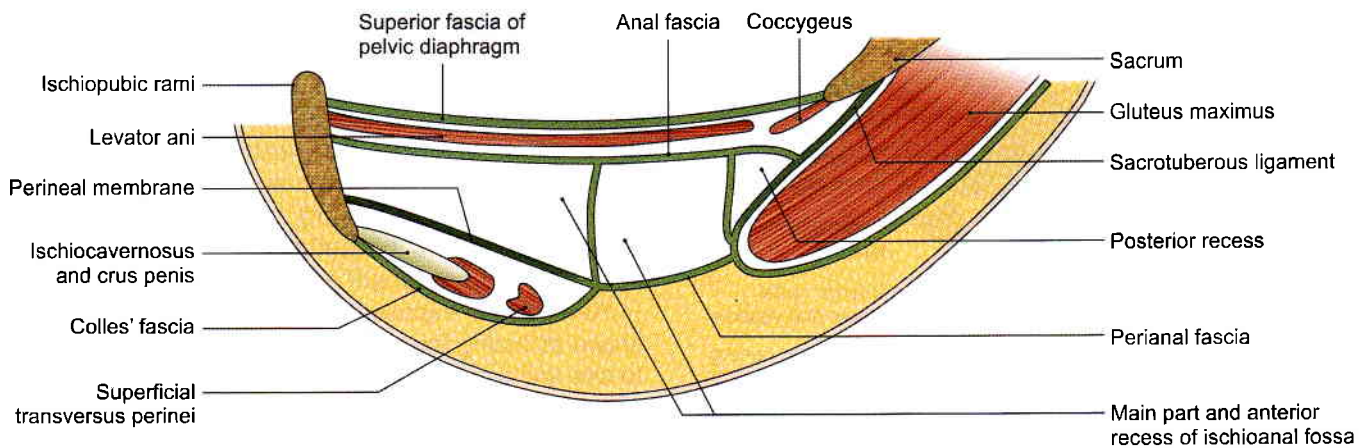


Fig. 28.8: Parasagittal section through the ischioanal fossa, showing its recesses



painful because swelling can occur without tension (Fig. 28.7).

The *lunate fascia* arches over the ischioanal fat. It begins laterally at the pudendal canal and merges medially with the fascia covering the deep part of the external anal sphincter. The fascia divides the ischioanal space into:

- a. *Supratsegmental space*, above the fascia.
- b. *Tegmental space*, below the fascia.

Pudendal Canal

This is a fascial canal in the lateral wall of the ischioanal fossa, enclosing the pudendal nerve and internal pudendal vessels. The fascia of the canal is fused with the lower part of the obturator fascia laterally, with the lunate fascia above, with the perianal fascia medially, and with the falciform process of the sacrotuberous ligament below.

Contents of Ischioanal Fossa

- 1 Ischioanal pad of fat.
- 2 Inferior rectal nerve and vessels. They pass through the fossa from lateral to medial side. They arch upwards above the fat (Fig. 28.9) to supply mucous membrane, external sphincter and the skin around the anus.
- 3 Pudendal canal with its contents. This canal lies along the lateral wall of the fossa (Fig. 28.7).
- 4 Posterior scrotal or posterior labial (in females) nerves and vessels. They cross the anterolateral part of the fossa and enter the urogenital triangle.
- 5 Perineal branch of the fourth sacral (S4) nerve. It enters the posterior angle of the fossa and runs over the levator ani to the external anal sphincter.
- 6 Perforating cutaneous branches of nerves S2, S3. They appear at the lower border of the gluteus maximus, in the posterior part of the fossa.

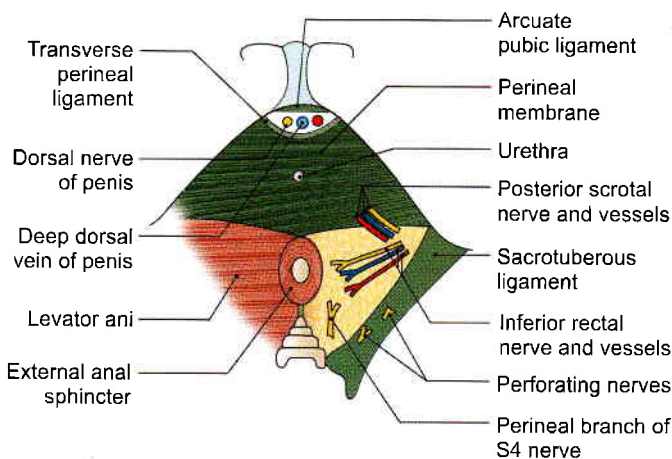


Fig. 28.9: Surface view of the ischioanal fossa, showing some of its contents

CLINICAL ANATOMY

- The two ischioanal fossae allow distention of the rectum and anal canal during passage of faeces.
- Both the perianal and ischioanal spaces are common sites of abscesses (Fig. 28.10).

Sometimes an abscess may burst into the anal canal or rectum internally, and on to the surface of the perineum externally. In this way an ischioanal type of *anorectal fistula* or *fistula in ano* may be produced. The most common site of the internal opening is in the floor of one of the anal crypts. If the abscess bursts only externally, and healing does not follow, an *external sinus* is produced. Through the horseshoe recess a unilateral abscess may become bilateral.

- The ischioanal fat acts as a cushion-like support to the rectum and anal canal. Loss of this fat in debilitating diseases like diarrhoea in children may result in *prolapse of the rectum*.
- The occasional gap between the tendinous origin of levator ani and the obturator fascia is known as *hiatus of Schwalbe*. Rarely pelvic organs may herniate through this gap into the ischioanal fossa, resulting in an *ischioanal hernia*.

MALE PERINEUM

DISSECTION

Place a finger in the ischioanal fossa and push it gently forwards. It will pass easily above the urogenital diaphragm, lateral to levator ani. Strip the ischio-cavernosus muscles from the crus of the penis or clitoris. Trace them to their termination.

Detach the superficial perineal muscles, including right crus of the penis from the ischiopubic rami. Turn it forwards to expose the deep artery and vein on the superior surface of perineal membrane also called inferior fascia of urogenital diaphragm.

In the male detach the bulb of the penis from the central perineal tendon. Turn it forwards to expose the urethra and the artery of the bulb.

In the female raise the posterior end of the bulb of the vestibule to expose the greater vestibular gland.

Detach the perineal membrane from the pubic arch on the right side. Carefully, reflect the membrane medially to visualise the urethra and a pair of posteriorly placed deep transversus perinei muscles.

Remove the exposed muscles of the deep perineal space including the endopelvic fascia. Clean the area to see the perineal surface of the levator ani.

Male External Genital Organs

These have been described in Chapter 17.

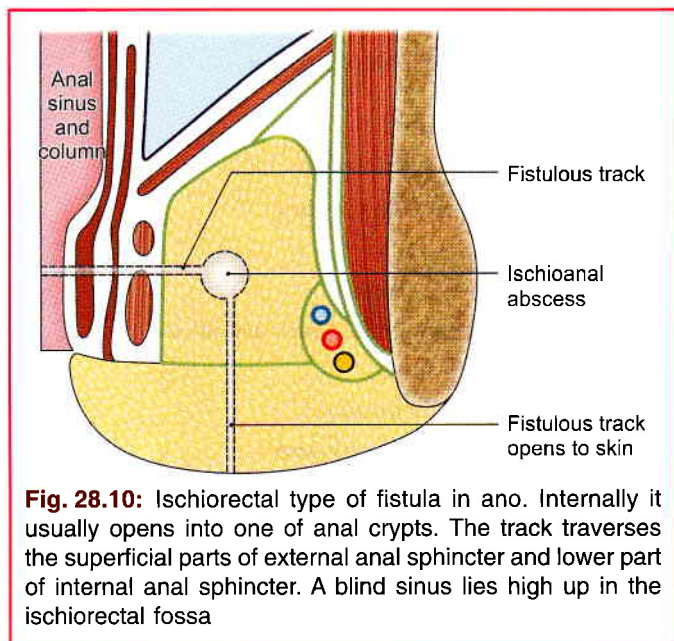


Fig. 28.10: Ischiorectal type of fistula in ano. Internally it usually opens into one of anal crypts. The track traverses the superficial parts of external anal sphincter and lower part of internal anal sphincter. A blind sinus lies high up in the ischioanal fossa

Male Urogenital Region

The anterior division of the perineum is the urogenital region. It contains the superficial and deep perineal spaces or pouches.

Cutaneous Innervation

- 1 Dorsal nerve of penis:** It supplies the skin of the penis, except at its root (Fig. 28.11).
- 2 Ilioinguinal nerve and genital branch of the genitofemoral nerve:** These supply the skin of the anterior one-third of the scrotum and the root of the penis.
- 3 Perineal branch of posterior cutaneous nerve of thigh:** It supplies the skin of the lateral part of the urogenital region and the lateral part of the posterior two-thirds of the scrotum.

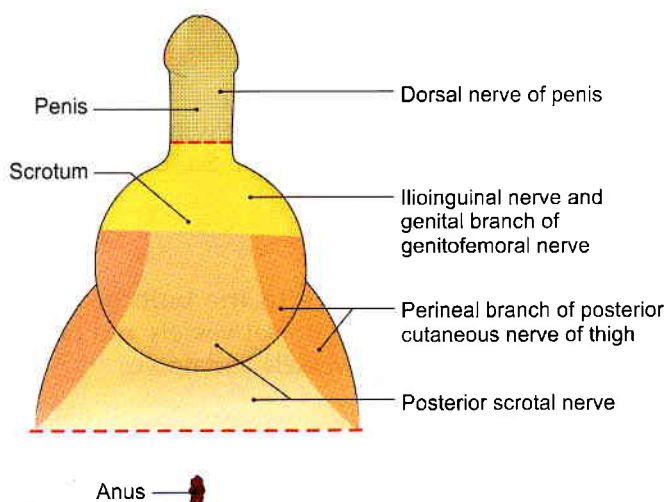


Fig. 28.11: Cutaneous innervation of the male perineum

- 4 Posterior scrotal:** These supply the skin of the medial part of the urogenital region and the medial part of the posterior two-thirds of the scrotum.
- 5** The mucous membrane of urethra is supplied by the *perineal branch of the pudendal nerve*.

CLINICAL ANATOMY

The cutaneous nerves of perineum are derived from the sacral nerves (S2, S3, S4). These segments also supply parasympathetic fibres to the pelvic organs. Diseases of these organs may, therefore, cause *referred pain* in the perineum.

Superficial Fascia

It is made up of two layers as in the lower part of the anterior abdominal wall. The superficial *fatty layer* is continuous with the superficial fascia of the surrounding regions. The deep *membranous layer* or Colles' fascia is attached posteriorly to the posterior border of perineal membrane, and on each side to pubic arch below the crus penis. Anteriorly, it is continuous with the fascia of the scrotum containing the dartos, fascia of the penis, and with the membranous layer of the superficial fascia of the anterior abdominal wall or fascia of Scarpa.

Deep Fascia

It is also made up of one layer that lines the deep perineal space inferiorly.

This fascia of the urogenital diaphragm is thick. It is also called the perineal membrane.

Boundaries

The urogenital region is bounded posteriorly by the interischial line which usually overlies the posterior border of the transverse perinei muscles. Anteriorly and laterally, it is bounded by symphysis pubis and ischiopubic rami.

Urogenital region extends superficially to encompass the scrotum and root of penis.

Urogenital region is divided into two parts by strong perineal membrane.

Above it: Deep perineal space.

Below it: Superficial perineal space.

DEEP PERINEAL SPACE

Previous view: Space between superior fascia of urogenital diaphragm and perineal membrane that contained urethra and urethral sphincter.

Present view: Now the urethral sphincter is known to be contained inside the urethra itself (within). The urogenital diaphragm does not exist. The deep perineal space is thin and open above (Fig. 28.12 and Table 28.1).

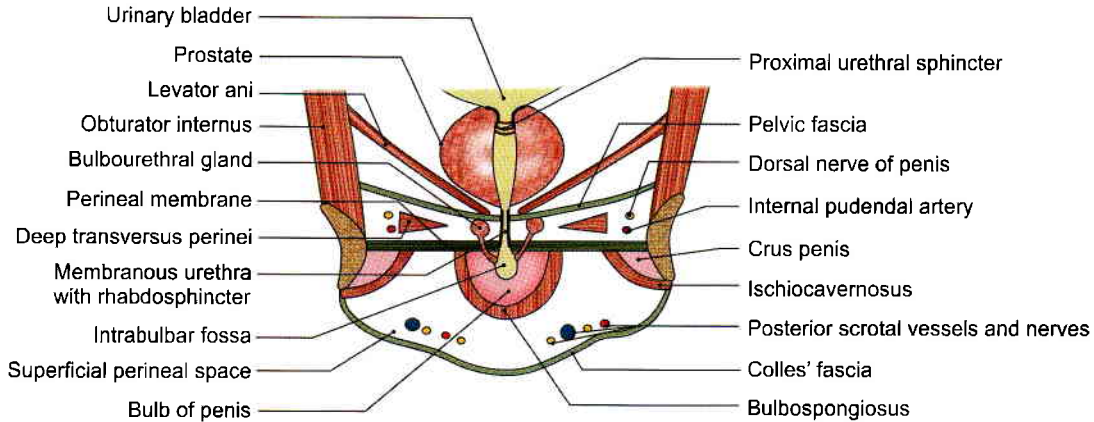


Fig. 28.12: Coronal section through the urogenital region of the male perineum

Table 28.1: Deep perineal space

Features	Male	Female
Definition	This is the thin space of the urogenital region situated deep to the perineal membrane Contributes to pelvic floor	Same
Boundaries		
a. Superficial	Perineal membrane (Fig. 28.12)	Same (Fig 28.19)
b. Deep	Open above	Same
c. On each side	Ischiopubic rami	Same
d. Anteriorly	Gap between perineal membrane and inferior pubic ligament	Same
Contents		
1. Tubes	Part of urethra	Parts of urethra and vagina
2. Muscles	a. Sphincter urethrae or distal urethral sphincter within the wall of urethra b. Deep transversus perinei. Mainly skeletal muscle	a. Sphincter urethrae within the wall of urethra b. Same attachment. Mainly smooth muscle c. Compressor urethrae d. Sphincter urethrovaginalis (Fig. 28.20)
3. Nerves on each side	a. Dorsal nerve of penis b. Muscular branches from perineal nerve	a. Dorsal nerve of clitoris b. Muscular branches from perineal nerve
4. Vessels	a. Artery of penis b. Stems of origin of four branches namely, artery to the bulb of penis, urethral artery, deep and dorsal arteries of penis	a. Artery of clitoris b. Stems of origin of four branches namely artery to bulb of vestibule, urethral artery, deep and dorsal arteries of clitoris
5. Glands	Bulbourethral glands	No glands

Boundaries

Deep aspect: Endopelvic fascia of pelvic floor.

Superficial aspect: Perineal membrane. Between these two fascial layers lie deep transverse perinei; superficial to the proximal urethral sphincter mechanism and bulbourethralis (Fig. 28.12).

The previous view was that sphincter urethrae extended between the two ischiopubic rami and was pierced by urethra but as of now the sphincter urethrae lies within wall of urethra as distal urethral sphincter.

These muscles do not form a true diaphragmatic sheet as such because fibres from the several parts extend through the visceral outlet in the pelvic floor

into the lower reaches of the pelvic cavity. (There is no sphincter urethrae outside urethra. So, no urogenital diaphragm exists).

Contents

Urethra, vessels and nerve to the bulb of penis, bulbourethral glands, deep dorsal vessels and nerves of penis, posterior scrotal vessels and nerves.

Deep Transverse Perinei

It forms an incomplete sheet of skeletal muscle extending across the urogenital triangle from the medial aspects of the ischiopubic rami. Posteriorly, the sheet



is attached to perineal body where its fibres decussate with those of opposite side.

Anteriorly, the muscles are deficient and the visceral structures pass across the endopelvic fascia and the perineal membrane. Some fibres pass to the deep part of external anal sphincter posteriorly and sphincter urethrae (contained within the urethra).

Together with superficial transverse perinei the muscles act to tether (hold) the perineal body in median plane. The muscle gives dynamic support for pelvic viscera.

Supplied by perineal branches of pudendal nerve and vessels.

Distal Urethral Sphincter Mechanism

Consists of intrinsic striated and smooth muscles of urethra and the pubourethralis component of levator ani which surrounds the urethra at the point of maximum concentration of those muscles. It surrounds the membranous urethra in the male.

Smooth muscle fibres also reach up to the lowest part of the neck of the bladder and between the two, fibres lie on the surface of prostate.

Bulk of fibres surround the membranous urethra. There are circularly disposed striated muscle fibres called *rhabdosphincter* which forms main part of distal urethral sphincter mechanism (Fig. 28.12). Some fibres are attached to inner surface of the ischiopubic ramus, forming *compressor urethrae*.

PERINEAL MEMBRANE

Perineal membrane is almost triangular membrane:

- Laterally attached to periosteum of ischiopubic rami.
- Apex attached to arcuate ligament of pubis, where the membrane is attached to this arcuate ligament of pubis, it is particularly thick and is called *transverse perineal ligament*.
- Posterior border is fused to deep parts of perineal body and is continuous with the fascia over deep transversus perinei.

Perineal membrane (Fig. 28.13) is crossed by or pierced by:

- Urethra 2–3 cm behind the inferior border of pubic symphysis.
- Artery to the bulb of penis.
- Duct of bulbourethral gland.
- Muscular branches to muscles of Fig. 28.14.
- Deep artery of the penis, urethral artery.
- Dorsal artery and dorsal nerves of penis.
- Posterior scrotal vessels and nerves, anterior to transverse perinei.

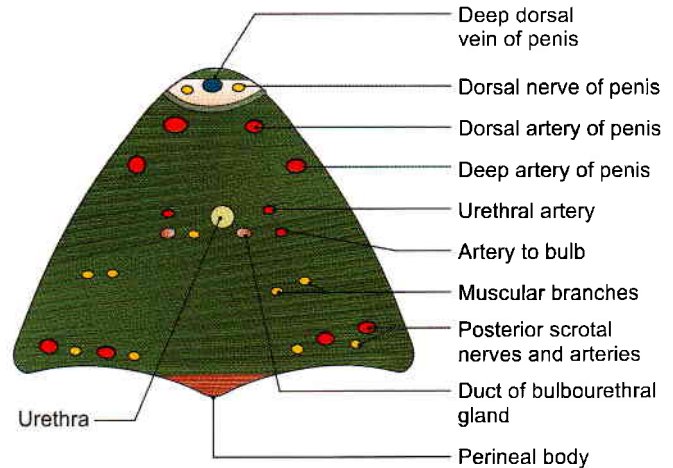


Fig. 28.13: Structures piercing the perineal membrane (male)

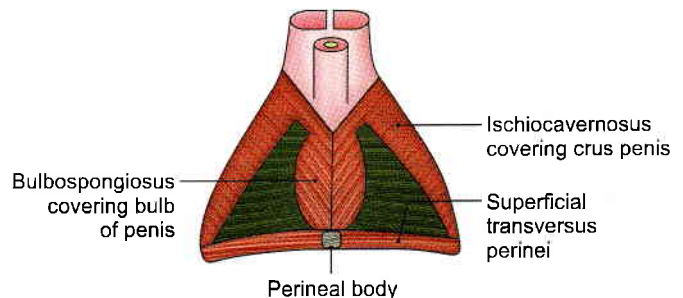


Fig. 28.14: Superficial muscles of the male perineum

Superficial perineal space is given in Tables 28.2 and 28.3.

CLINICAL ANATOMY

- The membranous part of the male urethra is the narrowest and least dilatable part of the urethra. In inexperienced hands, it is likely to be ruptured during instrumentation. The urethra can also rupture in accidental injuries.
- Rupture of the urethra leads to extravasation of urine, which may be superficial or deep. In *superficial extravasation*, the urine spreads downwards deep to the membranous layer of the superficial fascia. It first fills the superficial perineal space; and then the scrotum, the penis and the lower part of the anterior abdominal wall. It is prevented from going to the ischioanal fossa or the thigh by the firm attachment of the membranous layer of superficial fascia to their boundaries (Fig. 28.15).

In *deep extravasation*, the urine spreads upwards into the extraperitoneal space of the pelvis around bladder and prostate into the anterior abdominal wall (Fig. 28.16).

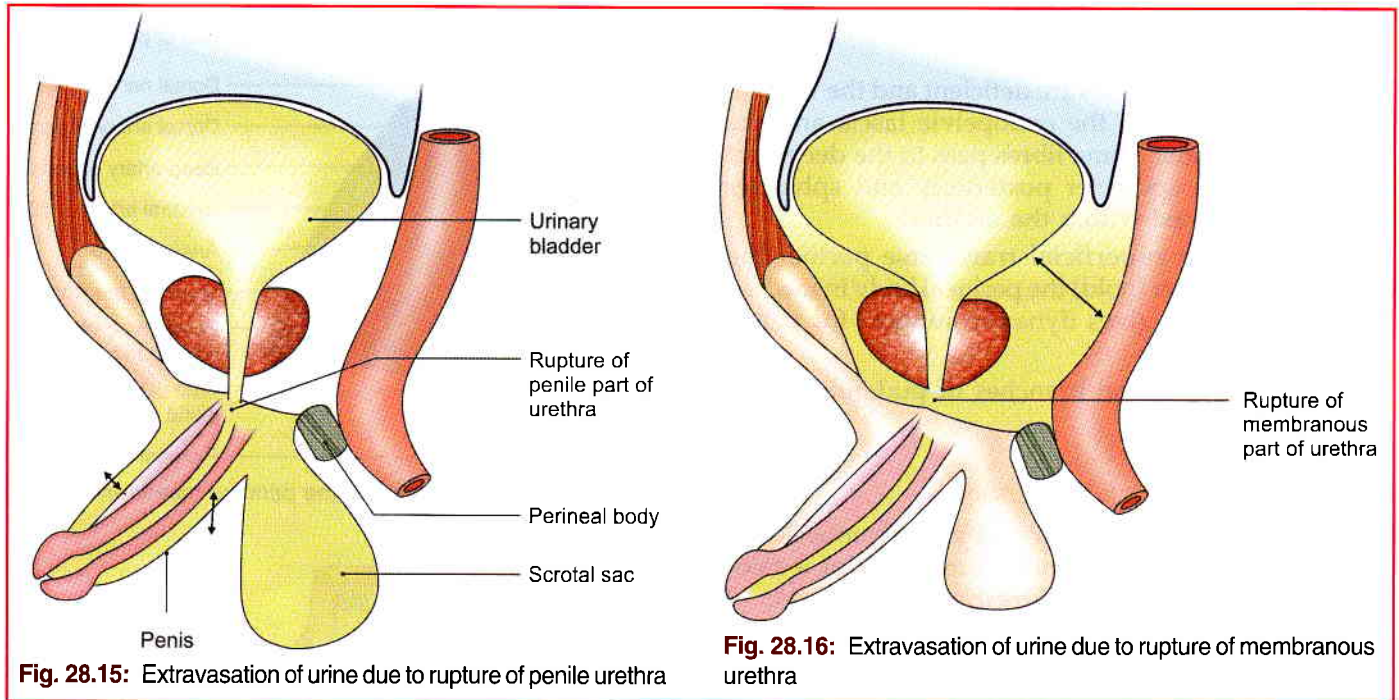


Fig. 28.15: Extravasation of urine due to rupture of penile urethra

Fig. 28.16: Extravasation of urine due to rupture of membranous urethra

FEMALE PERINEUM

It comprises of female external genital organs and female urogenital region.

FEMALE EXTERNAL GENITAL ORGANS/ PUDENDUM/VULVA

Pudendum includes:

- Mons pubis (Fig. 28.17)
- Labia majora
- Labia minora.
- Clitoris.
- Vestibule of the vagina.
- Bulbs of the vestibule.
- Greater vestibular glands.

Mons Pubis

Mons pubis is a rounded eminence present in front of the pubic symphysis. It is formed by accumulation of subcutaneous fat. It is covered with pubic hair. The hair bearing area has a nearly horizontal upper limit.

Labia Majora

Labia majora are two thick folds of skin enclosing fat. They form the lateral boundaries of the *pudendal cleft*. Their outer surfaces are covered with hair, and the inner surfaces are studded with large sebaceous glands. The larger anterior ends are connected to each other below the mons pubis to form the *anterior commissure*. The skin connecting the less prominent posterior ends of the labia is known as the *posterior*

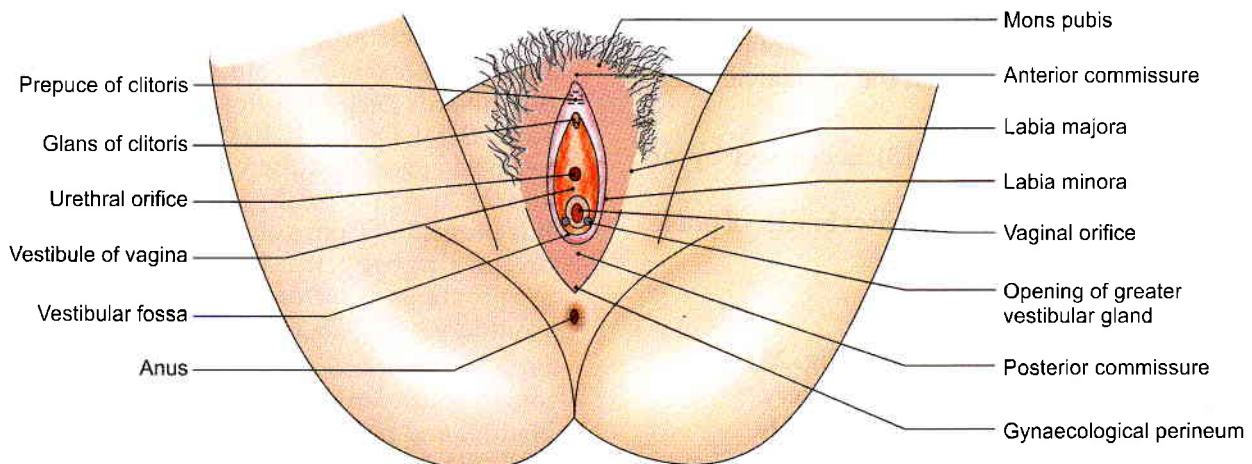


Fig. 28.17: The female external genital organs



commissure. The area between the posterior commissure and the anus which is about 2.5 cm long constitutes the *gynaecological perineum*.

Labia Minora

Labia minora are two thin folds of skin, which lie within the pudendal cleft. Anteriorly, each labium minus splits into two layers; the upper layer joins the corresponding layer of the opposite side to form the *prepuce of the clitoris*. Similarly the lower layers of the two sides join to form the *frenulum of the clitoris*. Posteriorly, the two labia minora meet to form the *frenulum of the labia minora*. The inner surface of the labia minora contains numerous sebaceous glands.

Clitoris

The clitoris is an erectile organ, homologous with the penis. However, *it is not traversed by urethra*. It lies in the anterior part of pudendal cleft. The body of clitoris is made up of two *corpora cavernosa* enclosed in a fibrous sheath and partly separated by an incomplete *pectiniform septum*. *The corpus spongiosum is absent*. Each corpus cavernosum is attached to the ischiopubic rami. The down-turned free end of clitoris is formed by a rounded tubercle, *glans clitoridis*, which caps the free ends of corpora. The glans is made up of erectile tissue continuous posteriorly with the commissural venous plexus uniting right and left bulbs of vestibule called *bulbar commissure*. The surface of glans is highly sensitive and plays an important role in sexual responses.

Vestibule of the Vagina

Vestibule of the vagina is space between two labia minora. It presents the following features.

- 1 The *urethral orifice* lies about 2.5 cm behind the clitoris and just in front of the vaginal orifice.
- 2 *Vaginal orifice* or *introitus* lies in the posterior part of the vestibule, and is partly closed, in the virgin, by a thin membrane called the *hymen*. In married women, the hymen is represented by rounded tags of tissue called the *carunculae hymenales*.
- 3 *Orifices of the ducts of greater vestibular glands* lie one on each side of vaginal orifice, between the hymen and labium minus (Fig. 28.19).
- 4 Numerous *lesser vestibular* or *mucous glands* open on the surface of vestibule.
- 5 The posterior part of vestibule between vaginal orifice and frenulum of labia minora forms a shallow depression known as *vestibular fossa*.

Bulbs of the Vestibule

Bulbs of the vestibule are two oval bodies of erectile tissue that correspond to the two halves of the bulb of the penis. The bulbs lie on either side of the vaginal and urethral orifices, superficial to the perineal

membrane. The tapering anterior ends of the bulbs are united in front of the urethra by a venous plexus, called the *bulbar commissure*. The expanded posterior ends of the bulbs partly overlap the greater vestibular glands.

Greater Vestibular Glands of Bartholin

Greater vestibular glands are homologous with the bulbourethral glands of Cowper in the male. These lie in the superficial perineal space. Each gland has a long duct about 2 cm long which opens at the side of the hymen, between the hymen and the labium minus.

FEMALE UROGENITAL REGION

Cutaneous Innervation

- 1 *Dorsal nerve of clitoris*. It supplies the skin of the clitoris (Fig. 28.18).
- 2 *Ilioinguinal nerve* and *genital branch of the genitofemoral nerve*. These supply the skin of the *anterior one-third* of the labium majus.
- 3 *Perineal branch of posterior cutaneous nerve of thigh*: It supplies the skin of the lateral part of the urogenital region and the lateral part of the *posterior two-thirds* of the labium majus.
- 4 *Posterior scrotal or labial nerves*: These supply the skin of the medial part of the urogenital region including the labium minus in females and the medial part of the posterior two-thirds of the labium majus.
- 5 The mucous membrane of urethra is supplied by the *perineal branch of the pudendal nerve*.

CLINICAL ANATOMY

The cutaneous nerves of perineum are derived from the sacral nerves (S2, S3, S4). These segments also supply parasympathetic fibres to the pelvic organs. Diseases of these organs may, therefore, cause *referred pain* in the perineum.

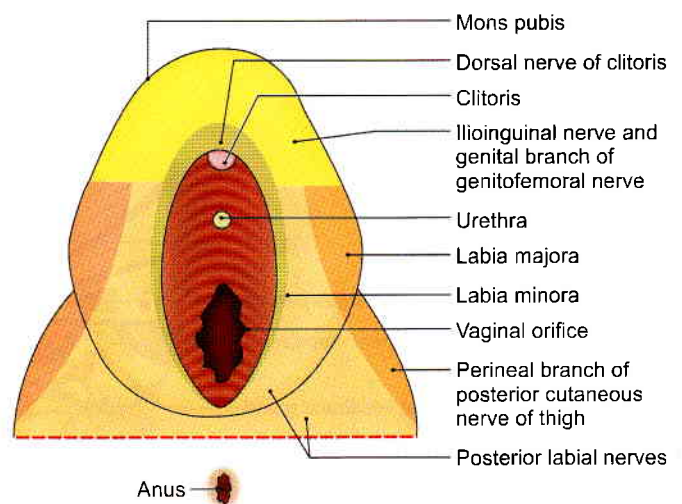


Fig. 28.18: Cutaneous innervation of the female perineum



Superficial Fascia

It is made up of two layers as in the lower part of the anterior abdominal wall. The superficial *fatty layer* is continuous with the superficial fascia of the surrounding regions. The deep *membranous layer* or Colles' fascia is attached posteriorly to the posterior border of perineal membrane, and on each side to pubic arch below the crus penis. Anteriorly, it is continuous with the fascia of the scrotum containing the dartos, fascia of the penis, and with the membranous layer of the superficial fascia of the anterior abdominal wall or fascia of Scarpa.

Deep Fascia

It is also made up of one layer that lines the deep perineal space inferiorly.

This fascia of the urogenital diaphragm is thick. It is also called the perineal membrane.

Boundaries

The urogenital region is bounded by the interischial line which usually overlies the posterior border of the transverse perinei muscles.

Anteriorly and laterally, it is bounded by symphysis pubis and ischiopubic rami.

In the female, urogenital region extends to the labia majora and mons pubis.

Urogenital region is divided into two parts by perineal membrane.

Above it: Deep perineal space.

Below it: Superficial perineal space.

DEEP PERINEAL SPACE

Previous view: Space between urogenital diaphragm and perineal membrane that contained urethra and urethral sphincter.

Present view: Now the urethral sphincter is known to be contained inside the urethra itself (within). The

urogenital diaphragm does not exist. It is thin space, open above (Fig. 28.19).

Boundaries

Superficial aspect: Perineal membrane. On the deep aspect of perineal membrane lie deep transverse perinei; superficial to compressor urethrae and sphincter urethrovaginalis.

Previous view was that sphincter urethrae extended between the two ischiopubic rami and was pierced by urethra and vagina but as of now the sphincter urethrae lies within urethra.

These muscles do not form a true diaphragmatic sheet as such because fibres from the several parts extend through the visceral outlet in the pelvic floor into the lower reaches of the pelvic cavity. There is no sphincter urethrae outside urethra. So no urogenital diaphragm exists.

Deep transverse perinei is mainly *smooth* muscle in female.

In female perineal membrane is less well defined and divided into two halves by urethra and vagina so that it forms triangle on two sides.

The pubourethral ligament links the two sides anteriorly behind pubic arch.

Contents

Urethra, vagina, deep dorsal vessels and nerves of clitoris, posterior labial vessels and nerves.

Urethral Sphincter Mechanism

Consists of intrinsic smooth muscle, intrinsic skeletal muscle. This is anatomically separate from the pubourethralis component of levator ani.

The sphincter mechanism surrounds more than the middle third of urethra. It blends above with the smooth muscle of bladder neck and below with the smooth muscle of lower urethra and vagina. Skeletal muscle fibres are circularly disposed, called *rhabdosphincter*.

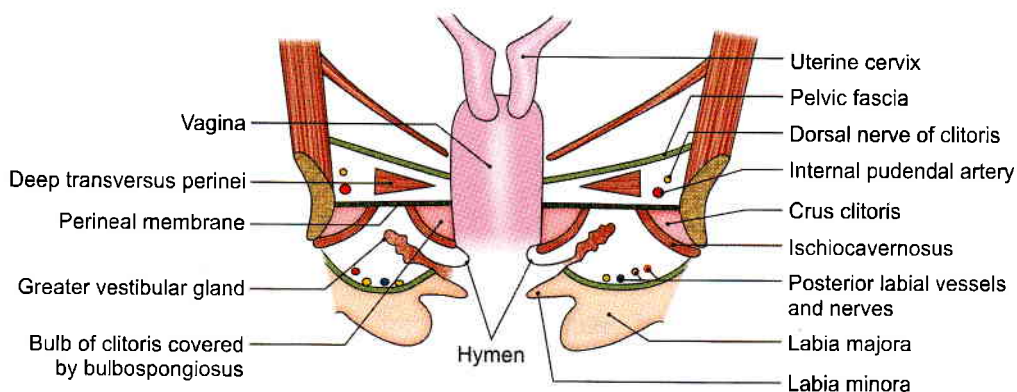


Fig. 28.19: Coronal section through the urogenital region of the female perineum



This forms main part of external urethral sphincter. This in reality is not distal but just urethral sphincter mechanism, since there is no proximal urethral sphincter in female (Fig. 28.20).

Actions

Compresses the urethra, particularly when bladder contains fluid. It contracts to expel the final drops of urine.

Nerve Supply

Perineal branch of pudendal nerve and pelvic splanchnic nerves.

Extensions of the muscles are:

Compressor Urethrae

Compressor urethrae arises from ischiopubic rami of each side by a small tendon. Fibres pass anteriorly to meet their counterparts in a flat band which lies anterior to urethra. A variable number of these fibres pass medially to reach the lower wall of vagina. Sphincter urethrae is within the wall of urethra (Fig. 28.21).

Sphincter Urethrovaginalis

Sphincter urethrovaginalis arises from perineal body. Its fibres pass forwards on either side of urethra and vagina to meet their counterparts in a flat band, anterior to urethra below compressor urethrae.

Actions

Direction of the fibres of compressor urethrae and sphincter urethrovaginalis suggest that these produce elongation as well as compression of the membranous urethra and thus aid continence in females. Both are supplied by perineal nerve.

PERINEAL MEMBRANE

Perineal membrane (Fig. 28.22) is pierced by:

- Urethra, 2–3 cm behind the inferior border of pubic symphysis.
- Vagina (centrally), behind urethra.
- Deep artery of clitoris.
- Dorsal vessels and nerves of clitoris.
- Artery to bulb of vestibule.

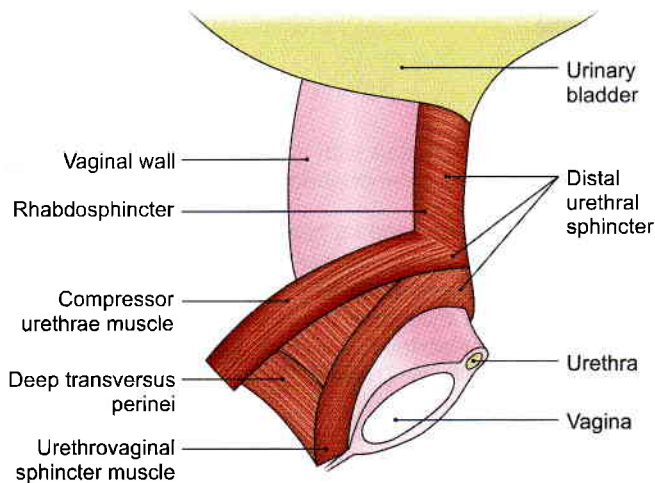


Fig. 28.20: Muscles in the deep perineal pouch in female

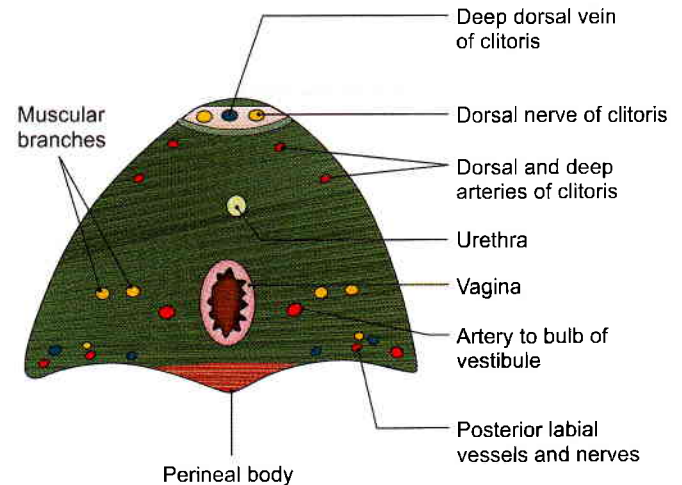


Fig. 28.22: Structures piercing the perineal membrane (female)

- Muscular branches to muscles of Fig. 28.21.
- Posterior labial vessels and nerves, anterior to transverse perinei.

PERINEAL SPACES/POUCHES

The arrangement of the superficial and deep fasciae in the urogenital region results in the formation of two triangular spaces, the superficial and deep perineal spaces or pouches (Fig. 28.18).

The boundaries and contents of the deep space are summarised in Table 28.1.

Table 28.2 summarises the boundaries and contents of superficial perineal space.

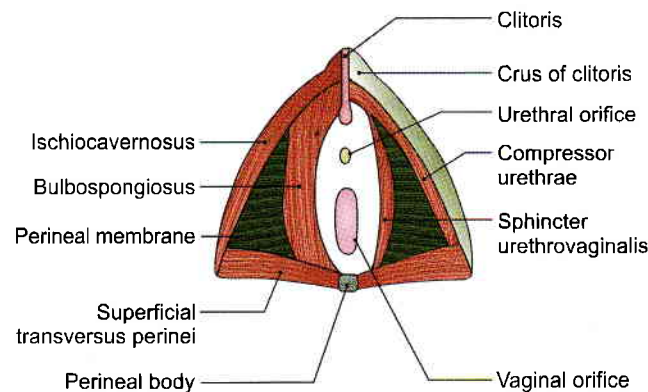


Fig. 28.21: Female perineum showing superficial muscles (left half) and deep perineal muscles on right half



Muscles of the Urogenital Region

These muscles are arranged in superficial and deep, groups. The superficial muscles are the ischiocavernosus, the bulbospongiosus and the superficial transversus perinei, described in Table 28.3. The deep muscles are the distal urethral sphincter mechanism, sphincter urethrae with extensions and the deep transversus perinei (described earlier).

PUDENDAL CANAL

This is a fascial tunnel present in the lateral wall of the ischioanal fossa, just above the sacrotuberous ligament. It transmits the pudendal nerve and the internal pudendal vessels.

The canal extends from the lesser sciatic notch to the posterior border of the perineal membrane (Fig. 28.23).

Formation

The pudendal canal is a space between obturator fascia and the lunate fascia. Others believe that it is formed by splitting of the obturator fascia (Fig. 28.7).

Contents

- Pudendal nerve (S2, S3, S4):** In the posterior part of the canal, pudendal nerve gives off the inferior rectal nerve and then soon divides into a larger perineal nerve and a smaller dorsal nerve of penis.

Table 28.2: The superficial perineal space

Features	Male	Female
Definition	This is the superficial space of the urogenital region situated superficial to the perineal membrane	Same
Boundaries		
a. Superficial	Colles' fascia	Same
b. Deep	Perineal membrane	Same
c. On each side	Ischiopubic rami	Same
d. Posteriorly	Closed by the fusion of perineal membrane with Colles' fascia.	Same
e. Anteriorly	Open and continuous with the spaces of the scrotum, penis and the anterior abdominal wall	Open and continuous with the spaces of the clitoris and the anterior abdominal wall
Contents	Root of penis, made up of two corpora cavernosa and one corpus spongiosum traversed by the urethra (Fig. 28.12)	Body of clitoris, made up only of two corpora cavernosa separated by an incomplete septum. The corpus spongiosum is absent. Urethral orifice lies 2 cm behind the clitoris. Vaginal orifice just behind urethral orifice. Two bulbs of vestibule are there, one on each side of these two orifices. These unite and get attached to the glans clitoridis.
Muscles on each side	<ol style="list-style-type: none"> Ischiocavernosus covering the corpora cavernosa of penis (Fig. 28.14) Bulbospongiosus covering corpus spongiosum; both are united by a median raphe Superficial transversus perinei 	<ol style="list-style-type: none"> Ischiocavernosus covering the corpora cavernosa of clitoris (Fig. 28.21) Bulbospongiosus covering bulb of vestibule. These remain separated to give passage to urethra and vagina (Fig. 28.19) Superficial transversus perinei
Nerves	<ol style="list-style-type: none"> Three sets of branches from perineal nerve namely posterior scrotal nerve, branch to bulb and muscular branches Long perineal nerve from posterior cutaneous nerve of thigh 	<ol style="list-style-type: none"> Three sets of branches from perineal nerve namely posterior labial nerve, branch to bulb of vestibule and muscular branches Same
Vessels	<ol style="list-style-type: none"> Two branches of perineal artery namely, the posterior scrotal and transverse perineal Four branches from the artery of penis namely, artery to the bulb of penis, urethral artery, deep and dorsal arteries of penis 	<ol style="list-style-type: none"> Two branches of perineal artery namely posterior labial and transverse perineal Four branches from the artery of clitoris, namely artery to bulb of vestibule, urethral artery, deep and dorsal arteries of clitoris
Glands and ducts	Only the ducts of bulbourethral glands	Greater vestibular glands and their ducts



Table 28.3: The superficial perineal muscles in male/female

Muscle	Origin	Fibres	Insertion	Nerve supply	Actions
1. Ischiocavernosus It covers the crus penis or crus clitoridis; smaller in females	a. Medial surface of ischial ramus behind the crus b. Posterior part of perineal membrane	Fibres run forwards and spiral over the crus	Inserted by an aponeurosis into the sides and undersurface of the anterior part of the crus	Perineal branch of pudendal nerve	It helps in maintaining erection of the penis by compressing the crus Causes erection of clitoris in female
2. Bulbospongiosus It covers the bulb of penis and the two muscles are united by a median raphe In females, it covers the bulb of vestibule and the two muscles are separated by the vagina and urethra	a. Perineal body b. Median raphe over the bulb of penis Perineal body	a. Posterior fibres embrace the posterior end of the bulb b. Middle fibres embrace the corpus spongiosum c. Anterior fibres embrace the entire body of penis Fibres pass anteriorly	a. Posterior fibres, into the perineal membrane b. Middle fibres embrace the bulb and corpus spongiosum, and the raphe on their upper surface c. Anterior fibres are inserted into the raphe on the dorsal surface of the penis a. Perineal membrane b. Bulb of vestibule c. Body of clitoris and corpus spongiosum	Perineal branch of pudendal nerve	1. Helps in ejaculation of semen and ejecting the last drops of urine 2. Middle fibres assist in the erection of the corpus spongiosum penis by compressing the bulb 3. Anterior fibres also help in the erection of penis by compressing the deep dorsal vein of penis In females it acts as sphincter of vagina and assists in erection of clitoris
3. Superficial trans- versus perinei Narrow slip running transversely in front of anus on either side	Medial surface of the root of ischial ramus	Fibres run medially	Inserted into the perineal body where it interlaces with other converging muscles	Perineal branch of pudendal nerve	Steadies the perineal body

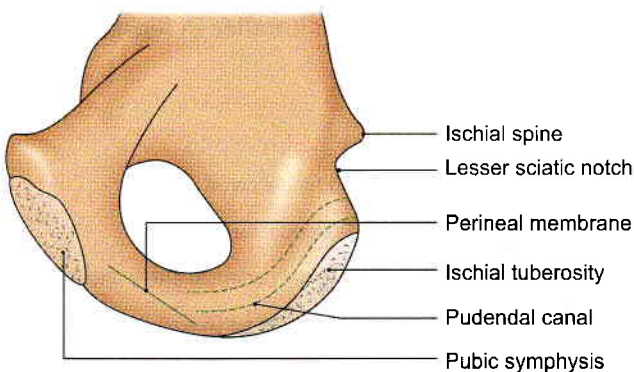


Fig. 28.23: Inner surface of the right hip bone showing the position of pudendal canal

2 Internal pudendal artery: This artery gives off the inferior rectal artery in the posterior part of the canal. In the anterior part of the canal, the artery divides into the perineal artery and the artery of penis. Vein accompanies the artery.

PUDENDAL NERVE

Pudendal nerve is the chief nerve of the perineum and of the external genitalia. It is accompanied by the internal pudendal vessels.

Origin

Pudendal nerve arises from the sacral plexus in the pelvis. It is derived from spinal nerves S2, S3, S4.

Course

It originates in the pelvis, enters gluteal region through greater sciatic notch, leaves it through lesser sciatic notch to enter the pudendal canal in the lateral wall of ischioanal fossa. It terminates by dividing into branches.

Relations

1 In the pelvis, the pudendal nerve descends in front of the piriformis deep to its fascia. It leaves the pelvis, to enter the gluteal region, by passing through the



lower part of the greater sciatic foramen, between the piriformis and the coccygeus, medial to internal pudendal vessels.

- 2 In the gluteal region, the pudendal nerve crosses the apex of the sacrospinous ligament, under cover of gluteus maximus. Here it lies medial to the internal pudendal vessels which cross the ischial spine. Accompanying these vessels, the nerve leaves the gluteal region by passing through the lesser sciatic foramen, and enters the pudendal canal.
- 3 In the pudendal canal, the neurovascular bundle lies in the lateral wall of the ischioanal fossa (Fig. 28.7).

Branches

In the posterior part of the pudendal canal the pudendal nerve gives off the inferior rectal nerve, and then divides into two terminal branches, the perineal nerve and the dorsal nerve of the penis or clitoris (Figs 28.24 and 28.25).

The *inferior rectal nerve* pierces the medial wall of the pudendal canal, crosses the ischioanal fossa from lateral

to medial side, and supplies the external anal sphincter, the skin around the anus, and the lining of the anal canal below the pectinate line (Fig. 28.9).

The *perineal nerve* is the larger terminal branch of the pudendal nerve. It runs forwards below the internal pudendal vessels, and terminates by dividing into:

- a. Medial and lateral *posterior scrotal* or labial nerves.
- b. *Muscular branches* to the urogenital muscles, and to anterior parts of external anal sphincter and the levator ani. The nerve to the bulbospongiosus also gives off the nerve to bulb which supplies corpus spongiosum, penis and the urethra.

The *dorsal nerve of the penis or clitoris* is the smaller terminal branch of the pudendal nerve. It runs forwards first in the pudendal canal above the internal pudendal vessels; and then in the deep perineal space between these vessels and the pubic arch. Next it passes through the lateral part of the oval gap between the apex of the perineal membrane and the arcuate pubic ligament, runs on the dorsum of the penis or clitoris, and ends in the glans penis or glans clitoridis. It supplies the skin of the body of the penis or clitoris and of the glans.

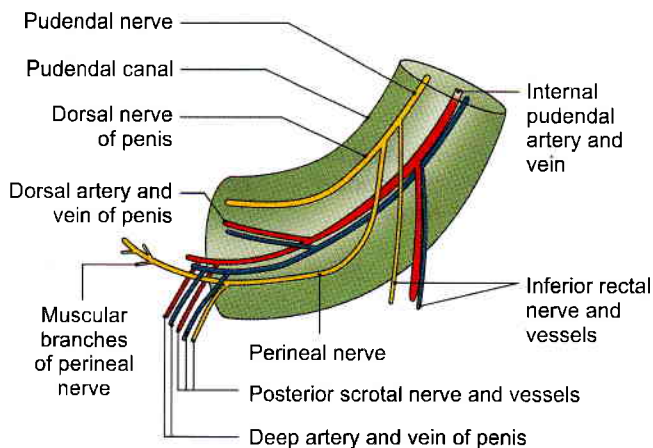


Fig. 28.24: Contents of pudendal canal

CLINICAL ANATOMY

The pudendal nerve supplies sensory branches to the lower of the vagina, through the inferior rectal and posterior labial branches. Therefore, in vaginal operations, general anaesthesia can be replaced by a *pudendal nerve block*. The nerve is infiltrated near the ischial spine by a needle passed through the vaginal wall and then guided by a finger (Fig. 28.26).

INTERNAL PUDENDAL ARTERY

This is the chief artery of the perineum and of the external genital organs. It is smaller in females than in males.

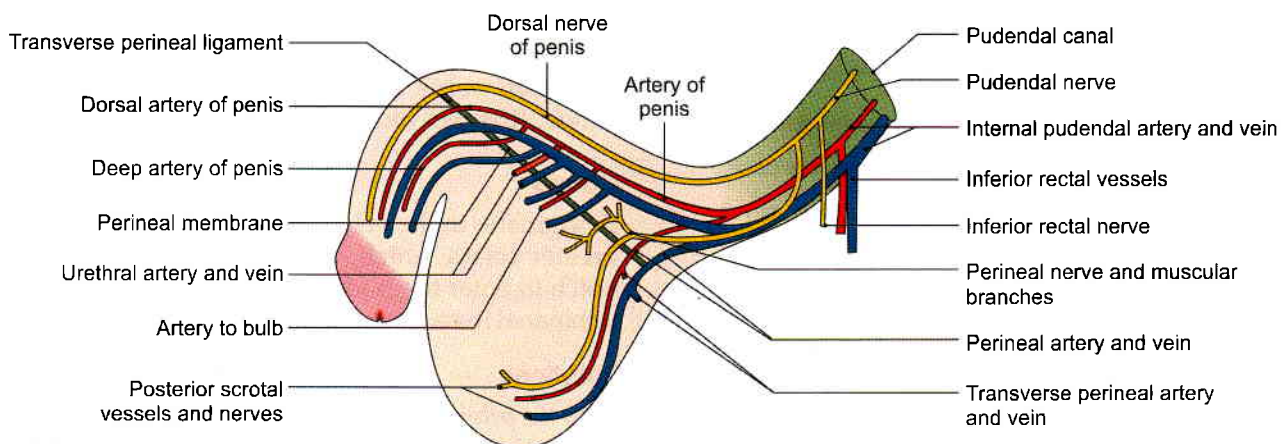
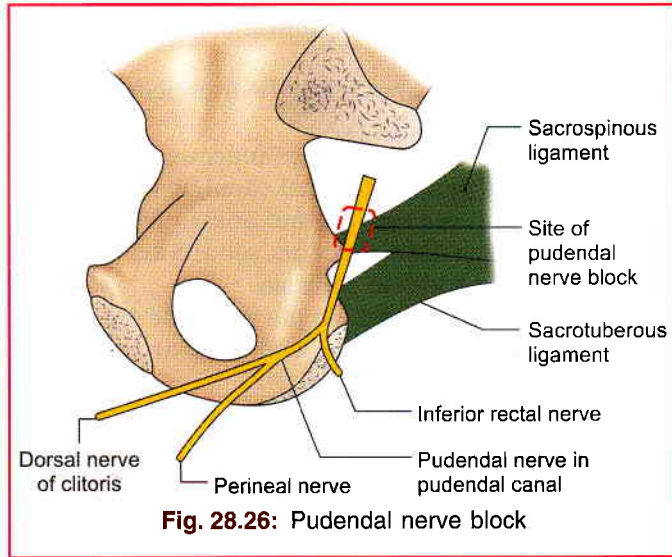


Fig. 28.25: Course and distribution of the pudendal nerve, and of the internal pudendal artery



Origin

The artery is the smaller terminal branch of the anterior division of the internal iliac artery, given off in the pelvis; the larger branch is the inferior gluteal.

Course

The course of internal pudendal artery is similar to the course of pudendal nerve.

Relations

In the pelvis, the artery runs downwards in front of the piriformis, the sacral plexus and the inferior gluteal artery. It leaves the pelvis by piercing the parietal pelvic fascia and passing through the greater sciatic foramen, below the piriformis, thus entering the gluteal region.

In the gluteal region, the artery crosses the dorsal aspect of the tip of the ischial spine, under cover of the gluteus maximus. Here it lies between the pudendal nerve medially and the nerve to the obturator internus laterally. It leaves the gluteal region by passing through the lesser sciatic foramen, and thus enters the pudendal canal.

In the pudendal canal, the artery runs downwards and forwards in the lateral wall of the ischioanal fossa, about 4 cm above the lower margin of the ischial tuberosity. Here it is related to the dorsal nerve above and the perineal nerve below. The artery gives off the inferior rectal artery in the posterior part of the canal, and the perineal artery in the anterior part. The internal pudendal artery continues into the deep perineal space as the artery of the penis or of the clitoris (Fig. 28.24).

In the deep perineal space, the artery of the penis or clitoris which is continuation of internal pudendal artery, runs forwards close to the side of pubic arch, medial to the dorsal nerve of penis or of clitoris. The

artery ends a little behind the arcuate pubic ligament by dividing into the deep and dorsal arteries of penis or of the clitoris (Fig. 28.25).

Branches

- 1 The *inferior rectal artery* arises near the posterior end of the pudendal canal, and accompanies the nerve of the same name. The artery supplies the skin, muscles and mucous membrane of the anal region, and anastomoses with the superior and middle rectal arteries (Fig. 28.24).
- 2 The *perineal artery* arises near the anterior end of the pudendal canal, and pierces the base of the perineal membrane to reach the superficial perineal space. Here it divides into the *transverse perineal* and the *posterior scrotal* or *posterior labial* branches.
- 3 The *artery of the penis* or *the clitoris* runs in the deep perineal space and gives off:
 - a. Artery to the bulb.
 - b. Urethral artery.
 - c. Deep artery of the penis or the clitoris.
 - d. Dorsal artery of the penis or the clitoris.

All of them pierce the perineal membrane and reach the superficial perineal space. The *artery to the bulb* supplies the bulb of the penis or bulb of vestibule and the posterior part of the urethra or only the urethra. The *urethral artery* supplies the corpus spongiosum and the anterior part of the urethra. The *deep artery of the penis* or *the clitoris* traverses and supplies the crus and the corpus cavernosum. The *dorsal artery of the penis* or *the clitoris* supplies the skin and fasciae of the body of the penis and of the glans or the glans clitoridis.

INTERNAL PUDENDAL VEIN

The tributaries of internal pudendal vein follow the branches of the internal pudendal artery. The vein drains into internal iliac vein.

HISTOLOGY OF BODY OF PENIS/CLITORIS

Penis consists of two corpora cavernosa containing the deep artery of the penis and a single corpora spongiosum with the urethra. All three erectile masses contain spaces or caverns. The spaces are larger in corpora cavernosa and smaller in corpus spongiosum. These three corpora are covered by fasciae and skin. In the deep fascia lie deep dorsal vein of penis, two dorsal arteries and two dorsal nerves of penis. The superficial dorsal vein of the penis lies in the superficial fascia.

Clitoris comprises two corpora cavernosa only. *Corpus spongiosum* is absent. The two erectile masses contain caverns or spaces.



FACTS TO REMEMBER

- Perineum is divided into anterior by placed urogenital triangle and posteriorly placed anal triangle.
- Anal triangle comprises terminal part of anal canal in the centre with right and left ischioanal fossae on each side. Ischioanal fossa contains internal pudendal vessels and pudendal nerve.
- Fat in ischioanal fossa keeps the anal canal closed except at the time of defaecation.
- Sphincter urethrae is within the wall of urethra. So there is hardly any deep perineal space.
- Perineal membrane is the key structure in urogenital triangle. Main difference in male and female perineum about the structures piercing the perineal membrane is the additional vaginal opening in female and two ducts of bulbourethral glands in the male only.
- Key structure and central tendon of perineum is perineal body.
- Body of clitoris in female is made up of only two corpora cavernosa and *no corpus spongiosum*
- There is corpus spongiosum with urethra in the penis of male in addition to two corpora cavernosa (see Fig. 17.2).
- Clitoris is much smaller than the penis and is *not traversed by the urethra*. Urethral orifice lies 2 cm behind clitoris.
- Bulbospongiosus of two sides are separate in female and overlie the bulb of vestibule. In male the two

are united by a median septum and overlie the bulb of penis.

- Pudendal nerve supplies all the muscles and skin of perineum.
- Inferior rectal nerve supplies mucous membrane of the lower part of the anal canal, external anal sphincter and the skin around anal opening.
- The labium majora contains sebaceous glands, sweat glands and hair follicles.
- There are four openings in the vestibule one each, of urethra, and vagina and two of ducts of Bartholin's glands.

CLINICOANATOMICAL PROBLEM

A woman few days after childbirth complained of a painful swelling in her perianal region.

- Name is the fossa related to anal canal.
- What vessel passes through the fossa?
- Disruption of which vessel causes collection of blood after the childbirth?

Ans: The fossa related to the anal region is the ischioanal fossa. There is one fossa on each side of the anal canal. The internal pudendal artery and pudendal nerve in course through the pudendal canal, lying in the lateral wall of the fossa.

The swelling occurred due to disruption of a small branch of internal pudendal artery, probably as a result of infection during childbirth or infection the episiotomy area.

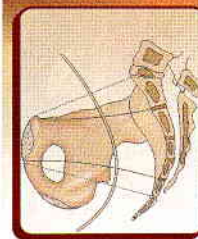
MULTIPLE CHOICE QUESTIONS

1. Deep boundaries of the perineum are all *except*:
 - a. Inferior pubic ligament
 - b. Tip of the coccyx
 - c. Sacrotuberous ligament
 - d. Sacrospinous ligament
2. Following are the paired muscles attached to the perineal body *except*:
 - a. Bulbospongiosus
 - b. Deep transverses perenei
 - c. Levator ani
 - d. Part of sphincter ani externus
3. Following are the contents of ischioanal fossa *except*:
 - a. Inferior rectal nerve and vessels
 - b. Pudendal nerve and internal pudendal vessels
 - c. Middle rectal vessels
 - d. Ischioanal pad of fat
4. Main bulk of distal urethral sphincter mechanism is formed by:
 - a. Compressor urethrae
 - b. Smooth muscle of urethra
 - c. Rhabdosphincter
 - d. Pubourethralis part of levator ani
5. Following structures pierce the perineal membrane in male *except*:
 - a. Vagina
 - b. Urethra
 - c. Deep artery of penis
 - d. Dorsal artery of penis
6. Which part of urethra is the least dilatable?
 - a. External opening
 - b. Prostatic part
 - c. Membranous part
 - d. Penile part

ANSWERS

1. d 2. d 3. c 4. c 5. a 6. c

Preliminary Consideration of Boundaries and Contents of Pelvis



It is a basin for housing lower parts of digestive and excretory systems. It chiefly lodges the genital system, the only system different in the male and female

INTRODUCTION

Pelvis is formed by articulation of each of the two hip bones with the sacrum behind and with each other in front. The greater pelvis is comfortably occupied by the abdominal viscera, leaving only the lesser pelvis for the pelvic viscera. Urinary bladder lies behind pubic symphysis; rectum and anal canal are close to the sacrum and coccyx. The middle space left is for the genital organs. Many structures cross the brim of the pelvis, i.e. curved line extending around the pelvis at the junction of greater and lesser pelvis (linea terminalis).

The bony pelvis is formed by *four bones* united at *four joints*. The bones are the two hip bones in front and on the sides, and the sacrum and coccyx behind. The joints are the two sacroiliac joints, the pubic symphysis and the sacrococcygeal joint.

The pelvis is divided by the plane of the *pelvic inlet* or pelvic brim, or superior aperture of the pelvis into two parts.

- Upper part is known as greater or *false pelvis*.
- Lower part is known as the *lesser* or *true pelvis*.

The plane of the pelvic inlet passes from the sacral promontory to the upper margin of the pubic symphysis. The *greater* or *false pelvis* includes the two iliac fossae, and forms a part of the posterior abdominal wall. The *lesser* or *true pelvis* contains the pelvic viscera.

LESSER PELVIS

Pelvic Walls

The pelvic walls are made up of bones, ligaments and muscles.

Bony Walls

These are formed:

- Anteriorly* by the pubic symphysis and bodies of the pubic bones.

- Posteriorly* by the sacrum and coccyx.
- On each side* by the two rami of the pubis, the ischium with its ramus, and the lower part of the ilium (Fig. 29.1).

Ligaments and Membranes

- Obturator membrane* closes the greater part of the obturator foramen, and completes the lower part of the lateral wall of the pelvis (Fig. 29.2).
- Sacrospinous* ligament and *sacrospinous* ligaments bridge the gap between the hip bone and the sacrum, and convert the greater and lesser sciatic notches into the foramina of the same name (Fig. 29.3).

Muscles

- The *obturator internus* with its fascia reinforces the lateral wall of the pelvis from the inside.
- The *piriformis* with its fascia forms the posterior wall of the pelvis. It also helps in filling the gap of the greater sciatic foramen (Figs 29.4 and 29.5).

Pelvic Inlet: Superior Aperture of Pelvis

The pelvic inlet is an oblique plane, making an angle of 50 to 60 degrees with the horizontal. It is *bounded*

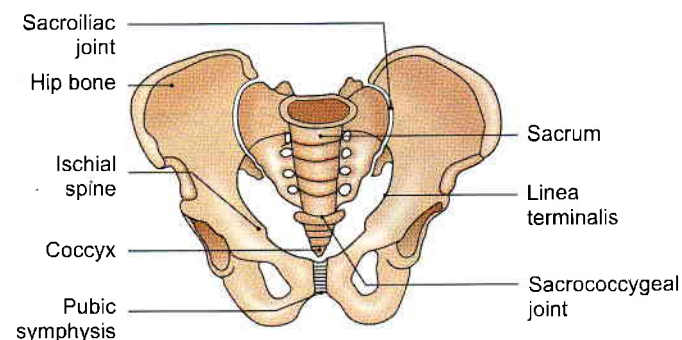


Fig. 29.1: Anterior view of the male pelvis

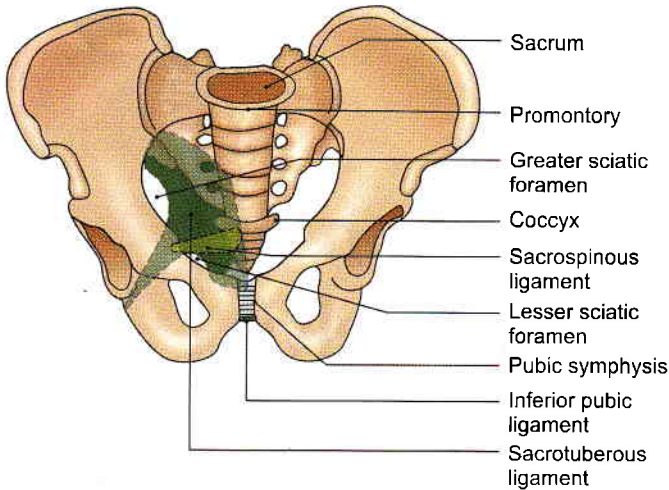


Fig. 29.2: Bones and ligaments of pelvis seen from the front

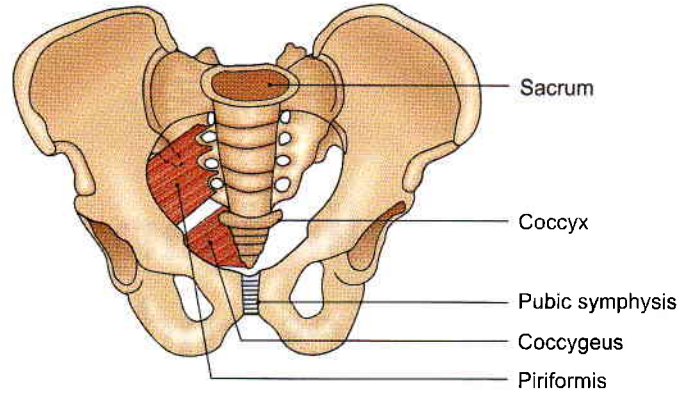


Fig. 29.5: Muscles of the posterior part of the pelvic wall seen from the front

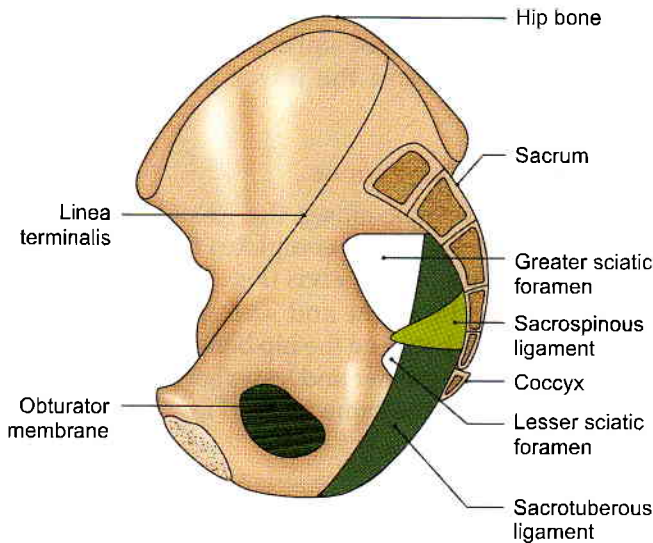


Fig. 29.3: Pelvic bones and ligaments seen from the medial side

posteriorly by the sacral promontory, anteriorly by the upper margin of the pubic symphysis, and on each side by the linea terminalis. The linea terminalis includes the anterior margin of the ala of the sacrum, the arcuate line or lower part of the medial border of the ilium, the pectineal line of the pubis or pecten pubis, and the pubic crest (Fig. 29.6).

The pelvic inlet is heart-shaped in the male, and is widest in its posterior part. In the female, it is oval, and is widest more anteriorly than in the male. Posteriorly, the inlet is indented by the sacral promontory, more so in the male than in the female (Fig. 29.7).

Pelvic Outlet: Inferior Aperture of Pelvis

The pelvic outlet is bounded anteriorly by the arcuate or inferior pubic ligament; posteriorly by the coccyx; and on each side by the ischiopubic rami or side of the pubic arch, the ischial tuberosities and the sacrotuberous

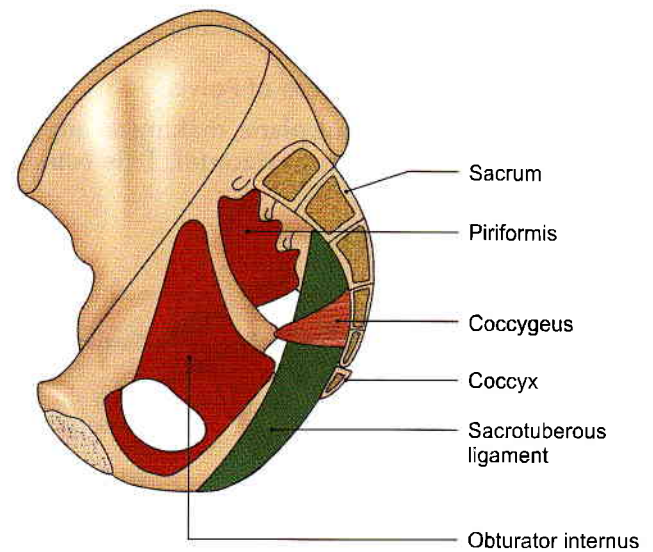


Fig. 29.4: Muscles of the pelvic wall seen from the medial side

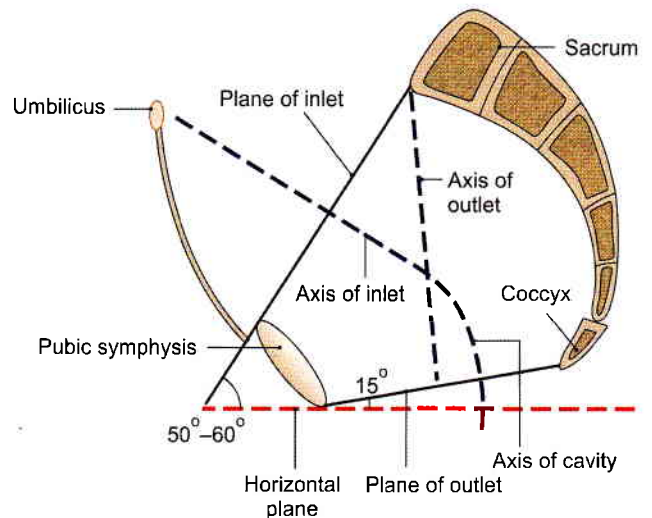


Fig. 29.6: Sagittal section of the pelvis showing the planes of its inlet and outlet and their axes. The axis of the pelvic cavity is J-shaped

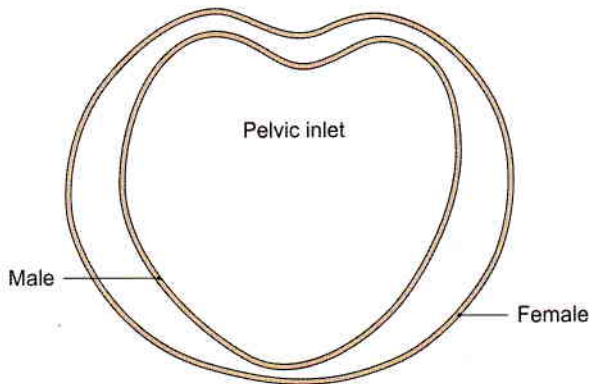


Fig. 29.7: Shape of pelvic inlet in the male, and in the female

ligaments. The posterior part of the outlet is formed by the coccyx and the sacrotuberous ligaments. It is mobile on the sacrum, and the sacrum itself is slightly mobile at the sacroiliac joints (Fig. 29.6).

The pubic arch is formed by the ischiopubic rami of the two sides and by the lower margin of the pubic symphysis which is rounded off by the arcuate pubic ligament (Fig. 29.2).

CLINICAL ANATOMY

- The pelvis is a basin with its various walls and many openings. The posterior wall contains 5 pairs of anterior sacral foramina. The greater and lesser sciatic notches are converted into foramina of the same name with the help of sacrotuberous and sacrospinous ligaments. Greater sciatic foramen is the “doorway” of the gluteal region. Pudendal nerve enters the region through the greater sciatic notch and quickly leaves it through lesser sciatic notch to enter the perineum. The lateral wall contains obturator foramen for the passage of obturator nerve which supplies adductors of the hip joint.
- Fracture may occur in the true (ring-like) pelvis. If fracture is at one point, the fracture will be stable.
- In athletes, anterior superior iliac spine may be pulled off by forcible contraction of sartorius. Similarly anterior inferior iliac spine or ischial tuberosity may get **avulsed** by the contraction of their attached muscles.

Pelvic Floor

The pelvic floor is formed by the pelvic diaphragm which consists of the levator ani and the coccygeus (see Chapter 34). It resembles a hammock, or a gutter because it slopes from either side towards the median plane where it is traversed by the urethra and the anal canal, and also by the vagina in the female. The pelvic diaphragm separates the perineum below from the pelvis above.

The muscles of the true pelvis, its blood vessels and nerves are considered in Chapter 34.

CLINICAL ANATOMY

- Pelvic floor formed by two gutter-shaped levator ani muscles supports the pelvic viscera, especially during raised intra-abdominal pressure. The foetal head travels in the axis of pelvic cavity (Fig. 29.8). During second stage of labor, the head of the baby on reaching the pelvic floor rotates from earlier transverse position to the anteroposterior position. The occiput moves downwards and forwards and reaches below the 80°–85° angled pubic arch. Then the head passes through the anterior hiatus of the levator ani to reach the perineum and then deliver. Sometimes episiotomy is given to enlarge the perineum (Fig. 29.9).
- Injury to pelvic floor which mostly occurs during vaginal delivery, may cause uterine, vaginal or even rectal prolapse.
- Appendicitis occurring due to pelvic position of the appendix may irritate the obturator nerve leading to referred pain in the medial side of thigh (see Fig. 20.23).
- Inflammation of ovaries may cause referred pain in the medial side of thigh due to irritation of the obturator nerve (see Fig. 31.1).
- The 2nd to 4th sacral nerves and coccygeal nerve can be anaesthetised by the anaesthetic agent put into the sacral canal. It is called *caudal anaesthesia* and is used in obstetrics practice.
- Pain in the sacroiliac joint is felt on pressing the posterior superior iliac spine present in a dimple on the lower back (see Fig. 5.1).

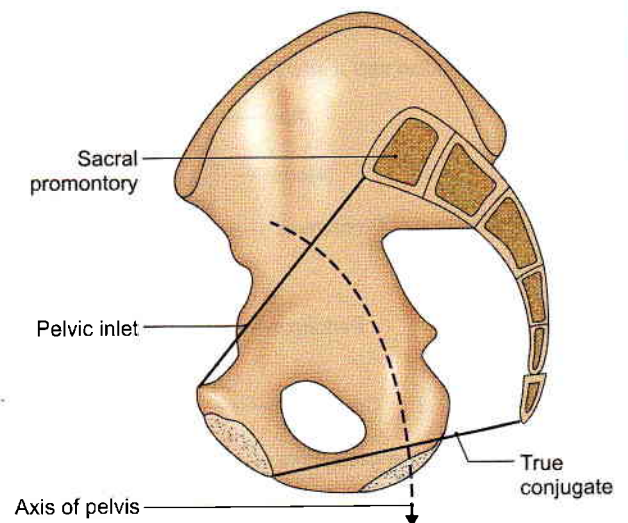


Fig. 29.8: Axis of pelvis

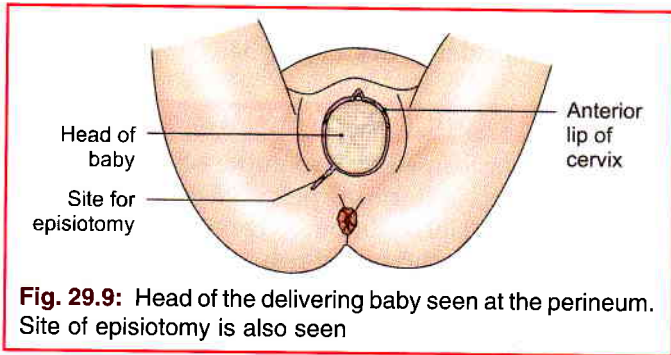


Fig. 29.9: Head of the delivering baby seen at the perineum. Site of episiotomy is also seen

Pelvic Cavity

The pelvic cavity is continuous above with the abdominal cavity at the pelvic brim, and is limited below by the pelvic diaphragm. The cavity is curved in such a way that it is first directed downwards and backwards, and then downwards and forwards (J-shaped) as shown in (Fig. 29.10). It has unequal walls, measuring only about 5 cm anteriorly and 15 cm posteriorly. The cavity is more roomy or larger in the female than in the male.

Contents

- 1 Sigmoid colon and rectum occupy the posterior part of the pelvis.
- 2 Urinary bladder lies anteriorly. The prostate lies below the neck of urinary bladder.
- 3 In between the bladder and rectum, there is a transverse septum or *genital septum* made up of connective tissue. In the male, the septum is small. It contains the ductus deferens, the seminal vesicle and the ureter on each side.
In the female, the septum is large, and contains the uterus, the uterine tubes, the round ligament of the

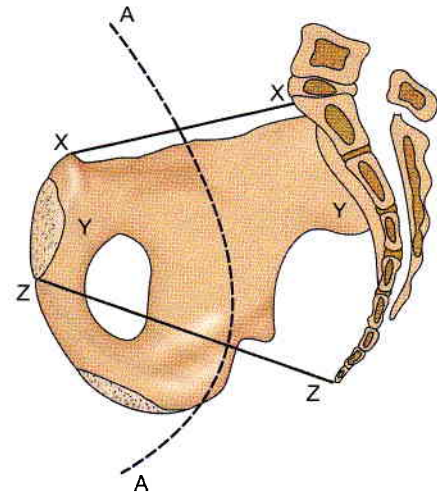


Fig. 29.10: Side view of bony female pelvis. AA—Axis of pelvic cavity (X-X—Plane of inlet, Y-Y—Zone of cavity, Z-Z—Plane of outlet)

uterus, the ligaments of the ovary, ovaries, the vagina and the ureters.

These contents are considered in detail in the chapters that follow.

Structures Crossing the Pelvic Inlet/Brim of the Pelvis

From posterior median plane sweeping laterally and anteriorly:

- 1 Median sacral vessels (Fig. 29.11).
- 2 Sympathetic trunk.
- 3 Lumbosacral trunk (Fig. 29.11).
- 4 Iliolumbar artery.
- 5 Obturator nerve.
- 6 Internal iliac vessels (*see* Fig. 34.1)
- 7 Medial limb of sigmoid mesocolon with superior rectal vessels—left side only (Fig. 29.11).

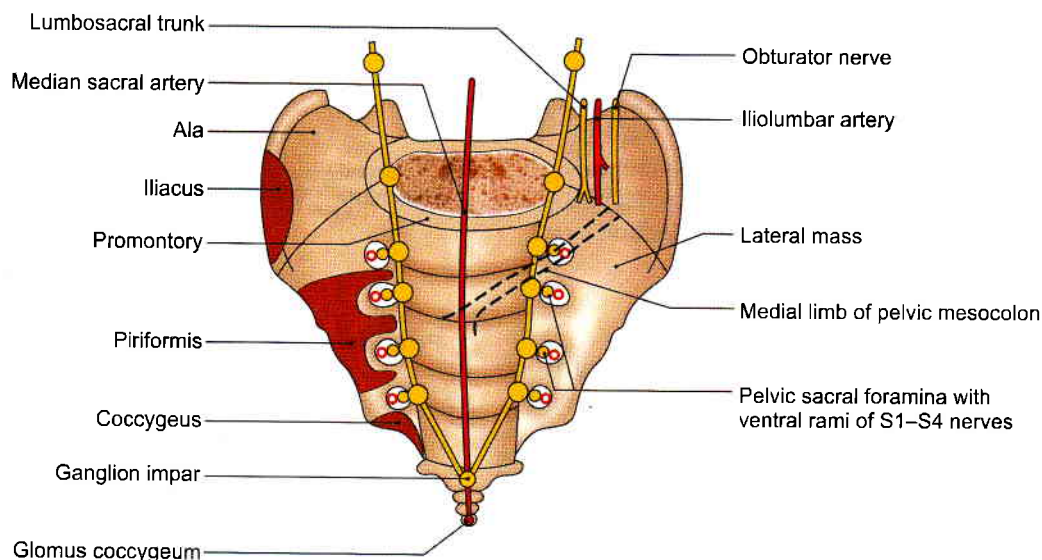


Fig. 29.11: Anterior (pelvic) view of the sacrum and attachment of sigmoid mesocolon

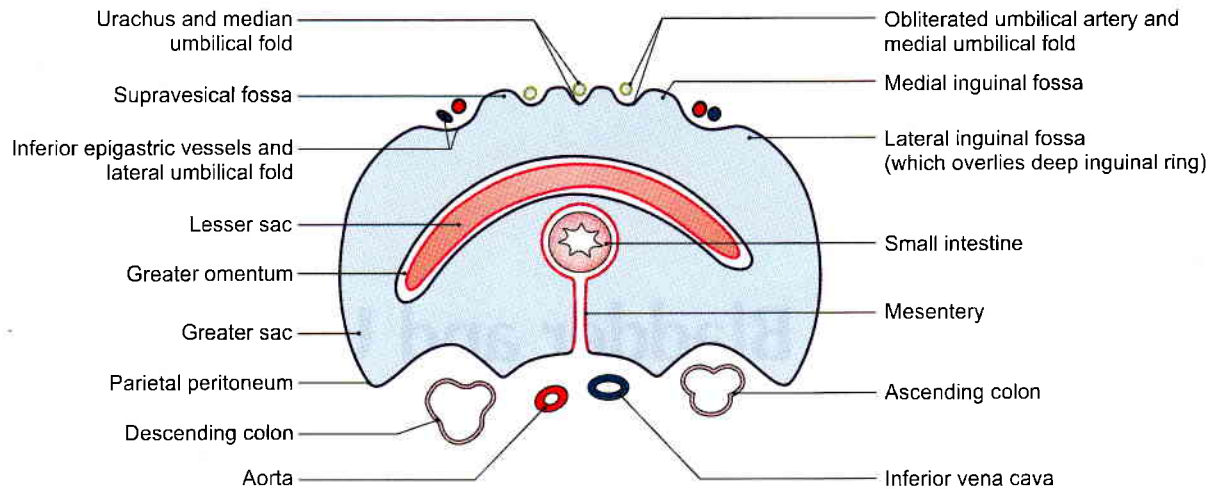


Fig. 29.12: Urachus and obliterated umbilical artery will cross the pelvic brim

- 8 Ureter (*see* Figs 24.22 and 30.3).
- 9 Sigmoid colon—on left side only.
- 10 Ovarian vessels in female.
- 11 Ductus deferens in male/round ligament of uterus in female (*see* Fig. 32.2).
- 12 Lateral umbilical ligament (Fig. 29.11).
- 13 Median umbilical ligament or urachus (Fig. 29.12).
- 14 Autonomic nerve plexuses.
- 15 Coils of intestine and pregnant uterus.
- 16 Full urinary bladder.

FACTS TO REMEMBER

- Axis of pelvic cavity is "J" shaped. Plane of outlet of pelvis makes an angle of 15° with the horizontal plane. Plane of inlet of pelvis makes an angle of 50° – 60° with the horizontal plane.
- Shallowest wall of pelvis is its anterior wall. Distance between two ischial spines is the least.

CLINICOANATOMICAL PROBLEM

During childbirth, a woman was given pudendal nerve block. She still complained of some pain during her labour

- What is pudendal nerve block?
- Which other nerves have to be anaesthetized to get painless childbirth?

Ans: Pudendal nerve arises from ventral rami of S2, S3, S4 segments of spinal cord. It is the nerve of the perineum. It supplies three muscles of superficial perineal space including most of the skin and mucous membrane of perineum. So it is blocked by an anaesthetic agent given above the ischial tuberosity.

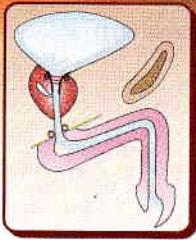
Since sensations from perineum are also carried by ilioinguinal (L1), genitofemoral (L1, L2), and posterior cutaneous nerve of thigh, these nerves also need to be blocked by making an injection of the same agent along the lateral margin of labia majora.

MULTIPLE CHOICE QUESTIONS

1. All the following are the characteristic features of the female bony pelvis *except*:
 - a. Pelvic inlet is oval or round
 - b. Subpubic angle is 50 – 60 degrees
 - c. Obturator foramen is small and triangular
 - d. Sciatic notches are wider
2. Axis of pelvic inlet is:
 - a. Vertical
 - b. Downwards and backwards
 - c. Transverse
 - d. Downwards and forwards
3. Angle of horizontal plane with plane of inlet is:
 - a. 70 – 80°
 - b. 50 – 60°
 - c. 40 – 50°
 - d. 45 – 65°
4. Angle of horizontal plane with plane of outlet is:
 - a. 10°
 - b. 15°
 - c. 20°
 - d. 25°
5. All the following structures cross the brim of pelvis in male *except*:
 - a. Internal iliac vessels
 - b. Ovarian vessels
 - c. Iliolumbar artery
 - d. Sympathetic trunks

ANSWERS

1. b 2. b 3. b 4. b 5. b



Urinary Bladder and Urethra

Poisons and medicines are often times the same substance given with different doses and different intents
— S Anthony

INTRODUCTION

Urinary bladder is the temporary store house of urine which gets emptied through the urethra. The external urethral sphincter is the sphincter urethrae which is placed proximally in the wall of urethra, and not at the terminal part of the urethra. In the case of pylorus and anal canal, the sphincters are placed at their terminal ends.

The male urethra subserving the functions of urination and ejaculation, i.e. expulsion of semen is 18–20 cm long with curvatures and comprises preprostatic, prostatic, membranous and longest anterior bulbar and penile parts.

The female urethra is for urination only and is 4 cm long. The catheterisation if required is much easier in the female than in the male.

DISSECTION

Clean and define the muscles, membranes and ligaments in the pelvic cavity. These are the levator ani obturator internus muscles; medial and lateral pubo prostatic ligaments and median, medial umbilical folds.

Identify the peritoneum on the superior surface of the bladder situated just behind the pubic symphysis. Identify and follow the median umbilical ligament from the apex of bladder. Define the surfaces, blunt borders and the openings in the urinary bladder.

In the male, trace the ductus deferens and ureter to the base of the bladder on both sides. Pull the bladder medially and identify the structures on its lateral surface, e.g. the levator ani, obturator vessels and nerve, superior vesical branch of umbilical artery and the obliterated umbilical artery.

In female, the cervix and vagina lie behind the urinary bladder.

Make the incision through the bladder wall along the junction of the superior and inferolateral surface on both

sides. Extend these incisions till the lateral extremities of the base. Incise the superior wall of the bladder to be able to visualise its interior.

In the male, make a median section through the penis, opening the entire length of the spongy part of the urethra. Examine the internal structure of the urethra.

URINARY BLADDER

Features

The urinary bladder is a muscular reservoir of urine, which lies in the anterior part of the pelvic cavity. The detrusor muscle of urinary bladder is arranged in whorls and spirals and is adapted for mass contraction rather than peristalsis.

Size, Shape and Position

The bladder varies in its size, shape and position according to the amount of urine it contains.

When empty, it lies entirely within the pelvis; but as it fills it expands and extends upwards into the abdominal cavity, reaching up to the umbilicus or even higher.

External Features

An empty bladder is tetrahedral in shape and has:

- 1 Apex, directed forwards.
- 2 Base or fundus, directed backwards.
- 3 Neck, which is the lowest and most fixed part of the bladder.
- 4 Three surfaces, superior, right and left inferolateral.
- 5 Four borders, two lateral, one anterior and one posterior (Figs 30.1 and 30.2).

A full bladder is ovoid in shape and has:

- 1 An apex, directed upwards towards the umbilicus.
- 2 A neck, directed downwards.
- 3 Two surfaces, anterior and posterior.

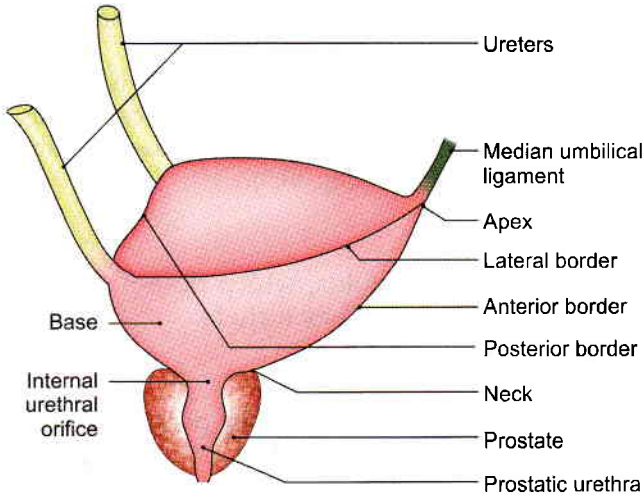
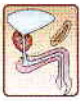

Fig. 30.1: The shape of the urinary bladder

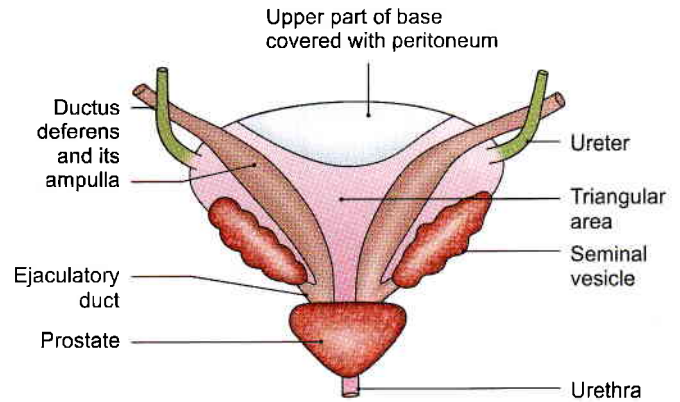


Fig. 30.3: Posterior view of a male urinary bladder and its relations to the genital ducts and glands

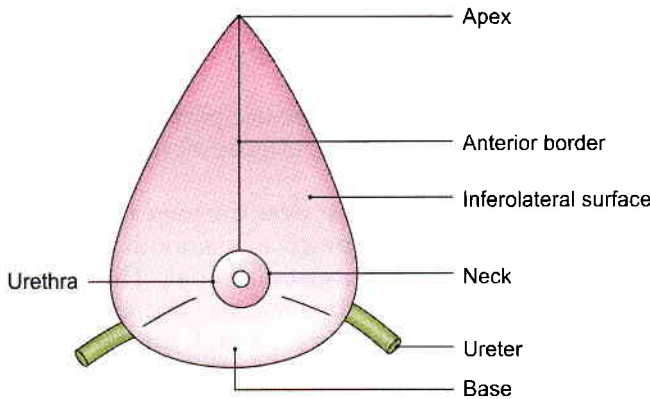


Fig. 30.2: Urinary bladder seen from below

Relations

- 1 The *apex* is connected to the umbilicus by the median umbilical ligament which represents the obliterated embryonic urachus (Fig. 30.1).
- 2 *Base:*
 - a. *In the female*, it is related to the uterine cervix and to the vagina (see Fig. 31.21).
 - b. *In the male*, the upper part of the base is separated from the rectum by the rectovesical pouch (see Fig. 18.17a) and the contained coils of intestine; and the lower part is related to the seminal vesicles and the terminations of the vas deferens (Fig. 30.3). The triangular area between the two deferent ducts is separated from the rectum by the rectovesical fascia of Denonvilliers.
- 3 The *neck* is the lowest and most fixed part of the bladder. It lies 3 to 4 cm behind the lower part of the pubic symphysis, a little above the plane of the pelvic outlet. It is pierced by the internal urethral orifice.
 - a. *In males*, smooth muscle bundles surround the bladder neck and preprostatic urethra. These are arranged as distinct circular collar with its own

distinct adrenergic innervations. This is the preprostatic sphincter and is devoid of parasympathetic cholinergic nerves. It is part of proximal urethral sphincter mechanism.

- b. *In females*, neck is related to the pelvic fascia which surrounds the upper part of the urethra.

In infants, the bladder lies at a higher level. The internal urethral orifice lies at the level of the superior border of the pubic symphysis. It gradually descends to reach the adult position after puberty.

4 Superior surface:

- a. *In males*, it is completely covered by peritoneum, and is in contact with the sigmoid colon and coils of the terminal ileum (see Fig. 18.17a).
- b. *In females*, peritoneum covers the greater part of the superior surface, except for a small area near the posterior border, which is related to the supravaginal part of the uterine cervix. The peritoneum from the superior surface is reflected to the isthmus of the uterus to form the vesicouterine pouch (see Fig. 18.17b).

5 Inferolateral surfaces: These are devoid of peritoneum, and are separated from each other anteriorly by the anterior border, and from the superior surface by the lateral borders.

- a. *In the male*, each surface is related to the pubis, the puboprostatic ligaments, the retro pubic fat, the levator ani and the obturator internus (Fig. 30.4).
- b. *In the female*, the relations are same, except that the puboprostatic ligaments are replaced by the pubovesical ligaments.

As the bladder fills, the inferolateral surfaces form the anterior surface of the distended bladder, which is covered by peritoneum only in its upper part. The lower part comes into direct contact with the anterior abdominal wall, there being no intervening peritoneum. This part can be approached surgically without entering the peritoneal cavity.

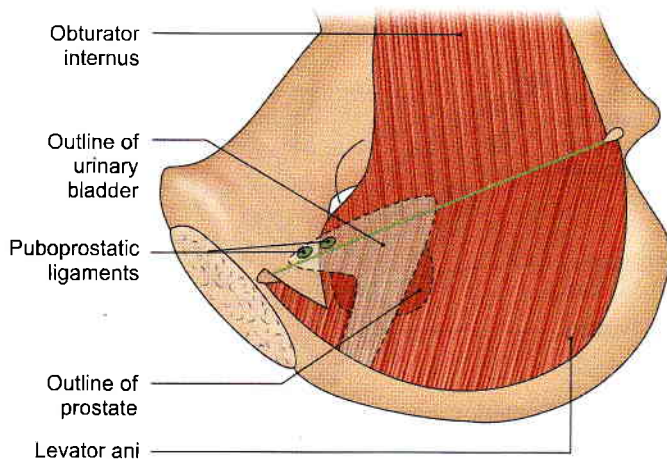


Fig. 30.4: Medial view of the lower part of the pelvic wall and the pelvic diaphragm. The urinary bladder has been superimposed to show relations of its inferolateral surface

Ligaments of the Bladder

True Ligaments

These are condensations of pelvic fascia around the neck and base of the bladder. They are continuous with the fascia on the superior surface of the levator ani.

- 1 The *lateral true ligament* of the bladder extends from the side of the bladder to the tendinous arch of the pelvic fascia (Fig. 30.5).
- 2 The *lateral puboprostatic ligament* is directed medially and backwards. It extends from the anterior end of the tendinous arch of the pelvic fascia to the upper part of the prostatic sheath (see Fig. 32.8).
- 3 The *medial puboprostatic ligament* is directed downwards and backwards. It extends from the back of the pubic bone (near the pubic symphysis) to the prostatic sheath. The ligaments of the two sides form the floor of the retropubic space (see Fig. 32.8).

In females, bands similar to the puboprostatic ligaments are known as the *pubovesical ligaments*. They end around the neck of the bladder (Fig. 30.5).

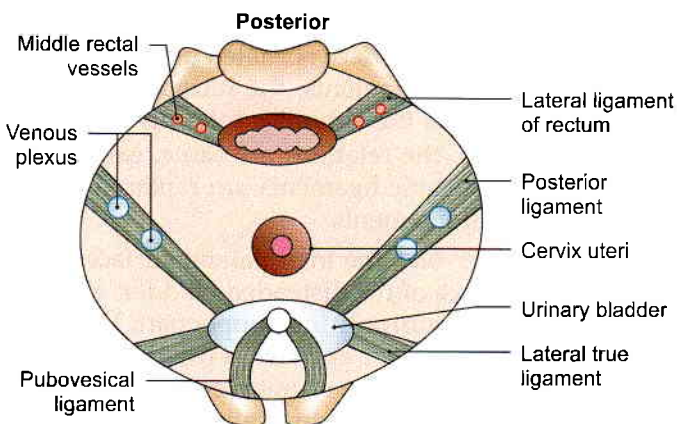


Fig. 30.5: True ligaments of the bladder in female

- 4 The *median umbilical ligament* is the remnant of the urachus (Fig. 30.1).
- 5 The *posterior ligament* of the bladder is directed backwards and upwards along the vesical plexus of veins. It extends on each side from the base of bladder to the wall of pelvis (Fig. 30.5).

False Ligaments

These are peritoneal folds, which do not form any support to the bladder. They include:

- 1 Median umbilical fold.
- 2 Medial umbilical fold.
- 3 Lateral false ligament, formed by peritoneum of the paravesical fossa.
- 4 Posterior false ligament formed by peritoneum of the sacrogenital folds (see Fig. 18.20).

Interior of the Bladder

It can be examined by cystoscopy, at operation or at autopsy.

In an empty bladder, the greater part of the mucosa shows irregular folds due to its loose attachment to the muscular coat.

In a small triangular area over the lower part of the base of the bladder, the mucosa is smooth due to its firm attachment to the muscular coat. This area is known as the *trigone* of the bladder. The apex of the trigone is directed downwards and forwards. The internal urethral orifice, opening into the urethra is located here. The ureters open at the posterolateral angles of the trigone. Their openings are 2.5 cm apart in the empty bladder, and 5 cm apart in a distended bladder (Fig. 30.6).

A slight elevation on the trigone immediately posterior to the urethral orifice produced by the median lobe of the prostate, is called the *uvula vesicae*. The base of the trigone is formed by the *interureteric ridge* or *bar of Mercier* produced by the continuation of the inner longitudinal muscle coats of the two ureters. The ridge

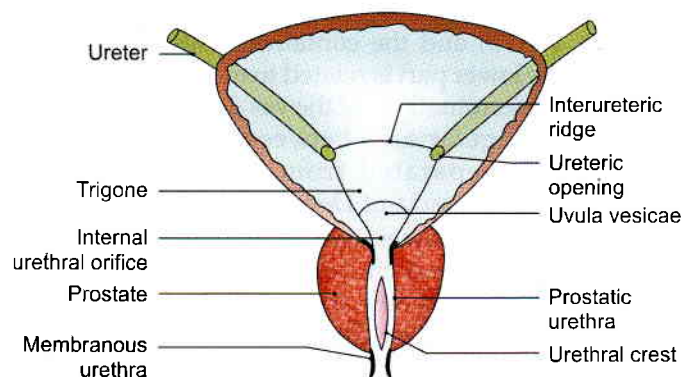


Fig. 30.6: Coronal section through the bladder and prostate to show the interior of the bladder



extends beyond the ureteric openings as the *ureteric folds* over the interstitial part of the ureters.

CLINICAL ANATOMY

- The interior of the bladder can be examined in the living by *cystoscope* (Fig. 30.7).
- A distended bladder may be *ruptured* by injuries of the lower abdominal wall. The peritoneum may or may not be involved.
- Chronic obstruction to the outflow of urine by an enlarged prostate causes hypertrophy of bladder leading to trabeculated bladder.
- In the operation of *suprapubic cystotomy*, the bladder is distended with about 300 ml of fluid. As a result the anterior aspect of the bladder comes into direct contact with the anterior abdominal wall, and can be approached without entering the peritoneal cavity.

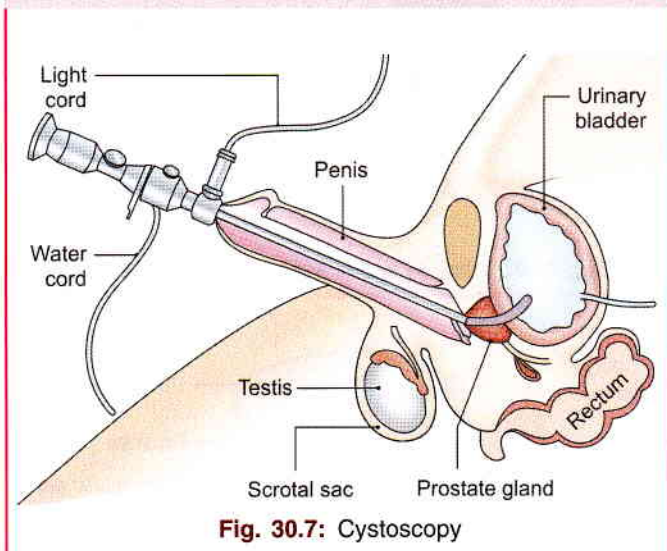


Fig. 30.7: Cystoscopy

Capacity of the Bladder

The mean capacity of the bladder in an adult male is 220 ml, varying from 120 to 320 ml. Filling beyond 220 ml causes a desire to micturate, and the bladder is usually emptied when filled to about 250 to 300 ml. Filling up to 500 ml may be tolerated, but beyond this it becomes painful. Referred pain is felt in the lower part of the anterior abdominal wall, perineum and penis (T11 to L2; S2 to S4).

Arterial Supply

- 1 The main supply comes from the superior and inferior vesical arteries, branches of anterior trunk of the internal iliac artery (see Fig. 34.1).
- 2 Additional supply is derived from the obturator, and inferior gluteal arteries; and in females from the uterine and vaginal arteries instead of inferior vesical.

Venous Drainage

Lying on the inferolateral surfaces of the bladder there is a vesical venous plexus. Veins from this plexus pass backwards in the posterior ligaments of the bladder, and drain into the internal iliac veins.

Lymphatic Drainage

Most of the lymphatics from the urinary bladder terminate in the external iliac nodes. A few vessels may pass to the internal iliac nodes or to the lateral aortic nodes.

Nerve Supply

The urinary bladder is supplied by the vesical plexus of nerves which is made up of fibres derived from the inferior hypogastric plexus. The vesical plexus contains both sympathetic and parasympathetic components, each of which contains motor or efferent and sensory or afferent fibres.

- 1 *Parasympathetic efferent* fibres or *nervi erigentes*, S2, S3, S4 are motor to the detrusor muscle. These nerves do not supply the preprostatic sphincter. If these are destroyed, normal micturition is not possible.
- 2 *Sympathetic efferent* fibres (T11 to L2) are said to be inhibitory to the detrusor and motor to the preprostatic sphincter mechanism.
- 3 The somatic, *puddendal nerve* (S2, S3, S4) supplies the sphincter urethrae which is voluntary and is situated within the wall of urethra.
- 4 *Sensory nerves*: Pain sensations, caused by distension or spasm of the bladder wall, are carried mainly by parasympathetic nerves and partly by sympathetic nerves. In the spinal cord, pain arising in bladder passes through the *lateral spinothalamic tract*, and awareness of bladder distension is mediated through the *posterior columns*. *Bilateral anterolateral cordotomy*, therefore, selectively abolishes pain without affecting the awareness of bladder distension and the desire to micturate.

CLINICAL ANATOMY

- *Emptying of bladder*: Emptying of the bladder is essentially a reflex function, involving the motor and sensory pathways. Voluntary control over this reflex is exerted through upper motor neurons, and as long as one pyramidal tract is functioning normally, control of the bladder remains normal. Acute injury to the cervical/thoracic segments of spinal cord leads to a state of spinal shock. The muscle of the bladder is relaxed, the sphincter vesicae contracted, but sphincter urethrae relaxed. The bladder distends and urine dribbles.



After a few days, the bladder starts contracting reflexly. When it is full, it contracts every 2–4 hours. This is “automatic reflex bladder” (Fig. 30.8).

Damage to the sacral segments of spinal cord situated in lower thoracic and lumbar one vertebra results in “autonomous bladder”. The bladder wall is flaccid and its capacity is greatly increased. It just fills to capacity and overflows. So there is continuous dribbling (Fig. 30.9).

- Urinary bladder is one of sites for stone formation as concentrated urine lies here.

MALE URETHRA

Male urethra is 18–20 cm long that extends from the internal urethral orifice in the urinary bladder to the external opening (meatus) at the end of the penis.

Considered in two parts:

- 1 Relatively short posterior urethra which is 4 cm long, lies in the pelvis proximal to corpus spongiosum and is acted upon by urogenital sphincter mechanisms and also acts as a conduit.

Posterior urethra

- a. Preprostatic segment (Fig. 30.10).
- b. Prostatic segment.
- c. Membranous segment.

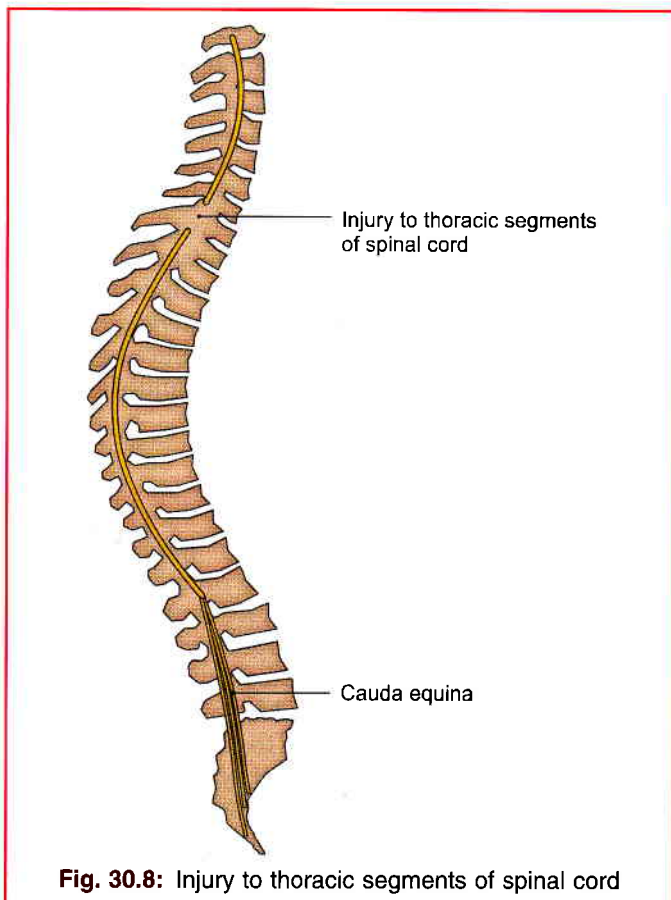


Fig. 30.8: Injury to thoracic segments of spinal cord

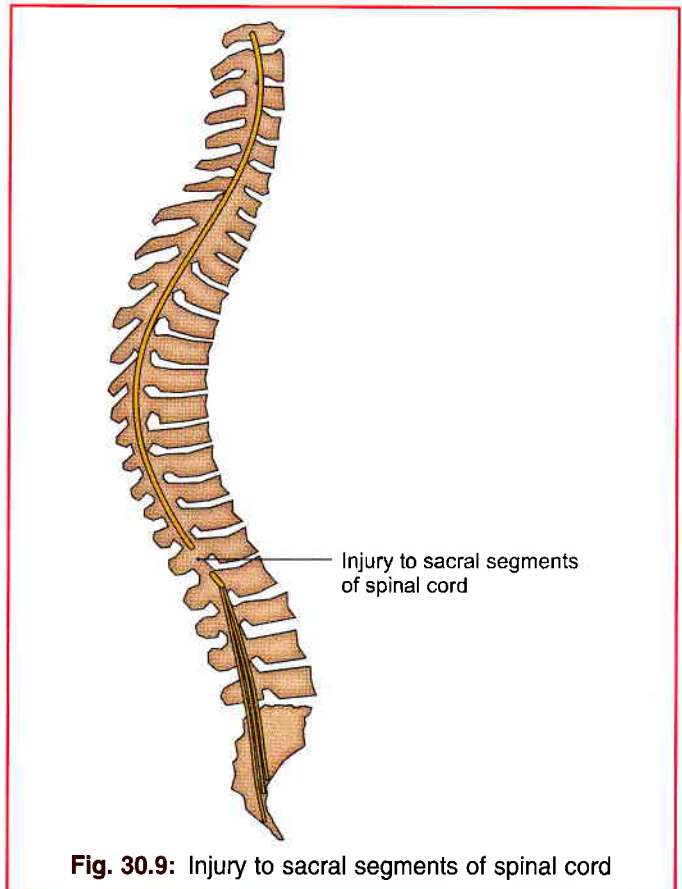


Fig. 30.9: Injury to sacral segments of spinal cord

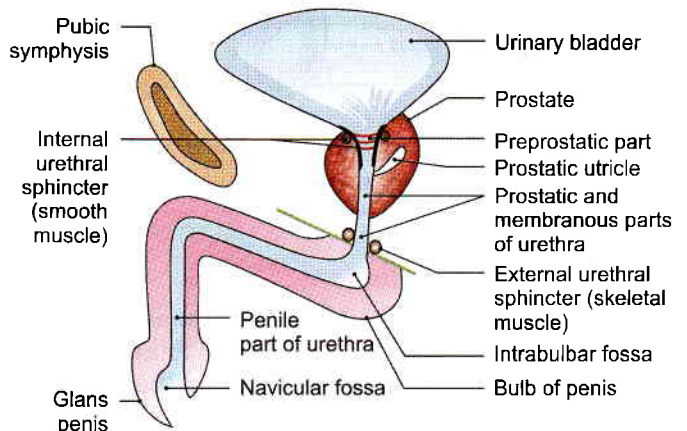


Fig. 30.10: Left view of a sagittal section through the male urethra showing its subdivisions

- 2 Relatively long anterior urethra which is 16 cm long within the perineum (proximally) and penis (distally). It is surrounded by corpus spongiosum and is functionally a conduit.

Anterior urethra

- a. Bulbar urethral (proximal) component surrounded by bulbospongiosus. Entirely within perineum (Fig. 30.11).

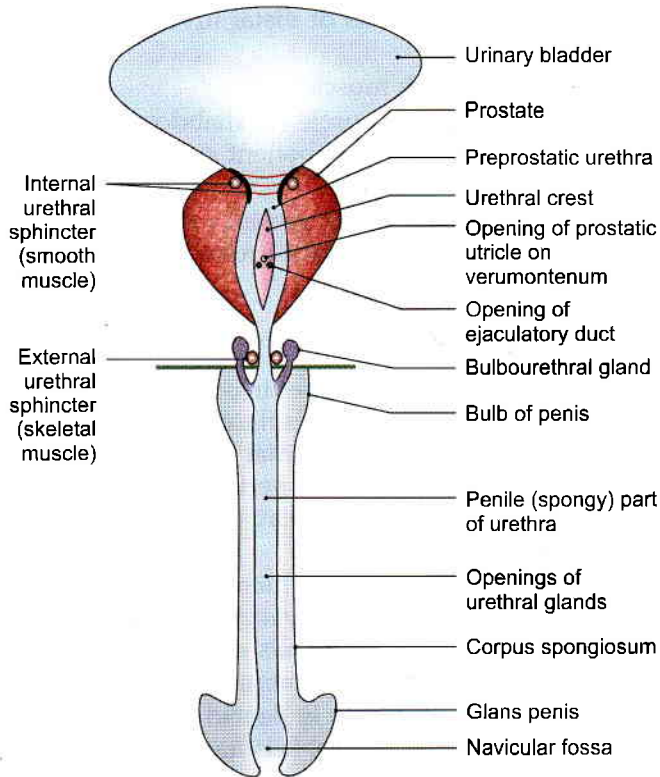


Fig. 30.11: Anterior view of the male urethra straightened and cut open

b. Pendulous/penile component that continues to the tip of penis.

In flaccid penis, urethra as a whole represents double curve except during the passage of fluid along it. The urethral canal is a mere slit.

In transverse section:

- The urethral slit is crescentic or transversely arched in prostatic part (Fig. 30.12).
- In the preprostatic and membranous part it is stellate.

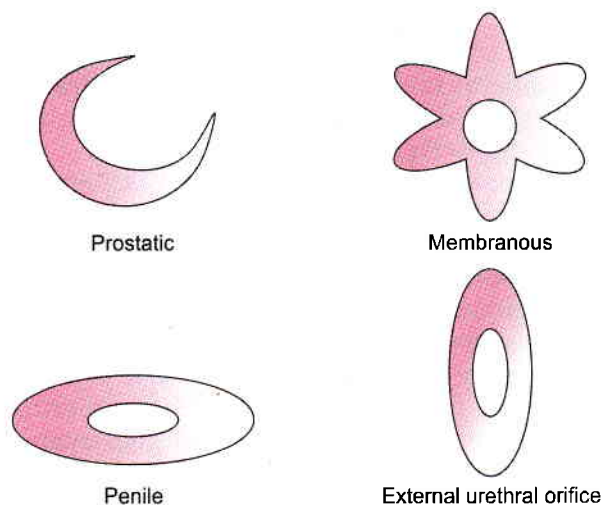


Fig. 30.12: Shape of different parts of the male urethra

- In bulbar and penile portions it is transverse.
- In external urethral orifice it is sagittal.

Passage of urine through different shapes of urethra causes it to flow in a continuous stream. Since it is passing under pressure, stream falls a little away from the body. Males can urinate standing without wetting themselves.

Posterior Part

Preprostatic Part

1–1.5 cm in length. It extends almost vertically from bladder neck to verumontanum (superior aspect) in prostatic urethra.

The preprostatic part is surrounded by proximal urethral sphincter mechanism (Fig. 30.10).

Proximal urethral sphincter mechanism

In addition to the smooth muscle bundles which run in continuity from the bladder neck down to the prostatic urethra and distinct from the smooth muscle within the prostate, smooth muscle bundles, surround the bladder neck and preprostatic urethra. They are arranged as distinct circular collar which has its own distinct adrenergic innervations.

The bundles which form this preprostatic sphincter are small in size compared with the muscle bundles of detrusor and are separated by a relatively larger connective tissue component rich in elastic fibres.

It is also different in that unlike detrusor and rest of urethral smooth muscle (common to both sexes), the preprostatic sphincter is almost totally devoid of parasympathetic cholinergic nerves.

Contraction of preprostatic urethra serves to prevent retrograde flow of ejaculate through proximal urethra into bladder.

It may maintain continence when external sphincter has been damaged. It is extensively disrupted in vast majority of men with:

- Bladder neck surgery.
- Transurethral resection of prostate.

So retrograde ejaculation occurs in such patients.

It is absent in female.

Simple mucus-secreting glands lie in the tissue around the preprostatic urethra and surrounded by the preprostatic sphincter. These simple glands are similar to those in the female urethra and are unlike the glands of prostate.

Prostatic Part

3–4 cm in length. It tunnels through the substance of prostate closer to anterior than the posterior surface of gland. Emerging from the prostate slightly anterior to the apex (most inferior part), urethra turns inferiorly as it passes through the prostate making an angle of 35°.



Throughout its length, the posterior wall has a midline ridge called as *urethral crest*. This crest projects into the lumen causing the lumen to appear crescentic in transverse section.

On each side of crest are shallow depression called *prostatic sinus*, the floor of which is perforated by orifices of 15–20 ducts prostatic ducts.

There is an elevation called *verumontanum* (colliculus seminalis) at about middle of urethral crest. It contains slit-like orifice of prostatic utricle.

On both side of or just within this orifice are the two small openings of the ejaculatory ducts (Fig. 30.11).

Prostatic utricle

It is a cul-de-sac 6 mm long, which runs upwards and backwards in the substance of prostate behind its median lobe. The walls are composed of fibrous tissue, muscle fibres and mucous membrane. The mucous membrane is pitted by the openings of numerous small glands. It develops from paramesonephric ducts or urogenital sinus and is thought to be homologous with the vagina of female.

So vagina masculine is also a name for this prostatic utricle.

Lowermost part of prostatic urethra is fixed by puboprostatic ligaments and is, therefore, immobile.

Membranous Part

It is 1.5 cm, shortest, least dilatable and with the exception of external orifice is the narrowest section of urethra. Descends with a slight ventral concavity from the prostate to bulb of penis, passing through the perineal membrane. 2.5 cm posteroinferior to pubic symphysis.

Wall of membranous urethra, i.e. part of external or distal urethral sphincter mechanism

Its muscle coat is separated from epithelium by narrow layer of fibroelastic connective tissue. Muscle coat consists of relatively thin layer of bundles of smooth muscle, which are continuous proximally with those of prostatic urethra and a prominent outer layer of the circularly oriented striated muscle fibres (rhabdosphincter) which form external urethral sphincter.

External sphincter represents points of highest in-transurethral pressure in the normal, contracted state.

Intrinsic striated muscle is made of fibres of very small diameter, devoid of muscle spindles, physiologically being slow twitch type, unlike pelvic floor with heterogenous mixture of slow and fast twitch type of larger diameter. So slow twitch fibres of sphincter are capable of sustained contraction over long period of time and contribute to tone that closes the urethra and maintains urinary continence.

So several components of distal urethral sphincter mechanism are:

- Urethral smooth muscle.
- Urethral striated muscle (of rhabdosphincter). It is most important component as it is capable of sustained contractions.
- Pubourethral part of levator ani, important to resist surges of intra-abdominal pressure (on coughing or exercise).

Anterior Part

Anterior or spongiosus part lies in corpus spongiosum and is 16 cm long when penis is flaccid. It extends from membranous urethra to external urethral orifice on glans penis. It starts below the perineal membrane at a point anterior to the lowest part of pubic symphysis (Fig. 30.11).

Part of anterior urethra which is surrounded by bulbospongiosus is called *bulbar urethra* and is wide part of urethra. Bulbourethral glands open in this section 2.5 cm below the perineal membrane.

From here, when penis is flaccid, urethra curves downwards as *penile urethra*. It is narrow and slit-like when empty and has diameter of 6 mm when passing urine. It is dilated at its termination within the glans penis and dilatation is called "navicular fossa".

External urethral orifice is the narrowest part of urethra and is a sagittal slit, 6 mm long, bounded on each side by a small labium.

Epithelium of urethra, particularly in bulbar and distal penile segment presents orifice of numerous small glands and follicles situated in the submucous tissue called *urethral glands*. It contains a number of small pit-like recesses, or lacunae of varying size whose orifice are directed forwards.

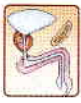One lacuna larger than the rest is *lacuna magna* which is situated on the roof of navicular fossa.

CLINICAL ANATOMY

Traumatic to urethra injured by a fall-astride (or straddle) results in injury to penile urethra in the perineum (see Fig. 28.15).

Extravasation of urine occurs but is prevented from going:

- Posteriorly as the perineal membrane and the membranous layer of superficial fascia are continuous with the fascia around superficial transverse perinei.
- Laterally by ischial and pubic rami.
- Above to lesser pelvis by intact perineal membrane. So, extravasated urine goes anteriorly into the loose connective tissue of scrotum and penis and then to anterior abdominal wall.



Arteries

- 1 Urethral artery arises from internal pudendal artery just below perineal membrane and travels through corpus spongiosum to reach glans penis.
- 2 Dorsal penile artery via circumflex branches on each side.

Veins

Anterior urethra → dorsal vein of penis → internal pudendal vein which drains into prostatic venous plexus → internal iliac veins.

Posterior urethra → prostatic and vesical venous plexus → internal iliac veins.

Lymphatic

- 1 Prostatic urethra → internal iliac.
- 2 Membranous urethra → internal iliac.
- 3 Anterior urethra → accompany that of glans → deep inguinal.

Innervation

Prostatic plexus supplies the smooth muscle of prostate and prostatic urethra. Greater cavernous nerves are sympathetic to preprostatic sphincter during ejaculation. Parasympathetic nerves are from 2nd–4th sacral segments.

Nerve supply of rhabdosphincter is controversial but is said to be by neurons in Onuf's nucleus situated in sacral 2 segment of spinal cord fibres pass via perineal branch of pudendal nerve.

FEMALE URETHRA

Female urethra is only 4 cm long and 6 mm in diameter. It begins at the internal urethral orifice of bladder, approximately opposite middle of the pubic symphysis and runs anteroinferiorly behind the symphysis pubis, embedded in anterior wall of vagina. It crosses the perineal membrane and ends at external urethral orifice as an anteroposterior slit with rather prominent margins situated directly anterior to the opening of vagina and 2.5 cm behind glans clitoridis.

Except during passage of urine anterior and posterior wall of canal possesses a ridge which is termed urethral crest. Many small mucous urethral glands and minute pit-like recess or lacunae open into urethra. On each side, near the lower end of urethra, a number of these glands are grouped and open into a duct, named *paraurethral duct*.

Each paraurethral duct runs down in the submucous tissue and ends in a small aperture on the lateral margins of external urethral orifice.

Arteries

Superior vesical and vaginal arteries.

Veins

Venous plexus around urethra → vesical venous plexus → internal pudendal vein → internal iliac vein.

Lymphatic

Internal and external iliac nodes.

Innervation

Parasympathetic preganglionic fibres from 2nd–4th sacral segments of spinal cord. These run through pelvic splanchnic nerves and synapse in vesical venous plexus. Postganglionic fibres reach smooth muscles.

Somatic fibres from same segments (S2–S4) reach the striated muscles through pelvic splanchnic nerves that do not synapse in vesical plexus.

Sensory fibres in pelvic splanchnic nerves reach to 2nd–4th sacral segments of spinal cord. Postganglionic sympathetic fibres arise from plexus around the vaginal arteries.

WALLS OF URETHRA

Wall has outer muscle coat and inner mucosa that lines the lumen and is continuous with that of bladder.

Muscle coat: Outer sheath of striated muscle/external urethral sphincter or distal sphincter mechanism together with smooth muscle.

Female external urethral sphincter is anatomically separate from the adjacent periurethral striated muscle of the anterior pelvic floor, i.e. pubourethralis part of levator ani.

The sphincter form a sleeve which is thickest anteriorly in the middle one-third of urethra, and is relatively deficient posteriorly. The striated muscle extends into the anterior wall of both proximal and distal thirds of urethra, but is deficient posteriorly. Muscle cells forming external urethral sphincter are all small diameter slow twitch fibres.

Smooth muscle coat (inner) extends throughout the length of urethra. A few circularly arranged muscle fibres occur in the outer aspect of nonstriated muscle layer which are oblique or longitudinally oriented and these intermingle with striated muscle fibres forming inner parts of external urethral sphincter.

Proximally, the urethral smooth muscle extends as far as the neck of bladder where it is replaced by detrusor smooth muscle. But this region in the females *lacks* well-defined circular smooth muscle components comparable to the *preprostatic sphincter* of male. Women do not possess an internal urethral sphincter.

Distally, urethral smooth muscle terminate in subcutaneous adipose tissue around external urethral meatus.



Smooth muscle of female urethra receives an extensive presumptive cholinergic nerve supply, but few noradrenergic fibres.

In the absence of an anatomical sphincter, competence of female bladder neck and proximal urethra is unlikely to be totally dependent on smooth muscle activity and is probably related to support provided by ligamentous structures which surround them.

Longitudinal orientation and the innervation of muscles suggests that urethral smooth muscle in female is active during micturition and serves to shorten and widen urethral lumen.

MICTURITION

- 1 Initially the bladder fills without much rise in the intravesical pressure. This is due to adjustment of bladder tone.
- 2 When the quantity of urine exceeds 220 cc, the intravesical pressure rises. This stimulates sensory nerves and produces a desire to micturate. If this is neglected, rhythmic reflex contractions of the detrusor muscle start, which become more and more powerful as the quantity of urine increases. This gives a feeling of fullness of the bladder, which later on becomes painful. The voluntary holding of urine is due to contraction of the sphincter urethrae and of the perineal muscles, with coincident inhibition of the detrusor muscle.
- 3 Micturition is initiated by the following successive events.
 - a. First there is relaxation of perineal muscles, except the distal urethral sphincter and contraction of the abdominal muscles.
 - b. This is followed by firm contraction of the detrusor and relaxation of the proximal urethral sphincter mechanism.
 - c. Lastly, distal urethral sphincter mechanism relaxes, and the flow of urine begins.
- 4 The bladder is emptied by the contraction of the detrusor muscle. Emptying is assisted by the contraction of abdominal muscles.
- 5 When urination is complete, the detrusor muscle relaxes, the proximal urethral sphincter mechanism contracts, and finally the distal urethral sphincter mechanism contracts. In the male, the last drops of urine are expelled from the bulbar portion of the urethra by contraction of the bulbospongiosus.

HISTOLOGY OF URINARY BLADDER

The epithelium of urinary bladder is of transitional variety. The luminal cells are well-defined dome shaped squamous cells with prominent nuclei. The middle

layers are pear-shaped cells and the basal layer is of short columnar cells. The muscle coat is admixture of longitudinal, circular and oblique layers. Outermost layer is the serous or adventitial coat.

DEVELOPMENT OF URINARY BLADDER AND URETHRA

Cloaca (Latin *sewer*) is divided by the *urorectal septum* into posterior *anorectal canal* and anterior *primitive urogenital sinus*. The cranial and largest part of primitive urogenital sinus called the *vesicourethral canal* forms most of the urinary bladder. It is connected with the *allantois*. The lumen of allantois gets obliterated to form *urachus* connecting the apex of the bladder to the umbilicus. This ligament is the *median umbilical ligament*. *Trigone* of bladder is formed by the absorption of *mesonephric ducts* and is mesodermal in origin. With time, the mesodermal lining is replaced by endodermal epithelium. So the epithelium is wholly endodermal, while muscles are of splanchnic origin.

- 1 Vesicourethral canal formed by endoderm forms the anterior wall of prostatic urethra above the opening of prostatic utricle.
- 2 Absorbed portions of the mesonephric ducts, i.e. mesoderm forms posterior wall of prostatic urethra above the opening of prostatic utricle.
- 3 Definitive urogenital sinus formed by endoderm forms the lower part of prostatic urethra and the membranous urethra.
- 4 Urethral plate or endoderm forms most of the anterior part of urethra.
- 5 Surface epithelium of glans penis or ectoderm forms the terminal portion of penile urethra.

CLINICAL ANATOMY

- *Catheterization of bladder*: In some cases, the patient is unable to pass urine leading to retention of urine. In such cases a rubber tube called a *catheter* is passed into the bladder through the urethra. While passing a catheter one has to remember the normal curvatures of the urethra. It has also to be remembered that the lacunae are directed forwards, and may intercept the point of the catheter (Fig. 30.13). Forceful insertion of instruments may create false passages in the urethra.
- *Rupture of urethra*: The urethra is commonly ruptured beneath the pubis by a fall astride a sharp object. This causes extravasation of urine (see Figs 28.15 and 28.16).
- Infection of the urethra is called *urethritis*.
- A constriction of the urethra is called *stricture* of the urethra. It is usually a result of infection.



- *Hypospadias* is a common anomaly in which the urethra opens on the undersurface of the penis or in the perineum.
- *Epispadias* is a rare condition in which the urethra opens on the dorsum of the penis. The condition is associated with ectopia vesicae and absence of infraumbilical part of anterior abdominal wall.

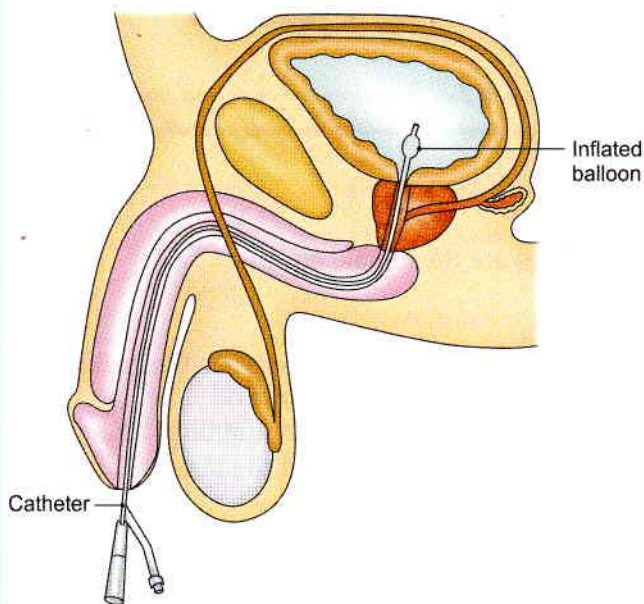


Fig. 30.13: Catheterisation of urinary bladder in male

FACTS TO REMEMBER

- Most fixed part of urinary bladder is the neck of bladder.
- Widest part of male urethra is prostatic part
- Least dilatable part of male urethra is the membranous part. Narrowest part of urethra is external urethral orifice.
- Prostatic utricle represents the vagina of female.
- Proximal urethral sphincter is lacking in the female.

CLINICOANATOMICAL PROBLEM

A female patient about 50 years suffered injuries in her pelvic region. X-ray showed fracture of pubic bones and catheterized urine specimen showed the presence of blood.

- What organ is most likely to be injured?
- Why is there blood in the urine specimen?
- Where would the extravasated urine go from the ruptured urinary bladder?

Ans: The organ ruptured is the urinary bladder. The pubic bones have also got fractured. As the bladder has ruptured few blood vessels are injured, making the urine red.

Urine would pass in the pelvic cavity and behind ascending and descending colons into the paracolic gutters. On percussion over descending colon, the note would be dull, When the patient is rolled to right side, urine escapes to right side and the note over the descending colon gets resonant.

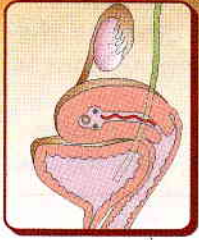
MULTIPLE CHOICE QUESTIONS

- Which of the following is true regarding the innervations of urinary bladder?
 - Parasympathetic efferent fibres are motor to detrusor muscle
 - Sympathetic nerves are sensory to sphincter urethrae
 - Pudendal nerve innervates sphincter vesicae
 - Awareness of distension of urinary bladder is mediated by lateral spinothalamic tract
- Which of the following is the shortest part of urethra?
 - Prostatic
 - Membranous
 - Perineal
 - Penile
- Capacity of urinary bladder in adult is about:

a. 300 ml	b. 200 ml
c. 500 ml	d. 1500 ml
- Which of the following sphincters is missing in female?
 - Rhabdosphincter
 - Preprostatic sphincter
 - Urethral smooth muscle
 - Pubourethral part of levator ani
- Urinary bladder develops from the following *except*:
 - Vesico-urethral canal
 - Absorption of mesonephric ducts
 - Urachus
 - Urethral plate

ANSWERS

1. a 2. b 3. a 4. b 5. d



Female Reproductive Organs

*No woman can call herself free who does not own and control her body.
No woman can call herself free until she can choose consciously whether she will or will not be a mother*
—Margaret Sanger

INTRODUCTION

Female reproductive organs include external and internal genital organs. The external genital organs have been described in Chapter 28.

The internal genital organs comprise a pair of ovaries, a pair of uterine/fallopian tubes, single uterus and vagina. The ovaries are homologous to the testes of males but lie within the pelvis. The ovaries are much smaller than the testes.

INTERNAL GENITAL ORGANS

DISSECTION

Cut through the pubic symphysis with a knife in the median plane and extend the incision into the urethra. Make a median dorsal cut with a saw through the fourth and fifth lumbar vertebrae, the sacrum and coccyx to meet the knife. Cut through the soft tissues.

Separate the two halves of the pelvis and examine the cut surface of all the tissues.

Locate the ovary on the lateral wall of pelvis in the female cadaver. Identify the ovarian vessels in the infundibulopelvic ligament and trace these to the ovary and uterine tube. Follow the ovarian artery till its anastomosis with the uterine artery.

Identify the uterus and follow the peritoneum on its superior and inferior surfaces which is thus free to move. Trace the uterus downwards till the supravaginal part of cervix which is attached to the lateral pelvic wall by transverse cervical ligaments and to the sacrum by uterosacral ligaments.

The vaginal part of cervix is surrounded on all sides by fornices of the vagina. The posterior fornix is the deepest. These can be felt by putting index and middle fingers through the vagina.

Identify the broad ligament attaching uterus to the lateral pelvic wall and note various structures present in its borders and surfaces.

OVARIES

The ovaries are the female gonads.

Situation

Each ovary lies in the ovarian fossa on the lateral pelvic wall. The ovarian fossa is bounded:

- 1 Anteriorly by the obliterated umbilical artery.
- 2 Posteriorly by the ureter and the internal iliac artery (Fig. 31.1).

Position

The position of the ovary is variable. In nulliparous women, its long axis is nearly vertical, so that the ovary is usually described as having an upper pole and a lower pole. However, in multiparous women, the long axis becomes horizontal; so that the upper pole points laterally and the lower pole medially (Figs 31.2a and b).

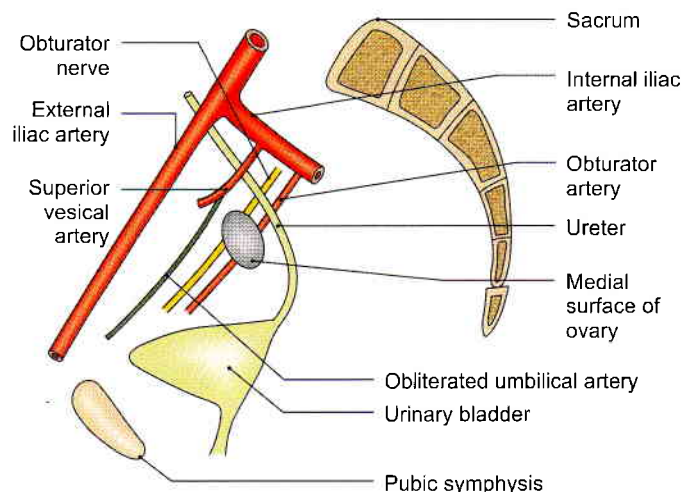
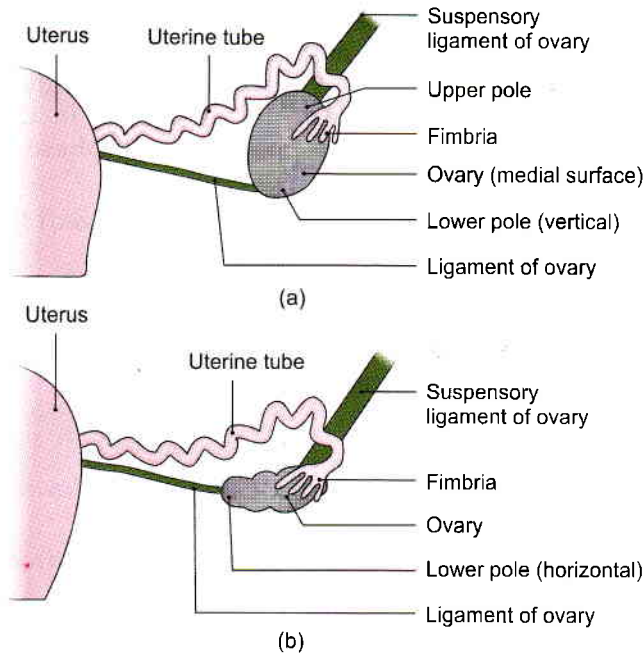
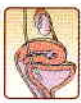

Fig. 31.1: Medial view of the boundaries of the ovarian fossa as seen in a sagittal section



Figs 31.2a and b: Positions of the ovary. (a) It is vertical in nullipara, and (b) horizontal in multipara (after one or more deliveries) due to the pull by the pregnant uterus

EXTERNAL FEATURES

In young girls, *before the onset of ovulation*, the ovaries have smooth surfaces which are greyish pink in colour. *After puberty*, the surface becomes uneven and the colour changes from pink to grey.

Each ovary has *two poles or extremities*, the upper or tubal pole, and the lower or uterine pole; *two borders*, the anterior or mesovarian border, and the posterior or free border; and *two surfaces*, lateral and medial.

Relations

Peritoneal Relations

The ovary is almost entirely covered with peritoneum, except along the mesovarian or anterior border where the two layers of the covering peritoneum are reflected on to the posterior layer of the broad ligament of the uterus. The ovary is connected to the posterior layer of the broad ligament by a short fold of peritoneum, called the *mesovarium* (Fig. 31.3). The squamous epithelium of the *mesovarium* is continuous with the cubical epithelium of the ovary. The mesovarium transmits the vessels and nerves to and from the ovary (see Fig. 18.21).

The lateral part of the broad ligament of uterus, extending from the infundibulum of the uterine tube and the upper pole of the ovary, to the external iliac vessels, forms a distinct fold known as *suspensory ligament of the ovary* or *infundibulopelvic ligament*. It contains the ovarian vessels and nerves (Fig. 31.4).

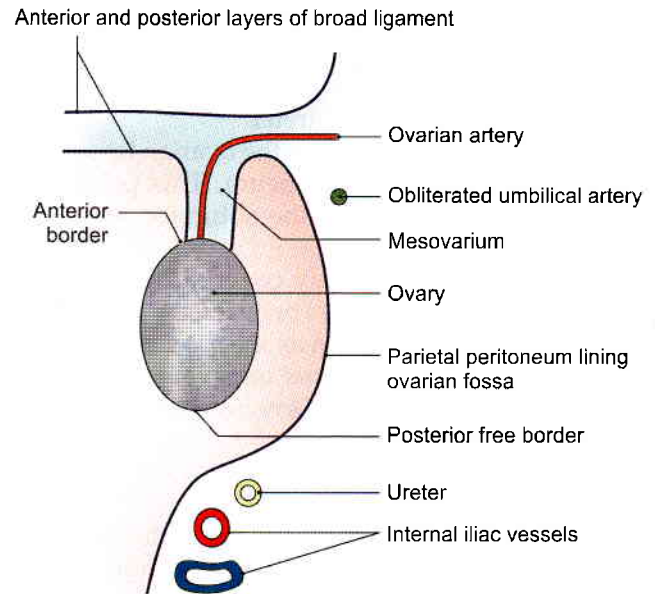


Fig. 31.3: Superior view of a horizontal section through the right ovarian fossa and the lateral part of the broad ligament

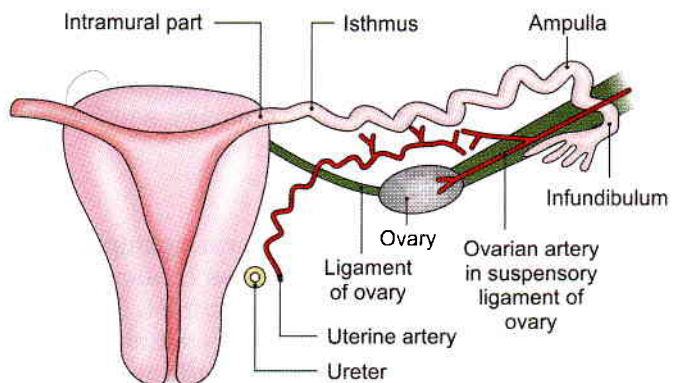


Fig. 31.4: The subdivisions, relations and blood supply of the uterine tube

Visceral Relations

- 1 Upper or tubal pole:** It is broader than the lower pole, and is related to the uterine tube and the external iliac vein. The right ovary may be related to the appendix if the latter is pelvic in position. The ovarian fimbria and the suspensory ligament of the ovary are attached to the upper pole of the ovary (Fig. 31.2).
- 2 Lower or uterine pole:** It is narrower than the upper pole and is related to the pelvic floor. It is connected, by the ligament of the ovary, to the lateral angle of the uterus, posteroinferior to the attachment of the uterine tube. The ligament lies between the two layers of the broad ligament of the uterus and contains some smooth muscle fibres (Fig. 31.2).
- 3 Anterior or mesovarian border:** It is straight and is related to the uterine tube and the obliterated umbilical artery. It is attached to the back of the broad



ligament of the uterus by the mesovarium, and forms the *hilus* of the ovary (Fig. 31.3).

- 4 *Posterior or free border*: It is convex and is related to the uterine tube and the ureter.
- 5 *Lateral surface*: It is related to the ovarian fossa which is lined by parietal peritoneum. This peritoneum separates the ovary from the obturator vessels and nerve (Fig. 31.1).
- 6 *Medial surface*: It is largely covered by the uterine tube. The peritoneal recess between the mesosalpinx and this surface is known as the *ovarian bursa*.

Only the lower pole and lateral surfaces are not related to uterine tube, remaining two borders, upper pole and medial surface are related to the tube.

Arterial Supply

- 1 The *ovarian artery* arises from the abdominal aorta just below the renal artery. It descends over the posterior abdominal wall and enters the suspensory ligament of the ovary. It sends branches to the ovary through the mesovarium, and continues medially through the broad ligament of the uterus to anastomose with the uterine artery (Fig. 31.4). In addition to ovary, the ovarian artery also supplies the uterine tube, the side of uterus and the ureter.
- 2 The uterine artery gives some branches which reach the ovary through the mesovarium.

Venous Drainage

The veins emerge at the hilus and form a pampiniform plexus around the artery. The plexus condenses into a single ovarian vein near the pelvic inlet. This vein ascends on the posterior abdominal wall and drains into the *inferior vena cava* on the right side and into the *left renal vein* on the left side.

Lymphatic Drainage

The lymphatics from the ovary communicate with the lymphatics from the uterine tube and fundus of the uterus. They ascend along the ovarian vessels to drain into the lateral aortic and preaortic nodes.

Nerve Supply

The ovarian plexus, derived from the renal, aortic and hypogastric plexuses, accompanies the ovarian artery. It contains both sympathetic and parasympathetic nerves. Sympathetic nerves (T10, T11) are afferent for pain as well as efferent or vasomotor. Parasympathetic nerves (S2, S3, S4) are vasodilator.

Functions

- 1 *Production of oocytes*: During reproductive life of about 30 years (from puberty to menopause), the ovaries produce alternately one secondary oocyte per month (per ovarian cycle of 28 days).

Liberation of oocyte from the ovary is called *ovulation*. It occurs on or about the 14th day of the 28-day menstrual cycle. Variations in the length of menstrual cycle are due to variations in the preovulatory phase; the postovulatory phase is constant.

An oocyte is viable (capable of being fertilized) for about 12–24 hours.

2 Production of hormones:

- a. *Oestrogen* is secreted by the follicular and paraluteal cells.
- b. *Progesterone* is secreted by the luteal cells.

HISTOLOGY

Histologically, the ovary is made up of the following parts from without inwards.

- 1 *Germinal epithelium* of cubical cells, derived from peritoneum.
- 2 *Tunica albuginea* is a thin layer of connective tissue.
- 3 The *cortex* contains *ovarian follicles* at various stages of development. Each follicle contains one oocyte. One follicle matures every month and sheds an oocyte. Total of 400 oocytes are ovulated in the reproductive life. After the oocyte is liberated the Graafian follicle is converted into a structure called the *corpus luteum*.
- 4 The hormone oestrogen is secreted by follicular cells of ovarian follicles. Another hormone, progesterone, is produced by the corpus luteum.
- 5 Medulla has rich vascular connective tissue, containing vessels, nerves and lymphatics.

CLINICAL ANATOMY

- *Determination of ovulation*: In cases of sterility, the ovulation can be determined by repeated ultrasonography.
- *Prolapse of ovaries*: Ovaries are frequently displaced to the pouch of Douglas where they can be palpated by a PV or per vaginal examination.
- *Ovarian cysts*: The developmental arrest of the ovarian follicles may result in the formation of one or more small ovarian cysts. Multiple small theca lutein cysts involve both the ovaries in cases with *Stein-Leventhal syndrome*. The syndrome is characterized by mild hirsutism, deep voice, secondary amenorrhoea, and cystic enlargement of both the ovaries.
- *Carcinoma of ovary* is common, and accounts for 15% of all cancers and 20% of gynaecological cancers.
- Ovaries are the commonest site in the abdomen for endometriosis. The endometrial cysts in the ovary are called the *chocolate cysts*.



UTERINE TUBES

Synonym

The uterine tubes are also called *fallopian tubes/salpinx*.

Definition

They are tortuous ducts which convey oocyte from the ovary to the uterus. Spermatozoa introduced into the vagina pass up into the uterus, and from there into the uterine tubes. Fertilization usually takes place in the lateral part of the tube.

Situation

These are situated in the free upper margin of the broad ligament of uterus.

Dimensions

Each uterine tube is about 10 cm long. At the lateral end, the uterine tube opens into the peritoneal cavity through its *abdominal ostium*. This ostium is about 3 mm in diameter.

Subdivisions

- 1 The lateral end of the uterine tube is shaped like a funnel and is, therefore, called the *infundibulum*. It bears a number of finger-like processes called *fimbriae* and is, therefore, called the *fimbriated end*. One of the fimbriae is longer than the others and is attached to the tubal pole of the ovary. It is known as the *ovarian fimbria* (Fig. 31.2).
- 2 The part of the uterine tube medial to the infundibulum is called the *ampulla*. It is thin-walled, dilated and tortuous, and forms approximately the lateral two-thirds or 6 to 7 cm of the tube. It arches over the upper pole of the ovary. The ampulla is about 4 mm in diameter (Fig. 31.4). This is the site for fertilisation.

- 3 The *isthmus* succeeds the ampulla. It is narrow, rounded and cord-like. It forms approximately the medial one-third or 2 to 3 cm of the tube.
- 4 The *uterine* or *intramural* or *interstitial* part of the tube is about 1 cm long and lies within the wall of the uterus. It opens at the superior angle of the uterine cavity by a narrow *uterine ostium*. This ostium is about 1 mm in diameter.

Course and Relations

- 1 The isthmus and the adjoining part of the ampulla are directed posterolaterally in a horizontal plane. Near the lateral pelvic wall, the ampulla arches over the ovary and is related to its anterior and posterior borders, its upper pole and its medial surface. The infundibulum projects beyond the free margin of the broad ligament.
- 2 The uterine tube lies in the upper free margin of the broad ligament of the uterus. The part of the broad ligament between the attachment of the mesovarium and the uterine tube is known as the *mesosalpinx* (Fig. 31.5). It contains the termination of the uterine and ovarian vessels and the epoophoron.

Blood Supply

The *uterine artery* supplies approximately the medial two-thirds, and the *ovarian artery* supplies the lateral one-third, of the tube. The *veins* run parallel with the arteries and drain into the pampiniform plexus of the ovary and into the uterine veins (Fig. 31.4).

Lymphatic Drainage

Most of the tubal lymphatics join the lymphatics from the ovary and drain with them into the *lateral aortic* and *preaortic nodes*. The lymphatics from the isthmus accompany the round ligament of the uterus and drain into the *superficial inguinal nodes*.

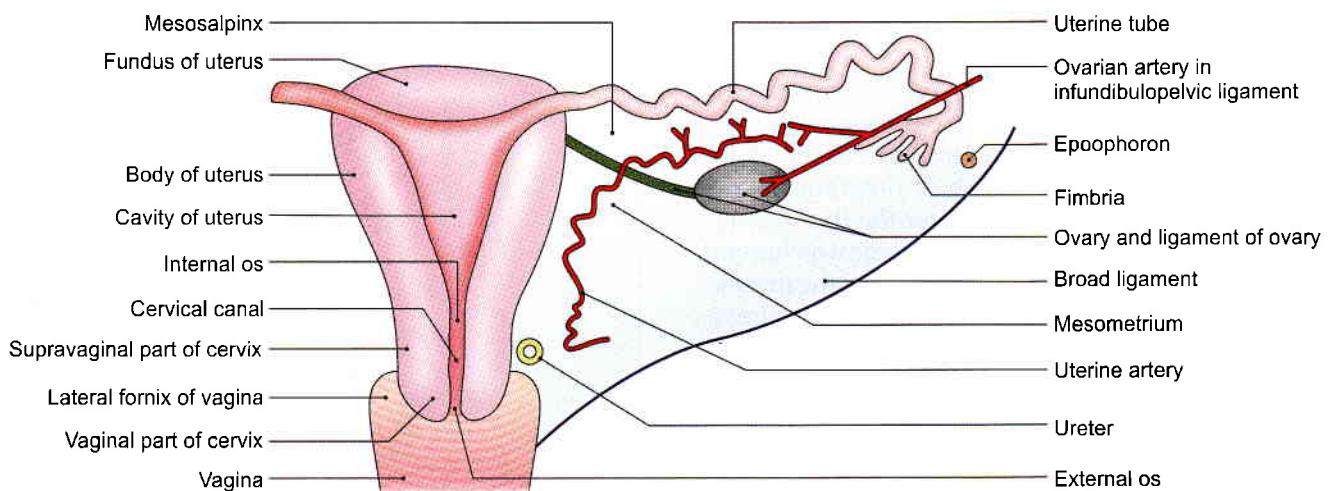


Fig. 31.5: Posterosuperior view of the uterus and the right broad ligament



Nerve Supply

The uterine tubes are supplied by both the sympathetic and parasympathetic nerves running along the uterine and ovarian arteries.

- 1 The *sympathetic nerves* from T10 to L2 segments are derived from the hypogastric plexuses. They contain both visceral afferent and efferent fibres. The latter are vasomotor and perhaps stimulate tubal peristalsis. However, peristalsis is mainly under hormonal control.
- 2 *Parasympathetic nerves* are derived from the vagus for the lateral half of the tube and from the pelvic splanchnic nerves from S2, S3, S4 segments of spinal cord for the medial half. They inhibit peristalsis and produce vasodilatation.

HISTOLOGY

Uterine tube is made up of the following coats.

- 1 An outer *serous coat*, derived from peritoneum.
- 2 The middle *muscular coat*, which is thick in the isthmus and thin in the ampulla. The circular muscle coat is thickest in the isthmus and acts as a sphincter which delays the progress of the zygote towards the uterus until it is sufficiently mature for implantation.
- 3 The inner *mucous membrane*, which is lined by the ciliated columnar epithelium mixed with the non-ciliated secretory cells or peg cells. The mucous membrane is thrown into *complicated folds* which fill up the lumen of the tube. In the isthmus, there are only 3–6 primary folds and the cilia tend to disappear. But in the ampulla, the folds are more complex and exhibit the secondary and even tertiary folds.

CLINICAL ANATOMY

- *Salpingitis*: Inflammation of the uterine tube is called salpingitis (Salpinx=trumpet or tube).
- *Sterility*: Inability to have a child is called sterility. The most common cause of sterility in the female is tubal blockage which may be congenital, or caused by infection. Patency of the tube can be investigated by:
 - a. *Insufflation test* or *Rubin's test*. Normally, air pushed into the uterus passes through the tubes and leaks into the peritoneal cavity. This leakage produces a hissing or bubbling sound which can be auscultated over the iliac fossae.
 - b. *Hysterosalpingography* is a radiological technique by which the cavity of the uterus and the lumina of the tubes can be visualized, after injecting a radiopaque oily dye into the uterus (Fig. 31.6).
- *Tubal pregnancy*: Sometimes the fertilized ovum instead of reaching the uterus adheres to the walls of the uterine tube and starts developing there. This is known as *tubal pregnancy*. The enlarging embryo may lead to rupture of tube.

- *Tubectomy*: For purposes of family planning a woman can be sterilized by removing a segment of the uterine tube on both sides. This can be done by laparoscopy (Fig. 31.7) or through an incision in abdominal wall (Fig. 31.8).
- *Transport of ovum*: The transport of ovum is chiefly due to muscular contractions. The ciliary movements create an effective stream of lymph towards the uterus which assists in the nourishment of ovum in the lumen of the tube over the mucosal ridges.

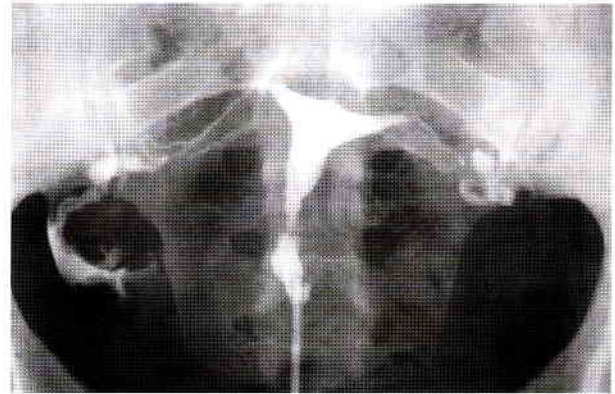


Fig. 31.6: Hysterosalpingogram

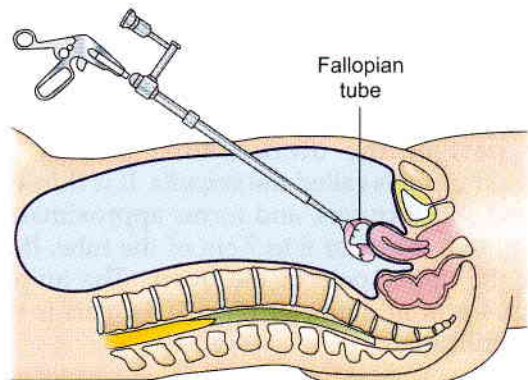


Fig. 31.7: Laparoscopic sterilisation

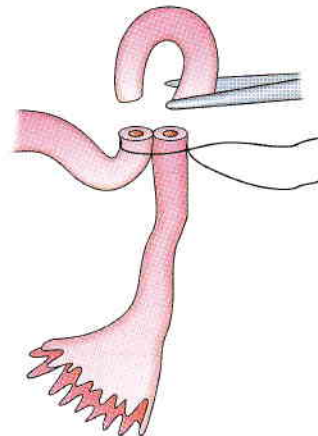


Fig. 31.8: Abdominal sterilisation



UTERUS

Synonym

In layman's language, the uterus is called the womb. It is also called *hystera*, on which word hysterectomy is based.

Definition

Uterus is a child-bearing organ in females, situated in the pelvis between bladder and rectum. Though hollow, it is thick walled and firm, and can be palpated bimanually during a PV (per vaginal) examination.

It is the organ which protects and provides nutrition to a fertilized ovum, enabling it to grow into a fully formed foetus. At the time of childbirth or parturition contractions of muscle in the wall of the organ result in expulsion of the foetus from the uterus.

Size and Shape

The uterus is pyriform in shape. It is about 7.5 cm long, 5 cm broad, and 2.5 cm thick. It weighs 30 to 40 grams. It is divisible into an upper expanded part called the *body* and a lower cylindrical part called the *cervix*. The junction of these two parts is marked by a circular constriction called the isthmus. Part of uterus above the opening of fallopian tube is called the fundus. The body forms the upper two-thirds of the organ, and the cervix forms the lower one-third.

The superolateral angle of the body project outwards at the junction of body and fundus and is called cornua of uterus. The uterine tube, ligament of ovary and round ligament are attached to it on each side.

Normal Position and Angulation

Normally, the long axis of the uterus forms an angle of about 90 degrees with the long axis of the vagina. The angle is open forwards. The forward bending of the uterus relative to the vagina is called *anteversion*. The backward bending of the uterus relative to vagina is known as *retroversion*. The uterus is also slightly flexed at the level of internal os of cervix; this is referred to as *anteflexion*. The angle of anteflexion is 125 degrees (Figs 31.9a to c).

Roughly, the long axis of the uterus corresponds to the axis of the pelvic inlet, and the axis of the vagina to the axis of the pelvic cavity and of the pelvic outlet (see Fig. 29.6).

It is normally deviated to right side and is called dextrorotation.

Communications

Superiorly, the uterus communicates on each side with the uterine tube, and inferiorly, with the vagina (Fig. 31.5).

Parts of Uterus

The uterus comprises:

- 1 A fundus,
- 2 Body with two surfaces, anterior or vesical and posterior or intestinal.
- 3 Two lateral borders.

The *fundus* is formed by the free upper end of the uterus. Fundus lies above the openings of the uterine tubes. It is convex like a dome. It is covered with peritoneum and is directed forward when the bladder is empty. The fertilized oocyte is usually implanted in the posterior wall of the fundus (Fig. 31.5).

The *anterior* or *vesical surface* of the body is flat and related to the urinary bladder. It is covered with peritoneum and forms the posterior or superior wall of the uterovesical pouch.

The *posterior* or *intestinal surface* is convex and is related to coils of the terminal ileum and to the sigmoid colon. It is covered with peritoneum and forms the anterior wall of the rectouterine pouch (see Figs 18.17b and 18.21).

Each *lateral border* is rounded and convex. It provides attachment to the broad ligament of the uterus which connects it to the lateral pelvic wall. The uterine tube opens into the uterus at the upper end of this border. This end of the border gives attachment to the round ligament of the uterus, anteroinferior to the tube; and to the ligament of the ovary posteroinferior to the tube. The uterine artery ascends along the lateral border of the uterus between the two layers of the broad ligament (Figs 31.10 and 31.11).

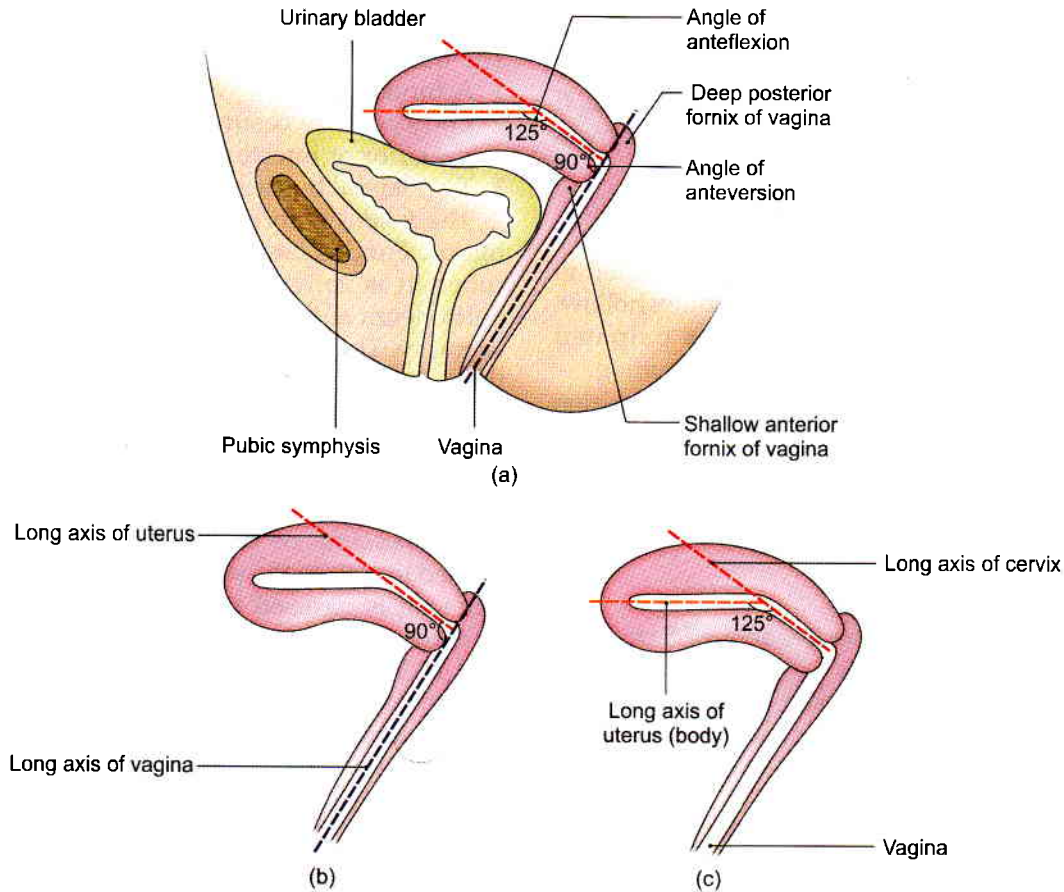
In sagittal section, the cavity of the body of the uterus is seen as a mere slit because the uterus is compressed anteroposteriorly. In coronal section, the cavity is seen to be triangular in shape, the apex being directed downwards. At the apex, the cavity becomes continuous with the canal of the cervix. The junction is called the *internal os*. The superolateral angles of the cavity receive the openings of the right and left uterine tubes (Fig. 31.5).

Cervix of Uterus

The cervix is the lower, cylindrical part of the uterus. It is less mobile than the body. It is about 2.5 cm long, and is slightly wider in the middle than at either end. The lower part of the cervix projects into the anterior wall of the vagina which divides it into supravaginal and vaginal parts.

The *supravaginal part* of the cervix is related:

- a. Anteriorly to the bladder.
- b. Posteriorly to the rectouterine pouch, containing coils of intestine and to the rectum (see Fig. 18.17b).
- c. On each side, to the ureter and to the uterine artery, embedded in parametrium. The fibrofatty



Figs 31.9a to c: (a) Angulations of the uterus and vagina, and their axes, (b) angle of anteversion, and (c) angle of antelexion

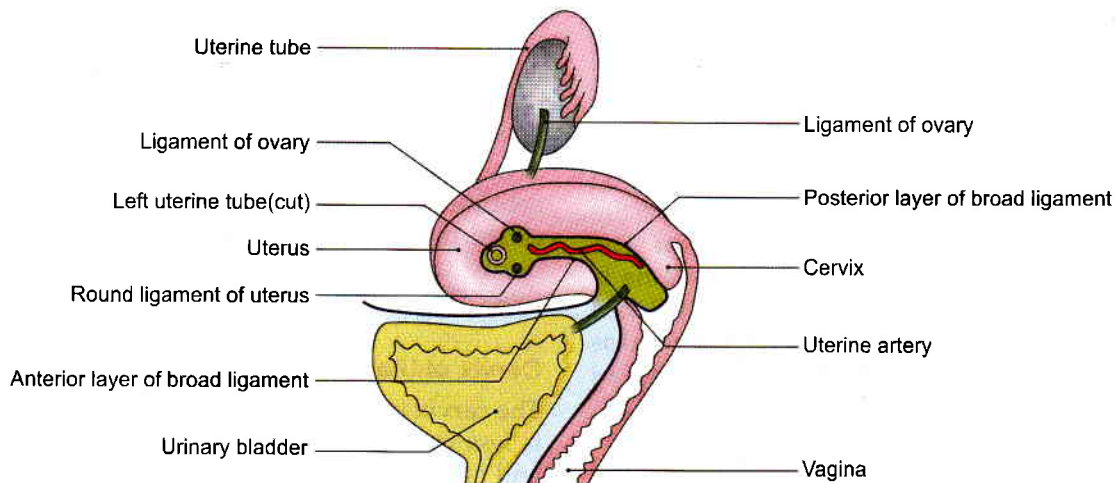


Fig. 31.10: Uterus, vagina and urinary bladder seen from the left side after removing the left broad ligament

tissue between the two layers of the broad ligament and below it, is called the *parametrium*. It is most abundant near the cervix and vagina (Fig. 31.10).

The *vaginal part* of the cervix projects into the anterior wall of the vagina. The spaces between it and the vaginal wall are called the *vaginal fornices*. The cervical

canal opens into the vagina by an opening called the *external os*. In a nulliparous woman, i.e. a woman who has not borne children, the external os is small and circular (Fig. 31.5). However, in multiparous women, the external os is bounded by anterior and posterior lips, both of which are in contact with the posterior wall of the vagina.

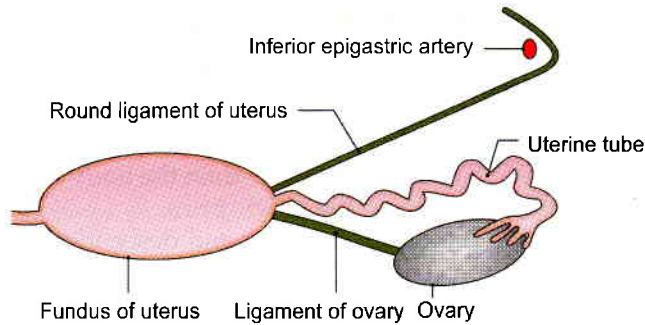


Fig. 31.11: Fundus of the uterus seen from above

The *cervical canal*, i.e. the cavity of the cervix is fusiform in shape. It communicates above with the cavity of the body of the uterus, through the *internal os*, and below with the vaginal cavity through the *external os*. The canal is flattened from before backwards so that it comes to have anterior and posterior walls. These walls show mucosal folds which resemble the branches of a tree called the *arbor vitae uteri*. The folds in the anterior and posterior walls interlock with each other and close the canal.

Ligaments of Uterus

Peritoneal Ligaments

These are mere peritoneal folds which do not provide any support to the uterus.

- 1 The *anterior ligament* consists of the uterovesical fold of peritoneum.
- 2 The *posterior ligament* consists of the rectovaginal fold of peritoneum (see Fig. 18.17).
- 3 The right and left *broad ligaments* are folds of peritoneum which attach the uterus to the lateral pelvic wall. When the bladder is full, the ligament has anterior and posterior surfaces, and upper, lower, medial and lateral borders. The upper border is free. The anterior and posterior layers of peritoneum forming the ligament become continuous here. The lateral and inferior borders of the ligament are attached to the corresponding parts of the pelvic wall. The medial border is attached to the lateral margin of the uterus (see Fig. 18.21).

The ovary is attached to the posterior layer of the broad ligament through the *mesovarium* (Fig. 31.3). The ligament of the ovary passes from the lower pole of the ovary to the lateral angle of the uterus. The part of the broad ligament lying between the uterine tube and the ligament of ovary is called the *mesosalpinx*, while the part below the ligament of ovary is called the *mesometrium*. The part of the broad ligament that stretches from the upper pole of the ovary and the infundibulum of the uterine tube to the lateral pelvic wall is called the *suspensory ligament of the ovary* or the *infundibulopelvic ligament* (Fig. 31.5).

The broad ligament contains the following structures.

- 1 The uterine tube (Figs 31.5 and 31.11).
- 2 The round ligament of the uterus.
- 3 The ligament of the ovary.
- 4 Uterine vessels near its attachment to the uterus (Fig. 31.4).
- 5 Ovarian vessels in the infundibulopelvic ligament.
- 6 The uterovaginal and ovarian nerve plexuses.
- 7 Epoophoron (Fig. 31.5).
- 8 Paroophoron.
- 9 Some lymph nodes and lymph vessels.
- 10 Dense connective tissue or parametrium present on the sides of the uterus.

Fibromuscular Ligaments

The fibromuscular ligaments are:

- 1 Round ligaments of the uterus.
- 2 Transverse cervical ligaments
- 3 Uterosacral ligaments.

These are described separately under the heading of "supports" of uterus.

Arterial Supply

The uterus is supplied:

- 1 Chiefly by the two uterine arteries which are markedly enlarged during pregnancy.
- 2 Partly by the ovarian arteries.

The *uterine artery* is a branch of the anterior division of the internal iliac artery. It first runs medially towards the cervix, crossing the ureter above the lateral fornix of the vagina and 2 cm lateral to the cervix. Then the artery ascends along the side of the uterus, with a tortuous course. Finally, it runs laterally towards the hilus of the ovary, and ends by anastomosing with the ovarian artery. The tortuosity of the artery without stretching the artery permits expansion of the uterus during pregnancy (Fig. 31.12). Apart from the uterus, the artery also gives branches to without stretching the artery.

- a. Vagina.
- b. Medial two-thirds of the uterine tube.
- c. Ovary.
- d. Ureter.
- e. Structures present in the broad ligament (Fig. 31.5).

Venous Drainage

The veins form a plexus along the lateral border of the uterus. The plexus drains through the uterine, ovarian and vaginal veins into the internal iliac veins.

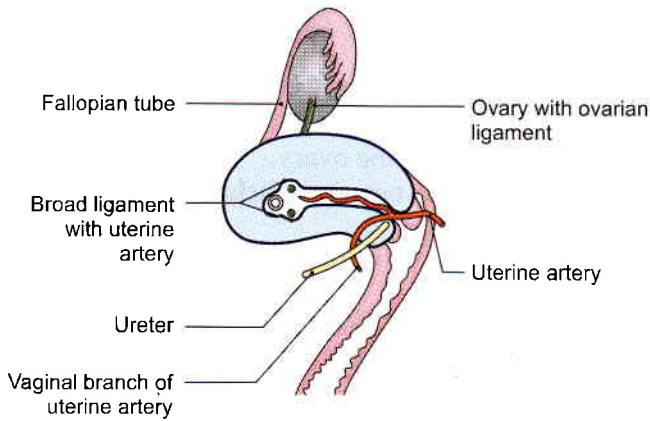


Fig. 31.12: Arterial supply of the uterus

Lymphatic Drainage

Lymphatics of the uterus begin at three intercommunicating networks, endometrial, myometrial and subperitoneal. These plexuses drain into lymphatics on the side of the uterus. Of these, the *upper lymphatics* from the fundus and upper part of the body drain mainly into the aortic nodes, and only partly to the superficial inguinal nodes along the round ligament of the uterus. The *lower lymphatics* from the cervix drain into the external iliac, internal iliac and sacral nodes. The *middle lymphatics* from the lower part of body drain into the external iliac nodes (Fig. 31.13).

Nerve Supply

The uterus is richly supplied by both sympathetic and parasympathetic nerves, through the inferior hypogastric and ovarian plexuses. Sympathetic nerves from T12, L1 segments of spinal cord produce uterine contraction and vasoconstriction. The parasympathetic nerves (S2, S3, S4) produce uterine inhibition and vasodilatation. However, these effects are complicated by the pronounced effects of hormones on the genital tract.

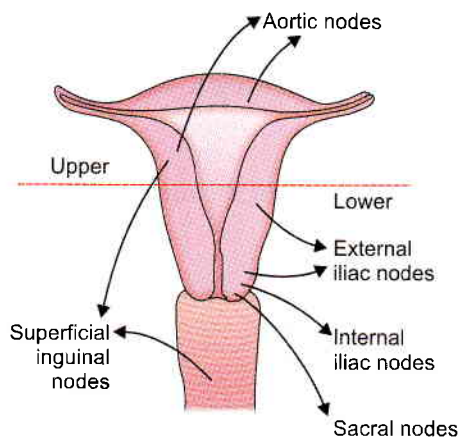


Fig. 31.13: Lymphatic drainage of uterus and vagina

Pain sensation from the body of the uterus pass along the sympathetic nerves, and from the cervix, along the parasympathetic nerves.

Age and Reproductive Changes

- 1 *In foetal life:* The cervix is larger than the body which projects a little above the pelvic brim.
- 2 *At puberty:* The uterus enlarges and descends to the adult position. The arbor vitae uteri also appear.
- 3 *During menstruation:* The uterus is slightly enlarged and becomes more vascular. The lips of the *external os* are swollen.
- 4 *During pregnancy:* The uterus is enormously enlarged, mainly due to hypertrophy of the smooth muscle fibres and partly due to hyperplasia. As pregnancy advances the uterine wall becomes progressively thinner. After parturition the uterus gradually involutes and returns almost to the nonpregnant size.
- 5 *In old age:* The uterus becomes atrophic and smaller in size and more dense in texture. The *internal os* is frequently obliterated. The lips of the *external os* disappear, and the *os* itself may be obliterated.

Supports of the Uterus

The uterus is a mobile organ which undergoes extensive changes in size and shape during the reproductive period of life. It is supported and prevented from sagging down by a number of factors which are chiefly muscular and fibromuscular.

Primary Supports

Muscular or active supports

- 1 Pelvic diaphragm.
- 2 Perineal body.
- 3 Distal urethral sphincter mechanism.

Fibromuscular or mechanical supports

- 1 Uterine axis.
- 2 Pubocervical ligaments.
- 3 Transverse cervical ligaments of Mackenrodt.
- 4 Uterosacral ligaments.
- 5 Round ligaments of uterus.

Secondary Supports

These are of doubtful value and are formed by peritoneal ligaments.

- 1 Broad ligaments (Fig. 31.5).
- 2 Vesicouterine pouch and fold of peritoneum.
- 3 Rectovaginal or rectouterine pouch and fold of peritoneum (see Fig. 18.17b).

Role of Individual Supports

Pelvic Diaphragm

The pelvic diaphragm (Fig. 31.14) supports the pelvic viscera and resists any rise in the intra-abdominal



pressure. The pubococcygeus part of the levator ani is partly inserted into the perineal body between the vagina and the rectum. Some of these fibres also form a supporting sling and a sphincter for the vagina, and so indirectly for the uterus and the urinary bladder. If the pubococcygeus is torn during parturition, the support to the vagina is lost, and the latter tends to sink into the vestibule along with the uterus, thus causing *prolapse* of the uterus. The efficacy of the levator ani as a support is also lost when the perineal muscles are torn. They normally fix the perineal body, and make it an anchor for the levator ani (Fig. 31.14).

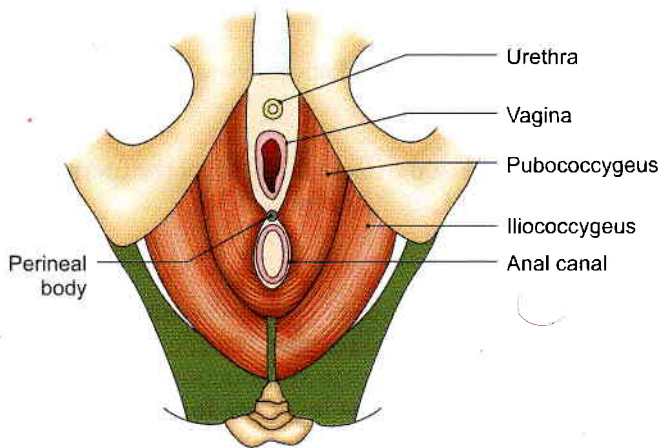


Fig. 31.14: Superior view of the pelvic diaphragm (the levator ani and coccygeus)

Perineal Body

It is a fibromuscular node to which ten muscles are attached. It acts as an anchor for the pelvic diaphragm, and thus maintains the integrity of the pelvic floor. The muscles are two superficial transversus perinei two deep transversus perinei, two pubococcygeus part of levator ani, two bulbospongiosus and single sphincter ani externus and unstriated fibres of longitudinal muscle coat of the anal canal (see Fig. 28.4).

Urethral Sphincter Mechanism

The urogenital diaphragm does not exist as sphincter urethrae is within the wall of the urethra. The urethral sphincter mechanism exists. In addition there is compressor urethrae and sphincter urethrae vaginalis. Since these are inserted into vagina, they support the uterus indirectly (see Fig. 28.20).

Uterine Axis

The anteverted position of the uterus itself prevents the organ from sagging down through the vagina. Any rise in intra-abdominal pressure tends to push the uterus against the bladder and pubic symphysis, which further accentuates anteversion. The angle of anteversion is

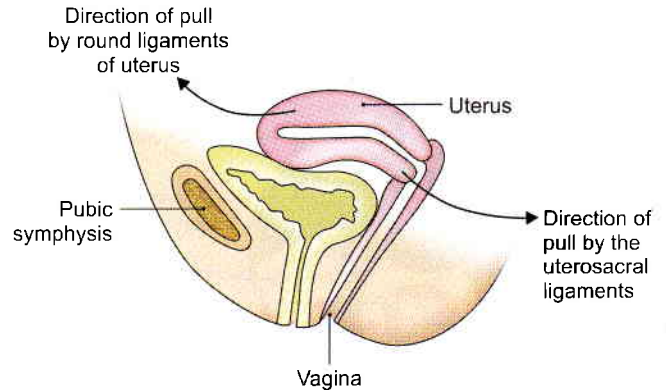


Fig. 31.15: Anteversion of the uterus is maintained by the couple of forces provided by the pull of the uterosacral ligament and the round ligament of the uterus

maintained by the uterosacral and round ligaments (Figs 31.9 and 31.15).

Pubocervical Ligaments

These ligaments connect the cervix to the posterior surface of pubis. They are derived from the endopelvic fascia, and correspond to the medial and lateral puboprostatic ligaments in the male (Fig. 31.16a).

Transverse Cervical Ligaments of Mackenrodt

These are also known by various other names like lateral cervical ligaments; cardinal ligaments; paracervical ligaments; retinacula uterine sustentaculum of Bonny (Figs 31.16b and 31.17).

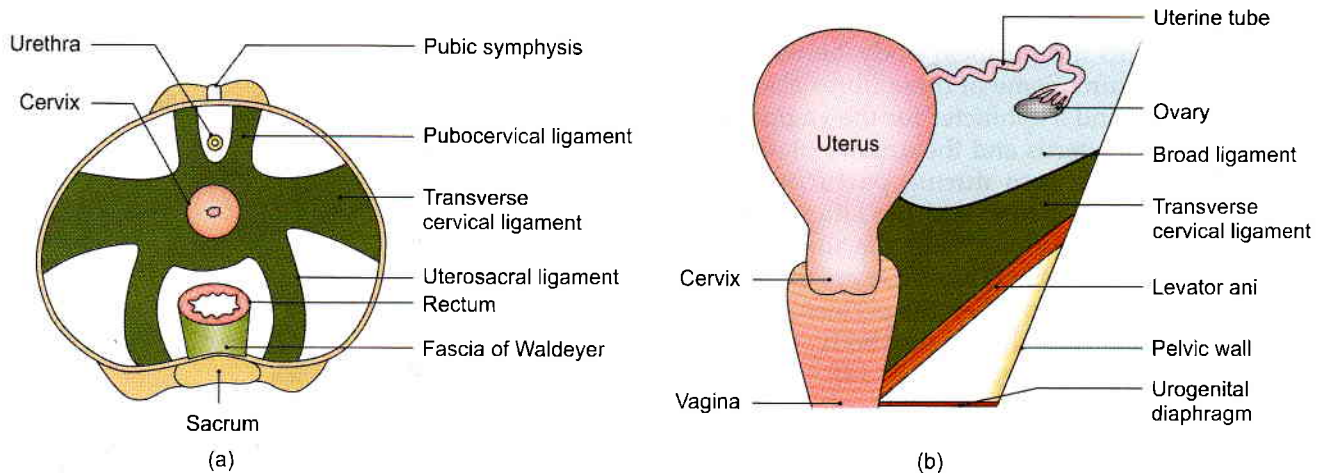
These are fan shaped condensations of the endopelvic fascia on each side of the cervix above the levator ani and around the uterine vessels. They connect the lateral aspects of the cervix and of the upper vaginal wall to the lateral pelvic wall, about 2.5 cm ventral to the ischial spine. They form a 'hammock' that supports the uterus.

Uterosacral Ligaments

These are also condensations of the endopelvic fascia. They connect the cervix to the periosteum of the sacrum (S2, S3) and are enclosed within rectouterine folds of peritoneum (which form the lateral boundaries of the rectouterine pouch). The *uterosacral ligaments* keep the cervix braced backwards against the forward pull of the round *ligaments*. The two ligaments form a couple that maintains the uterine axis (Figs 31.16a and 31.18).

Round Ligaments of Uterus

The round ligaments are two fibromuscular flat bands, 10 to 12 cm long, which lie between the two layers of the broad ligament, anteroinferior to the uterine tube. Each ligament begins at the lateral angle of the uterus, runs forwards and laterally, passes through the deep



Figs 31.16a and b: Condensation of pelvic fascia forming the supports of the pelvic organs. (a) Superior view of the ligamentous supports of the uterus and rectum, (b) coronal view of the right cardinal ligament

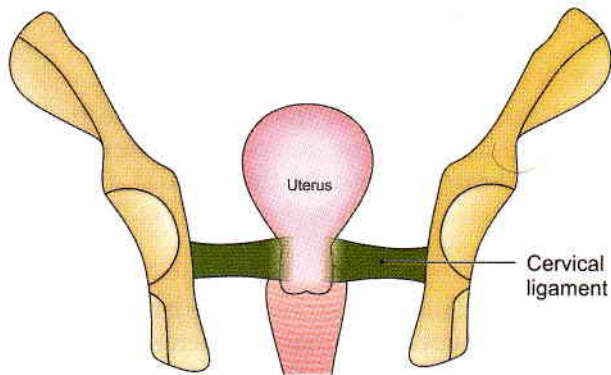


Fig. 31.17: Cervical ligaments supporting the uterus

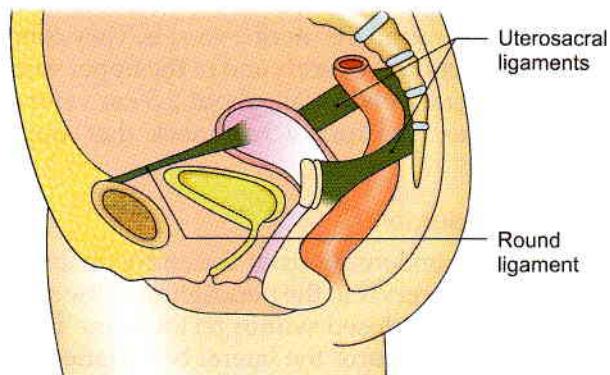


Fig. 31.18: Uterosacral and round ligaments supporting the uterus

inguinal ring, traverses the inguinal canal and merges with the areolar tissue of the labium majus after breaking up into thin filaments. In the inguinal canal, it is accompanied by a process of peritoneum during foetal life. If it persists after birth, it is known in females as the *canal of Nuck*. The round ligament keeps the fundus pulled forwards and maintains the angle of

anteversion against the backward pull of the uterosacral ligaments (Figs 31.10, 31.11 and 31.15).

HISTOLOGY

The mucous membrane is called the endometrium, which undergoes cyclic changes in three phases in one menstrual cycle. There is no submucous coat.

Myometrium is thickest layer made of an outer and an inner longitudinal coats and middle thick circular coat with lots of arterioles.

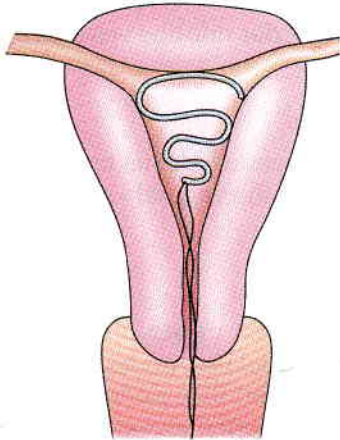
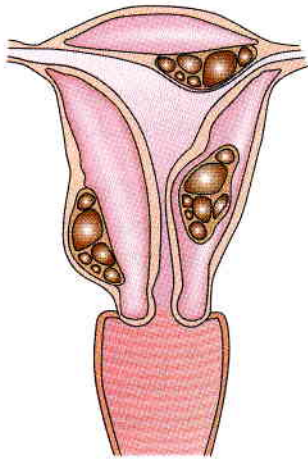
The serous lining of peritoneum forms the outer covering.

Following are the three phases of endometrium.

- 1 Proliferative phase:** The lining comprises simple columnar epithelium. Stroma contains simple tubular glands. Its deeper part contains sections of coiled arteries.
- 2 Progesterational phase:** The glands get sacculated and tortuous. The sections of coiled arteries are seen in the superficial part of thick endometrium.
- 3 Menstrual phase:** This phase occurs due to decline of both the hormones. The endometrium becomes ischaemic and starts being shed. The vessel wall gets necrosed and blood enters the stroma and menstrual flow starts.

CLINICAL ANATOMY

- **Colpotomy and colpoorrhaphy:** Posterior colpotomy is done to drain the pus from the pouch of Douglas.
- Intrauterine contraceptive device is used to prevent implantation of fertilised oocyte (Fig. 31.19).
- Uterus is common site of formation of fibroids (Fig. 31.20).
- Perineal body is one of the chief supports of pelvic organs. Damage to the perineal body often leads to prolapse of the uterus and of other pelvic organs.

**Fig. 31.19:** Intrauterine contraceptive device**Fig. 31.20:** Common sites of formation of fibroids

VAGINA

Synonym

Kolpos=Vagina (use of the terms colposcopy, colpotomy and colporrhaphy).

Definitions

The vagina is a fibromuscular canal, forming the female copulatory organ. The term 'vagina' means a sheath.

Extent and Situation

The vagina extends from the vulva to the uterus, and is situated behind the bladder and the urethra, and in front of the rectum and anal canal.

Direction

In the erect posture, the vagina is directed upwards and backwards. Long axis of uterus and cervix forms an angle of 90° with long axis of vagina (Figs 31.9b and 31.21).

Size and Shape

The anterior wall of the vagina is about 8 cm long and the posterior wall about 10 cm long.

The *diameter* of the vagina gradually increases from below upwards. The upper end or vault is roughly 5 cm twice the size of the lower end (2.5 cm). However, it is quite distensible and allows passage of the head of the foetus during delivery (Figs 31.5 and 31.10).

The *lumen* is circular at the upper end because of the protrusion of the cervix into it. Below the cervix, the anterior and posterior walls are in contact with each other, so that the lumen is a transverse slit in the middle part, and is H-shaped in the lower part.

In the virgin, the lower end of the vagina is partially closed by a thin annular fold of mucous membrane called the *hymen*. In married women the hymen is represented by rounded elevations around the vaginal orifice, the *caruncular hymenales*.

Fornices of Vagina

The interior of the upper end of the vagina or vaginal vault is in the form of a circular groove that surrounds the protruding cervix. The groove becomes progressively deeper from before backwards and is arbitrarily divided into four parts called the vaginal fornices. The *anterior fornix* lies in front of the cervix and is shallowest. The *posterior fornix* lies behind the cervix and is deepest. The *lateral fornices* lie one on each side of the cervix (Figs 31.5 and 31.9).

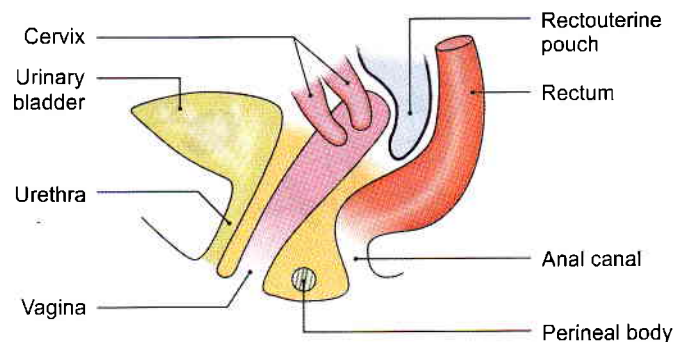
Relations

Anterior Wall

- 1 Upper half is related to the base of the bladder.
- 2 Lower half to the urethra (Fig. 31.21).

Posterior Wall

- 1 Upper one-fourth is separated from the rectum by the rectouterine pouch.
- 2 Middle two-fourths are separated from the rectum by loose connective tissue.
- 3 Lower one-fourth is separated from the anal canal by the perineal body and the muscles attached to it.

**Fig. 31.21:** Vagina and some related structures as seen in sagittal section



Lateral Walls

On each side:

- 1 Upper one-third is related to the transverse cervical ligament of pelvic fascia in which are embedded a network of vaginal veins, and the ureter gets crossed by the uterine artery (Fig. 31.22).
- 2 Middle one-third is related to the pubococcygeus part of the levator ani.
- 3 Lower one-third pierces the perineal membrane, below which it is related to the bulb of the vestibule, the bulbospongiosus and the duct of greater vestibular gland of Bartholin (see Figs 28.19, 31.22 and 31.23).

Arterial Supply

The vagina is a very vascular organ, and is supplied by the following arteries.

- 1 The main artery supplying it is the vaginal branch of the internal iliac artery.
- 2 In addition, the upper part is supplied by the cervicovaginal branch of the uterine artery (Fig. 31.23). The lower part is by the middle rectal and internal pudendal arteries.

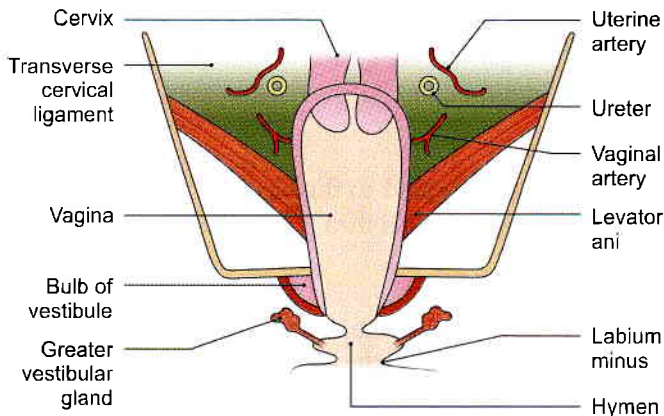


Fig. 31.22: Vagina and some related structures as seen in coronal section

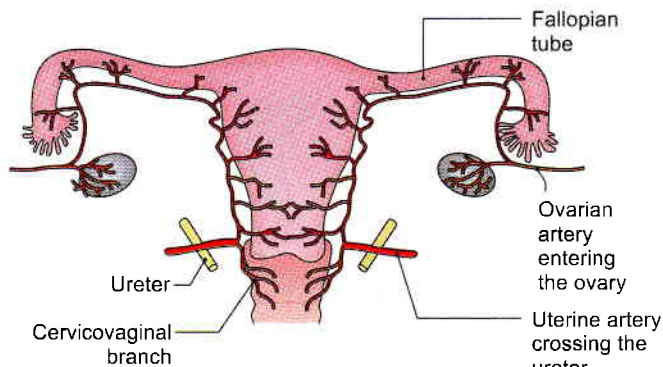


Fig. 31.23: Arterial supply of vagina and uterus by the uterine artery

Branches of these arteries anastomose to form anterior and posterior midline vessels called the *vaginal azygos arteries*.

Venous Drainage

The rich vaginal venous plexus drains into the internal iliac veins through the vaginal veins which accompany the vaginal arteries.

Lymphatic Drainage

Lymphatics from the upper one-third of the vagina drain into the external iliac nodes; from the middle one-third into the internal iliac nodes; and from the lower one-third into the medial group of superficial inguinal nodes.

Nerve Supply

- 1 The lower one-third of the vagina is pain sensitive and is supplied by the pudendal nerve through the inferior rectal and posterior labial branches of the perineal nerve.
- 2 The upper two-thirds of the vagina are pain insensitive and are supplied by sympathetic L1, L2 and parasympathetic segments S2 to S4. Nerves are derived from the inferior hypogastric and uterovaginal plexuses. Sympathetic nerves are vasoconstrictor and parasympathetic nerves vasodilator. The fibres which accompany the vaginal arteries form the vaginal nerves.

Ureter in Female Pelvis

As ureter lies anterior to internal iliac artery and immediately behind ovary it forms the posterior boundary of the ovarian fossa. It descends down till ischial spine. Then it courses anteromedially towards urinary bladder (Fig. 31.1).

In its anteromedial part, ureter is related to the uterine artery, cervix and vaginal fornices. Ureter lies in endopelvic fascia in inferomedial part of broad ligament of uterus, where it may be damaged (Figs 31.10, 31.12 and 31.23).

In the broad ligament, uterine artery is antero-superior to ureter by 2.5 cm and then crosses the ureter to ascend along lateral side of the uterus (Fig. 31.5).

Ureter runs forwards slightly above the lateral fornix of vagina and is 2 cm lateral to supravaginal part of cervix. It then turns medially towards urinary bladder and is apposed to vagina.

Left ureter is often more close to vagina, as uterus is slightly on the right side and vagina is on the left side of median plane.

One has to be careful of ureter, especially during ligation of the uterine artery. Ureter exhibits peristaltic movements and can be identified easily.



HISTOLOGY

- 1 Mucous membrane is lined by nonkeratinised stratified squamous epithelium.
- 2 Lamina propria is made up of loose connective tissue.
- 3 Muscle coat consists of an outer longitudinal and an inner circular layer.
- 4 The outer fibrous coat is the usual connective tissue.

There are no glands in the vaginal mucosa. It is kept moist by the cervical glands from above and the greater vestibular glands from below. The vaginal fluid is acidic in nature because of the fermentation of glycogen (in vaginal cells) by the Doderlein's bacilli.

CLINICAL ANATOMY

- *Vaginal Examination*
 - a. *Inspection:* Vagina is first inspected at the introitus by separating the labia minora with the left hand. Next the speculum examination is done to inspect the cervix and vaginal vault, and to take the vaginal swab.
 - b. *Palpation* of the pelvic organs can be done by a per vaginal (PV) digital examination (Fig. 31.24). With the examining fingers one can feel:
 - *Anteriorly*, the urethra, bladder and pubic symphysis;
 - *Posteriorly*, the rectum and pouch of Douglas;
 - *Laterally*, the ovary, tube, lateral pelvic wall, thickened ligaments, and ureters; and
 - *Superiorly*, the cervix.

Bimanual (abdominovaginal) examination helps in the assessment of the size and position of the uterus, enlargements of the ovaries and tubes, and the other pelvic masses.

- *Vaginal lacerations:* Traumatic lacerations of vagina are common, and may be caused by forcible coitus (rape), during childbirth, or by accidents. This may give rise to profuse bleeding.
- Hymen is examined in medicolegal cases to confirm virginity.
- *Vaginitis:* It is common before puberty and after menopause because of the thin delicate epithelium. In adults, the resistant squamous epithelium prevents the infection. Vaginitis is commonly caused by the trichomonas, monilial and gonococcal infections. It causes leucorrhoea or white discharge.
- *Prolapse:* Prolapse of the anterior wall of vagina drags the bladder (cystocoele) and urethra (urethrocoele); the posterior wall drags the rectum (rectocoele).

Weakness of supports of uterus can give rise to different degrees of prolapse.

Similarly, trauma to the anterior and posterior walls of vagina can cause the vesicovaginal, urethrovaginal and rectovaginal fistulae.

- *Neoplasms:* Primary new growths of vagina, like the infections, are uncommon. However, secondary involvement of vagina by the cancer cervix is very common.
- Episiotomy is an incision given in posterolateral side of vagina to increase the size of outlet for the baby during delivery. The position of episiotomy incision during 2nd stage of labor is shown (see Fig. 29.9). Some muscles of superficial perineal space are incised.

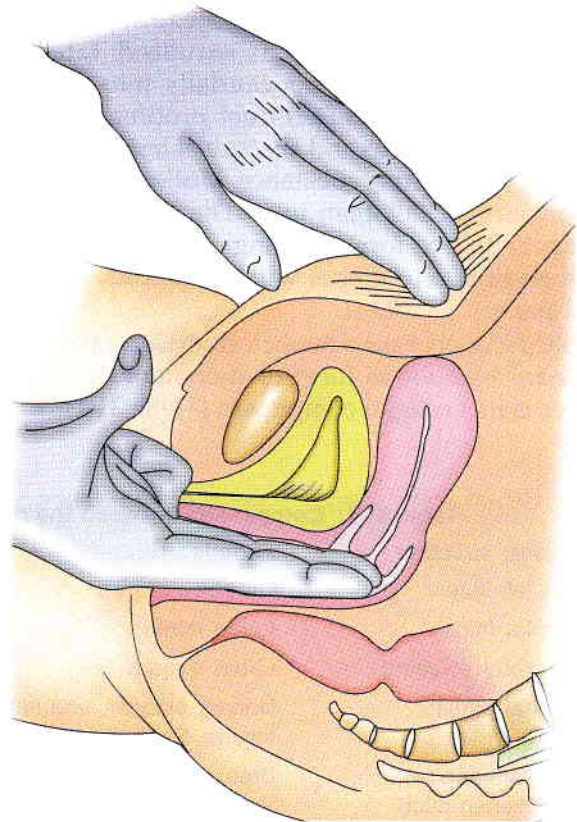


Fig. 31.24: Bimanual examination of the female internal genital organs

DEVELOPMENT

Female reproductive system comprises two ovaries and

- 1 Genital ducts
- 2 External genitalia

Ovary

Sex of the embryo is determined at the time of fertilization.



The chromosomal complement in female is 'XX'. Various components of ovary are germ cells, follicular cells and the stromal cells.

Germ cells get migrated from the dorsocaudal end of the yolk sac. Follicular cells are derived from the epithelial cells of the coelomic epithelium, while stromal cells are derived from mesoderm.

There is no tunica albuginea in the ovary and the *cortical part* of the gonad predominates.

Ovary descends down till the pelvis. Its descent is interrupted due to the presence of the single uterus, which divides the gubernaculum into ligament of ovary and round ligament of uterus.

Ducts

In female, müllerian or paramesonephric duct predominates. This duct is situated lateral to mesonephric duct. It opens caudally into definitive urogenital sinus. Müllerian duct proliferates due to presence of oestrogens and absence of testosterone and of müllerian inhibiting substance. Müllerian duct forms all four parts of fallopian tube. The distal part of the two ducts fuse to form the single uterovaginal canal which gives rise to uterus with its fundus, body and cervix parts.

Wolffian duct or mesonephric duct forms the trigone of urinary bladder as functional component. Duct of Gartner is its vestigial component (Table 31.1).

Mesonephric Tubules

These only form vestigial elements in female. These are epoophoron, paroophoron and aberrant ductules.

Epoophoron

It consists of 10 to 15 parallel tubules situated in the lateral part of the mesosalpinx between the ovary and the uterine tube. The tubules end in a longitudinal duct. These tubules represent cranial mesonephric tubules while the duct is a remnant of the mesonephric duct (Fig. 31.5).

Paroophoron

It consists of a few very short rudimentary tubules situated in the broad ligament between the ovary and uterus. These represent caudal mesonephric tubules which are not attached to the mesonephric duct.

Duct of Gartner

Occasionally, the duct of the epoophoron is much larger than usual and is called the *duct of Gartner*. It can be traced first along the uterine tube, and then along the lateral margin of the uterus up to the level of the *internal os*. Further down it runs through the cervix and the lateral wall of the vagina, and ends near the free margin of the hymen. It represents the mesonephric duct. It may form a cyst in the anterior or lateral wall of the vagina.

Table 31.1: Comparison between the derivatives of female and male urogenital structures

Embryonic structure	Female	Male
Genital tubercle	Clitoris	Penis
Urogenital folds	Labia minora	Ventral aspect of penis
Labioscrotal swelling	Labia majora	Scrotum
Urogenital sinus	Urinary bladder, urethral glands vagina, Bartholin's glands	Urinary bladder urethra its glands and prostate Bulbourethral glands
Paramesonephric duct (müllerian duct)	Uterus, cervix, fallopian tubes, upper part of vagina	Appendix of testis
Mesonephric duct (Wolffian duct)	Duct of Gartner Duct of epoophoron Trigone of urinary bladder	Epididymis, vas deferens Seminal vesicle Trigone of urinary bladder
Mesonephric tubules	Epoophoron Paroophoron	Efferent ductules Paradidymis
Gonad	Ovary secretes oestrogen and progesterone hormones Ovary is a pelvic organ	Testis secretes testosterone hormone Testis descends outside the abdominal cavity as spermatogenesis requires 3 degree lower temperature
Gubernaculum	Ligament of ovary Round ligament of uterus	Gubernaculum Testis
Müllerian tubercle	Hymen	Seminal colliculus



Vesicular Appendix

Occasionally, one or two pedunculated cysts are found attached to the fimbriated end of the uterine tube. These are called the *vesicular appendices* or *paramesonephric appendices*. These are believed to develop from the cranial end of the paramesonephric duct.

VAGINA

As the fused müllerian or paramesonephric ducts which form the uterovaginal canal open into the definitive urogenital sinus, the endoderm bulges to form the müllerian tubercle. Uterovaginal canal forms upper 1/3rd of vagina.

Endoderm on either side of müllerian tubercle proliferates to form two sinovaginal bulbs which fuse to form vaginal plate. The vaginal plate surrounds the caudal end of the uterovaginal canal.

Soon there is canalisation of the vaginal plate to form lower 2/3rd of vagina and vaginal fornices. It opens through an endodermal partial septum—the hymen in the definitive urogenital sinus.

EXTERNAL GENITALIA

Mesenchymal cells migrate around cloacal membrane to form cloacal folds. These folds fuse ventrally to form genital tubercle.

Cloacal folds get divided into urethral folds anteriorly and anal folds posteriorly. This occurs at the same time that the cloacal membrane gets divided into urogenital membrane and anal membrane.

Lateral to urethral folds another pair of folds, the genital swellings, make their appearance.

Genital tubercle forms clitoris; urethral folds form labia minora, genital swellings form labia majora, urogenital membrane gets ruptured to form the vestibule.

Mnemonics

Female pelvic organs “3 organs, each gets 2 blood supplies”

Vagina: Uterine, vaginal

Rectum: Middle rectal, inferior rectal (inferior rectal is the branch of pudendal)

Bladder in female: Superior vesical, vaginal



FACTS TO REMEMBER

- Cervix is the least movable part of uterus.
- Main ligamentous support of uterus is the transverse cervical ligament.

- Site of implantation of the blastocyst is posterior wall of fundus of uterus, close to its body.
- Uterine artery crosses ureter from lateral to medial side anteriorly to run tortuously along lateral surface of uterus.
- The epithelium of uterus is simple columnar type. The glands are simple, tubular. The submucous layer is absent. Tall columnar cells line the cervical canal.
- The cortex of the ovary is full of follicles. The medulla contains hilus cells, homologous to the interstitial cells of the testis.
- Pelvic part of the ureter about 13 cm long, lies close to the supravaginal part of the cervix. It is narrow at (i) where ureter crosses the brim of pelvis, (ii) where it is crossed by the uterine artery and (iii) in the intravesical part.
- Broad ligament has four parts: (i) infundibulopelvic ligament, (ii) mesovarium, (iii) mesosalpinx and (iv) mesometrium.
- Round ligament is 10–12 cm long with one end attached to uterine cornua and other to anterior third of labia majora.
- Before PV examination, the urinary bladder must be emptied.
- Forced penetration of penis into vagina is known as “rape”. It is a punishable crime.
- Caesarean section is the delivery of the baby by cutting open the anterior abdominal wall and the uterus.

CLINICOANATOMICAL PROBLEM

Due to repeated child births, a female felt something out at the perineum, especially while standing.

- What organ descends down?
- Name the supports of the organ?

Ans: The organ which descends down is the uterus. It occurs due to repeated childbirths. Normally the organ is supported by number of muscles and ligaments. These may get weakened and stretched and thus are unable to support uterus. So uterus descends down through vagina. Its supports are:

Muscular: All parts of levator ani, perineal body with its attached muscles and distal urethral sphincter mechanism.

Ligaments: Transverse cervical ligament, uterosacral ligament, these are true supports

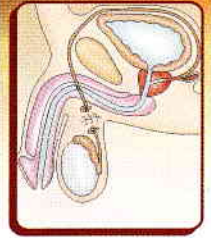


MULTIPLE CHOICE QUESTIONS

1. Normal position of uterus is:
 - a. Anteverted and anteflexed
 - b. Retroverted and retroflexed
 - c. Anteverted and retroflexed
 - d. Retroverted and anteflexed
2. Cervix is supplied by which of the following nerves?
 - a. Pudendal
 - b. Pelvic splanchnic nerve
 - c. Sacral
 - d. Lumbar 5, Sacral 1
3. Which of the following is not a content of broad ligament?
 - a. Cervix
 - b. Uterine tube
 - c. Ligament of the ovary
 - d. Round ligament
4. Uterine artery is a branch of which artery?
 - a. External iliac
 - b. Internal iliac
 - c. Abdominal aorta
 - d. Common iliac
5. Following are the muscular supports of uterus *except*:
 - a. Pelvic diaphragm
 - b. Perineal body
 - c. Proximal urethral sphincter mechanism
 - d. Distal urethral sphincter mechanism

ANSWERS

1. a 2. b 3. a 4. b 5. c



Male Reproductive Organs

There is no medicine like hope, no incentive so great, and no tonic so powerful as expectation of something tomorrow

—O S Mardern

INTRODUCTION

The male reproductive organs include the external and internal genitalia. The external genitalia are the penis and the scrotum containing testis, epididymis and part of ductus deferens. The internal genitalia on each side are, the part of ductus deferens, the seminal vesicle, the ejaculatory ducts, and the prostate.

The external genitalia have been described in Chapter 17, and the male urethra in Chapter 30. The remaining structures are considered below.

MALE REPRODUCTIVE ORGANS

DISSECTION

The ductus deferens has been seen till the deep inguinal ring in the anterior abdominal wall. Follow it from there as it hooks round the lateral side of inferior epigastric artery to pass backwards and medially across the external iliac vessels to enter into the lesser pelvis. There it crosses the ureter and lies on the posterior surface of urinary bladder medial to the seminal vesicle (Fig. 32.2). Separate the ductus from the adjacent seminal vesicle and trace these till the base of the prostate gland (*refer to 3*).

Follow the deep dorsal vein of the penis and its two divisions into the prostatic venous plexus situated in the angle between the bladder and the prostate.

Feel the thickened puboprostatic ligaments. Feel the firm prostate lying just at the neck of the urinary bladder.

Identify the levator prostatae muscle lying inferolateral to the prostate. This is identifiable by pulling both the bladder and prostate medially. The first part of urethra traverses the prostate. Cut through the anterior one-third of the gland to expose the prostatic urethra.

DUCTUS DEFERENS

Synonyms

The *ductus deferens* is also called the *vas deferens* or the *deferent duct*.

Definition

The ductus deferens is a thick-walled, muscular tube which transmits spermatozoa from the epididymis to the ejaculatory duct (Fig. 32.1). It feels cord-like at the upper lateral part of scrotum. Ductus deferens has a narrow lumen except at the terminal dilated part called the ampulla (Fig. 32.2).

Length

The ductus deferens is about 45 cm long when straightened.

Location and Course

In its course, the vas lies successively:

- 1 Within the scrotum along the posterior border of the testis.
- 2 In the inguinal canal as part of the spermatic cord (Fig. 32.1).
- 3 In the greater pelvis.
- 4 In the lesser pelvis.

Course and Relations

- 1 The ductus deferens begins as a continuation of the tail of the epididymis (Fig. 32.1).
- 2 *Along the posterior border of the testis:* At first it is very tortuous, but gradually straightens as it ascends along the posterior border of the testis, medial to the epididymis.
- 3 *In the spermatic cord:* The ductus deferens lies vertically in posterior part of spermatic cord. It runs upwards to the superficial inguinal ring, and then traverses the

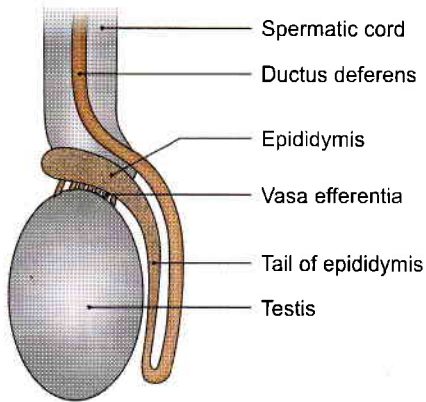


Fig. 32.1: Schematic diagram to show the relationship of the ductus deferens to the testis and the spermatic cord

inguinal canal. In the vertical part of its course, it can be felt as a cord-like structure within the spermatic cord.

- 4 *In the greater pelvis:* At the deep inguinal ring it leaves the spermatic cord, and hooks round the lateral side of the inferior epigastric artery. It then passes backwards and medially, across the external iliac vessels, and enters the lesser pelvis (Fig. 32.2).
- 5 *In the lesser pelvis:* The ductus deferens runs downwards and backwards on the lateral pelvic wall, deep to the peritoneum. Here it crosses the obliterated umbilical artery, the obturator nerve and vessels, and the vesical vessels. It then crosses the ureter, and bends medially at right angles, to enter the sacrogenital fold of peritoneum. Reaching the base of the urinary bladder the ductus runs downwards and forwards medial to the seminal vesicle. Here it approaches the opposite duct and reaches the base of the prostate (Fig. 32.3).

At the base of the prostate, the ductus deferens is joined at an acute angle by the duct of the seminal vesicle to form the ejaculatory duct.

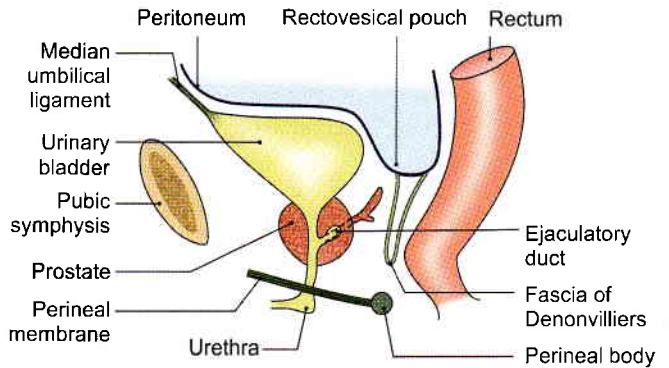


Fig. 32.3: Prostate gland and some related structures as seen in sagittal section

The part of the ductus lying behind the base of the bladder, is dilated and tortuous, and is known as the ampulla (*see* Fig. 30.3).

Arterial Supply

The artery to the ductus deferens arises from one of the terminal branches of the superior vesical artery. It accompanies the ductus to testis, where it anastomoses with the testicular artery.

Venous Drainage

Veins from the ductus join the vesical venous plexus which opens into the internal iliac vein.

HISTOLOGY

The lining epithelium of vas deferens is of pseudo-stratified ciliated type. The underlying lamina propria contains elastic fibres. The muscle coat is in three layers, middle is circular and outer and inner layers are of longitudinal type. Adventitia is made of thin connective tissue layer with fine nerves and arterioles.

DEVELOPMENT

Ductus deferens develops from the mesonephric duct.

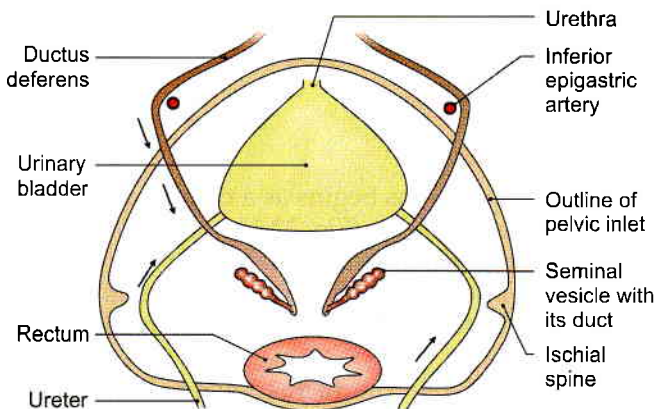


Fig. 32.2: Schematic diagram to show the course of the ductus deferens

CLINICAL ANATOMY

- *Vasectomy* or removing part of the vas deferens is one of the commonest operations being done for purposes of family planning. It is a minor operation which is done under local anaesthesia. A median incision is made in the upper part of the scrotum, just below the penis. Through this incision both the deferent ducts are operated. A short segment of each duct is excised, and the cut ends are ligated. The operation is reversible, and recanalisation can be done if required (Fig. 32.4).
- After vasectomy, the testes continue to produce the hormones normally to maintain the male



characteristics. The hormones pass out through the veins. Sperms are present in the ejaculations after vasectomy for 2–3 months as it is an emptying process. Newly formed sperms are destroyed in the epididymis and are removed by phagocytosis.

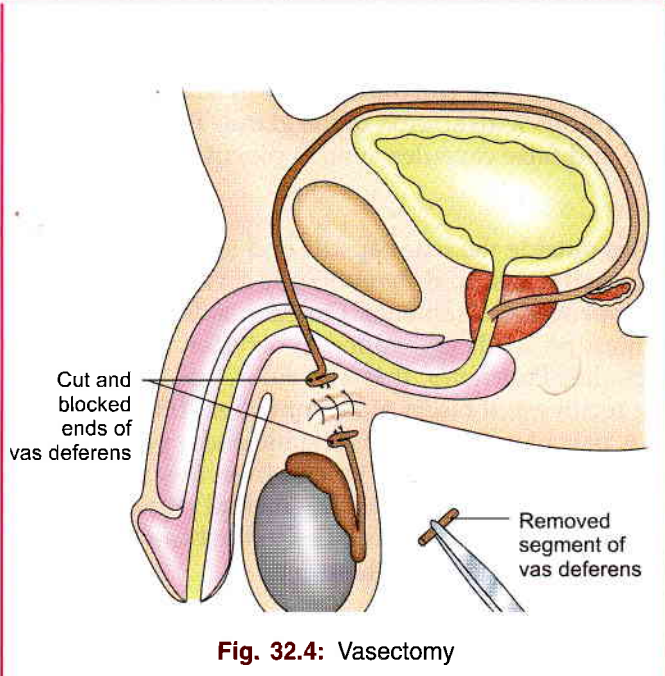


Fig. 32.4: Vasectomy

SEMINAL VESICLES

These are two lobulated sacs, situated between the bladder and rectum. Each vesicle is about 5 cm long, and is directed upwards and laterally. The lower narrow end forms the duct of the seminal vesicle which joins the ductus deferens to form the ejaculatory duct (see Fig. 30.3).

The seminal vesicles do not form a reservoir for spermatozoa. Their secretion forms a large part of the seminal fluid. The secretion is slightly alkaline and contains fructose and a coagulating enzyme called the vesiculase.

PROSTATE

The prostate is an accessory gland of the male reproductive system. The secretions of this gland add bulk to the seminal fluid along with those of the seminal vesicles and the bulbourethral glands. The prostate is firm in consistency. Its firmness is due to the presence of a dense fibromuscular stroma in which the glandular elements are embedded. In the female the prostate is represented by the paraurethral glands of Skene.

Situation

The prostate lies in the lesser pelvis, below the neck of the urinary bladder, behind the lower part of the pubic

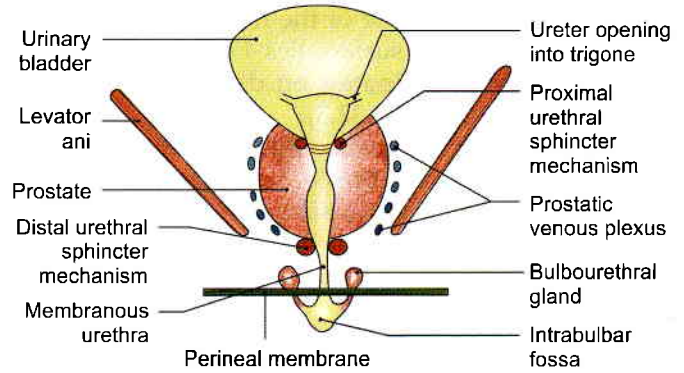


Fig. 32.5: Prostate and some related structures as seen in a coronal section

symphysis and the upper part of the pubic arch. It lies in front of the ampulla of the rectum (Figs 32.3 and 32.5).

Shape, Size and Weight

It resembles an inverted cone, measuring about 4 cm transversely at the base, i.e. width; 3 cm vertically, i.e. length; and 2 cm anteroposteriorly or thickness. It weighs about 8 g.

Gross Feature

The prostate presents an apex directed downwards; a base; four surfaces: anterior, posterior and two inferolateral.

Apex

The *apex* is directed downwards surrounds the junction of prostatic and membranous parts of posterior urethra. It is separated from the anal canal by the perineal body (Fig. 32.3).

Base

The *base* is directed upwards, and is structurally continuous with the neck of the bladder. The junction is marked by a circular groove which lodges venules of the vesical and prostatic plexuses.

Surfaces

The *anterior surface* is narrow and convex from side to side. It lies 2 cm behind the pubic symphysis, with retropubic fat intervening. Its upper part is connected to the pubic bones by the puboprostatic ligaments. The lower end of this surface is pierced by the urethra. The lower end of urethra emerges from this surface anterosuperior to the apex of gland. This surface is composed of fibrous tissue.

The *posterior surface* is triangular in shape. It is flattened from side to side and convex from above downwards. It is separated from the rectum by the fascia of Denonvilliers which is the obliterated rectovesical pouch of peritoneum. Near its upper border



it is pierced on each side of the median plane by the ejaculatory duct. This surface lies 4 cm from the anus, and can be easily palpated on digital examination through the rectum (Fig. 32.3).

The *inferolateral surfaces* are related to the side walls of pelvis. The anterior fibres of the levator ani enclose the gland in pubourethral sling. They are separated from the muscle by a plexus of veins embedded in its sheath (Fig. 32.5).

Zones of the Prostate

According to McNeal, the gland is divided into:

- 1 The peripheral zone forms 70% of glandular tissue. It is situated posteriorly and is cancer vulnerable (Fig. 32.6).
- 2 Central zone constitutes 25% of glandular tissue situated posterior to urethral lumen and above the ejaculatory ducts. The two zones are like an egg in its egg-cup. The central zone is not involved in disease and is of Wolfian duct origin.
- 3 There is a periurethral transition zone (5%) from which benign prostatic hyperplasia arises. The central zone and transition zone constitute "central gland".

Sphincters Related to Prostate

In the preprostatic part of urethra there is proximal urethral sphincter mechanism that subserves sexual function of closing during ejaculation. If this sphincter gets resected, retrograde ejaculation occurs (Fig. 32.7).

Distal urethral sphincter mechanism is seen at the junction of prostatic and membranous parts of urethra. It is horseshoe shaped, with most of the bulk lying anteriorly. It is distinct from muscle of pelvic floor.

Lobes

The prostate gland was described as having five lobes initially. These were one anterior, one posterior, one

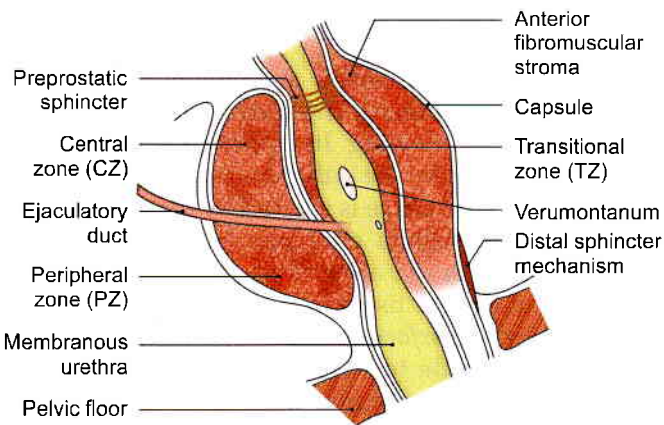


Fig. 32.6: Different zones of the prostate gland

median and two lateral. These were one anterior, one posterior, one median and two lateral. As of now, the glandular tissue is divided into three lobes, two lateral and one median (Figs 32.7a to c).

Capsules and Ligaments of Prostate

True capsule

It is formed by condensation of the peripheral part of the gland. It is fibromuscular in structure and is continuous with stroma of the gland. The lies between true and false capsules venous plexus (Fig. 32.8).

False Capsule

It lies outside the true capsule and is derived from the endopelvic fascia. *Anteriorly*, it is continuous with the puboprostatic ligaments. On each side, the prostatic venous plexus is embedded in between false and true capsules. *Posteriorly*, it is avascular, and is formed by the rectovesical fascia of Denonvilliers (Fig. 32.3).

A pair of medial puboprostatic and a pair of lateral puboprostatic ligaments extend from the false capsule to the back of pubic bone. The medial pair lie near the apex while lateral pair is close to the base. These four ligaments support the gland.

Structures within the Prostate

- 1 Prostatic urethra traverses the gland vertically at the junction of its anterior one-third with the posterior two-thirds (Figs 32.7a and b).
- 2 The prostatic utricle is a blind sac directed upwards and backwards. It opens at the middle of the urethral crest.
- 3 The ejaculatory ducts pass downwards and forwards, and open into the prostatic urethra on each side of the opening of the prostatic utricle (Figs 32.7a to c).

Structural Zones of the Prostate

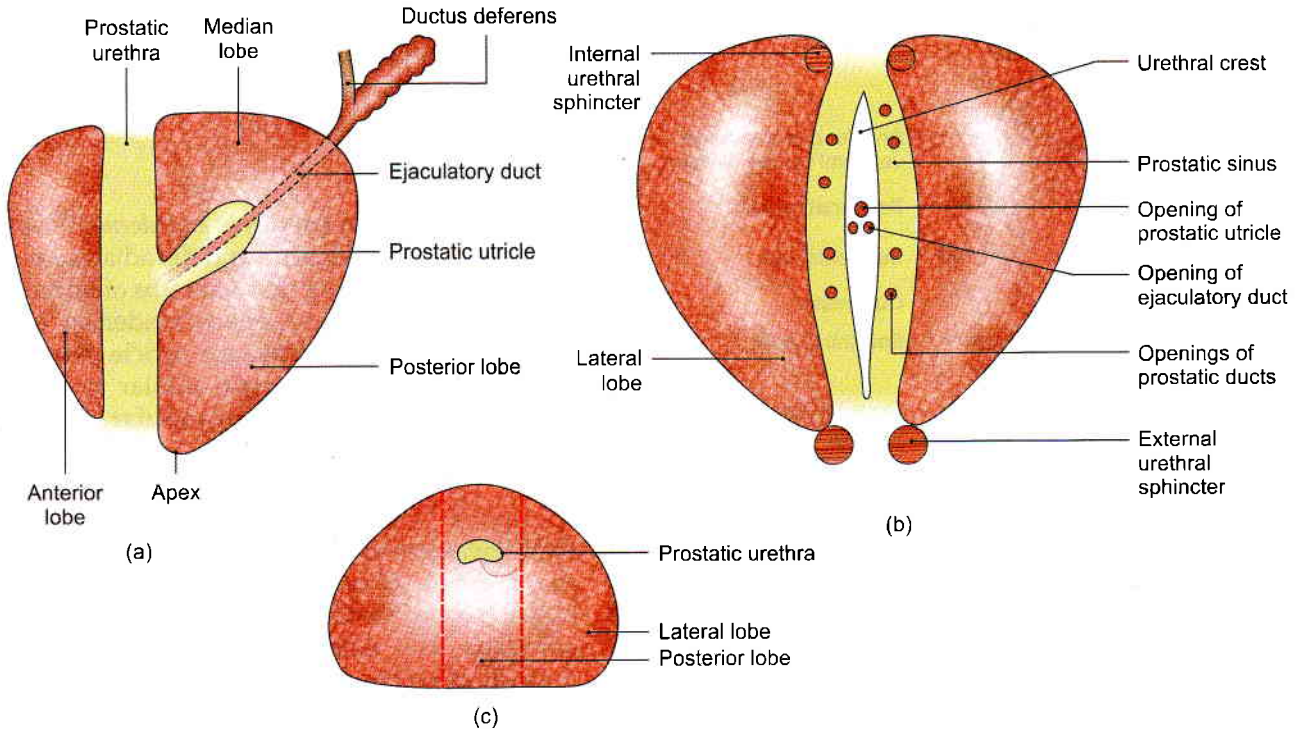
Histological sections of the prostate do not show the lobar pattern of the organ. Instead there are two well-defined concentric zones separated by an ill-defined irregular capsule. The zones are absent anteriorly (Fig. 32.9).

The *outer larger zone* is composed of large branched glands, the ducts of which curve backwards and open mainly into the prostatic sinuses. This zone is frequently the site of carcinoma.

The *inner smaller zone* is composed of submucosal glands opening in the prostatic sinuses, and a group of short, simple mucosal glands surrounding the upper part of the urethra. These zones are typically prone to *benign hypertrophy*.

Blood Supply

The prostate is supplied by branches from the inferior vesical, middle rectal and internal pudendal arteries.



Figs 32.7a to c: Lobes of the prostate gland as seen in sections through different planes. (a) Left view of a sagittal section, (b) posterior half of a coronal section, and (c) horizontal section. The prostatic utricle, ejaculatory duct and the prostatic urethra are also seen

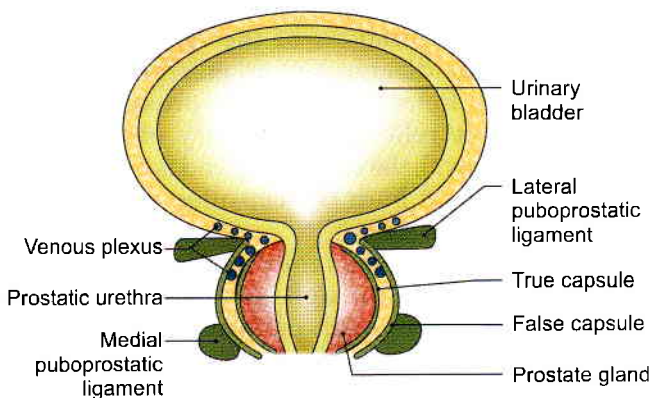


Fig. 32.8: Ligaments and venous plexus of prostate gland

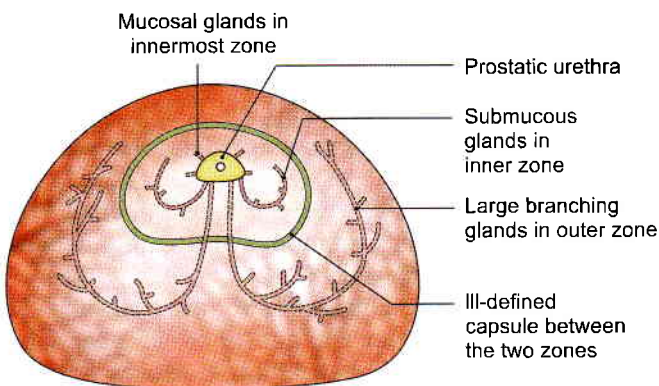


Fig. 32.9: Horizontal section through the prostate gland showing the histological zones and the glands in them

Branches of these arteries form a large outer or subcapsular plexus, and a small inner or periurethral plexus. The greater part of the gland is supplied by the subcapsular plexus.

The *veins* form a rich plexus around the sides and base of the gland. The plexus communicates with the vesical plexus and with the internal pudendal vein, and drains into the vesical and internal iliac veins. Valveless communications exist between the prostatic and vertebral venous plexuses through which prostatic carcinoma can spread to the vertebral column and to the skull (Fig. 32.10).

Lymphatic Drainage

Lymphatics from the prostate drain chiefly into the internal iliac and sacral nodes; and partly into the external iliac nodes.

Nerve Supply

The prostatic plexus of nerves is derived from the lower part of the inferior hypogastric plexus. It contains thick nerves and numerous large ganglia. In addition to the prostate and structures within it, the plexus also supplies the seminal vesicles, the corpora cavernosa, the corpus spongiosum, the membranous and penile parts of the urethra, and the bulbourethral glands.

The prostate is supplied by both sympathetic and parasympathetic nerves. The gland contains numerous end-organs, impulses from which are relayed to the

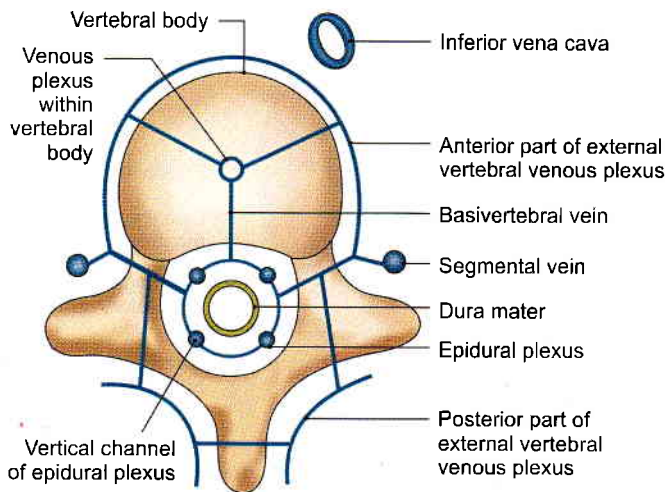


Fig. 32.10: The vertebral system of veins

lower three lumbar and upper sacral segments. Secretions of the prostate are produced and discharged after stimulation of both the parasympathetic and sympathetic nerves.

Age Changes in Prostate

- 1 *At birth* the prostate is small in size, and is made up mainly of stroma in which a simple duct system is embedded. During the first 6 weeks after birth the epithelium of the ducts and of the prostatic utricle undergoes hyperplasia and squamous metaplasia, under the stimulation of maternal oestrogens. Thereafter, up to the age of 9 years changes are negligible. Between 9 and 14 years, the duct system becomes more elaborate by formation of side buds, and the gland slowly increases in size.
- 2 *At puberty* the male hormones bring about rapid changes in the gland. In about one year it becomes double its prepubertal size due to rapid growth of the follicles and condensation and reduction of the stroma.
- 3 *From 20 to 30 years* there occurs marked proliferation of the glandular elements with infolding of the glandular epithelium into the lumen of the follicles, making them irregular.
- 4 *From 30 to 45 years* the size of the prostate remains constant, and involution starts. The epithelial infoldings gradually disappear and amyloid bodies increase in number.
- 5 *After 45 to 50 years* the prostate is either enlarged called the benign hypertrophy or reduced in size called the senile atrophy.

HISTOLOGY

Prostate is a fibromuscular glandular organ. The stroma comprises collagen fibres and smooth fibres. The

columnar epithelium of acini is folded. The lumen may contain small colloid masses called amyloid bodies. The prostatic urethra, lined by transitional epithelium may also be seen.

DEVELOPMENT

Prostate develops from a series of *endodermal buds* from the lining of primitive urethra and the adjacent portion of urogenital sinus, during first 3 months of intrauterine life. The surrounding *mesenchyme* condenses to form the stroma of the gland. Prostatic utricle develops in the region of müllerian tubercle similar to vagina in females. The central zone of glandular tissue is of wolffian duct system.

CLINICAL ANATOMY

- *Senile enlargement of prostate:* After 50 years of age the prostate is often enlarged due to benign hypertrophy or due to the formation of an adenoma. This causes retention of urine due to distortion of the urethra. Enlargement of the median lobe not only projects into bladder, but forms a sort of valve over the internal urethral orifice, so that more patient strains, more it obstructs the passage. Urine passes when the patient relaxes.

Digital examination of the rectum is very helpful in the diagnosis of an enlarged prostate (Fig. 32.11). Removal of such a prostate called *prostatectomy* relieves the urinary obstruction. During removal, the enlarged gland is enucleated, leaving behind both the capsules and venous plexus between them.

The prostate can be removed through bladder (transvesical), through prostatic capsule (retropubic), or through perineum and fascia of Denonvilliers (perineal approach) or through urethra (TUR: transurethral resection).

- Inflammation of the prostate is referred to as *prostatitis*. It may be acute or chronic. Acute prostatitis is secondary to gonococcal urethritis and chronic prostatitis may be secondary to tuberculous infection of epididymis, seminal vesicles and the bladder.
- Different zones of the prostate gland are seen in Fig. 32.6.
- Benign prostatic hyperplasia occurs in periurethral zone. Carcinoma of prostate occurs in peripheral zone (Fig. 32.12).
- The prostate is a common site of carcinoma. It usually occurs after the age of 50–55 years. In addition to urinary obstruction, it causes pain in perineum, low backache or sciatica. Rectal examination reveals an irregular hard and fixed



prostate. Metastatic spread occurs to the vertebral column through the valveless connections between the prostatic and vertebral venous plexuses (Fig. 32.10).

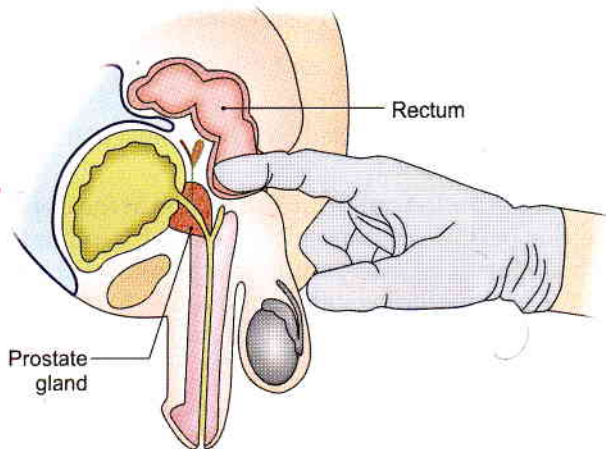


Fig. 32.11: Per rectal (PR) examination for prostate gland

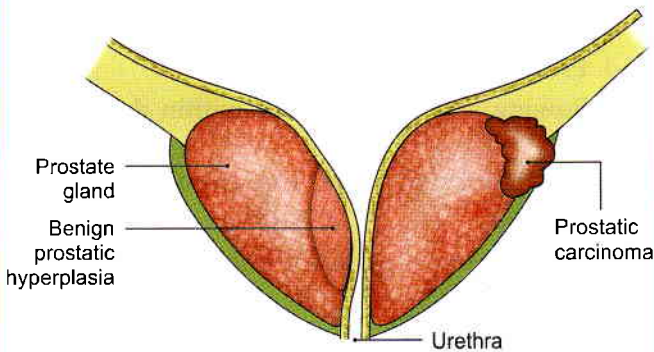


Fig. 32.12: Benign prostatic hyperplasia and prostatic carcinoma

VERTEBRAL SYSTEM OF VEINS

Synonym

Batson's plexus (Batson, 1957).

The vertebral venous plexus assumes importance in cases of:

- 1 Carcinoma of prostate causing secondaries in the vertebral column and the skull.
- 2 Chronic empyema causing brain abscess by septic emboli.

Anatomy of Batson's Plexus

Vertebral venous system is made up of a valveless, complicated network of veins with a longitudinal pattern. It runs parallel to and anastomoses with the superior and inferior venae cavae. This network has three intercommunicating subdivisions (Fig. 32.10).

- 1 *Epidural plexus* lies in vertebral canal outside the dura mater. The plexus consists of a postcentral and a prelaminar portion. Each portion is drained by two vessels. It drains the structures in the vertebral canal, and is itself drained at regular intervals by segmental veins (vertebral, posterior intercostal, lumbar and lateral sacral).
- 2 *Plexus within the vertebral bodies*: It drains backwards into the epidural plexus, and anterolaterally into the external vertebral plexus.
- 3 *External vertebral venous plexus*: It consists of anterior vessels in front of the vertebral bodies, and the posterior vessels on the back of vertebral arches and adjacent muscles. It is drained by segmental veins. Suboccipital plexus of veins is a part of the external plexus. It lies on and in the suboccipital triangle. It receives the occipital veins of scalp, is connected with the transverse sinus by emissary veins, and drains into the subclavian veins.

COMMUNICATIONS AND IMPLICATIONS

The vertebral system of veins communicates:

- 1 Above with the intracranial venous sinuses.
- 2 Below with the pelvic veins, portal vein, and caval system of veins.

The veins are valveless and the blood can flow in them in either direction. An increase in intrathoracic or intra-abdominal pressure, such as is brought about by coughing and straining, may cause blood to flow in the plexus away from the heart, either upwards or downwards. Such periodic changes in venous pressure are clinically important because they spread tumours or infections. Thus the cells from pelvic, abdominal, thoracic and breast tumours may enter the venous system, and may ultimately lodge in the vertebrae, the spinal cord, skull, or brain.

The common primary sites causing secondaries in vertebrae are the breast, prostate, and kidney. Vertebral tuberculosis is similarly explained.



FACTS TO REMEMBER

- Prostate comprises three lobes, one median, one anterior, one posterior and two lateral.
- Benign hypertrophy of prostate occurs in the median lobe; carcinoma occurs in the peripheral zone of prostate.
- Per-rectal examination is an important examination to judge the prostate, or anal canal pathology.
- Prostatic adenoma is enucleated, both the capsules are left behind in the patient.
- Cancer of prostate may metastasise to distant parts through vertebral venous plexus.



CLINICOANATOMICAL PROBLEMS

Case 1

A 65-year-old man had prostatectomy done 2 years back. Because of low backache he got X-ray of spine done which showed secondaries in the lumbar vertebrae

- How do cancer cells spread to lumbar vertebrae?
- Where else can these spread and how?

Ans: The cancer cells pass via venous system. Prostatic venous plexus drains into internal iliac veins and also into vertebral venous plexus through ventral sacral foramina. These pass up along this plexus situated in the epidural space till lumbar vertebrae causing secondaries there.

These cancer cells can also travel up through this quiet, valveless dangerous venous plexus in the cervical region and to basilar venous plexus inside the cranial cavity. Thus cancer of prostate can spread till the cranial cavity.

Case 2

A man was referred for vasectomy. A few problems were posed to the medical student.

- Is vasectomy done on one or both sides?
- How does one feel the vas deferens?
- How is vasectomy done?
- Does the patient need hospitalisation?

Ans: Vasectomy is done on both sides at the same sitting, one after the other.

Vas deferens is palpated as a firm muscular tube in the spermatic cord.

The vas is pulled out from the incision at the upper posterior part of scrotum and ligated at two places one cm apart. The intervening part is removed and sent for histopathological examination to confirm that the tissue removed is vas deferens only.

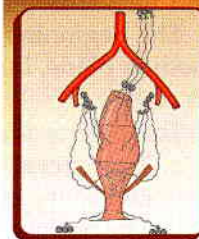
It is an outpatient procedure and needs no hospitalisation.

MULTIPLE CHOICE QUESTIONS

- Which of the following is formed by mesonephric duct?
 - Uterus
 - Penis
 - Ureter
 - Uterine tube
- Zones of prostate are following *except*:
 - Peripheral zone
 - Central zone
 - Periurethral transition zone
 - Paraurethral zone
- Mesonephric duct in male forms all the following structures *except*:
 - Trigone of urinary bladder
 - Collecting part of kidney
 - Epididymis, ductus deferens
 - Prostate gland
- Following are the structures within the prostate *except*:
 - Prostatic utricle
 - Two ejaculatory ducts
 - Urethra
 - Ureter
- Various types of glands within prostate are the following *except*:
 - Mucosal
 - Submucosal
 - Large branching glands
 - Small branching glands

ANSWERS

1. c 2. d 3. d 4. d 5. d



Rectum and Anal Canal

As heat conserved is transmuted into energy, so anger controlled can be transmuted into a power which can move the world

—Mahatama Gandhi

INTRODUCTION

The lowest part of the gastrointestinal tract is formed by the rectum and anal canal. Useful components of the food are absorbed and waste material is expelled from the anus; which is the external opening of the anal canal seen in the perineum. Anal canal is heavily guarded by the sphincters and is subjected to many maladies. Balanced food at proper timing decreases these maladies.

RECTUM

DISSECTION

Identify the relation of the peritoneum to the upper two-thirds of the rectum. See the structures/viscera related to the rectum both in male and female cadavers. Cut through the rectum and examine its mucous membrane with a hand lens.

Find the superior rectal artery, as the continuation of the inferior mesenteric artery. Trace it on to the posterior surface of the upper part of rectum and follow its branches downwards on the posterolateral surfaces till the lowest part of the rectum. Trace the middle rectal artery from its origin from the internal iliac artery till the wall of the rectum.

Features

The rectum is the distal part of the large gut. It is placed between the sigmoid colon above and the anal canal below. Distension of the rectum causes the desire to defaecate.

The rectum in man is not straight as the name implies. In fact it is curved in an anteroposterior direction and also from side to side. The three cardinal features of the large intestine, e.g. sacculations, appendices epiploicae and taeniae are absent in the rectum.

Situation

The rectum is situated in the posterior part of the lesser pelvis, in front of the lower three pieces of the sacrum and the coccyx (Fig. 33.1).

Extent

The rectum *begins* as a continuation of the sigmoid colon at the level of third sacral vertebra. The rectosigmoid junction is indicated by the lower end of the sigmoid mesocolon. The rectum *ends* by becoming continuous with the anal canal at the anorectal junction. The junction lies 2 to 3 cm in front of and a little below the tip of the coccyx. In males the junction corresponds to the apex of the prostate.

Dimensions

The rectum is 12 cm long. In the upper part it has the same diameter of 4 cm as that of the sigmoid colon, but in the lower part it is dilated to form the *rectal ampulla*.

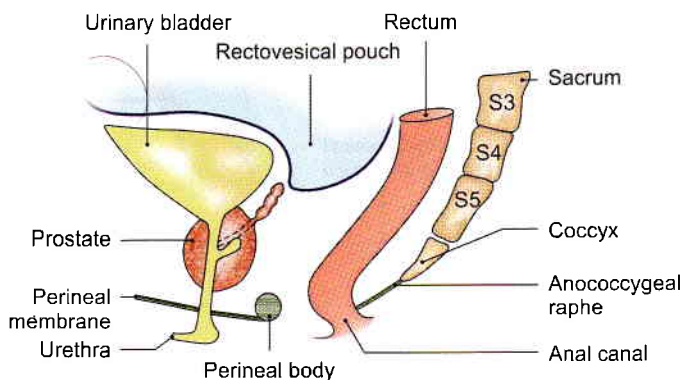


Fig. 33.1: Sagittal section through the male pelvis showing the location of the rectum and some of its anterior and posterior relations



Course and Direction

In its course, the rectum runs first downwards and backwards, then downwards, and finally downwards and forwards (Fig. 33.1).

The beginning and the end of the rectum lie in the median plane, but it shows two types of curvatures in its course.

Two anteroposterior curves:

- The sacral flexure of the rectum follows the concavity of the sacrum and coccyx.
- The perineal flexure of the rectum is the backward bend at the anorectal junction (Figs 33.2a and b).

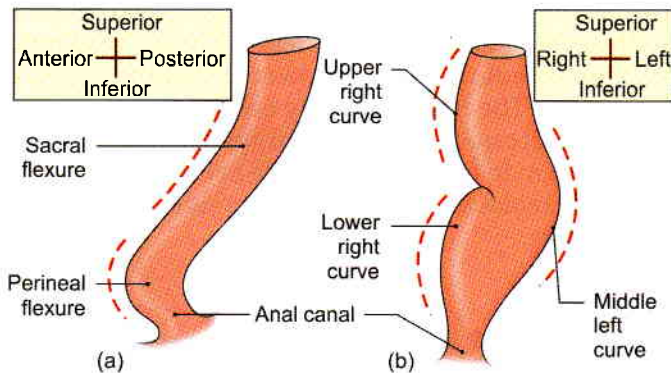
Three lateral curves:

- The upper lateral curve of rectum is convex to the right.
- The middle lateral curve is convex to the left and is most prominent.
- The lower lateral curve is convex to the right.

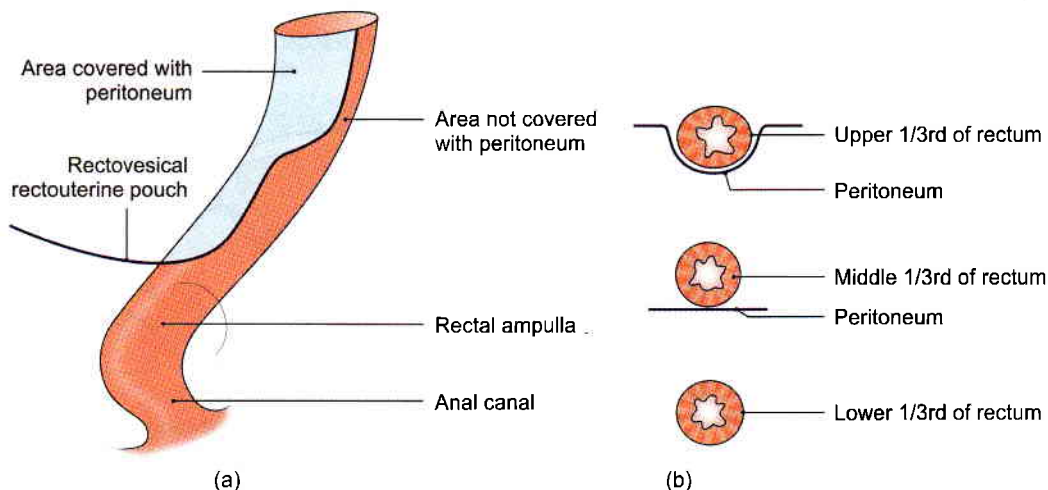
Relations

Peritoneal Relations

- The upper one-third of the rectum is covered with peritoneum in front and on the sides.



Figs 33.2a and b: Curvatures of the rectum: (a) Anteroposterior curves, and (b) side to side (lateral) curves



Figs 33.3a and b: Peritoneal relations of the rectum

- The middle one-third is covered only in front.
- The lower one-third, which is dilated to form the ampulla, is devoid of peritoneum, and lies below the rectovesical pouch in males and below the rectouterine pouch in females. The distance between the anus and the floor of the pouch is 7.5 cm in males but only 5.5 cm in females (Figs 33.3a and b).

Visceral Relations

Anteriorly in males

- The upper two-thirds of the rectum are related to the rectovesical pouch with coils of intestine and sigmoid colon.
- The lower one-third of the rectum is related to the base of the urinary bladder, the terminal parts of the ureters, the seminal vesicles, the deferent ducts and the prostate (see Fig. 30.3).

Anteriorly in females

- The upper two-thirds of the rectum are related to the rectouterine pouch with coils of intestine and sigmoid colon. The pouch separates the rectum from the uterus, and from the upper part of the vagina.
- The lower one-third of the rectum is related to the lower part of the vagina (see Figs 18.17b and 31.21).

Posteriorly

The relations are the same in the male and female. They are as follows.

- Lower three pieces of the sacrum, the coccyx and the anococcygeal ligament.
- Piriformis, the coccygeus and the levator ani.
- The median sacral, the superior rectal and the lower lateral sacral vessels.
- The sympathetic chain with the ganglion impar; the anterior primary rami of S3, S4, S5, coccygeal 1 and the pelvic splanchnic nerves; lymph nodes, lymphatics and fat (Fig. 33.4).

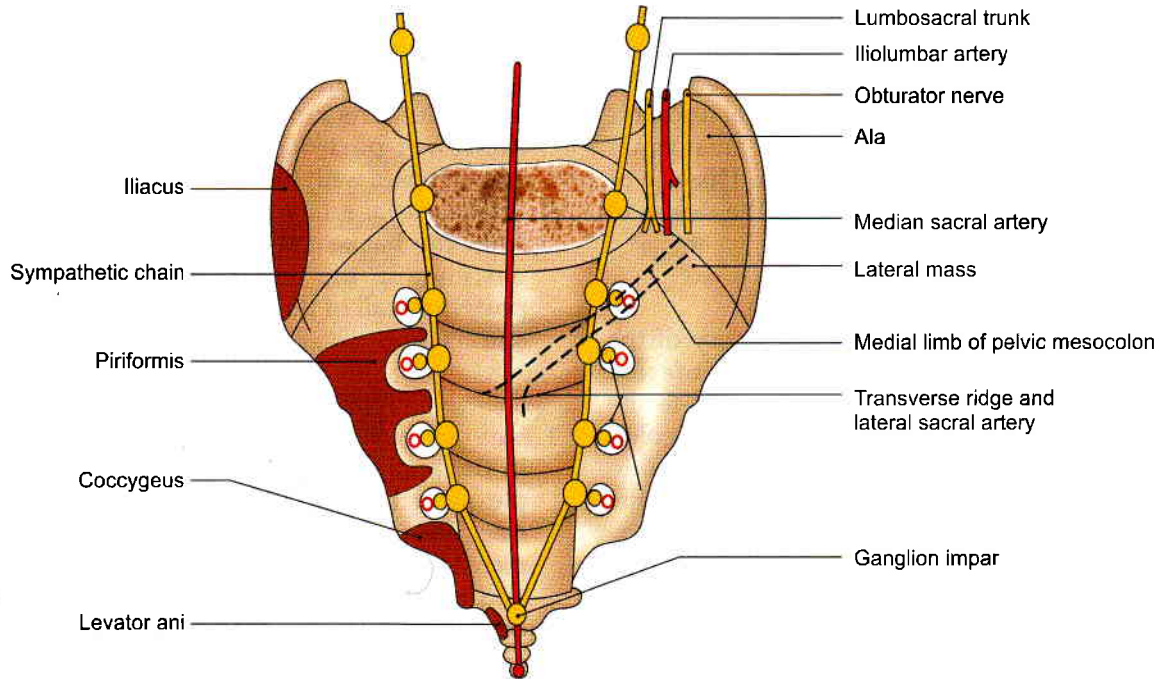


Fig. 33.4: Posterior relations of the rectum (below the level of the middle of the third piece of the sacrum)

Mucosal Folds

The mucous membrane of an empty rectum shows two types of folds, longitudinal and transverse.

The *longitudinal folds* are transitory. They are present in the lower part of an empty rectum, and are obliterated by distension.

The *transverse* or *horizontal folds* or Houston's valves or plicae transversales are permanent and most marked when the rectum is distended.

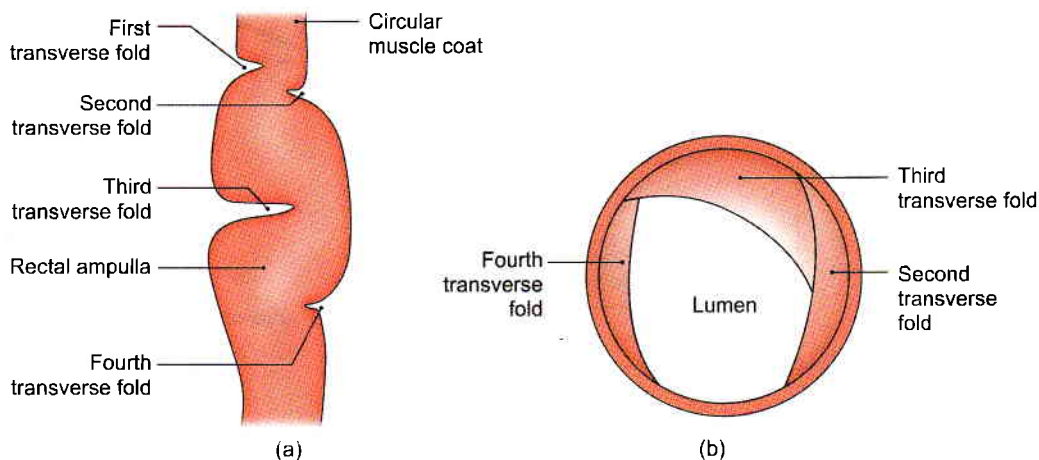
- The first small transverse fold projects from right wall. It is 12–14 cm above anal canal.
- The *second transverse fold* lies near the upper end of the rectum, and projects from the left wall

situated 7.5 cm above anus. Sometimes it may encircle and partially constrict the lumen.

- The *third transverse fold*, the largest and most constant, lies at the upper end of the rectal ampulla, and projects from the anterior and right walls. It is some above anus.
- The *fourth transverse fold* which is inconstant lies 2.5 cm below the middle fold, and projects from the left wall (Figs 33.5a and b).

Functional Parts of Rectum

The rectum has two developmental parts. The upper part related to the peritoneum develops from the



Figs 33.5a and b: Superior view of the transverse mucosal folds of the rectum



hindgut and lies above the third transverse fold of the rectum. The lower part devoid of peritoneum develops from the cloaca and lies below the third transverse fold.

Functionally, the sigmoid colon is the faecal reservoir and the whole of the rectum is empty in normal individuals, being sensitive to distension. Passage of faeces into the rectum, therefore, causes the desire to defaecate.

Arterial Supply

1 *Superior rectal artery:* This is the chief artery of the rectum. It is the continuation of the inferior mesenteric artery at the pelvic brim, medial to the left ureter. It lies in medial limb of pelvic mesocolon and divides opposite the third sacral vertebra into right and left branches which run on each side of the rectum. Each branch breaks up at the middle of the rectum into several small branches which pierce the muscular coats and run in the anal columns up to the anal valves where they form looped anastomoses (Fig. 33.6).

2 *Middle rectal arteries:* These supply only the superficial coats of the lower rectum. They arise from the anterior division of the internal iliac artery, run in the lateral ligaments of rectum, and supply the muscle coats of the lower part of the rectum (Fig. 33.6). Their anastomoses with the adjacent arteries are poor.

3 *Median sacral artery:* This is a small branch arising from the back of the aorta near its lower end. It descends in the median plane and supplies the posterior wall of the anorectal junction (see Figs 27.1 and 33.4).

Venous Drainage

1 *Superior rectal vein:* The tributaries of this vein begin in the anal canal, from the internal rectal venous plexus, in the form of about three veins of considerable size. They pass upwards in the rectal submucosa, pierce the muscular coat about 7.5 cm above the anus and unite to form the superior rectal vein which continues upwards as the inferior mesenteric vein to end in the splenic vein (Fig. 33.6).

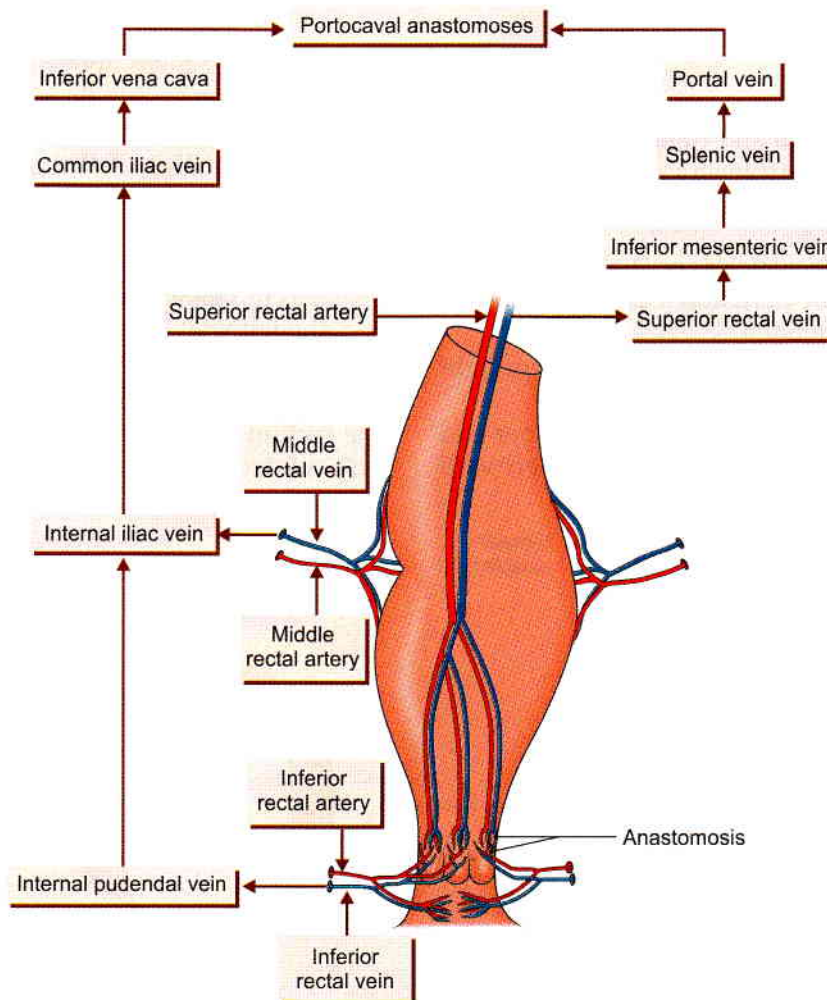
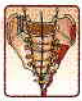

Fig. 33.6: Blood supply of rectum and anal canal



- 2 *Middle rectal vein*: The tributaries of this vein drain, chiefly, the muscular walls of the rectal ampulla, and open into the internal iliac veins (Fig. 33.6).
- 3 *Median sacral vein*: It joins left common iliac vein.

Lymphatic Drainage

- 1 Lymphatics from more than the *upper half* of the rectum pass along the superior rectal vessels to the inferior mesenteric nodes after passing through the pararectal and sigmoid nodes (Fig. 33.7).
- 2 Lymphatics from the *lower half* of the rectum pass along the middle rectal vessels to the internal iliac nodes.
- 3 Lymphatics from the lower part of anal canal drain into superficial inguinal nodes.

Nerve Supply

The rectum is supplied by both sympathetic (L1, L2) and parasympathetic (S2, S3, S4) nerves through the superior rectal or inferior mesenteric and inferior hypogastric plexuses.

Sympathetic nerves are vasoconstrictor, inhibitory to the rectal musculature and motor to the internal sphincter. Parasympathetic nerves are motor to the

musculature of the rectum and inhibitory to the internal sphincter.

Sensations of distension of the rectum pass through the parasympathetic nerves, while pain sensations are carried by both the sympathetic and parasympathetic nerves.

Supports of Rectum

- 1 Pelvic floor formed by levator ani muscles (*see* Fig. 31.14).
- 2 *Fascia of Waldeyer*: It attaches the lower part of the rectal ampulla to the sacrum. It is formed by condensation of the pelvic fascia behind the rectum. It encloses the superior rectal vessels and lymphatics.
- 3 *Lateral ligaments of the rectum*: They are formed by condensation of the pelvic fascia on each side of the rectum. They enclose the middle rectal vessels, and branches of the pelvic plexuses, and attach the rectum to the posterolateral walls of the lesser pelvis.
- 4 *Rectovesical fascia of Denonvilliers*: It extends from the rectum behind to the seminal vesicles and prostate in front (*see* Fig. 32.3).
- 5 The *pelvic peritoneum* and the related *vascular pedicles* also help in keeping the rectum in position (Fig. 33.3).
- 6 Perineal body with its muscles (*see* Fig. 28.4).

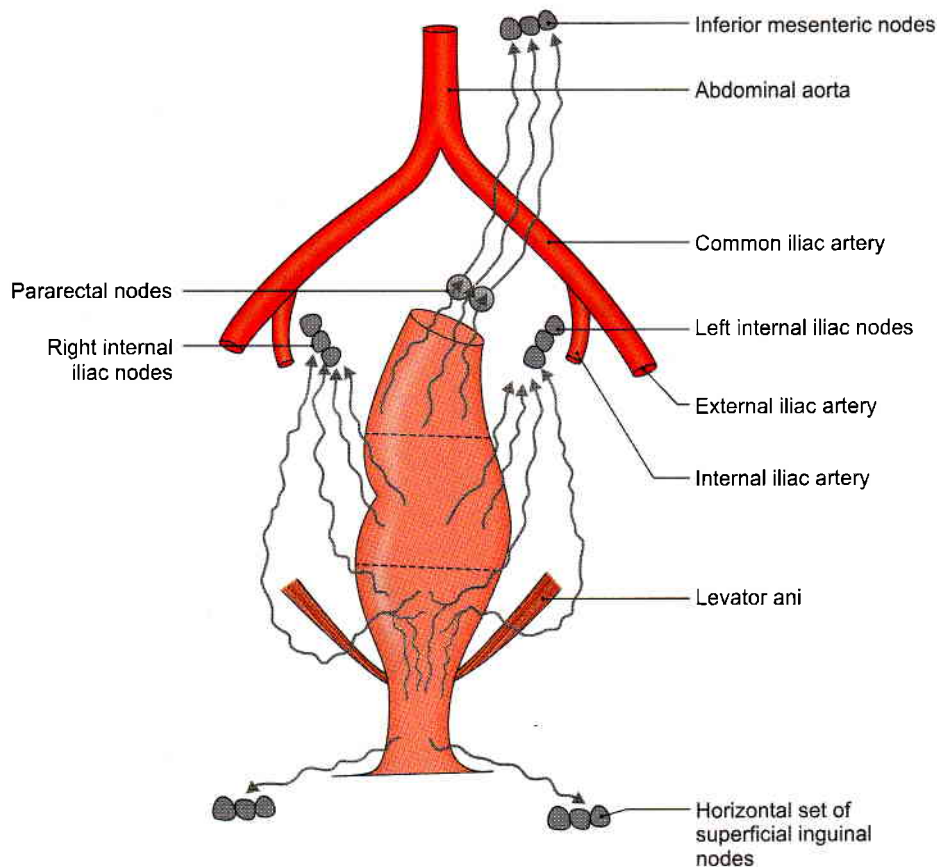


Fig. 33.7: Lymph drainage of rectum and anal canal



CLINICAL ANATOMY

- **Digital per rectum (PR) examination:** In PR examination the finger enters anal canal before reaching lower end of rectum.

In a normal person, the following structures can be palpated by a finger passed per rectum.

In males (Fig. 33.8):

1. Posterior surface of prostate.
2. Seminal vesicles.
3. Vas deferens.

In females (Fig. 33.9):

1. Perineal body.
2. Cervix.
3. Presenting part of the foetus during delivery.

In both sexes:

1. Anorectal ring.
2. Coccyx and sacrum.
3. Ischioanal fossae and ischial spines.

In patients, a PR examination can help in the palpation of following abnormalities.

- a. Within the lumen: Faecal impaction and foreign bodies, bleeding piles or haemorrhoids.
- b. In the rectal wall: Rectal growths and strictures, and thrombosed piles.
- c. Outside the rectal wall: In males, the enlargements of prostate, seminal vesicles and bulbourethral glands, and stone in membranous urethra; in females, enlargements of uterus, tubes and ovaries, and abnormalities in the pouch of Douglas; and in both sexes, the distended bladder, lower ureteric stones, and tumours of the bony pelvis.

During parturition the dilatation of cervix is commonly assessed through the rectal wall to avoid infection by repeated vaginal examinations (Fig. 33.9).

- **Proctoscopy and sigmoidoscopy:** The interior of the rectum and anal canal can be examined under direct vision with special instruments, like a proctoscope or a sigmoidoscope. Proctoscopy shows internal piles and growths in lower part of rectum. Sigmoidoscopy helps in revealing the ulcers, growths and diverticula, and in taking a rectal biopsy.
- **Prolapse of rectum:** *Incomplete* or *mucosal prolapse* of the rectum through the anus may occur following violent straining. This is due to imperfect support of the rectal mucosa by the submucosa which is made up of loose areolar tissue.

Complete prolapse or *proctidentia* is the condition in which the whole thickness of the rectal wall protrudes through the anus. The contributory factors in its causation are:

- a. Laxity of the pelvic floor.
- b. Excessively deep rectovesical or rectouterine pouch.
- c. Inadequate fixation of the rectum in its presacral bed.

- **Neurological disturbances of the rectum:** In spite of the identical innervation of the rectum and bladder, the rectal involvement in nervous lesions is less severe than that of the bladder.

After sacral denervation of the rectum the peripheral nervous plexus controls the automatic evacuation of the rectum. This reflex activity is more massive and complete when sacral innervation is intact, e.g. complete cord lesion above the sacral region. However, due to weak musculature of the rectum and sparing of the tone of the external sphincter by transverse lesions of the cord, rectal disturbances tend to cause constipation, although complete lesions may cause reflex defaecation.

- **Carcinoma of rectum:** It is quite common, and is generally situated at the rectosigmoid junction (constricting type), or in the ampulla (proliferating type). It causes bleeding per rectum from an indurated raised ulcer. The condition is surgically treated by an abdominoperineal excision in which the anus, anal canal and rectum with their fascial sheaths, and a varying amount of distal colon along with its mesocolon containing the lymph nodes are removed en bloc, and a permanent colostomy in the left iliac fossa is done with the proximal cut end of the colon.
- **Rectal continence:** Rectal continence depends solely on the anorectal ring. Damage to the ring results in rectal incontinence. The surgeon has to carefully protect the anorectal ring in operating on the region.

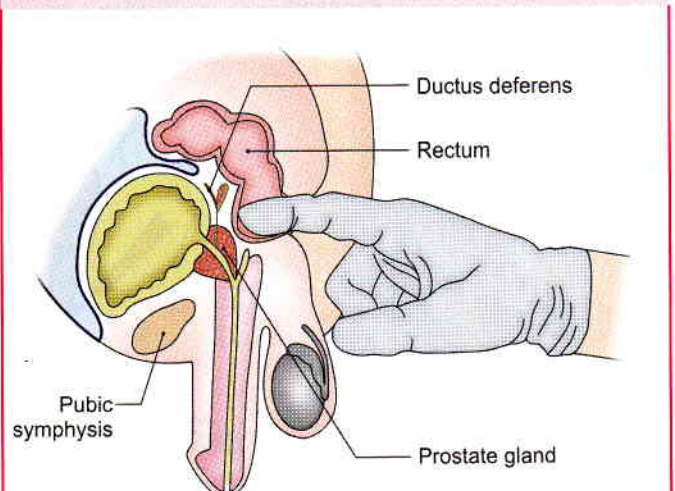


Fig. 33.8: Digital per rectal (PR) examination in male

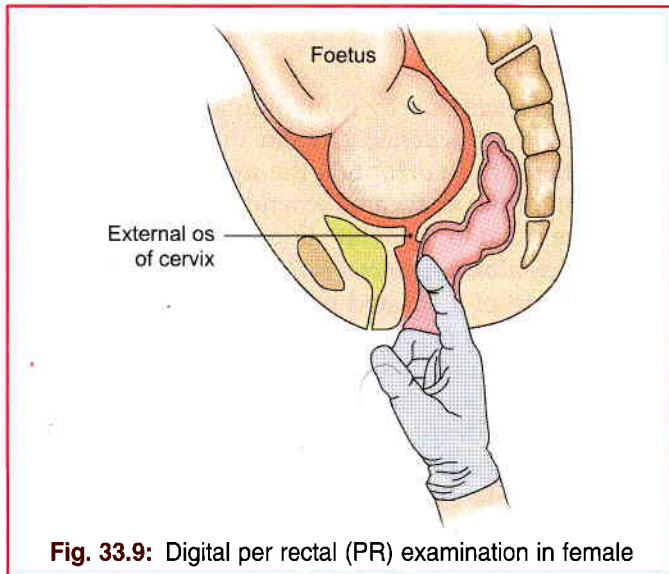
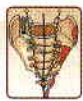

Fig. 33.9: Digital per rectal (PR) examination in female

ANAL CANAL

DISSECTION

Identify the relations of the anal canal in both male and female. Examine the lining of the anal canal. Strip the mucous membrane and skin from a sector of the anal canal. Identify the thickened part of the circular muscle layer forming the internal sphincter of the anus. Locate the external anal sphincter with its parts, partly overlapping the internal sphincter. The anal canal is the terminal part of the large intestine.

Situation

Anal canal is situated below the level of the pelvic diaphragm. It lies in the anal triangle of perineum in between the right and left ischioanal fossae, which allows its expansion during passage of the faeces. The sacculations and taeniae are absent here also.

Length, Extent and Direction

The anal canal is 3.8 cm long. It extends from the anorectal junction to the anus. It is directed downwards and backwards. The anal canal is surrounded by inner involuntary and outer voluntary sphincters which keep the lumen closed in the form of an anteroposterior slit.

The *anorectal junction* is marked by the forward convexity of the perineal flexure of the rectum (Fig. 33.2) and lies 2–3 cm in front of and slightly below the tip of the coccyx. Here the ampulla of the rectum suddenly narrows and pierces the pelvic diaphragm. In males it corresponds to the level of the apex of the prostate.

The *anus* is the surface opening of the anal canal, situated about 4 cm below and in front of the tip of the

coccyx in the cleft between the two buttocks. The surrounding skin is pigmented and thrown into radiating folds, and contains a ring of large apocrine glands.

RELATIONS OF THE ANAL CANAL

Anteriorly

- 1 *In both sexes*: Perineal body.
- 2 *In males*: Membranous urethra and bulb of penis.
- 3 *In females*: Lower end of the vagina (see Fig. 31.21).

Posteriorly

- 1 Anococcygeal ligament.
- 2 Tip of the coccyx (see Fig. 28.6).

Laterally: Ischioanal fossae (see Fig. 28.6).

All-round: Anal canal is surrounded by the sphincter muscles, the tone of which keeps the canal closed.

INTERIOR OF THE ANAL CANAL

The interior of the anal canal shows many important features and can be divided into three parts: the upper part about 15 mm long; the middle part about 15 mm long; and the lower part about 8 mm long. Each part is lined by a characteristic epithelium and reacts differently to various diseases of this region (Fig. 33.10).

Upper Mucous Part

- 1 This part is about 15 mm long. It is lined by mucous membrane, and is of endodermal origin.
- 2 The mucous membrane shows:
 - a. 6 to 10 vertical folds; these folds are called the *anal columns* of Morgagni.
 - b. The lower ends of the anal columns are united to each other by short transverse folds of mucous membrane; these folds are called the *anal valves*.
 - c. Above each valve there is a depression in the mucosa which is called the *anal sinus*.
 - d. The anal valves together form a transverse line that runs all-round the anal canal. This is the

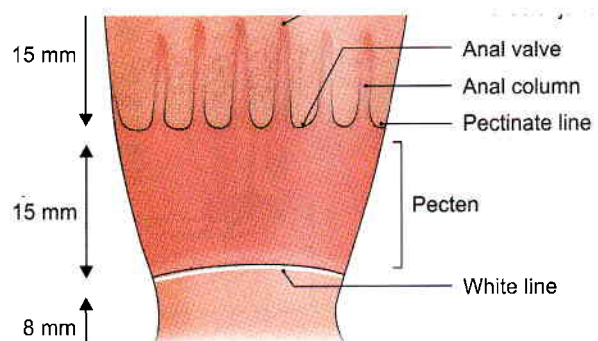
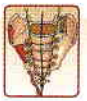

Fig. 33.10: Interior of the anal canal



pectinate line. It is situated opposite the middle of internal anal sphincter, the junction of ectodermal and endodermal parts. Occasionally the anal valves show epithelial projections called *anal papillae*. These papillae are remnants of the embryonic anal membrane (Fig. 33.11).

- e. The anal sinus contains anal glands. The secretion of these glands produce peculiar smell which is important in lower animals to attract.

Middle Part or Transitional Zone or Pecten

- 1 The next 15 mm or so of the anal canal is also lined by mucous membrane, but anal columns are not present here. The mucosa has a bluish appearance because of a dense venous plexus that lies between it and the muscle coat. The mucosa is less mobile than in the upper part of the anal canal. This region is referred to as the *pecten* or *transitional zone*. The lower limit of the pecten often has a whitish appearance because of which it is referred to as the *white line of Hilton*. Hilton's line is situated at the level of the interval between the subcutaneous part of external anal sphincter and the lower border of internal anal sphincter.
- 2 It marks the lower limit of pecten or stratified squamous epithelium which is thin, pale and glossy and is devoid of sweat glands.

Lower Cutaneous Part

It is about 8 mm long and is lined by true skin containing sebaceous glands. The epithelium of the lowest part resembles that of pigmented skin in which sebaceous glands, sweat glands and hair are present.

MUSCULATURE OF THE ANAL CANAL

Anal Sphincters

The *internal anal sphincter* is involuntary in nature. It is formed by the thickened circular muscle coat of this part of the gut. It surrounds the upper three-fourths, i.e. 30 mm of the anal canal extending from the upper end of the canal to the white line of Hilton.

The *external anal sphincter* is under voluntary control. It is made up of a striated muscle and is supplied by the inferior rectal nerve and the perineal branch of the fourth sacral nerve. It surrounds the whole length of the anal canal and has three parts, subcutaneous, superficial and deep.

Contrary to earlier view, the external anal sphincter forms a single functional and anatomic entity. Uppermost fibres blend with fibres of puborectalis. Anteriorly some fibres decussate with superficial transverse perinei muscle and posterior fibres get attached to anococcygeal raphe (Fig. 33.12a).

Middle fibres surround lower part of internal anal sphincter. These are attached to perineal body anteriorly and to coccyx via anococcygeal ligament posteriorly. Some fibres of each side decussate to form a commissure in the midline.

Lower fibres lie below the level of internal anal sphincter and are separated from anal epithelium by submucosa.

In males transverse perinei and bulbospongiosus end in central point of perineum, so that there is a surgical plane of cleavage between urogenital triangle and anal canal.

In females, the puborectalis is separate from external anal sphincter. Its anterior portion is thinner and shorter (Fig. 33.12b).

In addition, in females, transverse perinei and bulbospongiosus fuse with external anal sphincter in lower part of perineum.

Conjoint Longitudinal Coat

It is formed by fusion of the puborectalis with the longitudinal muscle coat of the rectum at the anorectal junction. It lies between the external and internal sphincters. When traced downwards it becomes fibroelastic and at the level of the white line it breaks up into a number of fibroelastic septa which spread out fan wise, pierce the subcutaneous part of the external sphincter, and are attached to the skin around the anus called as corrugator cutis ani. The most lateral of these septa forms the perianal fascia. The most medial septum forms, the *anal intermuscular septum*, which is attached to the white line. In addition, some strands pass obliquely through the internal sphincter and end in the submucosa below the anal valves (Fig. 33.11).

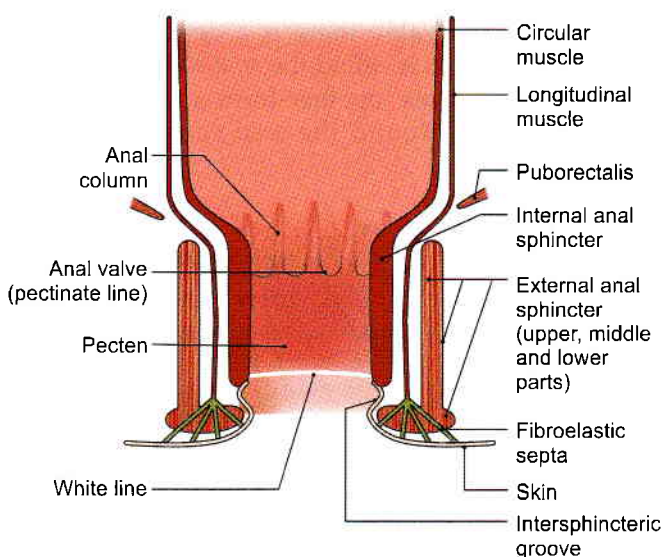
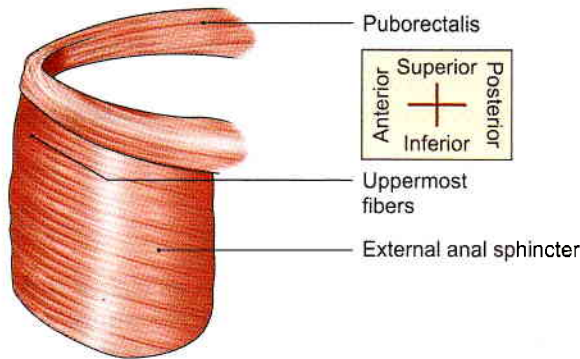
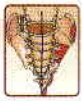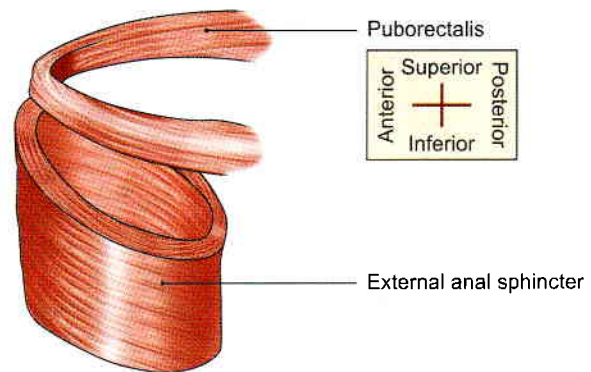


Fig. 33.11: Coronal section through the wall of the anal canal



Male
(a)



Female
(b)

Figs 33.12a and b: Relation of puborectalis and external anal sphincter (a) in male, and (b) in female

Anorectal Ring

This is a muscular ring present at the anorectal junction. It is formed by the fusion of the puborectalis, uppermost fibres of external sphincter and the internal sphincter. It is easily felt by a finger in the anal canal. Surgical division of this ring results in rectal incontinence. The ring is less marked anteriorly where the fibres of the puborectalis are absent (Figs 33.12a and b).

Surgical Spaces Related to the Anal Canal

- 1 The *ischioanal space* or fossa lies on each side of the anal canal. It is described in Chapter 28.
- 2 The *perianal space* surrounds the anal canal below the white line. It contains the lower fibres of external sphincter, the external rectal venous plexus, and the terminal branches of the inferior rectal vessels and nerves. Pus in this space tends to spread to the anal canal at the white line or to the surface of the perineal skin rather than to the ischioanal space.
- 3 The *submucous space* of the canal lies above the white line between the mucous membrane and the internal sphincter. It contains the internal rectal venous plexus and lymphatics (Fig. 33.13).

Arterial Supply

- 1 The part of the anal canal above the pectinate line is supplied by the superior rectal artery.
- 2 The part below the pectinate line is supplied by the inferior rectal arteries (Fig. 33.6).

Venous Drainage

- 1 The *internal rectal venous plexus* or haemorrhoidal plexus lies in the submucosa of the anal canal. It drains mainly into the superior rectal vein, but communicates freely with the external plexus and thus with the middle and inferior rectal veins. The internal plexus is, therefore, an important site of communication between the portal and systemic veins. The internal plexus is in the form of a series of

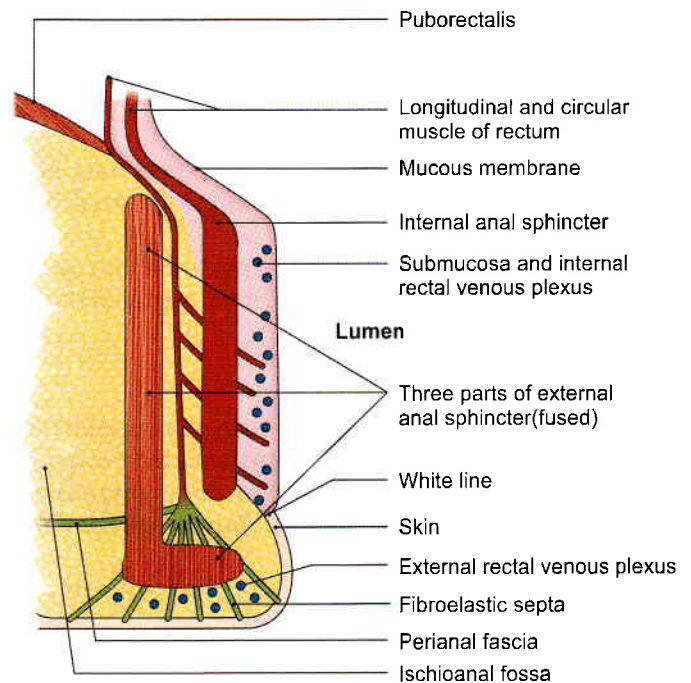


Fig. 33.13: Coronal section through the anal canal (magnified)

dilated pouches connected by transverse branches around the anal canal (Fig. 33.6).

Veins present in the three anal columns situated at 3, 7 and 11 o'clock positions as seen in the lithotomy position are large and constitute potential sites for the formation of primary internal piles (Fig. 33.14).

- 2 The *external rectal venous plexus* lies outside the muscular coat of the rectum and anal canal, and communicates freely with the internal plexus. The lower part of the external plexus is drained by the inferior rectal vein into internal pudendal vein; the middle part by middle rectal vein into internal iliac vein; and the upper part by superior rectal vein which continues as the inferior mesenteric vein.
- 3 The *anal veins* are arranged radially around the anal margin. They communicate with the internal rectal

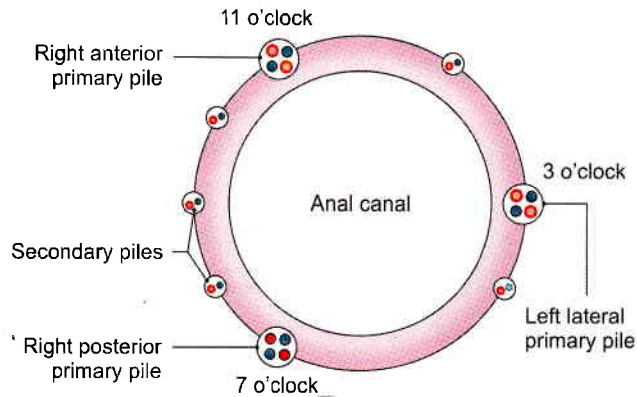


Fig. 33.14: Position of primary and secondary piles haemorrhoids

plexus and with the inferior rectal veins. Excessive straining during the defaecation may rupture one of these veins, forming a subcutaneous perianal haematoma known as external piles.

Lymphatic Drainage

Lymph vessels from the part above the pectinate line, drain with those of the rectum into the internal iliac nodes.

Vessels from the part below the pectinate line drain into the medial group of the superficial inguinal nodes (Fig. 33.7).

Nerve Supply

- Above the pectinate line*, the anal canal is supplied by autonomic nerves, both sympathetic (inferior hypogastric plexus; L1, L2) and parasympathetic (pelvic splanchnic, S2, S3, S4). Pain sensations are carried by both of them.
- Below the pectinate line*, it is supplied by somatic (inferior rectal, S2, S3, S4) nerves.
- Sphincters:* The internal sphincter is caused to contract by sympathetic nerves and is relaxed by parasympathetic nerves. The external sphincter is supplied by the inferior rectal nerve and by the perineal branch of the fourth sacral nerve.

HISTOLOGY

Rectum: The mucous membrane of rectum has many large folds. The epithelium and crypts contain abundant goblet cells. Submucosa contains plexus of nerves and capillaries. Muscularis externa is of uniform thickness. Serosa is seen in upper part and adventitia in lower part.

Anal canal: The epithelium lining of upper 15 mm is simple or stratified columnar, while that of middle 15 mm is stratified squamous without any sweat gland or sebaceous gland or hair follicle. The epithelium of lowest 8 mm resembles that of true skin with sweat and sebaceous glands and hair follicles.

The thick inner circular layer covers the upper three-fourths of anal canal to form the internal anal sphincter. The outer longitudinal layer is a thin layer. Outside these smooth muscle layers is the striated external anal sphincter.

DEVELOPMENT

Rectum

The distal part of hindgut known as cloaca is divided by urorectal septum into primitive anorectal canal posteriorly and vesicourethral canal anteriorly. Primitive anorectal canal forms the lower part of rectum and proximal part of anal canal. Its distal part of anal canal is formed by the proctodeum.

Upper part of rectum, i.e. part above the third transverse fold of rectum, develops from endoderm of hindgut. This part is related to peritoneum. Lower part, below the third transverse fold, is formed from the dorsal part of the cloaca. It is devoid of peritoneum.

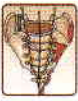Anal Canal

Upper 15 mm develops from the primitive anorectal canal. Lower part below the pectinate line (lower 15 + 8 mm) is formed from ectodermal invagination, i.e. proctodeum (Greek *on the way to*). Non-continuity of the two parts results in imperforate anus.

Table 33.1 shows comparison of upper and lower parts of anal canal.

CLINICAL ANATOMY

- Piles/haemorrhoids:** *Internal piles* or true piles are saccular dilatations of the internal rectal venous plexus. They occur above the pectinate line and are, therefore, painless. They bleed profusely during straining at stool. The *primary piles* occur in 3, 7 and 11 o'clock positions of the anal wall when viewed in the lithotomy position. They are formed by enlargement of the three main radicles of the superior rectal vein which lie in the anal columns, which occupy the left lateral, right posterior, and right anterior positions (Fig. 33.14). Varicosities in other positions of the lumen are called *secondary piles*. The various factors responsible for causing internal piles are:
 - Poor support to veins from the surrounding loose connective tissue, so that the veins are less capable of resisting increased blood pressure;
 - Absence of valves in the superior rectal and portal veins;
 - Compression of the veins at the sites where they pierce the muscular coat of the rectum; and
 - Direct transmission of the increased portal pressure at the portosystemic communications.
 For these reasons the development of piles is

**Table 33.1: Comparison of upper (15 mm) and lower (23 mm) parts of anal canal**

	Upper part 15 mm	Lower part 15 + 8 mm
1. Development	Hindgut (endoderm)	Proctodaeum (ectoderm)
2. Lining	Simple columnar epithelium squamous.	Stratified columnar and stratified
3. Arterial supply of mucosa	Mainly superior rectal	Mainly inferior rectal
4. Venous drainage	Chiefly into portal vein.	Chiefly into systemic veins
5. Lymph drainage	Internal iliac lymph nodes.	Superficial inguinal lymph nodes.
6. Nerve supply	Autonomic nerves: Sympathetic L1, L2 Parasympathetic S2, S3, S4	Inferior rectal (somatic) nerve, S2, S3, S4
7. Sensory to	Ischaemia, distension and spasm	Pain, touch, temperature and pressure.
8. Type of piles	Internal painless piles	External painful piles

favoured by constipation, prolonged standing, excessive straining at stool, and portal hypertension.

- *External piles* or false piles occur below the pectinate line and are, therefore, very painful. They do not bleed on straining at stool.
- *Fissure in ano*: Anal fissure is caused by the rupture of one of the anal valves, usually by the passage of dry hard stool in a constipated person. Each valve is lined with mucous membrane above, and with skin below. Because of the involvement of skin the condition is extremely painful and is associated with marked spasm of the anal sphincters.
- *Fistula in ano*: A fistula is an abnormal epithelialised track connecting two cavities, or one cavity with the exterior (see Fig. 28.10).
- *Fistula in ano* is caused by spontaneous rupture of an abscess around the anus or may follow surgical drainage of the abscess. Most of these abscesses are formed by the small vestigial glands opening into the anal sinuses. Such an anorectal abscess tends to track in various directions and may open medially into the anal sinus, laterally into the ischioanal fossa, inferiorly at the surface, and superiorly into the rectum. A fistula can also be caused by an ischioanal or a pelvirectal abscess. The fistula is said to be complete when it opens both internally into the lumen of the gut and externally at the surface.
- More severe malformations of the anorectal region include the following.
 - a. Anal stenosis.
 - b. Anal agenesis with or without a fistula.
 - c. Anorectal agenesis with or without a fistula. Most of the anorectal malformations are caused by abnormal partitioning of the cloaca by the urorectal septum.

**FACTS TO REMEMBER**

- Middle lateral curvature of rectum is most prominent. It is convex to the left side.
- Chief artery of rectum is superior rectal and chief vein is superior rectal vein.
- Perineal body and levator ani form the main supports of rectum.
- Most of the anal canal is surrounded by internal and external anal sphincters.
- Only middle fibres of external anal sphincter have a bony attachment.
- Proximal 15 mm of anal canal develops from anorectal canal (endoderm) and distal 23 mm develops from the proctodaeum (ectoderm)
- Primary piles appear at 3, 7, 11 o'clock positions.

CLINICOANATOMICAL PROBLEM

A female patient aged 40 years complained of a painless, bleeding with some structure coming out of anus at the time of defaecation

- What is the painless structure which bleeds during defaecation?
- Identify the reasons for this development

Ans: The patient has developed internal haemorrhoids or piles. These are due to prolapse of the mucous membrane containing the tributaries of internal rectal venous plexus draining blood from the anal canal. Since this part of mucous membrane is supplied by autonomic nerves, these piles are not painful. Since these contain varicose venous radicles, these rupture due to pressure, resulting in painless bleeding during defaecation.

These types of piles may result from irregular bowel habits, chronic constipation, too much straining during defaecation and also in case of portal hypertension resulting due to liver cirrhosis.



MULTIPLE CHOICE QUESTIONS

1. Inferior rectal artery is a branch of:
 - a. Internal iliac
 - b. Inferior mesenteric
 - c. Internal pudendal
 - d. Superior mesenteric
2. Superior rectal is a branch/continuation of:
 - a. Superior mesenteric
 - b. Inferior mesenteric
 - c. Internal iliac
 - d. External iliac
3. Which artery supplies the posterior part of anorectal junction and posterior part of anal canal?
 - a. Inferior rectal
 - b. Superior rectal
 - c. Median sacral
 - d. Middle rectal
4. Middle rectal artery chiefly supplies:
 - a. Mucous membrane
 - b. Muscle layers
 - c. Connective tissue
 - d. All of the above
5. Which vessel is present in the lateral rectal ligament?
 - a. Superior rectal
 - b. Middle rectal
 - c. Inferior rectal
 - d. All of the above
6. Following structures form the anorectal ring *except*:
 - a. Deep external sphincter
 - b. Internal sphincter
 - c. Puborectalis
 - d. Conjoint longitudinal coat
7. Which part of sphincter ani externus has a bony attachment?
 - a. Superficial
 - b. Subcutaneous
 - c. Deep
 - d. All of the above

ANSWERS

1. c 2. b 3. c 4. b 5. b 6. d 7. a



Walls of Pelvis

There is a great man who makes every one feel small. But the real great man is the man who makes every one feel great
—Charles Dickens

All the pelvic viscera, i.e. terminal parts of digestive and urinary system; and components of genital system are located in the pelvis. These organs are provided due protection and nutrition by the bones, muscles, fascia, blood vessels, lymphatics and nerves of the pelvis. The posterior superior iliac spine seen as a dimple (mostly covered) lies opposite the middle of the sacroiliac joint.

Contents: In this chapter the vessels, nerves, muscles, fascia, and joints of the pelvis will be considered.

VESSELS OF THE PELVIS

DISSECTION

Remove the viscera from the pelvic wall and the pelvic cavity. Trace the internal iliac artery and its two divisions. Follow the branches of each of its divisions to the position of the viscera and the parieties. Remove the veins and venous plexuses as these obstruct the view of the arteries. Clean the hypogastric plexus.

INTERNAL ILIAC ARTERY

The internal iliac artery is the smaller terminal branch of the common iliac artery. It is 3.75 cm long. It supplies:

- 1 Pelvic organs except those supplied by the superior rectal, ovarian and median sacral arteries.
- 2 Perineum.
- 3 Greater part of the gluteal region.
- 4 Iliac fossa.

In the foetus, internal iliac artery is double the size of the external iliac artery because it transmits blood to the placenta through the umbilical artery. The umbilical artery with the internal iliac then forms the direct continuation of the common iliac artery. After birth the proximal part of the umbilical artery persists to form

superior vesical artery, and the rest of it degenerates into a fibrous cord, the medial umbilical ligament.

Course

The internal iliac artery begins in front of the sacroiliac joint, at the level of the intervertebral disc between the fifth lumbar vertebra and the sacrum. Here it lies medial to the psoas major muscle. The artery runs downwards and backwards, and ends near the upper margin of the greater sciatic notch, by dividing into anterior and posterior divisions or trunks (Fig. 34.1).

Relations

- Anterior : Ureter. In female to the ovary and lateral end of the uterine tube (*see* Fig. 31.1)
- Posterior : Internal iliac vein, lumbosacral trunk and the sacroiliac joint (*see* Figs 24.27 and 34.7)
- Lateral : External iliac vessels and obturator nerve (Fig. 34.1)
- Medial : Peritoneum and to a few tributaries of the internal iliac vein.

Branches

Branches of Anterior Division

In the male, it gives off six branches.

- 1 Superior vesical.
- 2 Obturator.
- 3 Middle rectal.
- 4 Inferior vesical.
- 5 Inferior gluteal.
- 6 Internal pudendal. The last two are the terminal branches.

In the female, it gives off seven branches. The inferior vesical artery is replaced by the vaginal artery. The uterine artery is the seventh branch.

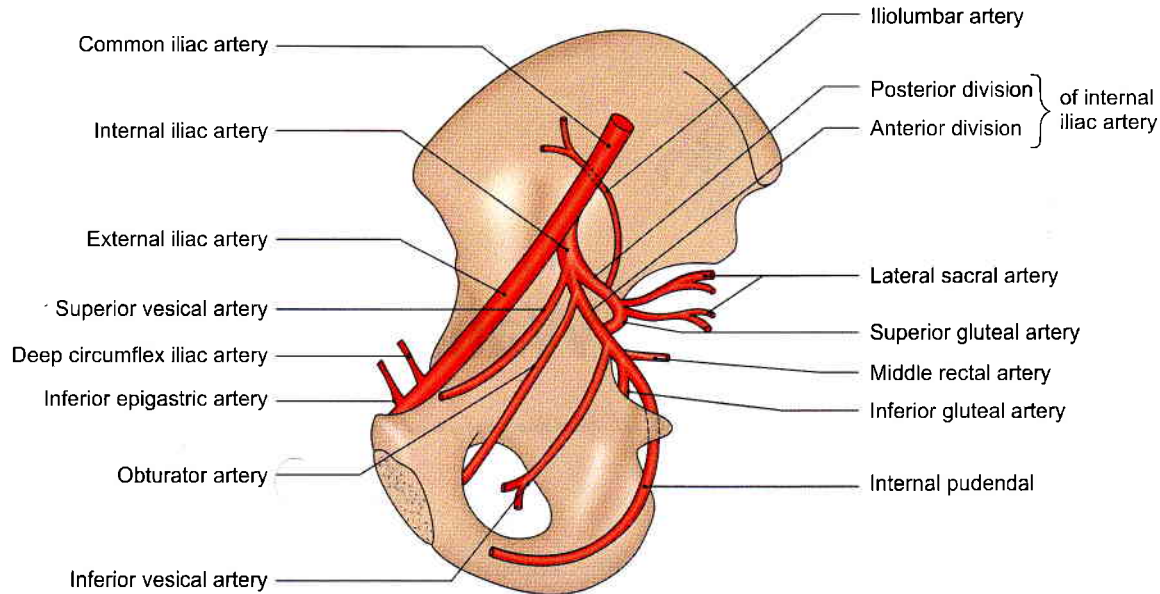


Fig. 34.1: Branches of the right internal iliac artery in a male

Branches of Posterior Division

It gives off:

- 1 Iliolumbar.
- 2 Two lateral sacral.
- 3 Superior gluteal arteries (Flow chart 34.1).

Parietal Branches of Anterior Division

- 1 **Inferior gluteal artery:** It is the largest branch of the anterior division of the internal iliac artery. It is the *axial artery* of the lower limb. It supplies chiefly the buttock and the back of the thigh. In the pelvis, it runs downwards in front of the sacral plexus and piriformis. Next, it pierces the parietal pelvic fascia, passes below the first sacral nerve and then between the piriformis and the coccygeus, and enters the gluteal region through the lower part of the greater sciatic foramen (Fig. 34.2). In the pelvis, it supplies:
 - a. Muscular branches to nearby muscles.
 - b. Vesical branches to the base of the bladder, the seminal vesicles and the prostate.
- 2 **Obturator artery:** It runs forwards and downwards on the obturator fascia below the obturator nerve and above the obturator vein (NAV). Medially, it is crossed by the ureter and the ductus deferens, and is covered with peritoneum. It passes through the obturator foramen to leave the pelvis and enter the thigh. In the pelvis it gives off:
 - a. Iliac branches to the iliac fossa.
 - b. A vesical branch to the urinary bladder.
 - c. A pubic branch to the peritoneum on the back of the pubis, which anastomoses with the pubic branch of the inferior epigastric artery and with its fellow of the opposite side.

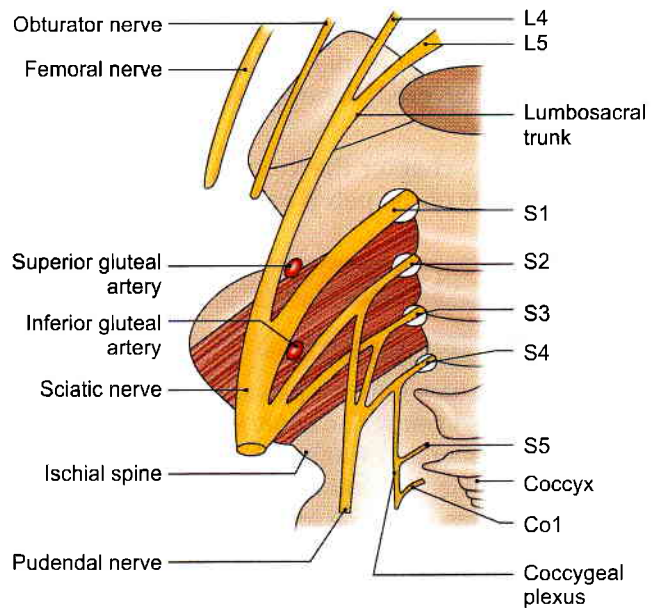


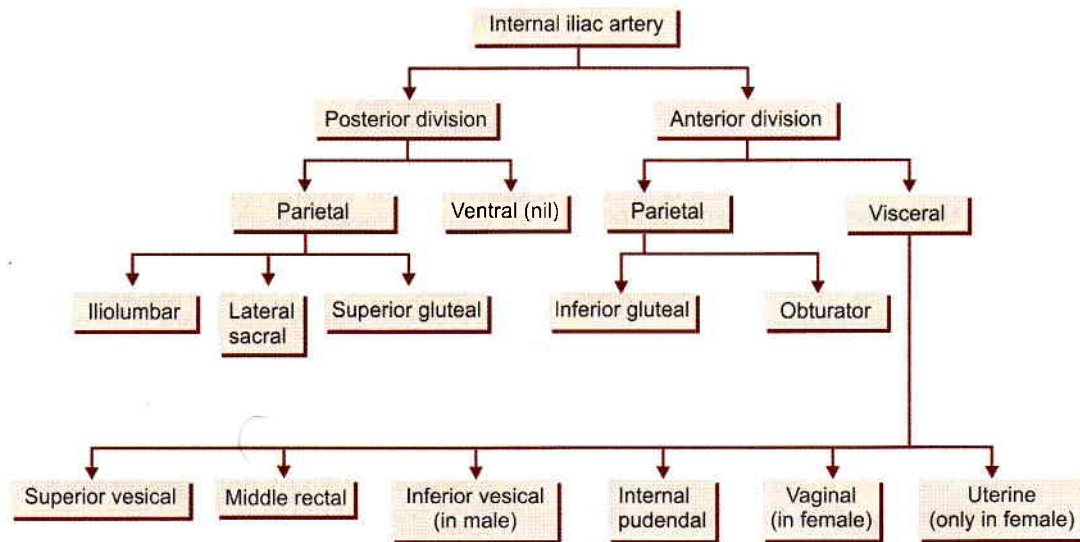
Fig. 34.2: Anterior view of the right sacral and coccygeal plexuses

Visceral Branches of Anterior Division

- 1 **Superior vesical artery:** The proximal 2.5 cm or so of the superior vesical artery represents the persistent part of the umbilical artery. It supplies many branches to the upper part of the urinary bladder. One of these branches gives off the artery to the ductus deferens.
- 2 **Middle rectal artery:** It is characterized by three features.
 - a. It is often absent, especially in females.
 - b. Very little of its blood goes to the rectum, and that too goes only to its muscle coats.
 - c. Most of its blood goes to the prostate and seminal vesicles.



Flow chart 34.1: Branches of internal Iliac artery



- 3 *Inferior vesical artery*: It supplies the trigone of the bladder, the prostate, the seminal vesicles, and the lower part of the ureter.
- 4 *Internal pudendal artery*: It is the smaller terminal branch of the anterior division of the internal iliac artery. It supplies the perineum and external genitalia. Its branches are inferior rectal, perineal, artery to bulb, urethra, deep and dorsal arteries. It is described in Chapter 28.
- 5 *Vaginal artery*: It corresponds to the inferior vesical artery of the male, and supplies the vagina, the bulb of the vestibule, the base of the urinary bladder, and the adjacent part of the rectum (see Chapter 31).
- 6 *Uterine artery*: It has a tortuous course. Crosses the ureter 2 cm lateral to cervix. Runs along side of uterus. Supplies vagina, cervix uterus, fallopian tube (see Chapter 31).

Branches of Posterior Division

- 1 *Iliolumbar artery*: It runs upwards in front of the sacroiliac joint and lumbosacral trunk, and behind the obturator nerve and external iliac vessels (Fig. 34.1). Behind the psoas major, it divides into the lumbar and iliac branches.
The *lumbar branch* represents the fifth lumbar artery, and supplies the psoas, the quadratus lumborum and the erector spinae. Its spinal branch supplies the cauda equina.
The *iliac branch* supplies the iliac fossa and the iliacus. It participates in the anastomoses around the anterior superior iliac spine.
- 2 *Lateral sacral arteries*: These are usually two in number, upper and lower. They run downwards and medially over the sacral nerves. Their branches enter the four anterior sacral foramina to supply the

contents of the sacral canal. Their terminations pass out through the posterior sacral foramina and supply the muscles and skin on the back of the sacrum (see Fig. 33.4).

- 3 *Superior gluteal artery*: It runs backwards, pierces the pelvic fascia, passes above the first sacral nerve, and leaves the pelvis through the greater sciatic foramen above the piriformis (Fig. 34.2). It supplies gluteus maximus muscle. Also takes part in anastomoses around anterior superior iliac spine and in trochanteric anastomoses to supply nearby muscles and overlying skin. For further course see Chapter 5.

INTERNAL ILIAC VEIN

It ascends posteromedial to the internal iliac artery, and joins the external iliac vein to form the common iliac vein at the pelvic brim, in front of the lower part of the sacroiliac joint. Its tributaries correspond with the branches of the artery, except for the iliolumbar vein which joins the common iliac vein. The tributaries are as follows.

Veins arising in and outside the pelvic wall

- 1 Superior gluteal is the largest tributary,
- 2 Inferior gluteal,
- 3 Internal pudendal,
- 4 Obturator, and
- 5 Lateral sacral veins.

Veins arising from the plexuses of pelvic viscera

- 1 Rectal venous plexus is drained by the superior, middle and inferior rectal veins.
- 2 Prostatic venous plexus is drained by the vesical and internal iliac veins.
- 3 Vesical venous plexus is drained by the vesical veins.



- 4 Uterine venous plexus is drained by the uterine veins.
- 5 Vaginal venous plexus is drained by the vaginal veins.

LYMPH NODES OF THE PELVIS

The pelvic lymphatics drain into the following lymph nodes, which lie along the vessels of the same name.

- 1 The *common iliac nodes* 4 to 6 receive lymphatics from the external and internal iliac nodes, and send their efferents to the lateral aortic nodes.
- 2 The *external iliac nodes* 8 to 10 receive lymphatics from the inguinal nodes, the deeper layers of the infraumbilical part of the anterior abdominal wall, the membranous urethra, the prostate, the base of the urinary bladder, the uterine cervix, and part of the vagina. Their efferents pass to the common iliac nodes. The *inferior epigastric* and *circumflex iliac nodes* are outlying members of this group.
- 3 The *internal iliac nodes* receive lymphatics from all the pelvic viscera, the deeper parts of the perineum, and muscles of the buttocks and of the back of the thigh. Their efferents pass to the common iliac nodes. The sacral and obturator nodes are outlying members of this group.

NERVES OF THE PELVIS

DISSECTION

Expose the lumbosacral trunk and ventral rami of sacral one to sacral five nerves. Lift the sacral plexus forwards and expose its terminal branches, the sciatic and pudendal nerves.

Find the nerves arising from the dorsal surface of plexus, e.g. superior gluteal, inferior gluteal, perforating cutaneous and perineal branch of fourth sacral nerve.

Trace the two branches, e.g. nerve to quadratus femoris and nerve to obturator internus arising from the pelvic surface of the plexus.

Trace the sympathetic trunks in the pelvis till these terminate in the single *ganglion impar* on the coccyx. Trace the large grey rami communicans from the ganglia to the ventral rami of the sacral nerves.

Find the inferior hypogastric plexus around the internal iliac vessels. In addition, trace the pelvic splanchnic nerves reaching the inferior hypogastric plexus from the ventral rami of second, third and fourth sacral nerves.

The nerves of the pelvis include:

- 1 Lumbosacral plexus,
- 2 Coccygeal plexus, and
- 3 Pelvic splanchnic nerves.

LUMBOSACRAL PLEXUS

Formation

The lumbosacral plexus is formed by the lumbosacral trunk and the ventral rami of the first to third sacral nerves, and part of the fourth sacral nerve (Fig. 34.2).

The *lumbosacral trunk* is formed by the descending branch of the ventral ramus of nerve L4 and the whole of ventral ramus L5. The trunk descends over the ala of the sacrum, crosses the pelvic brim in front of the sacroiliac joint, and joins nerve S1 (see Fig. 33.4).

Nerves S1 and S2 are large. The other sacral nerves become progressively smaller in size.

Relations

- 1 The lumbosacral trunk and ramus S1 are separated from each other by the superior gluteal vessels. Both lie in front of the sacroiliac joint before passing on to the surface of the piriformis. Thus both may be involved in pathological conditions of the joint (Fig. 34.2).
- 2 Ramus S1 is separated from ramus S2 by the inferior gluteal vessels.
- 3 Rami S2, S3 and a part of S4 lie between the anterior surface of the piriformis and the pelvic fascia.
- 4 The main plexus lies in front of the piriformis deep to the pelvic fascia, and behind the internal iliac vessels and the ureter (Fig. 34.4).

Layout of Connections and Branches

- 1 Each ventral ramus receives a *grey ramus communicans* from the sympathetic chain at the anterior sacral foramen.
- 2 Before uniting to form the plexus, the ventral rami give off:
 - a. Twigs to the piriformis (S1, S2).
 - b. Twigs to the levator ani, the coccygeus and the sphincter ani externus (S4).
 - c. Pelvic splanchnic nerves (S2, S3, S4).
- 3 The plexus gives rise to two main branches namely, the sciatic and pudendal nerves, concerned respectively with locomotion and reproduction.
- 4 As in other plexuses, the rami tend to divide into ventral and dorsal divisions which supply the corresponding aspects of the lower limb and trunk. In general, the *dorsal divisions* supply the extensors and the abductors, and the *ventral divisions* supply the flexors and the adductors, of the limb.

Branches

Branches derived from both dorsal and ventral divisions are as follows.

- 1 *Sciatic nerve*: The common peroneal nerve component arises from dorsal divisions of L4, L5, S1, S2. It supplies evertors of foot and dorsiflexors of ankle



joint. The tibial nerve component arises from ventral divisions of L4, L5, S1, S2, S3. It supplies the hamstring muscles, all muscles of calf and intrinsic muscles of the sole. This nerve is described in Chapter 7.

- 2 *Posterior cutaneous nerve of thigh*: Dorsal divisions of S1, S2 and ventral divisions of S2, S3 (see Chapter 7).

Branches from Dorsal Divisions

- 1 Superior gluteal nerve: L4, L5, S1 (see Fig. 5.14).
- 2 Inferior gluteal nerve: L5, S1, S2 (see Fig. 5.14).
- 3 Nerve to piriformis: S1, S2.
- 4 Perforating cutaneous nerve: S2, S3.

Branches from Ventral Division

- 1 Nerve to quadratus femoris: L4, L5, S1.
- 2 Nerve to obturator internus: L5, S1, S2.
- 3 Pudendal nerve: S2, S3, S4: Supplies sphincter ani externus and all muscles in urogenital triangles.
- 4 Muscular branches to the levator ani, the coccygeus and the sphincter ani externus, including perineal branch of nerve S4.
- 5 Pelvic splanchnic nerves: S2, S3, S4.

Muscular Branches

Nerves to the levator ani or iliococcygeus part and the coccygeus or ischiococcygeus arise from nerve S4 and enter their pelvic surfaces.

The nerve to the middle part of the sphincter ani externus is called the *perineal branch of the fourth sacral nerve*. It runs forwards on the coccygeus and reaches the ischioanal fossa by passing between the coccygeus and the levator ani. In addition to the lower end of external sphincter, it supplies the skin between the anus and the coccyx.

COCCYGEAL PLEXUS

- 1 It is formed by the ventral rami of spinal nerves S4 (descending branch), S5 and the coccygeal nerve (Fig. 34.2).
- 2 The three nerves join on the pelvic surface of the coccygeus to form a small plexus known as the coccygeal plexus.
- 3 The plexus gives off the anococcygeal nerves, which pierce the sacrotuberous ligament and supply the skin in the region of the coccyx.

CLINICAL ANATOMY

The lumbosacral trunk (L4, L5) and the ventral ramus of nerve S1 cross the pelvic surface of the joint and may be involved in disease of the joint, causing pain in the area of their distribution below the knee. L4 supplies medial aspect of leg and sole. S1 supplies lateral aspect of sole refer (see Fig. 10.2).

PELVIC AUTONOMIC NERVES

Pelvic Sympathetic System

The pelvic part of the sympathetic chain runs downwards and slightly medially over the body of sacrum, and then along the medial margins of the anterior sacral foramina. The two chains unite in front of the coccyx to form a small *ganglion impar*. The chain bears four sacral ganglia on each side and the single ganglion impar in the central part.

The *branches* of the chain are:

- a. Grey rami communicans to all sacral and coccygeal ventral rami.
- b. Branches to the inferior hypogastric plexus from the upper ganglia.
- c. Branches to the median sacral artery from the lower ganglia.
- d. Branches to the rectum from the lower ganglia.
- e. Branches to the glomus coccygeum (see Fig. 29.11) from the ganglion impar.

The *inferior hypogastric plexus* (see Chapter 27) one on each side of the rectum and other pelvic viscera is formed by the corresponding hypogastric nerve from the superior hypogastric plexus; branches from the upper ganglia of the sacral sympathetic chain; and the pelvic splanchnic nerves. Branches of the plexus accompany the visceral branches of the internal iliac artery; and are named:

- a. Rectal plexus,
- b. Vesical plexus,
- c. Prostatic plexus, and
- d. Uterovaginal plexus.

Pelvic Splanchnic Nerves

Nervi Erigentes

The *nervi erigentes* represent the sacral outflow of the parasympathetic nervous system. The nerves arise as fine filaments from the ventral rami of S2, S3 and S4. They join the inferior hypogastric plexus and are distributed to the pelvic organs. Some parasympathetic fibres ascend with the hypogastric nerve to the superior hypogastric plexus and thence to the inferior mesenteric plexus. Others ascend independently and directly to the part of the colon derived from the hindgut.

PELVIC FASCIA AND MUSCLES

PELVIC FASCIA

The pelvic fascia is distributed in the extraperitoneal space of the pelvis. It covers the lateral pelvic wall and the pelvic floor called *parietal pelvic fascia*; and also surrounds the pelvic viscera called *visceral pelvic fascia*.

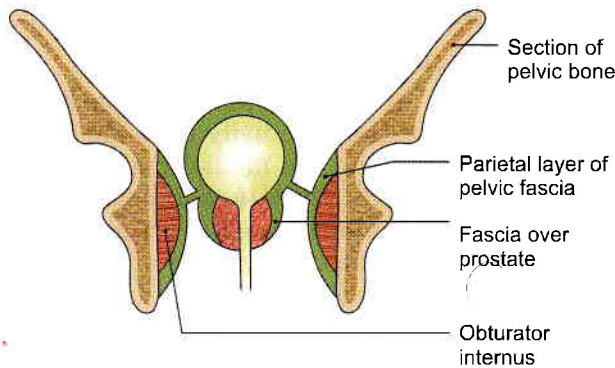


Fig. 34.3: Pelvic fascia

Principles Governing its Distribution

- 1 The fascia is dense and membranous over nonexpansile structures, e.g. lateral pelvic wall, but is only loosely arranged over expansile structures, e.g. viscera, and over mobile structures, e.g. the pelvic floor (Fig. 34.3).
- 2 As a rule the fascia does not extend over bare bones; at the margins of the muscles it fuses with the periosteum. In this respect, the fascia of Waldeyer is an exception, which extends from the sacrum to the ampulla of rectum.

Parietal Fascia of the Lateral Pelvic Wall

- 1 The fascia covering the muscles of the lateral pelvic wall is condensed to form thick and strong membranes. It is closely adherent to the walls of the pelvic cavity. It is attached along a line from iliopectineal line to the inferior border of pubic bone.
- 2 The fascia covering the obturator internus is called the *obturator fascia*. It shows a linear thickening or tendinous arch for the origin of the levator ani. Below this origin it is closely related to the lunate fascia and to the pudendal canal.
- 3 The *fascia covering the piriformis* is thin. The nerves over the piriformis, i.e. the sacral plexus lie external to the pelvic fascia and, therefore, do not pierce the fascia while passing out of the pelvis. The gluteal vessels, on the other hand, lie internal to the pelvic fascia and, therefore, have to pierce the fascia while passing out of the pelvis (Fig. 34.4).

Parietal Fascia of the Pelvic Floor

- 1 The pelvic fascia covers both the surfaces of the pelvic diaphragm, forming the superior and inferior layers. The inferior fascia is also known as the *anal fascia*.
- 2 In general, the fascia of the pelvic floor is loosely arranged between the peritoneum and the pelvic floor, forming a dead space for distension of the bladder, the rectum, the uterus and the vagina. Because of the loose nature of the fascia infections can spread rapidly within it.

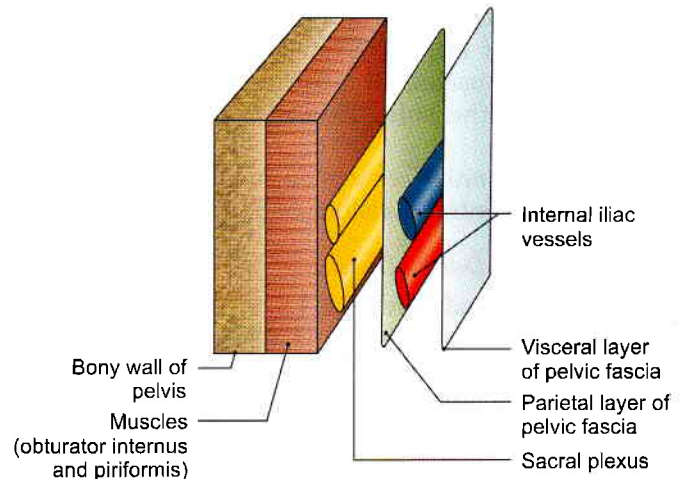


Fig. 34.4: Arrangement of structures on the walls of true pelvis

- 3 However, the fascia is condensed at places to form fibromuscular ligaments which support the pelvic viscera. The various ligaments are dealt with individual viscera including the prostate, bladder, uterus and the rectum.

Visceral Pelvic Fascia

This fascia surrounds the extraperitoneal parts of the pelvic viscera. It is loose and cellular around distensible organs like bladder, rectum and vagina, but is dense around non-distensible organs, like the prostate. The visceral layer is attached along a line extending from the middle of back of pubis to the ischial spine.

PELVIC MUSCLES

DISSECTION

Muscles of lesser pelvis

Identify the origin of piriformis from the ventral surface of the sacrum. Trace it through the greater sciatic foramen to its insertion into the upper border of greater trochanter of femur.

Feel the ischial spine and trace the fibres of coccygeus and levator ani that arise from it. Trace the origin of levator ani from thickened fascia, i.e. tendinous arch over the middle of obturator internus muscle till the back of body of the pubis. Note that the right and left sheet like levator ani muscles are united and the muscles are inserted into central perineal tendon or perineal body, anal canal, anococcygeal ligament.

Detach the origin of levator ani from obturator fascia. While removing obturator fascia identify pudendal canal with its contents in the lower part of the fascia.

Trace the tendon of obturator internus muscle. This tendon along with superior and inferior gemelli muscles leaves through the lesser sciatic foramen to be inserted into the medial surface of greater trochanter of femur.



Features

The pelvic muscles include two groups.

- 1 Piriformis and obturator internus, which are short lateral rotators of the hip joint and are described with the muscles of the lower limb.
- 2 Levator ani and coccygeus, which with the corresponding muscles of the opposite side, form the pelvic diaphragm. The diaphragm separates the pelvis from the perineum (Figs 34.5a and b).

The levator ani and coccygeus may be regarded as one morphological entity, divisible from before backwards into the pubococcygeus, the iliococcygeus and the ischiococcygeus or coccygeus. They have a continuous linear origin from the pelvic surface of the body of the pubis, the obturator fascia or white line or tendinous arch and the ischial spine. The muscle fibres slope downwards and backwards to the midline, making a gutter-shaped pelvic floor. These muscles are described below.

THE LEVATOR ANI

The muscle is divisible into a pubococcygeus part, an iliococcygeus part and a ischiococcygeus part (Fig. 34.6).

Pubococcygeus Part

- 1 The anterior fibres of this part arise from the medial part of the pelvic surface of the body of the pubis. In the male these fibres closely surround the prostate and constitute the *levator prostatae*. In the female these fibres surround the vagina and form the *sphincter vaginae*. In both cases the anterior fibres are inserted into the perineal body.
- 2 The middle fibres constitute the puborectalis. These arise from the lateral part of the pelvic surface of the body of the pubis. They partly form a loop or sling around the anorectal junction; and are partly continuous with the longitudinal muscle coat of the

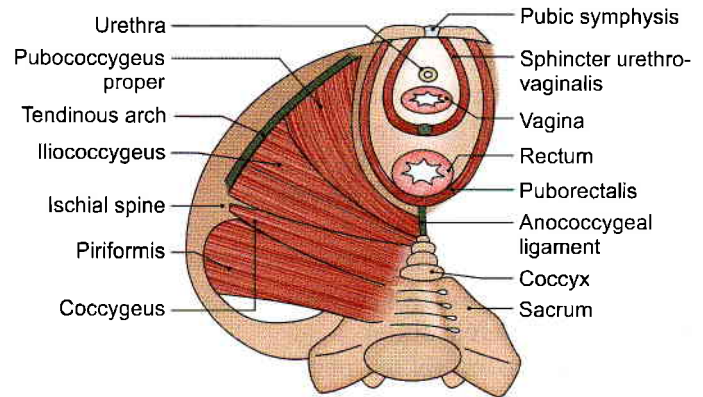


Fig. 34.6: The levator ani, the coccygeus and the piriformis in a female

rectum. In female the anterior portion of puborectalis is thinner and shorter (*see* Fig. 33.12b).

- 3 The posterior fibres of the pubococcygeus arise from the anterior half of the white line on the obturator fascia. These get attached to anococcygeal ligament and tip of coccyx.

Iliococcygeus Part

The fibres of this part arise from:

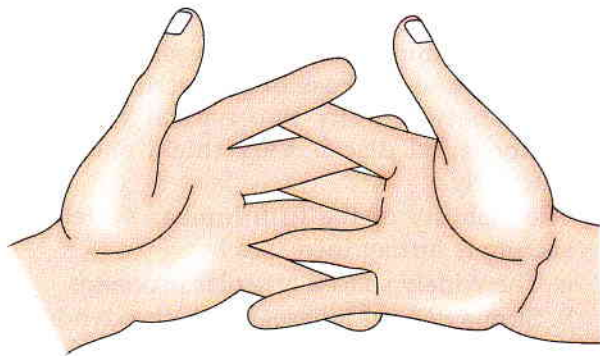
- 1 The posterior half of the white line on the obturator fascia.
- 2 The pelvic surface of the ischial spine. They are inserted into the anococcygeal ligament and into the side of the last two pieces of coccyx.

Coccygeus

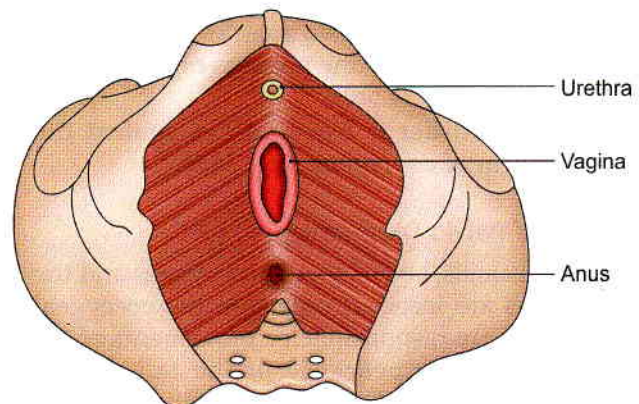
This muscle represents the posterior or ischiococcygeus part of the pelvic diaphragm. It is triangular in shape. It is partly muscular and partly tendinous.

Its fibres arise from:

- a. The pelvic surface of the ischial spine.
- b. The sacrospinous ligament. It is inserted into the side of the coccyx, and into the fifth sacral vertebra.



(a)



(b)

Figs 34.5a and b: (a) Interlocking hands represent the enterlocking fibres of two levator ani muscles, and (b) openings in the pelvic diaphragm in female



Nerve Supply

The levator ani is supplied by:

- 1 A branch from the fourth sacral nerve.
- 2 A branch from the inferior rectal nerve.

The coccygeus is supplied by a branch derived from the fourth and fifth sacral nerves.

Actions of Levators Ani and Coccygeus

- 1 The levatores ani and coccygeus close the posterior part of the pelvic outlet.
- 2 The levators ani fix the perineal body and support the pelvic viscera.
- 3 During coughing, sneezing, lifting and other muscular efforts, the levators ani and coccygei counteract or resist increased intra-abdominal pressure and help to maintain continence of the bladder and the rectum.

In micturition, defaecation and parturition, a particular pelvic outlet is open, but contraction of fibres around other openings resists increased intra-abdominal pressure and prevents any prolapse through the pelvic floor. The increase in the intra-abdominal pressure is momentary in coughing and sneezing and is more prolonged in yawning, micturition, defaecation and lifting heavy weights. It is most prolonged and intense in second stage of labour.

- 4 The coccygeus pulls forwards and support the coccyx, after it has been pressed backwards during defaecation, parturition or childbirth.

Relations of the Levator Ani

- 1 The superior or pelvic surface is covered with pelvic fascia which separates it from the bladder, prostate, rectum and the peritoneum.
- 2 The inferior or perineal surface is covered with anal fascia and forms the medial boundary of the ischioanal fossa (see Fig. 28.7).
- 3 The anterior borders of the two muscles are separated by a triangular space for the passage of the urethra and the vagina (Fig. 34.5b).
- 4 The posterior border is free and lies against the anterior margin of coccygeus (Fig. 34.6).

Morphology of Pelvic Diaphragm

- 1 In lower mammals, both the pubococcygeus and the iliococcygeus are inserted only into the coccygeal vertebrae and are responsible for movements of the tail. With the disappearance of the tail during evolution, the muscles have been modified to form the pelvic diaphragm which supports the viscera. Such support became necessary with the adoption of the erect posture by man.

- 2 In lower mammals, the levator ani arises from the pelvic brim. In man, the origin has shifted down to the side wall of the pelvis.
- 3 The coccygeus muscle corresponds exactly with the sacrospinous ligament, which is a degenerated part of the aponeurosis of this muscle. The two are inversely proportional in their development.

CLINICAL ANATOMY

The muscles of the pelvic floor may be injured during parturition. When the perineal body is torn, and has not been repaired satisfactorily, the contraction of anterior fibres of the levator ani increases the normal gap in the pelvic floor, instead of decreasing it. This results in prolapse of the uterus.

JOINTS OF PELVIS

DISSECTION

Joints

Remove the remains of any muscle of the back or thoracolumbar fascia. Identify the iliolumbar and dorsal sacroiliac ligaments. Remove the dorsal sacroiliac ligament to identify the deeply placed interosseous sacroiliac ligament. Divide this interosseous ligament and open the joint from the posterior aspect.

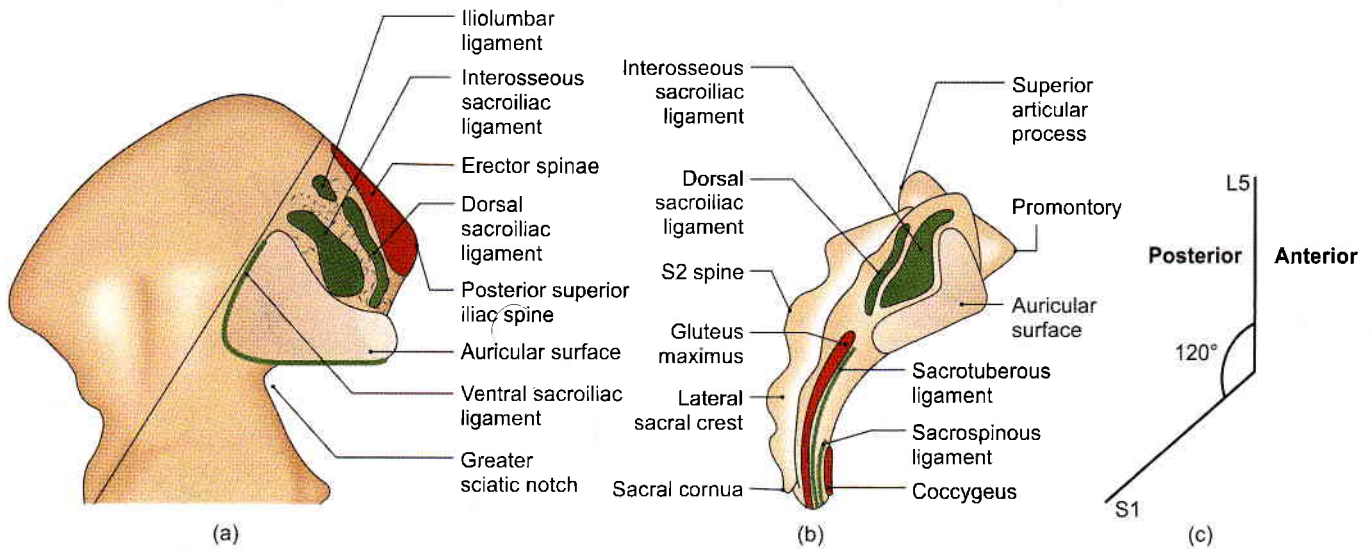
Define the attachments of ventral sacroiliac ligament. Cut through this thin ligament to open the sacroiliac joint.

The following parts are considered.

- 1 Lumbosacral joints,
- 2 Sacrococcygeal and intercoccygeal joints,
- 3 Sacroiliac joints with vertebropelvic ligaments,
- 4 Pubic symphysis; followed by
- 5 The mechanism of pelvis.

LUMBOSACRAL JOINTS

- 1 The joints and ligaments between the fifth lumbar vertebra and the base of the sacrum are similar to those between any two typical vertebrae. The lumbosacral disc is very thick, and is thickest anteriorly.
- 2 The stability of the fifth lumbar vertebra on the sacrum is further increased by:
 - a. The widely spaced articular processes.
 - b. Strong *iliolumbar ligament* which extends from the stout transverse process of the fifth lumbar vertebra to the iliac crest. The ligament fans out inferiorly to be attached to the lateral part of the ala of the sacrum as the lumbosacral ligament (Figs 34.7a and b).



Figs 34.7a to c: Articular surfaces of the right sacroiliac joint. (a) Medial view of the upper part of the right hip bone, (b) right lateral view of the sacrum, and (c) lumbosacral angle is 120° opening backwards

- 3 The body of the fifth lumbar vertebra makes an angle of about 120 degrees opens backwards with the sacrum. This is the lumbosacral or sacrovertebral angle, and opens backwards (Fig. 34.7c).
- 4 This region is subject to a number of variations which give rise to symptoms of backache. These are:
 - a. Sacralization of the fifth lumbar vertebra.
 - b. Lumbralization of the first sacral vertebra.
 - c. Spina bifida.
 - d. Spondylolisthesis, etc.

SACROCCOCCYGEAL AND INTERCOCCYGEAL JOINTS

The *sacroccocygeal joint* is a secondary cartilaginous joint between the apex of the sacrum and the base of the coccyx. The bones are united by:

- 1 A thin intervertebral disc.
- 2 Ventral sacroccocygeal ligament corresponding to the anterior longitudinal ligament.
- 3 Deep dorsal sacroccocygeal ligament corresponding to the posterior longitudinal ligament.
- 4 Superficial dorsal sacroccocygeal ligament, completing the lower part of the sacral canal.
- 5 Lateral sacroccocygeal ligament corresponding to the intertransverse ligament and completing the foramen for the fifth sacral nerve.
- 6 Intercornual ligament, connecting the cornua of the sacrum and the coccyx. In old age the joint is obliterated and the ligaments are ossified. Sometimes the joint is synovial, and the coccyx is freely mobile.

The *intercoccygeal joints* are present only in young subjects. Fusion of the segments begins at the age of 20 years and is complete by about 30 years.

SACROILIAC JOINT

Type

This is a synovial joint of the plane variety. The articular surfaces are flat in infants; but in adults show interlocking irregularities which discourage movements at this joint.

Articular Surface

The joint is formed between:

- 1 Auricular surface of the sacrum, which is covered with fibrocartilage.
- 2 Auricular surface of the ilium, which is covered with hyaline cartilage (Fig. 34.7).

Ligaments

- 1 The *fibrous capsule* is attached close to the margins of the articular surfaces. It is lined by synovial membrane (Fig. 34.8).
- 2 The *ventral sacroiliac ligament* is a thickening of the anterior and inferior parts of the fibrous capsule. Its lower part is attached to the preauricular sulcus.
- 3 The *interosseous sacroiliac ligament* is massive and very strong, forming the chief bond of union between the sacrum and the ilium. It connects the wide, rough areas adjoining the concave margins of the auricular surfaces, and is covered by the dorsal sacroiliac ligament.
- 4 The dorsal sacroiliac ligament covers the interosseous sacroiliac ligament, from which it is separated by the dorsal rami of the sacral spinal nerves and vessels.

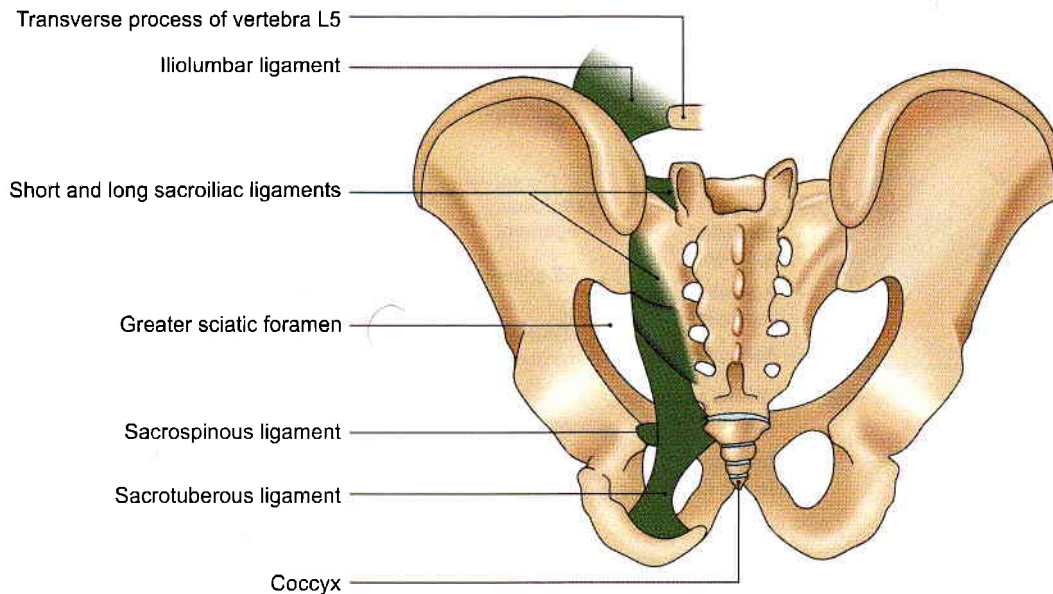


Fig. 34.8: Ligaments of the pelvis as seen from behind

Dorsal sacroiliac consists of:

- a. Short transverse fibres or *short posterior sacroiliac ligament* passing from the ilium to the transverse tubercles of the first two sacral pieces.
 - b. A long, more vertical, band or *long posterior sacroiliac ligament* passing from the posterior superior iliac spine to the transverse tubercles of the third and fourth sacral pieces; it is continuous laterally with medial edge of the sacrotuberous ligament.
- 5 The *vertebro pelvic ligaments* include the iliolumbar, sacrotuberous and sacrospinous ligaments. These are accessory ligaments to the sacroiliac joint and are important in maintaining its stability.
- a. The *iliolumbar ligament* is a strong, triangular ligament, extending from the thick transverse process of the fifth lumbar vertebra to the posterior part of the inner lip of the iliac crest. It is continuous with the middle and anterior layers of the thoracolumbar fascia and gives partial origin to the quadratus lumborum. It is covered anteriorly by the psoas, and posteriorly by the erector spinae. It prevents anteroinferior slipping of the fifth lumbar vertebra under the influence of body weight, and also prevents forward movement at the sacroiliac joint (Fig. 34.8).
 - b. The *sacrotuberous ligament* is a long and strong band which forms parts of the boundaries of the pelvic outlet and of the sciatic foramina. Its superomedial end or base is wide. It is attached to the posterior superior and posterior inferior iliac spines, the lower transverse tubercles of the sacrum, the lateral margin of the lower part of the sacrum and the upper part of the coccyx. The inferolateral end is narrow. It is attached to the medial margin of the ischial tuberosity. A part of

it that extends along the ramus of the ischium is called the falciform process. The ligament is covered by and also gives partial origin to gluteus maximus, and is pierced by the perforating cutaneous nerve, the fifth sacral and first coccygeal nerves, and branches of the coccygeal plexus (see Figs 5.14 and 34.8).

- c. The *sacrospinous ligament* is a thin, triangular ligament, which lies deep to sacrotuberous ligament, and separates the greater and lesser sciatic foramina. Its base is attached to the lateral margins of the last piece of the sacrum and to the coccyx and its apex to the ischial spine. Its pelvic surface is covered by and also gives origin to the coccygeus. Morphologically, the ligament is a degenerated part of the coccygeus (Fig. 34.8).

The sacrotuberous and sacrospinous ligaments bind the sacrum to the ischium. They oppose upward tilting of the lower end of the sacrum and therefore, downward tilting of its upper end under body weight.

Relations

Posteriorly

- 1 Joint is covered by the erector spinae, the gluteus maximus and the sacrotuberous ligament (Fig. 34.7b).
- 2 Dimple overlying the posterior superior iliac spine lies opposite the middle of joint (see Fig. 5.1).

Abdominal Surface

- 1 It is covered by the psoas and iliacus (see Fig. 2.5).
- 2 Deep to the psoas, the joint is crossed by the iliolumbar vessels and the obturator nerve (see Fig. 15.11).
- 3 Femoral nerve is separated from the joint by the iliacus muscle.



The *pelvic surface* is related to:

- 1 Lumbosacral trunk and the posterior division of the internal iliac artery.
- 2 Internal iliac vein and the anterior division of the internal iliac artery.
- 3 Superior gluteal vessels and the first sacral nerve (S1) (Fig. 34.2).
- 4 Upper part of the piriformis.

Factors Providing Stability

Stability is the primary requirement of the joint as it transmits body weight from the vertebral column to the lower limbs. Stability is maintained by a number of factors which are as follows.

- 1 Interlocking of the articular surfaces.
- 2 Thick and strong interosseous and dorsal sacroiliac ligaments play a very important role in maintaining stability (Fig. 34.7).
- 3 Vertebropelvic ligaments, i.e. iliolumbar, sacrotuberous and sacrospinous are equally important in this respect.
- 4 With advancing age, partial synostosis of the joint takes place which further reduces movements.

Blood Supply

Sacroiliac joint is supplied by twigs from all the three branches of posterior division of internal iliac artery, i.e. iliolumbar, lateral sacral and superior gluteal arteries.

Nerve Supply

The joint is supplied by the following nerves.

- 1 Superior gluteal.
- 2 Ventral rami and the lateral branches of dorsal rami of the first and second sacral nerves.

Movements

During flexion and extension of the trunk, stooping and straightening, i.e. the sacroiliac joint permits a small amount of *anteroposterior rotatory movement* around a transverse axis passing 5 to 10 cm vertically below the sacral promontory. This little movement serves the important function of *absorbing the shocks* of jumping and bearing of loads. The range of movement is increased temporarily in pregnancy in which all the ligaments of the pelvis become loose, under the influence of hormones, to facilitate delivery of the foetus.

PUBIC SYMPHYSIS

This is a secondary cartilaginous joint between the bodies of the right and left pubic bones. Each articular surface is covered with a thin layer of hyaline cartilage. The fibrocartilaginous disc is reinforced by surrounding ligamentous fibres. The fibres are thickest inferiorly where they form the *arcuate pubic ligament*. Anteriorly, the fibres form the *anterior pubic ligament* (see Fig. 15.14a).

The pubic symphysis permits slight movement between the hip bones, which helps in absorbing shocks. The range of movement is increased during pregnancy.

THE MECHANISM OF PELVIS

The most important mechanical function of the pelvis is to transmit the weight of trunk to the lower limb. The weight passes mainly through the alae of sacrum and through the thick part of hip bone lying between sacroiliac joint and acetabulum.

Theoretically, the weight falling on the lumbosacral joint is divided into two components.

- a. *One component of the force* is expanded in trying to drive the sacrum downwards and backwards between the iliac bones. This is resisted by the ligaments of pubic symphysis.
- b. *Second component of the force* tries to push the upper end of sacrum downwards and forwards towards the pelvic cavity. This is resisted by the middle segment of the sacroiliac joint, where the auricular surface of the sacrum is wider posteriorly, i.e. wedge-shaped and is concave for interlocking with the reciprocal surface of the ilium.

Because of the poor wedging and poor locking of the articular surfaces in the anterior and posterior segments of the sacroiliac joint, the sacrum is forced to rotate under the influence of body weight. In this rotation, the anterior segment is tilted downwards and the posterior segment upwards. The downward tilt of the anterior segment is prevented chiefly by the dorsal and interosseous sacroiliac ligaments; and the upward tilt of the posterior segment is prevented chiefly by the sacrotuberous and sacrospinous ligaments.

During all these movements the separation of iliac bones is resisted by sacroiliac and iliolumbar ligaments, and the ligaments of pubic symphysis.

CLINICAL ANATOMY

- During pregnancy the pelvic joints and ligaments are relaxed, so that the range of movement is increased and locking mechanism becomes less efficient. This naturally puts greater strain on the ligaments. The *sacroiliac strain* thus produced may persist even after pregnancy.

After childbirth the ligaments are tightened up again, so that the locking mechanism returns to its original efficiency. Sometimes locking occurs in the rotated position of the hip bones adopted during pregnancy. This results in *subluxation* of the joint, causing low backache due to strain on ligaments.

- The *diseases of the lumbosacral and sacroiliac joints can be differentiated* by the following tests.
 - a. In lumbosacral lesions, the tenderness is present over the spines and above the dimple of posterior



superior iliac spine (over the iliolumbar ligament); in sacroiliac lesions, the tenderness is located inferomedial to the dimple (over the posterior sacroiliac ligament) (Fig. 34.9).

- b. In lumbosacral disease, the movements of vertebral column are restricted in all directions; in sacroiliac disease, the movements are free, except for extreme forward bending, when the tension on hamstrings causes backward rotation of the hip bones, opposite to that of sacrum, producing pain in a diseased joint.

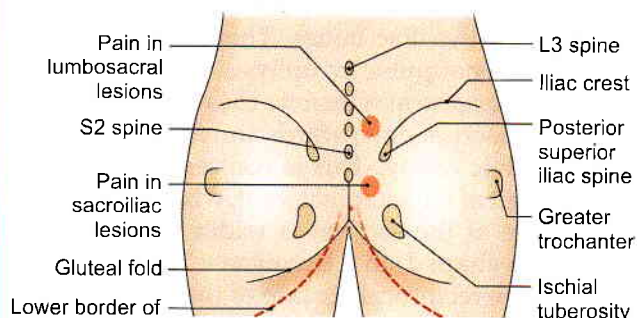


Fig. 34.9: Sites of tenderness in lumbosacral and sacroiliac lesions

FACTS TO REMEMBER

- Inferior gluteal artery is the largest branch of anterior division of internal iliac artery. It is also part of the axial artery of lower limb.
- Pelvic viscera are supported by pelvic diaphragm formed by levator ani and coccygeus muscles in the large posterior part of pelvic outlet. In its small anterior part, the muscles of urogenital region support the viscera.

- Inferior vesical is replaced by vaginal artery in female.
- Uterine artery is the additional artery exclusively in the female.
- Ventral ramus of L4 nerve takes part both in formation of lumbar plexus as well as sacral plexus and is called *nervi furcalis*.
- Nerves forming sacral plexus lie outside the parietal layer of pelvic fascia. Blood vessels of the pelvis lie inside the parietal layer.
- Interosseous sacroiliac ligament is the strongest ligament of the body.
- The free anastomoses between superior rectal vein of portal and the middle and inferior rectal veins of the caval system explain the metastases in the liver from cancers of the genital organs.
- The sensory nerve supply of the ovary and fallopian tube is from T10–T12 nerves.

CLINICOANATOMICAL PROBLEM

An elderly person was hit by a speeding car. As he fell down, he was run over by the vehicle. He was taken to the hospital.

- Which bones are likely to be fractured?
- What structures form the pelvic ring?
- Which viscera are likely to be injured?
- What type of joints are pubic symphysis and sacroiliac joints?

Ans:

- Pubic bone of one side is fractured and sacroiliac joint of the other side is dislocated.
- Pelvic ring comprises of pubic rami, acetabulum, ischium, ilium and sacrum.
- Urinary bladder is likely to be injured.
- Pubic symphysis is secondary cartilaginous joint and sacroiliac joint is plane synovial joint.

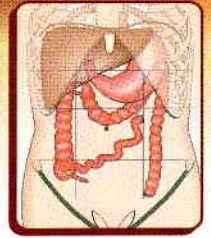
MULTIPLE CHOICE QUESTIONS

- Following are the branches of anterior division of the internal iliac artery *except*:
a. Superior vesical b. Inferior vesical
c. External pudendal d. Internal pudendal
- Following are the branches of posterior division of internal iliac artery *except*:
a. Iliolumbar b. Two lateral sacral
c. Superior gluteal d. Inferior gluteal
- Branches of anterior division of internal iliac artery in female are as follows *except*:
a. Obturator
b. Uterine
c. Vaginal
d. Inferior vesical
- Nervi erigentes arises from:
a. Ventral rami of S2, S3, S4 segments
b. Ventral rami of S2, S3, S4 and S5 segments
c. Ventral rami of S1, S2, S3 segments
d. Dorsal rami of S2, S3, S4 segments
- Parts of levator ani are as follows *except*:
a. Pubococcygeus b. Iliococcygeus
c. Ischiococcygeus d. External anal sphincter

ANSWERS

1. c 2. d 3. d 4. a 5. d

Surface Marking of Abdomen and Pelvis



It is easy to hate but it is healthy to love
—S Radhakrishnan

PLANES AND REGIONS OF THE ABDOMEN

Two horizontal (transpyloric and transtubercular) and two vertical (right and left lateral) planes divide the abdomen into nine regions (Fig. 35.1). These are described in Chapter 18.

SURFACE MARKING

Viscera

Spleen

- 1 It is marked on the left side of the back, with its long axis corresponding with that of the 10th rib.
- 2 The upper border corresponds to the upper border of the 9th rib, and the lower border to the lower border of the 11th rib (Fig. 35.2).
- 3 The medial end lies 4 to 5 cm from the posterior midline; and the lateral end on the left midaxillary line.

Stomach

- 1 **Cardiac orifice:** It is marked by two short parallel lines 2 cm apart, directed downwards and to the left on 7th costal cartilage, 2.5 cm to the left of median plane (Fig. 35.3).

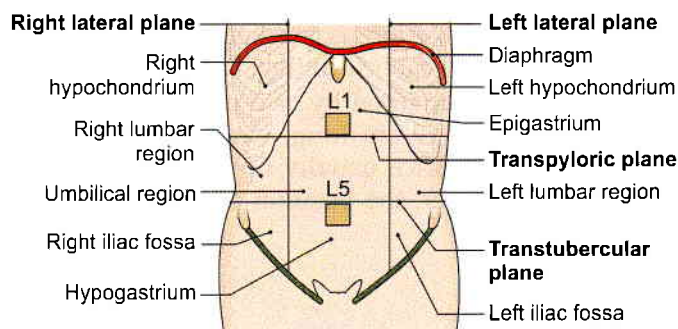


Fig. 35.1: Surface marking of regions of the abdomen

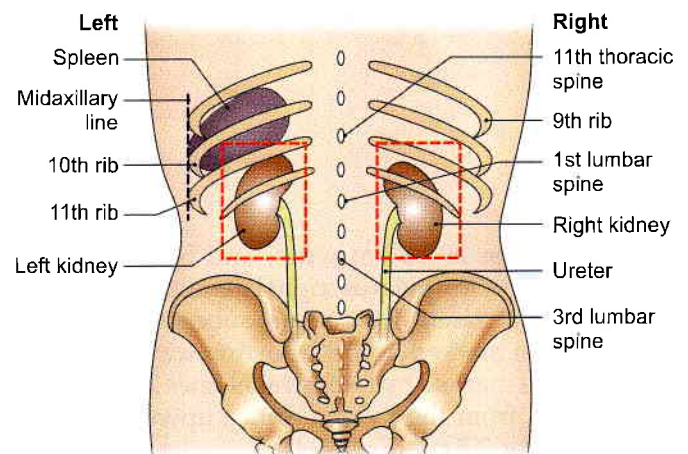


Fig. 35.2: Position of spleen, kidney and ureter from the posterior aspect

- 2 **Pyloric orifice:** It is marked by two short parallel lines 2 cm apart, directed upwards and to the right, on transpyloric plane, 1.2 cm to the right of the median plane.
- 3 **Lesser curvature:** It is marked by joining the right margin of the cardiac orifice with upper margin of the pyloric orifice by a J-shaped curved line. The lowest point of this line reaches a little below the transpyloric plane.
- 4 **Fundus:** This is marked by a line convex upwards drawn from the left margin of the cardiac orifice to highest point in the left 5th intercostal space just below the nipple.
- 5 **Greater curvature:** This is marked by a curved line convex to the left and downwards, drawn from the fundus to the lower margin of the pyloric orifice. It cuts the left costal margin between the tips of the 9th and 10th costal cartilages and extends down to the subcostal plane, i.e. level of lumbar 3 vertebra.

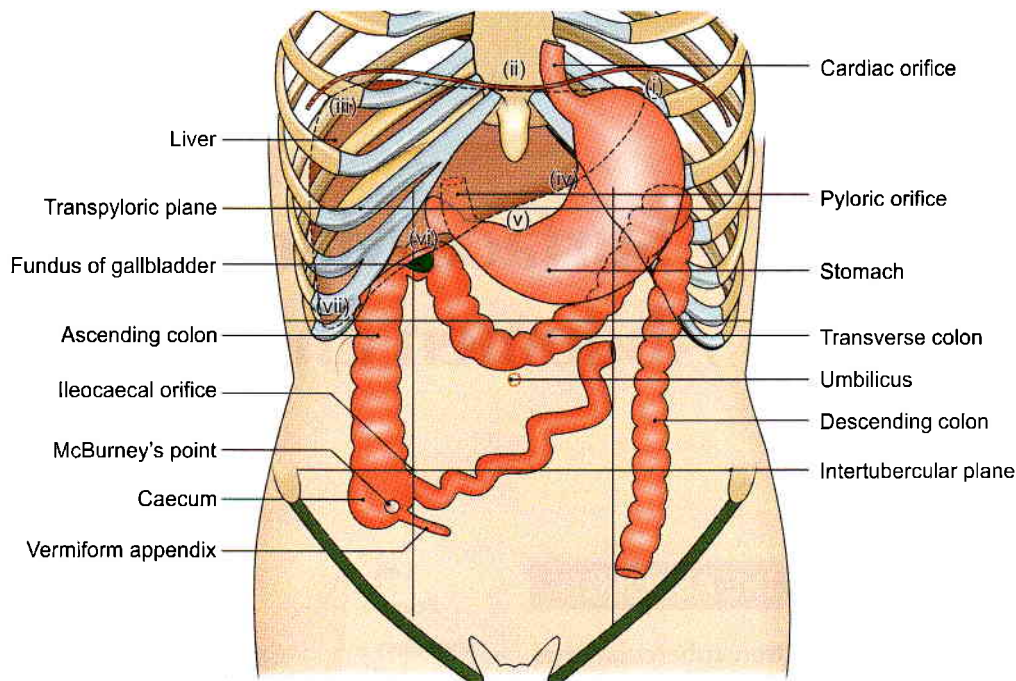


Fig. 35.3: Surface marking of some abdominal organs

Duodenum

The duodenum is 2.5 cm wide, and lies above the umbilicus. Mark the pylorus, right lateral vertical plane, median plane, transpyloric plane, subcostal plane. Its four parts are marked in the following way.

- 1 *First part* is marked by two parallel lines 2.5 cm apart extending from the pyloric orifice upwards and to the right for 2.5 cm (Fig. 35.4).
- 2 *Second part* is marked by similar lines on the right lateral vertical plane extending from the end of the first part downwards for 7.5 cm.
- 3 *Third part* is marked by two transverse parallel lines 2.5 cm apart on the subcostal plane, extending from the lower end of the second part towards the left for

10 cm. It crosses the median plane above the umbilicus.

- 4 *Fourth part* is marked by two lines extending from the left end of the third part to the duodenojejunal flexure which lies 1 cm below the transpyloric plane, and 3 cm to the left of the median plane. This part is 2.5 cm long.

Caecum

The caecum is marked in the right iliac fossa between inguinal ligament, right lateral plane and intertubercular plane. It is about 6 cm long and 7.5 cm broad. Its axis is directed downwards and slightly medially (Fig. 35.3).

Ileocaecal Orifice or Valve

Ileocaecal orifice is marked on the point of intersection of the right lateral and transtuberular planes (Fig. 35.3).

Appendix

- 1 The *appendicular orifice* is marked at a point 2 cm below the ileocaecal orifice (Fig. 35.3).
- 2 The *appendix* is marked by two parallel lines 1 cm apart and 7 to 10 cm long, extending from the appendicular orifice usually upwards behind the caecum. However, the position of the appendix is highly variable.

Ascending Colon

Ascending colon is marked by two parallel lines 5 cm apart, immediately to the right of the right lateral

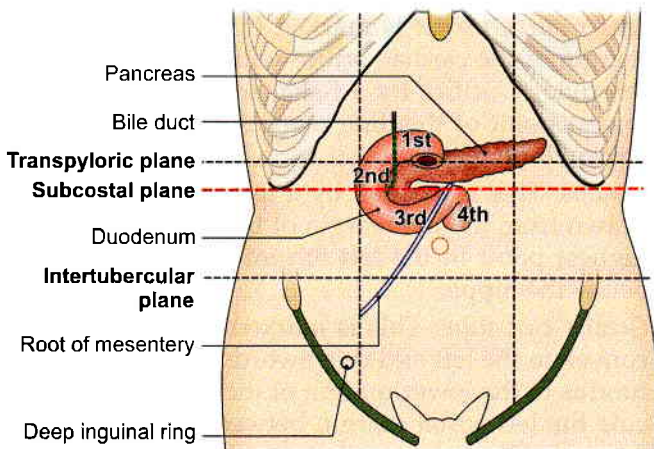


Fig. 35.4: Position of duodenum, pancreas, root of mesentery



vertical plane, from the level of the intertubercular plane (upper end of caecum) to the upper part of the 9th costal cartilage (right colic flexure) (Fig. 35.3).

Transverse Colon

Transverse colon is marked by two parallel lines 5 cm apart. It begins at the upper part of the 9th costal cartilage (right colic flexure), runs downwards and medially to the umbilicus, and then upwards and laterally, crossing the transpyloric plane and also the left lateral vertical plane, to end at the 8th costal cartilage (left colic flexure) (Fig. 35.3).

Descending Colon

Descending colon is marked by two parallel lines 2.5 cm apart. It begins at the 8th costal cartilage (left colic flexure), runs downward immediately lateral to the left lateral vertical plane, and ends at the fold of the groin (inguinal ligament) (Fig. 35.3).

Rectum and Anal Canal

Rectum and anal canal are marked on the back by drawing two lines joining the posterior superior iliac spines to the anus. The lower parts of these lines (from 1 cm below the second sacral spine) represent the rectum and anal canal.

Liver

In surface projection from anterior aspect the liver is triangular in shape when seen from the front.

Planes to be drawn:

- Right midclavicular line
- Left midclavicular line
- Median line
- Transpyloric plane
- Subcostal plane

- a. The *upper border* (Fig. 35.3) is marked by joining the following points:
 - First point (i) in the left 5th intercostal space below and medial to left nipple.
 - Second point (ii) at the xiphisternal joint.
 - Third point (iii) at the upper border of the right 5th costal cartilage in the right lateral vertical plane.
- b. The *lower border* (Fig. 35.3) is marked by a curved line joining the following points.
 - First point (i) in the left 5th intercostal space below and medial to left nipple.
 - Fourth point (iv) at the tip of the 8th costal cartilage on the left costal margin.
 - Fifth point (v) at the transpyloric plane in the midline.
 - Sixth point (vi) at the tip of the 9th costal cartilage on the right costal margin.

- Seventh point (vii) 1 cm below the right costal margin at the tip of 10th costal cartilage.
- c. The *right border* is marked on the front by a curved line convex laterally, drawn from a point little below the right nipple to a point 1 cm below the right costal margin at the tip of the 10th costal cartilage (points number (iii) and (vii)).

Gallbladder

The fundus of the gallbladder (Fig. 35.3) is marked by a small convex area at the tip of right 9th costal cartilage.

Bile Duct

Bile duct is marked by a line 7.5 cm long. The line is vertical in its upper half and inclines to the right in its lower half. The line extends from a point 5 cm above the transpyloric plane and 2 cm to the right of the median plane, to the middle of the medial border of the second part of the duodenum.

Pancreas

First draw duodenum.

- 1 The *head* is marked within the concavity of the duodenum (Fig. 35.4).
- 2 The *neck* passes upwards and to the left behind the pylorus in the transpyloric plane.
- 3 The *body* is marked by two parallel lines 3 cm apart, drawn upwards and to the left for 10 cm from the neck, occupying the upper two-thirds of the space between the transpyloric and subcostal planes.

Kidney

The kidney measures 11 × 5 cm. It can be marked both on the back as well on the front.

On the back, it is marked within Morrison's parallelogram which is drawn in the following way. Two horizontal lines are drawn, one at the level of the 11th thoracic spine and the other at the level of the 3rd lumbar spine (Fig. 35.2).

On the front, the bean-shaped kidney is marked with following specifications.

- a. On the right side the *centre of the hilum* lies 5 cm from the median plane a little below the transpyloric plane; and on the left side it lies 5 cm from the median plane a little above the transpyloric plane, just medial to the tip of the 9th costal cartilage.
- b. The *upper pole* lies 4 to 5 cm from the midline, half way between the xiphisternum and the transpyloric plane (right one, a little lower).
- c. The *lower pole* lies 6 to 7 cm from the midline on the right side at the umbilical plane and on the left side at subcostal plane (Fig. 35.5).

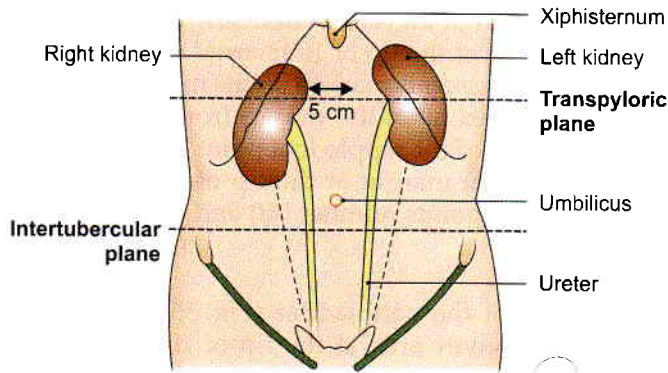


Fig. 35.5: Surface marking of kidneys from anterior aspect

Ureter

The ureter can also be marked both on the front as well as on the back.

- 1 *On the front*, it is marked by a line running downwards and slightly medially from the tip of the 9th costal cartilage to the pubic tubercle. The upper 5 cm of this line represents the renal pelvis (Fig. 35.5).
- 2 *On the back*, it is marked by a line running vertically upwards from the posterior superior iliac spine to the level of the second lumbar spine. The lower end of the renal hilum lies at this level (Fig. 35.2).

Vessels

Abdominal Aorta

Abdominal aorta is marked by two parallel lines 2 cm apart, extending from a point 2.5 cm above the transpyloric plane in the median plane to a point 1.2 cm below and to the left of the umbilicus (level of vertebra L4).

Common Iliac Artery

Common iliac artery is represented by the upper one-third of a broad line drawn from the lower end of the abdominal aorta to the midinguinal point (midpoint between ASIS and pubic symphysis).

External Iliac Artery

External iliac artery is represented by the lower two-thirds of a line drawn from the lower end of the abdominal aorta to the midinguinal point.

Coeliac Trunk and its Branches

The coeliac trunk is marked as a point 1 cm below the beginning of the abdominal aorta (Fig. 35.6).

The *left gastric artery* is marked by a line passing from the coeliac artery upwards and to the left towards the cardiac end of the stomach.

The *splenic artery* is marked by a broad line passing from the coeliac artery towards the left and slightly upwards for about 10 cm.

The *common hepatic artery* is marked by a line passing from the coeliac artery towards the right and slightly downwards for 2.5 cm, and then vertically upwards for 3 cm as proper hepatic artery.

Superior Mesenteric Artery

Superior mesenteric artery is marked by a curved line convex to the left, extending from the abdominal aorta just above the transpyloric plane to the point of intersection of the transtuberular and right lateral planes.

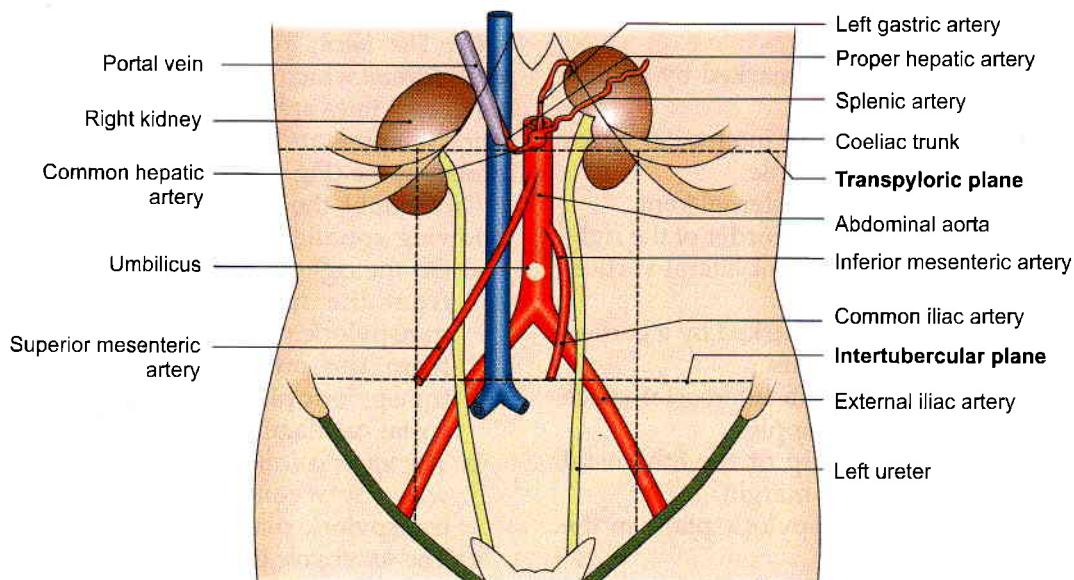


Fig. 35.6: Surface marking of various blood vessels and kidneys



Inferior Mesenteric Artery

Inferior mesenteric artery is marked by a curved line slightly convex to the left, extending from the abdominal aorta 4 cm below the transpyloric plane to a point 4 cm below the umbilicus, and about the same distance to the left of median plane (Fig. 35.6).

Inferior Vena Cava

Inferior vena cava is marked by two vertical parallel lines 2.5 cm apart, a little to the right of the median plane. It extends from a point just below the transtuberular plane to the sternal end of the right 6th costal cartilage.

Portal Vein

Portal vein is marked by a broad line extending from a point on the transpyloric plane 1.2 cm to the right of the median plane upwards and to the right for about 8 cm (Fig. 35.6).

Miscellaneous

Inguinal Canal

Inguinal canal is marked by two parallel lines 1 cm apart and about 3.7 cm long, above the medial half of the inguinal ligament, extending from the deep to the superficial inguinal rings.

The *deep inguinal ring* is marked 1 cm above the midinguinal point, as a vertical oval ring (Fig. 35.7).

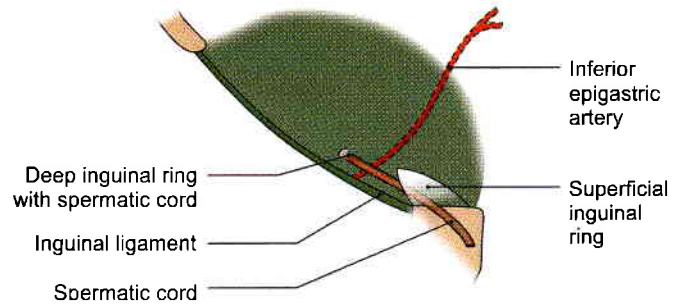


Fig. 35.7: Superficial and deep inguinal rings

Superficial inguinal ring lies above and lateral to the pubic crest. Pubic crest forms the base of the triangle; the margins are called the crura. Each crus meets laterally to form an obtuse apex, which lies above and lateral to pubic tubercle. Lateral crus is thicker and curved while medial crus is thinner and oblique.

Root of Mesentery

Root of mesentery is marked by two parallel lines close together, extending from the duodenojejunal flexure to the junction to the right lateral and transtuberular planes. The duodenojejunal flexure lies 1 cm below the transpyloric plane and 3 cm to the left of the median plane (Fig. 35.4).



Radiological and Imaging Procedures

Never forget that it is not a pneumonia, but a pneumonic man who is your patient

—WW Gull

The common radiological methods used for the study or investigation of abdomen include the following.

- 1 Plain radiography.
- 2 Barium studies for the gastrointestinal tract.
- 3 Ultrasonography for the gallbladder, cystic duct, bile duct, pancreas, kidneys, spleen, abdominal vessels, uterus, ovaries and prostate.
- 4 Hysterosalpingography for uterus and fallopian tubes.
- 5 Aortography and selective angiography for coeliac, superior and inferior mesenteric vessels, iliac vessels and renal vessels.

PLAIN SKIAGRAM OF ABDOMEN

Nomenclature

Anteroposterior plain skiagram of the abdomen has been variously named, as the straight film, survey film, scout and KUB film. When done in a case of acute abdomen, it is often called a straight film. A scout film is obtained before taking a contrast radiograph. A KUB film is taken primarily for examining the kidney, ureter, and urinary bladder, for which the acronym KUB stands.

Preparation

In cases of emergency, requiring urgent surgical intervention, a straight film is taken without any preparation. However, in chronic conditions it is better to prepare the patient to obtain a clear and good picture. The object of preparation is to make the gastrointestinal tract as empty as possible, free from food in the stomach and from gases and faecal matter in the intestines. This may be achieved by:

- 1 Using antifatulents for 3 days antifatulents, like enzyme preparations, charcoal tablets and laxatives.
- 2 Avoiding oral feeds for about 12 hours before the investigation. Constipated subjects may require an enema to empty their bowels.

In a picture taken without any preparation, the shadows of the gases and faecal matter may completely mask the significant findings.

Reading of Skiagram

The plain skiagram of the abdomen can be studied systematically in the following way.

Bony Shadows

The radiograph (Fig. 36.1) shows:

- 1 The lower ribs.
- 2 Lumbar vertebrae.
- 3 Upper parts of the hip bones.
- 4 Sacrum with the sacroiliac joints.

However, the whole of the pelvis may have been included in the exposure. The bony shadows are used as landmarks for the assessment of the position of viscera and of existing abnormalities. Any variation in the ribs and vertebrae, if present, may be noted.

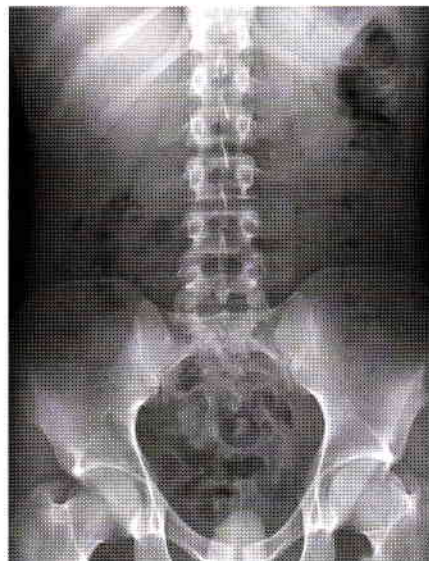

Fig. 36.1: Plain X-ray abdomen

Soft Tissue Shadows

The faint shadows of the following structures may be seen.

- 1 Domes of the diaphragm.
- 2 Psoas major.
- 3 Kidney, made visible by the perirenal fat.
- 4 Liver, beneath the right dome of diaphragm.
- 5 The spleen.

Gas Shadows

Gas shadows are seen as black shadows because gases are radiolucent.

- 1 Gas in the fundus of stomach appears as a large bubble under the left dome of diaphragm.
- 2 The scattered intestinal gas shadows are often intermixed with the shadows of faecal matter.

Abnormal Shadows

Various abnormal shadows may be seen in different diseases.

ALIMENTARY CANAL: BARIUM STUDIES

Contrast Medium

The alimentary canal can be visualized and examined radiologically by using a suspension of barium sulphate in water. Barium is radio-opaque because of its high molecular weight. Barium sulphate is absolutely harmless to the body and is not absorbed from the gastrointestinal tract. Barium sulphate is not soluble in water, and can make only a suspension or emulsion in it.

Principle Involved

The passage of barium through the lumen outlines the mucosal patterns, which can be examined under a screen (fluoroscopy) or radiographed on a film.

Barium Swallow

50% suspension of barium sulphate is to be swallowed 2–3 times with patient standing behind fluoroscopic screen. Barium swallow shows the normal position of oesophagus as it lies posterior to aortic arch, left bronchus and the left atrium of heart (Fig. 36.2).

Enlargement of left atrium would show narrowed oesophagus.

Barium Meal Examination

Preparation

The subject is instructed not to eat or drink anything for 12 hours before the examination.

Administration of Contrast Medium

The patient is made to drink 300 to 400 cc (10 to 15 oz.) of a 5% barium sulphate suspension in water, and then

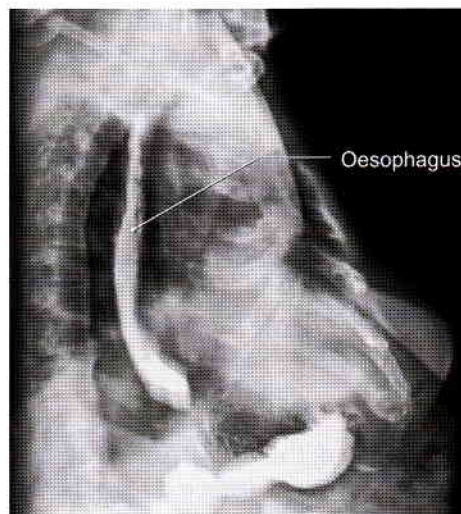


Fig. 36.2: Barium swallow

examined under fluoroscopy. Thus, the entire alimentary canal can be examined by following the barium and taking successive radiographs. The stomach and duodenum are visualized immediately after the barium drink (Fig. 36.3). The medium reaches the ileocaecal region in 3 to 4 hours, the hepatic flexure of the colon in about 6 hours, the splenic flexure of the colon in about 9 hours, the descending colon in 11 hours, and the sigmoid colon in about 16 hours. It is usually evacuated in 16 to 24 hours. However, some barium may persist in the large intestine for several days.

Stomach

As barium enters the stomach, it tends to form a triangular mass below the air in the fundus. It then descends in a narrow stream (canalization) to the

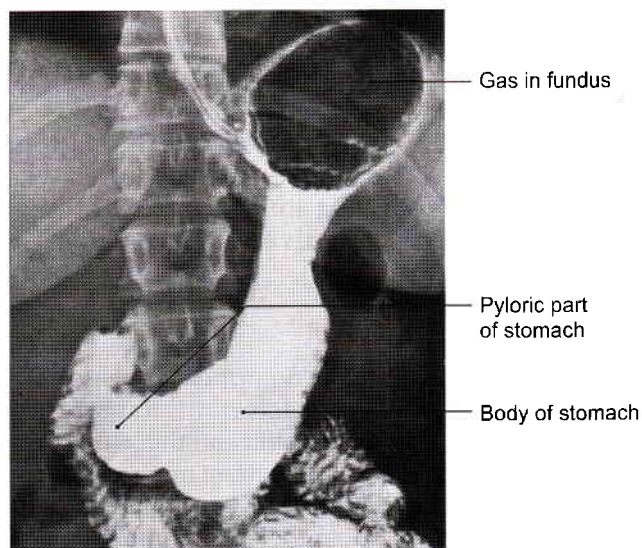


Fig. 36.3: Barium meal



pyloric part of the stomach. In addition, the shape, curvatures, peristaltic waves, and the rate of emptying of the stomach can also be studied.

Duodenum

The beginning of the first part of duodenum shows a well-formed *duodenal cap* produced by poorly developed circular folds of mucous membrane and protruding pylorus into it. The rest of the duodenum has a characteristic feathery or floccular appearance due to the presence of well-developed circular folds.

Jejunum and Ileum

The greater part of the small intestine presents a feathery or floccular appearance due to the presence of transverse mucosal folds and their rapid movements. However, the terminal part of the ileum is comparatively narrow and shows a homogeneous shadow of barium.

Large Intestine

It is identified by its smooth outline marked by characteristic haustra or sacculations which are most prominent in the proximal part and may disappear in the distal part. Acute curvatures at the flexures cause superimposition of the shadows. Occasionally, the appendix may also be visible. Diseases of the large intestine are better examined by barium enema which gives a better filling.

Barium Enema

Preparation

- 1 A mild laxative is given on two nights before the examination.
- 2 A plain warm water enema on the morning of the examination.

Contrast Medium

About 2 liters of barium sulphate suspension are slowly introduced through the anus, from a can kept at a height of 2 to 4 feet. The enema is stopped when the barium starts flowing into the terminal ileum through the ileocaecal valve (as seen under the fluoroscopic screen).

Appearance

The rectum and sigmoid colon appear much dilated, and the colon shows characteristic haustrations (Fig. 36.4). The outline of the colon and the haustra may be accentuated by the double-contrast method in which the barium is evacuated and air is injected through the anus to distend the colon. In the background of air, the barium still lining the mucosa makes it clearly visible.

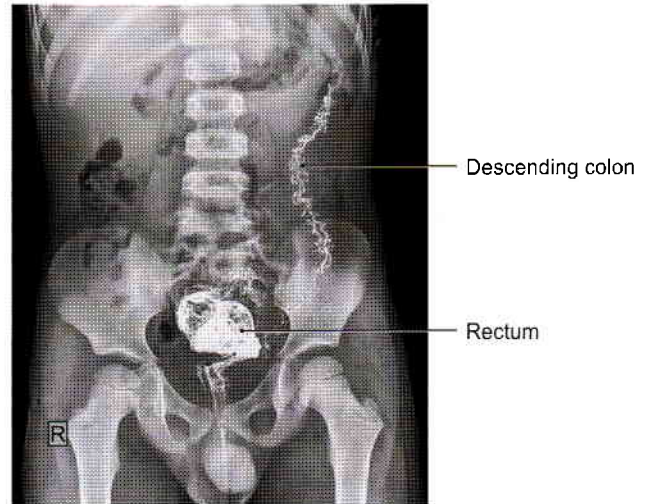


Fig. 36.4: Barium enema

PYELOGRAPHY

Pyelography (urography) is a radiological method by which the urinary tract is visualized. The radiograph thus obtained is called a *pyelogram*. It can be done in two ways depending on the route of administration of the radiopaque dye. When the dye is injected intravenously, it is called the *excretory (intravenous or descending) pyelography*. When the dye is injected directly into the ureter, through a ureteric catheter guided through a cystoscope, the technique is called *retrograde (instrumental or ascending) pyelography*.

Excretory (Intravenous or Descending) Pyelography

Preparation

In addition to routine abdomen preparation:

- 1 For 8 hours before pyelography, the patient is not given anything orally, all fluids are withheld, and diuretics are discontinued.
- 2 Patient is asked to empty his bladder just before the injection of the dye (Fig. 36.5).

Administration of the Dye

20–40 cc of a warm iodine compound (urograffin 60% or 76% Conray 420 or Conray 280) which is selectively excreted by the kidneys, is slowly injected intravenously. Care is taken not to push any dye outside the vein because it is an irritant and may cause sloughing.

Exposures

Serial skiagram (excretory pyelograms) are taken at 5, 15 and 30 minutes after the injection of the dye. Maximum concentration is reached in 15 to 20 minutes, and by 30 minutes the dye fills the urinary bladder.

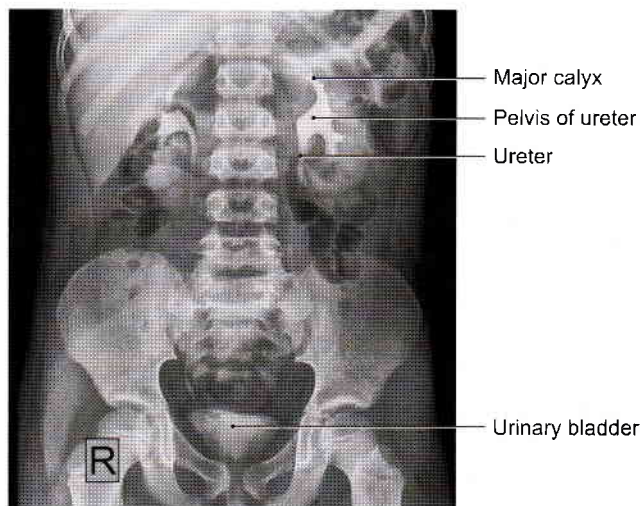


Fig. 36.5: Intravenous pyelogram

Reading

Intravenous pyelography is an anatomical as well as a physiological test because it permits not only visualisation of the urinary tract but also helps in assessment of the functional status of the kidney. Normally:

- 1 Minor calices are cup shaped due to the renal papillae projecting into them.
- 2 Renal pelvis is funnel-shaped.
- 3 Course of the ureter is clearly seen along the tips of the lumbar transverse processes, the sacroiliac joint and the ischial spine, up to the bladder.
- 4 Bladder appears oval or triangular in shape.

Retrograde (Instrumental or Ascending) Pyelography

Preparation

Preparation of the patient is similar to that for descending pyelography.

Injection of Dye

The technique is quite difficult and can be done only by urologists. A cystoscope is passed into the urinary bladder through the urethra. Then the ureteric catheter is guided into the ureteric opening and passed up to the renal pelvis. Through the catheter, 5 to 10 ml of a sterile solution of 6–8% sodium iodide (Conray 280) is injected. As the renal pelvis is filled to its capacity, the patient begins to complain of pain, when further injection must be stopped. General anaesthesia is therefore, contraindicated because of the risk of overdistension of the pelvis. If the renal pelvis admits more than 10 ml of the dye, hydronephrosis is suspected.

An ascending pyelogram can be distinguished from a descending pyelogram because:

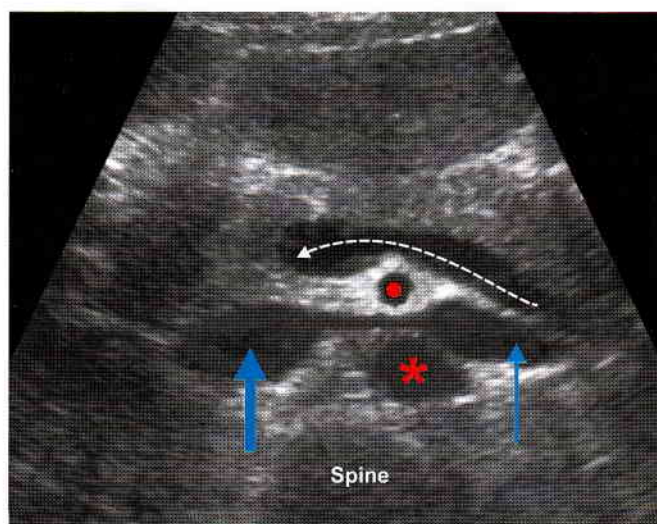
- a. Only one pelvis is outlined.
- b. The catheter through which the dye is injected can be seen.

BILIARY APPARATUS

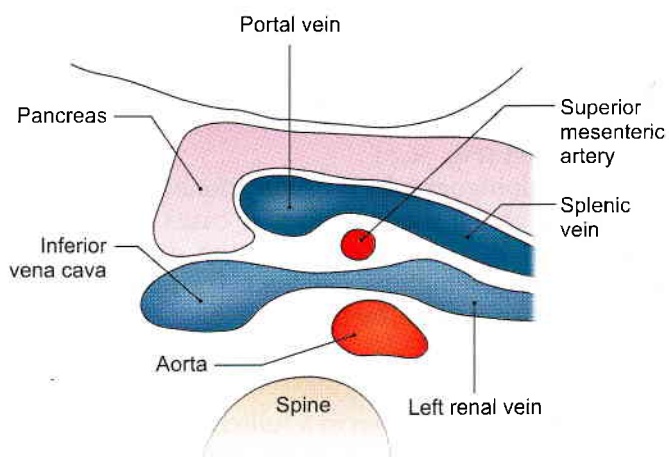
Investigation of Choice

The investigation of choice for gallbladder is *ultrasonography*. It can be undertaken on a fasting patient. Gallbladder is seen as a cystic oval shadow with a narrow neck in the right upper quadrant along with visualisation of the bile duct and portal vein. However, endoscopic retrograde cholangio-pancreaticography (ERCP) can be carried out to outline the intrahepatic radicals, bile duct, pancreatic duct and gallbladder through the oral route via an endoscope through which a catheter is inserted and the contrast is injected into the common bile duct.

Ultrasonography of abdomen shows pancreas and related structures (Figs 36.6a and b).

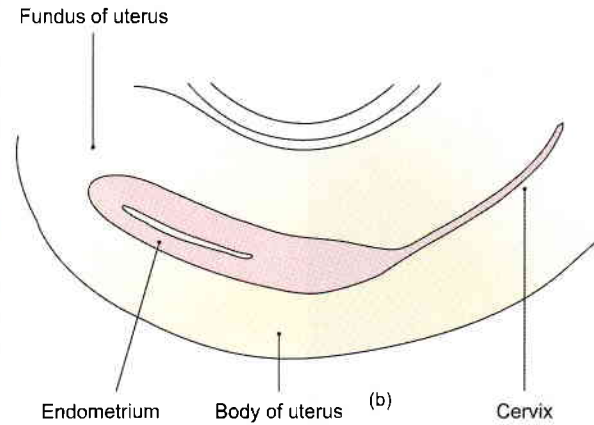
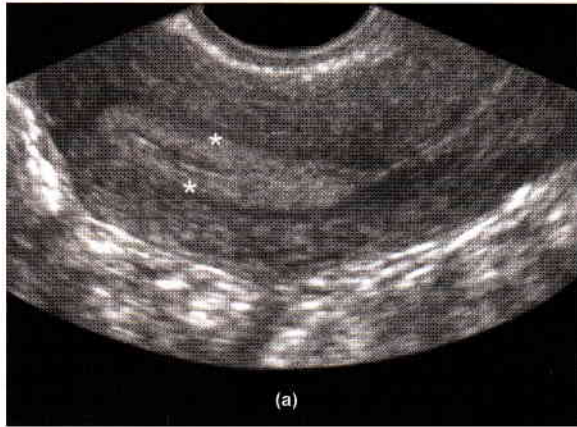


(a)



(b)

Figs 36.6a and b: Ultrasound image of pancreas and related structures



Figs 36.7a and b: Ultrasound image of uterus and cervix

Oral cholecystography is an outdated method for visualising the gallbladder by taking radiopaque dye which is exclusively excreted by the liver and concentrated by the gallbladder. The contrast is taken overnight and X-rays are taken 14–16 hours after the intake of the dye and gallbladder, cystic duct and bile duct can be seen. It is, however, dependent on the proper absorption from intestines.

Uterus of the female pelvis is seen by ultrasonography (Figs 36.7a and b).

HYSTEROSALPINGOGRAPHY

This is a radiological method by which the uterus and uterine tubes are visualized and their patency confirmed. The radiograph thus obtained is called a *hysterosalpingogram*.

The investigation is done preferably within the first 5 to 10 days of the menstrual cycle. A tight-fitting cannula is introduced into the internal os of the cervix. The cannula is connected to a syringe through which 5 to 10 ml of an iodized oil (lipiodol) are injected, and the skiagram taken.

The shape and size of the uterus and of the uterine tubes are studied. Spilling of the dye into the peritoneal cavity is noted (Fig. 36.8).

Hysterosalpingography is usually done to determine the patency of the uterine tubes in cases of sterility. However, it is also of value in the diagnosis of anomalies of the female genital tract. The female pelvic organs can also be seen by ultrasound.

FOETOGRAM

Plain X-ray of the abdomen in a fullterm pregnant lady showing the foetus with vertex presentation. The shaft of bones of upper and lower limbs and body of vertebrae can easily be identified and appreciated (Fig. 36.9).

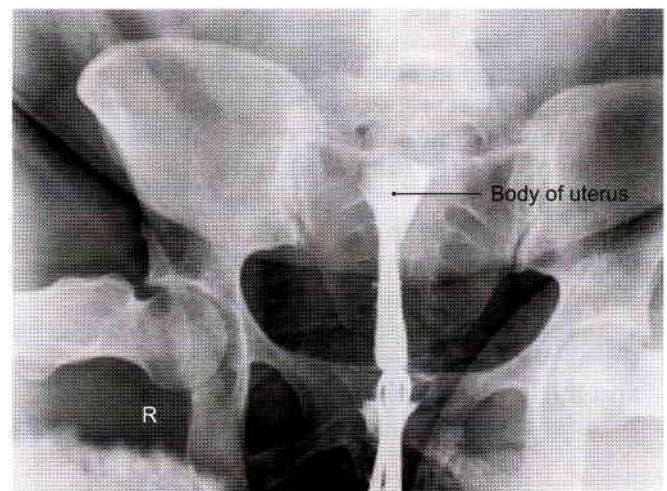


Fig. 36.8: Hysterosalpingogram

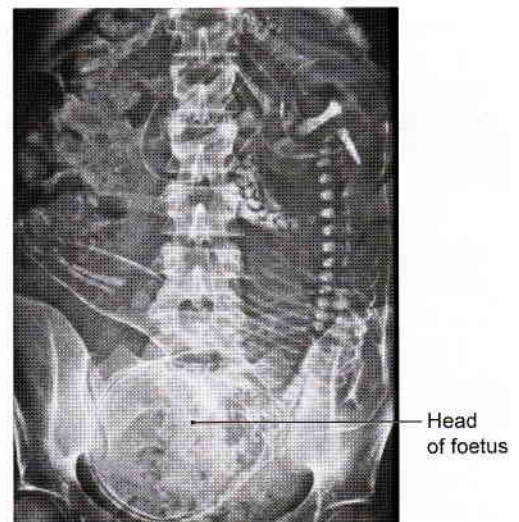
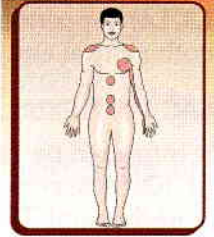


Fig. 36.9: Foetogram

Appendix 2



And to, the Hospital, grey, quiet, old where Life and Death like friendly chaffers meet
—Wilhan Errest Henley

NERVES OF ABDOMEN

LOWER INTERCOSTAL NERVES

Course

The ventral rami of T7–T11 pass forwards in the intercostal spaces below respective intercostal vessels. At the back of chest they lie between the pleura and posterior intercostal membrane but in most of their course they lie between internal intercostal and intercostalis intimi.

As they reach the anterior ends of their respective spaces, the 7th and 8th nerves curve upwards and medially across the deep surface of costal margin, passing between digitations of transverses abdominis then piercing the posterior layer of internal oblique, to enter the rectus sheath, and continue to run upwards and medially parallel to the costal margin. After supplying rectus abdominis, they pierce the anterior wall of the rectus sheath to reach the skin. 7th nerve supplies skin of the epigastrium and 8th below it.

At the anterior ends of 9th, 10th and 11th intercostal spaces, the 9th, 10th and 11th intercostal nerves pass between digitations of transversus abdominis to lie between it and the internal oblique and run in this plane. The 9th nerve runs horizontally, but 10th and 11th run downwards and medially.

When they reach the lateral margin of rectus abdominis, they pierce the posterior layer of rectus sheath, enter it, pierce the muscle and its anterior sheath to supply the skin. The 10th nerve supplies the band of skin which includes the umbilicus.

The ventral ramus of T12 is larger than the others. It accompanies the subcostal artery along the lower border of 12th rib and passes behind the lateral arcuate ligament. It lies behind the kidney, anterior to quadratus lumborum, pierces the aponeurosis of

transversus abdominis and runs in the interval between transversus and internal oblique.

Branches

Muscular

The intercostal and subcostal nerves and their collateral branches supply intercostal muscles and muscles of anterolateral abdominal wall. T12 supplies pyramidalis also, if present.

Cutaneous

The terminal parts of T7–T12 nerves are called as the anterior cutaneous branches. These supply the skin close to the anterior median line. T10 supplying the skin around umbilicus; T7, the skin of epigastrium and T8, T9 the intervening skin between epigastrium and the umbilicus. T11, T12 and iliohypogastric (L1) supply the skin between umbilicus and pubic symphysis.

The lateral cutaneous branches of the T7–T11 intercostal nerves divide into anterior and posterior branches to supply the skin of lateral side of abdomen and back.

The lateral cutaneous branch of T12 supplies the skin of anterior part of the gluteal region.

UPPER LUMBAR NERVES

- 1 Iliohypogastric.
- 2 Ilioinguinal.
- 3 Genitofemoral.
- 4 Lateral cutaneous nerve of thigh.

All these nerves are described in Chapter 27.

LUMBAR PLEXUS

Formed by ventral rami of L1, L2, L3 and part of L4. These rami divide into dorsal and ventral divisions. From the ventral divisions of these rami arise



ilioinguinal (L1), genitofemoral (L1, L2), obturator (L2, L3, L4), accessory obturator (L3, L4) nerves.

The dorsal divisions of these rami give rise to lateral cutaneous nerve of thigh (L2, L3), femoral nerve (L2, L3, L4) (Appendix 1). Iliohypogastric contains fibres of both ventral and dorsal divisions (L1).

SACRAL PLEXUS

It is formed by ventral rami of part of L4, whole of L5, S1, S2, S3 nerves. Few muscular branches are given off from the rami. Then these divide into ventral and dorsal divisions.

Branches arising from ventral divisions are:

- 1 Nerve to quadratus femoris (L4, L5, S1): Supplies quadratus femoris, inferior gemellus and hip joint.
- 2 Nerve to obturator internus (L5, S1, S2): Supplies obturator internus and superior gemellus.
- 3 Pudendal nerve (S2, S3, S4) is described below.
- 4 Perforating cutaneous nerve (S3, S4): Supplies small area of skin of gluteal region.
- 5 Tibial part of sciatic nerve (L4, L5, S1, S2, S3): Supplies hamstrings all muscles of the calf and of the sole.
- 6 Posterior cutaneous nerve of thigh (S1, S2): Supplies skin of back of thigh.

Branches from dorsal divisions are:

- 1 Superior gluteal nerve (L4, L5, S1): Supplies gluteus medius, gluteus minimus and tensor fascia latae.
- 2 Inferior gluteal nerve (L5, S1, S2): Supplies only gluteus maximus.
- 3 Common peroneal part of sciatic nerve (L4, L5, S1, S2): Supplies evertors and foot and dorsiflexors of ankle joint and extensor digitorum brevis.

Pudendal Nerve

Pudendal nerve supplies the skin, external genital organs and muscles of perineum. It is concerned with micturition, defaecation, erection, ejaculation and in females, with parturition. It is accompanied by internal pudendal vessels.

Root value: It arises from the sacral plexus in the pelvis. Its root value is ventral rami of S2, S3, S4 segments of spinal cord.

Course: It starts in the pelvis, enters the gluteal region through greater sciatic notch, lies on the sacrospinous ligament, leaves the gluteal region through lesser sciatic notch. It just peeps into the gluteal region to enter the pudendal canal in the lateral wall of the ischiorectal fossa.

Branches

- 1 *Inferior rectal nerve:* Skin around anus, external anal sphincter and lining of anal canal below the pectinate line.

- 2 *Perineal nerve:* Medial and lateral scrotal/labial branches. Muscular branches to deep transversus perinei, ischiocavernosus, bulbospongiosus, external anal sphincter, levator ani, corpus spongiosum, penis and urethra, lower 2.5 cm of vagina.
- 3 *Dorsal nerve of penis/clitoris:* Passes through deep perineal space, then runs on the dorsum of penis/clitoris and ends in the glans; supplying skin of body of penis/clitoris and of the glans.

Clinical Anatomy

Pudendal nerve block is given in some vaginal operations and may be given during delivery.

ABDOMINAL PART OF SYMPATHETIC TRUNK

Sympathetic trunk runs along the medial border of psoas major muscle. It is continuous with the pelvic part by passing behind the common iliac vessels. There are 4 ganglia in the lumbar or abdominal part. Only upper two ganglia receive white ramus communicans from the ventral primary rami of first and second lumbar nerves.

Branches

- 1 Grey rami communicans to the lumbar spinal nerves. These pass along the spinal nerves to be distributed to the sweat glands, cutaneous blood vessels and arrector pili muscles (sudomotor, vasomotor and pilomotor).
- 2 Postganglionic fibres pass medially to the aortic plexus.
- 3 Postganglionic fibres pass in front of common iliac vessels to form hypogastric plexus, which is also supplemented by branches of aortic plexus.

Aortic Plexus

This plexus is formed by preganglionic sympathetic, postganglionic sympathetic, preganglionic parasympathetic and visceral afferent fibres around the abdominal aorta. The plexus is concentrated around the origin of ventral and lateral branches of abdominal aorta. These are known as coeliac plexus, superior mesenteric plexus, inferior mesenteric plexus, and renal plexus.

PELVIC PART OF SYMPATHETIC TRUNK

It runs in front of sacrum, medial to ventral sacral foramina. Caudally the two trunks unite and fuse into a single *ganglion impar* in front of coccyx. There are 4 ganglia in this part of sympathetic trunk. Their branches are:

- 1 Grey rami communicans to the sacral and coccygeal nerves.
- 2 Branches to the pelvic plexuses.



COLLATERAL OR PREVERTEBRAL GANGLIA AND PLEXUSES

Coeliac Plexus

It is the largest of the three autonomic plexuses, e.g. coeliac, superior mesenteric and inferior mesenteric plexuses. It is a dense network of nerve fibres which unite the two coeliac ganglia. The ganglia receive the greater splanchnic nerves, lesser splanchnic nerves of both sides including some filaments of vagi and phrenic nerves.

Coeliac ganglia are two irregularly shaped ganglia. Each ganglion receives greater splanchnic nerve. The lower part of the ganglion receives lesser splanchnic nerve and is also called as aorticorenal ganglion. The aorticorenal ganglion gives off the renal plexus which accompanies the renal vessels.

Secondary plexuses arising from coeliac and aorticorenal plexuses are distributed along the branches of the aorta, namely phrenic, splenic, left gastric, hepatic, intermesenteric, suprarenal, renal, gonadal, superior and inferior mesenteric plexuses, and abdominal aortic plexus.

Superior Hypogastric Plexus

This plexus lies between the two common iliac arteries and is formed by:

- 1 Aortic plexus.
- 2 Branches from third and fourth lumbar sympathetic ganglia.

It divides into right and left inferior hypogastric plexus (pelvic plexus); which runs on the medial side of internal iliac artery and is supplemented by pelvic splanchnic nerves (parasympathetic nerves). Thus inferior hypogastric plexus contains both sympathetic and parasympathetic nerves. These are for the supply of the pelvic viscera along the branches of the arteries. The plexuses supply gastrointestinal tract and genitourinary tract.

AUTONOMIC NERVE SUPPLY OF VARIOUS ORGANS

Gastrointestinal Tract

Oesophagus

It receives its nerve supply from vagus and sympathetic.

Cervical part of oesophagus receives branches from recurrent laryngeal nerve of vagus and middle cervical ganglion of sympathetic trunk.

Thoracic part gets branches from vagal trunks and oesophageal plexus as well as from sympathetic trunks and greater splanchnic nerves.

Abdominal part receives fibres from vagal trunk (i.e. anterior and posterior gastric nerves), thoracic part of sympathetic trunks, greater splanchnic nerves and

plexus around left gastric artery. The nerves form a plexus called *myenteric* plexus between two layers of the muscularis externa and another one in the submucous layer.

Stomach

Sympathetic supply reaches from coeliac plexus along gastric and gastroepiploic arteries. A few branches also reach from thoracic and lumbar sympathetic trunks.

Parasympathetic supply is derived from vagus nerves. The left vagus forms anterior gastric, while right vagus comprises posterior gastric nerve. The anterior gastric nerve supplies cardiac orifice, anterior surface of body as well as fundus of stomach, pylorus and liver.

Posterior gastric nerve supplies posterior surface of body and fundus till pyloric antrum. It gives a number of coeliac branches, which form part of the coeliac plexus.

Vagus is secretomotor to stomach. Its stimulation causes secretion which is rich in pepsin. Sympathetic inhibits peristalsis and is motor to the pyloric sphincter. It also carries pain fibres from stomach. Spasm, ischaemia and distension causes pain.

Small Intestine

The nerves of this part of the gut are derived from coeliac ganglia formed by posterior gastric nerve (parasympathetic) and the plexus around superior mesenteric artery. These nerves form myenteric plexus and submucous plexus. Parasympathetic fibres relay in the ganglion cells present in these plexuses. Sympathetic inhibits the peristaltic movements of intestine but stimulates the sphincters.

Large Intestine

Large intestine except the lower half of anal canal is supplied by both components of autonomic nervous system. The derivatives of midgut, i.e. caecum, vermiform appendix, ascending colon and right two-thirds of transverse colon receive their sympathetic nerve supply from coeliac and superior mesenteric ganglia and parasympathetic from vagus nerve.

Left one-third of transverse colon, descending colon, sigmoid colon, rectum and upper half of anal canal (developed from hindgut and anorectal canal) receive their sympathetic nerve supply from lumbar part of sympathetic trunk and superior hypogastric plexus through the plexuses on the branches of inferior mesenteric artery. Its effect is chiefly vasomotor. Parasympathetic supply of colon is received from pelvic splanchnic nerves.

Pelvic splanchnic nerves give fibres to inferior hypogastric plexuses to supply rectum and upper half



of anal canal. Some fibres of inferior hypogastric plexus pass up through superior hypogastric plexus and get distributed along the branches of inferior mesenteric artery to the left one-third of transverse colon, descending and sigmoid colon.

Rectum and Anal Canal

Sympathetic fibres pass along inferior mesenteric and superior rectal arteries also via superior and inferior hypogastric plexuses.

Parasympathetic supply is from pelvic splanchnic nerve, which joins inferior hypogastric plexus. This supply is motor to muscles of rectum and inhibitory to internal sphincter.

The external anal sphincter is supplied by inferior rectal branch of pudendal nerve. Afferent impulses of physiological distension of rectum and sigmoid colon are carried by parasympathetic, whereas pain impulses are conveyed both by sympathetic and parasympathetic nerves.

Pancreas

Branches of coeliac plexus pass along the arteries. Sympathetic is vasomotor. The nerve fibres make synaptic contact with acinar cells before innervating the islets. The parasympathetic ganglia lies in sparse connective tissue of the gland and in the islet cells.

Liver

Nerves of the liver are derived from hepatic plexus which contain both sympathetic and parasympathetic fibres. These accompany the blood vessels and bile ducts. Both types of nerve fibres also reach the liver through various peritoneal folds.

Gallbladder

Parasympathetic and sympathetic nerves of gallbladder are derived from coeliac plexus, along the hepatic artery (hepatic plexus) and its branches. Fibres from the right phrenic nerve (C4) through the communication of coeliac and phrenic plexus also reach gallbladder in the hepatic plexus. The reason of pain in the right shoulder (from where impulses are carried by lateral supraclavicular nerve C4) in cholecystitis is the stimulation of phrenic nerve fibres (C4) due to the communication of phrenic plexus and hepatic plexus via coeliac plexus.

Genitourinary Tract

Kidneys

The kidneys are supplied by renal plexus formed from coeliac ganglion, coeliac plexus, lowest thoracic splanchnic nerve, and first lumbar splanchnic nerve. The plexus runs along the branches of renal artery to

supply the vessels, renal glomeruli and tubules. These are chiefly vasomotor in function.

Ureter is supplied in its upper part from renal and aortic plexus, middle part from superior hypogastric plexus and lower part from hypogastric nerve and inferior hypogastric plexus.

Vesical Plexus

Sympathetic fibres arise from T11 and T12 segments and L1 and L2 segments of spinal cord. Parasympathetic fibres arise from sacral S2, S3, S4 segments of spinal cord, which relay in the neurons present in and near the wall of urinary bladder. Parasympathetic is motor to the muscular coat and inhibitory to the sphincter; sympathetic is chiefly vasomotor. Emptying and filling of bladder is normally controlled by parasympathetic only.

Male Reproductive Organs

Testicular plexus accompanies the testicular artery to reach the testis. It is formed by renal and aortic plexus, and also from superior and inferior hypogastric plexuses. This plexus supplies the epididymis and ductus deferens.

Prostatic plexus is formed from inferior hypogastric plexus and branches are distributed to prostate, seminal vesicle, prostatic urethra, ejaculatory ducts, erectile tissue of penis, penile part of urethra and bulbourethral glands. Sympathetic nerves cause vasoconstriction, parasympathetic nerves cause vasodilatation.

Female Reproductive Organs

Ovary and uterine tube receive their nerve supply from plexus around the ovarian vessels. This plexus is derived from renal, aortic plexuses and also superior and inferior hypogastric plexuses. Sympathetic fibres derived from T10 and T11 segments of spinal cord are vasomotor in nature whereas parasympathetic fibres are probably vasodilator in function.

Uterus

It is supplied by uterovaginal plexus, formed from the inferior hypogastric plexus. The sympathetic fibres are derived from T12 and L1 segments of spinal cord. Parasympathetic fibres arise from S2, S3, S4 segments of spinal cord. Sympathetic causes uterine contraction and vasoconstriction, while parasympathetic nerves produce vasodilatation and uterine inhibition. Vagina is supplied by nerves arising from inferior hypogastric plexus and uterovaginal plexus. These supply wall of vagina including vestibular glands and clitoris. Parasympathetic fibres contain vasodilator effect on the erectile tissue.



CLINICAL ANATOMY

- In some diseases affecting the nerve trunks near their origins, the pain is referred to their peripheral terminations. In tuberculosis of thoracic vertebrae, the pain is referred to abdomen either as constricting pain when one nerve is involved or general diffuse pain when more nerves are involved.
- The muscle and skin of the anterolateral abdominal wall is supplied by thoracic (T)7–12 spinal nerves. These muscles protect the underlying viscera effectively. Any blow to the abdominal wall will do no harm to the viscera if the muscles are firmly contracted. If the muscles are caught unawares, blow can do a lot of damage to viscera. Mostly there is reflex contraction of muscles if there is any attack to the skin (Fig. A2.1).
- The lower intercostal nerves are connected to sympathetic ganglia via the rami communicans. From these ganglia arise greater splanchnic nerves which supply abdominal viscera. In injury to the viscera or peritonitis, the muscles of abdominal wall firmly contract, giving rise to “board-like rigidity” to prevent any further insult to the viscera.
- If the lateral cutaneous nerve of thigh gets compressed as it pierces the inguinal ligament, there is pain tingling, numbness and anaesthesia over the anterolateral aspect of thigh. This is called “meralgia paraesthetica” (Fig. A2.1).

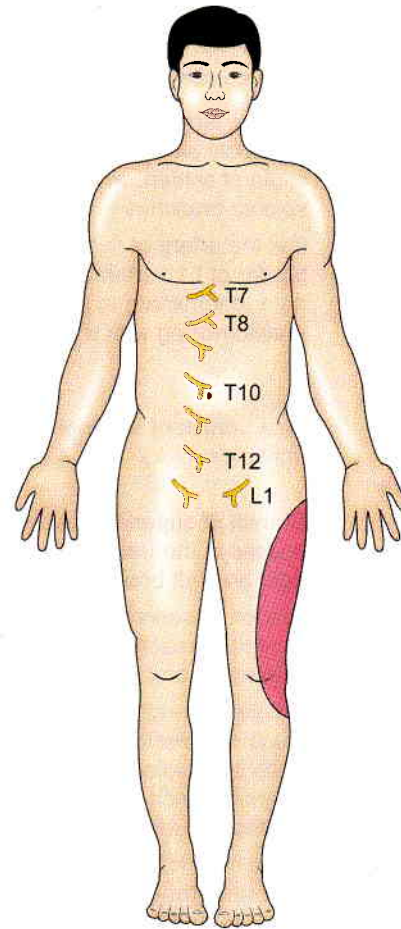


Fig. A2.1: Nerve supply of the abdominal wall and site of meralgia paraesthetica

ARTERIES OF ABDOMEN AND PELVIS

VENTRAL BRANCHES OF ABDOMINAL AORTA

Artery	Origin, course and termination	Area of distribution
Coeliac trunk (see Fig. 21.3)	It is the artery of foregut and the first ventral visceral branch of abdominal aorta arising at upper border of L1 vertebra. It has a course of 1.25 cm and ends by dividing into left gastric, common hepatic and splenic arteries	Coeliac trunk supplies the derivatives of foregut, namely oesophagus, stomach, proximal part of duodenum, spleen, greater part of pancreas, liver and gallbladder
Left gastric artery	Smallest branch of coeliac trunk. First it courses upward till the cardiac end of stomach, then it enters lesser omentum to run along lesser curvature of stomach. Ends by anastomosing with right gastric artery	Oesophageal branches to lower part of oesophagus. This part is also supplied by oesophageal branches of thoracic aorta. Gives gastric branches to both surfaces of stomach
Common hepatic artery	Branch of coeliac trunk. First descends till the upper border of duodenum, where it gives gastroduodenal artery, and continues as proper hepatic artery	Gastroduodenal supplies the stomach and 1st part of duodenum
Proper hepatic artery	It runs upwards in lesser omentum and ends at porta hepatis by dividing into right and left hepatic branches	Right gastric supplies stomach. Cystic artery for gallbladder from right hepatic artery. Two hepatic arteries to supply oxygen to the hepatic cells

(Contd...)



ARTERIES OF ABDOMEN AND PELVIS (Contd...)

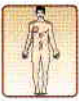VENTRAL BRANCHES OF ABDOMINAL AORTA

Artery	Origin, course and termination	Area of distribution
Splenic artery	It is the largest branch of coeliac trunk. Runs sinuously along upper border of pancreas to reach hilum of spleen, where it ends by dividing 5–7 splenic branches	<ul style="list-style-type: none"> • Gives numerous pancreatic branches • 5–7 short gastric branches for fundus of stomach • Left gastroepiploic to supply stomach along greater curvature and greater omentum also
Superior mesenteric artery (see Fig. 21.7)	It is the artery of midgut, arising from aorta at lower border of L1 vertebra. Courses downwards and to right to terminate in the right iliac fossa by anastomosing with a branch of ileocolic artery	<ul style="list-style-type: none"> • Distal part of duodenum below the opening of bile duct • Jejunum and ileum • Vermiform appendix • Caecum and ascending colon • Right two-thirds of transverse colon
<i>Inferior pancreaticoduodenal artery</i>	First branch of superior mesenteric artery from its right side	Supplies both duodenum and pancreas
<i>Middle colic</i>	Branch of superior mesenteric from its right side, it passes in the transverse mesocolon and divides into right and left branches	Supplies the transverse colon
<i>Right colic</i>	Branch of superior mesenteric from right side passes to right to reach ascending colon and divides into ascending and descending branches	Supplies the hepatic flexure and ascending colon
<i>Ileocolic artery</i>	Arises from right side of superior mesenteric artery. Runs downwards and to right till the caecum and ends by dividing into superior and inferior branches. Inferior branch ends by anastomosing with superior mesenteric artery	Supplies ascending colon, caecum, vermiform appendix and terminal ileum
<i>12–15 Jejunal and ileal branches</i>	Arise from left side of superior mesenteric artery course between layers of mesentery to reach the jejunum and ileum	Supply both surfaces of jejunum and ileum
Inferior mesenteric artery (see Fig. 21.10)	This is the artery of the hindgut. It is also a ventral branch of abdominal aorta arising at the left, crosses to left at the level of L3 vertebra. It courses downwards crosses common iliac artery and continues in sigmoid mesocolon, by changing its name to superior rectal artery	<p>It supplies the:</p> <ul style="list-style-type: none"> • Left one-third of transverse colon • The descending colon, the sigmoid colon • The rectum • Upper part of anal canal
<i>Left colic artery</i>	First branch of inferior mesenteric artery. Runs upwards and to the left and ends by dividing into ascending and descending branches	<ul style="list-style-type: none"> • Left one-third of transverse colon • Descending colon
<i>Sigmoid arteries</i>	2–4 sigmoid arteries pass downwards and to left and anastomose with each other, lowest branch anastomoses with superior rectal artery	<ul style="list-style-type: none"> • Descending colon • Sigmoid colon
<i>Superior rectal artery</i>	Continuation of inferior mesenteric artery at the pelvic brim. Divides into right and left branches	Muscles and mucous membrane of rectum and upper part of anal canal

OTHER BRANCHES OF ABDOMINAL AORTA

Inferior phrenic arteries	Right and left inferior phrenic arteries give branches to the respective suprarenal glands and end in the thoracoabdominal diaphragm	Suprarenal glands and muscles of the diaphragm
Middle suprarenal arteries	Right and left arteries run upwards on the muscles of diaphragm to end in the suprarenal glands	Suprarenal glands
Renal arteries (see Fig. 27.1)	These two large arteries arise at the level of L2 vertebra. Reach the hila of respective kidney to supply kidney	Suprarenals, ureters and kidneys

(Contd...)

**ARTERIES OF ABDOMEN AND PELVIS (Contd...)**

Artery	Origin, course and termination	Area of distribution
Gonadal	Arise at level of L2 vertebra. Each artery runs downwards and laterally	Runs as ovarian artery in female and as testicular artery in male
Ovarian arteries	Ovarian artery crosses the pelvic brim to enter the suspensory ligament of ovary. It then enters the hila of respective ovary	Supplies ovary and lateral part of oviduct
Testicular arteries	Each testicular artery joins the spermatic cord at the deep inguinal ring, courses through the inguinal canal. At the upper pole of testis, it divides into branches which supply testis and epididymis	Testis and epididymis
Lumbar arteries	Four pairs of lumbar arteries arise from the dorsal aspect of abdominal aorta. These pass laterally and dorsally to supply muscles of posterior abdominal wall. Gives branch to the vertebral canal also	Muscles of anterolateral and posterior abdominal wall. Spinal cord, muscles and skin of the back are also supplied
Median sacral artery	Single artery from back of aorta above its bifurcation. Ends in front of coccyx	Rectum and muscles of the pelvis
Common iliac artery	The two terminal branches of abdominal aorta. Each runs downwards and laterally and ends by dividing into larger external iliac and smaller internal iliac in front of sacroiliac joint at the level of L5 and S1 vertebrae	No branches are given off

EXTERNAL ILIAC ARTERY

External iliac artery	Larger terminal branch of common iliac artery Courses downwards and laterally till the midinguinal point from where it continues as the femoral artery	<ul style="list-style-type: none"> • Deep circumflex iliac for the muscles attached to the iliac crest • Inferior epigastric which enters the rectus sheath to supply the muscle and overlying skin
------------------------------	---	---

INTERNAL ILIAC ARTERY

Internal iliac artery (see Fig. 34.1)	Smaller terminal branch of common iliac artery Begins in front of sacroiliac joint, crosses the pelvic brim and ends by dividing into anterior and posterior divisions	The artery supplies most of the pelvic organs, perineum and the gluteal region
Anterior division		
<i>Superior vesical</i>	Branch of internal iliac artery. Ends by giving branches to urinary bladder and ductus deferens	Superior surface of urinary bladder and the muscular wall of ductus deferens
<i>Obturator artery</i>	Branch of internal iliac artery. Runs on the lateral wall of pelvis, passes through obturator foramen to enter the thigh	Gives branches to obturator internus and iliacus muscles. In thigh it supplies the adductor muscles
<i>Middle rectal artery</i>	Branch of internal iliac artery. Ends by supplying muscle coats of rectum	Supplies muscle coats of rectum, prostate and seminal vesicles
<i>Inferior vesical artery</i>	Branch of internal iliac artery. Only in male ends by supplying trigone of urinary bladder	Supplies urinary bladder, prostate, seminal vesicle and lower part of ureter
<i>Inferior gluteal artery</i>	Largest and one of the terminal branches of internal iliac artery. It leaves the pelvis through greater sciatic notch to enter the gluteal region	Branches to muscles of gluteal region It is the axial artery of lower limb
<i>Internal pudendal artery</i>	Smaller terminal branch of internal iliac artery. Runs out of pelvis through greater sciatic notch and leaves the gluteal region by passing through lesser sciatic foramen to enter the pudendal canal. Then it runs in pudendal canal in the lateral wall of ischioanal fossa. Lastly it enters the Urogenital triangle above	In ischioanal fossa, inferior rectal artery is given off which supplies mucous membrane and musculature of anal canal including skin overlying it. In perineum it gives perineal artery for muscles, scrotal or labial branches, deep and dorsal arteries of penis or clitoris

(Contd...)



ARTERIES OF ABDOMEN AND PELVIS (Contd...)

Artery	Origin, course and termination	Area of distribution
	the perineal membrane where it ends by dividing into deep and dorsal arteries	
Vaginal artery	Branches of internal iliac artery only in female It ends by supplying the vagina	Supplies vagina, base of urinary bladder
Uterine artery	It is branch of internal iliac artery only in female. It runs downwards and medially till the lateral fornix of vagina and then upwards along vagina, cervix and uterus with a tortuous course and ends by anastomosing with the ovarian artery	Supplies vagina, uterus, medial two-thirds of oviduct The artery crosses in front of ureter
Posterior division		
Iliolumbar artery	Runs upwards in front of sacroiliac joint and ends by dividing into iliac branch and lumbar branch	Iliac branch supplies iliacus and lumbar branch supplies muscles of back and through its spinal branch, cauda equina is also supplied
Lateral sacral arteries	2 lateral sacral arteries which divide to enter 4 ventral sacral foramina to supply sacral canal and muscles of back of sacrum	Supply cauda equina and muscles of back of sacrum
Superior gluteal artery	Passes out through greater sciatic notch to reach gluteal region	It supplies muscles of gluteal region, especially gluteus medius and minimus

CLINICAL TERMS

Paramedian incision: These are given to open up the abdominal cavity. In paramedian incision the rectus abdominis muscle is pushed laterally so that the various nerves supplying the rectus muscle are not pulled or injured (see Fig. 16.19).

Inguinal hernia: Hernia is the protrusion of the contents of a cavity through any of its walls. Hernia is common at any weak spot in any of the walls. Testis descends down along a peritoneal process called processus vaginalis. The connection is usually obliterated. In some cases the connection between peritoneal cavity and processus vaginalis remains open giving rise to congenital inguinal hernia.

Femoral hernia: The femoral canal is the medial compartment of the femoral sheath. It permits dilatation of femoral vein whenever required. This canal is wider in females than males because of the broad pelvis and smaller vessels. Sometimes a part of intestine or peritoneum may project in the femoral canal and be seen as a swelling below and lateral to pubic tubercle. The condition is called femoral hernia (see Fig. 16.32). It is never congenital.

Abdominal paracentesis: Collection of fluid in the peritoneal cavity is called "ascites". In these cases the excess fluid has to be removed. For the removal, abdominal paracentesis is done with a trocar and cannula. The site is usually midway between umbilicus and pubic symphysis.

Peritonitis: Inflammation of the peritoneum is called peritonitis. It is usually secondary to perforation of any viscera. The anterior abdominal muscles are in a state of contraction, and the condition is called "board-like rigidity".

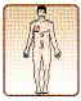Peritonitis is common in females, as the peritoneal cavity communicates with outside through fallopian tubes, uterus, vagina.

Internal hernia: Sometimes a loop of intestines enters a foramen, fossae, fold within the abdominal cavity itself, but cannot come out. It may become obstructed or strangulated (lack of blood supply). The condition is acute and needs immediate attention and treatment (see Fig. 18.26).

Femoral and inguinal hernia are external hernia.

Morrison's pouch: The intraperitoneal space or pouch between the posterior surface of liver, right kidney and hepatic flexure is called Morrison's or hepatorenal pouch. When a person is lying down, this pouch is the deepest. So pus or fluid tend to gravitate in this pouch (see Fig. 18.28).

Abdominal policeman: The greater omentum is a four-layered peritoneum between greater curvature of stomach and transverse colon. It hangs down and covers all the abdominal viscera like an apron. It also moves. Any infected viscera or perforating viscera may be sealed by greater omentum. So it does try to limit the infection and hence is called abdominal policeman (see Fig. 18.17a).



Pouch of Douglas: The rectouterine pouch in females is the deepest or most dependent part of peritoneal cavity in sitting position. It lies at a depth of 5.5 cm from the skin of perineum (see Fig. 18.30).

Gastric ulcers: The gastric ulcers are common along the lesser curvatures as the fluids (hot/cold), alcoholic beverages pass along lesser curvature. The blood supply is also relatively less along the lesser curvature so the ulcers are common here. Gastric pain is felt in the epigastrium because the stomach is supplied from segments T6–T10 of the spinal cord, which also supply the upper part of the abdominal wall.

Referred pain in early appendicitis: The visceral peritoneum over vermiform appendix is supplied by lesser splanchnic nerve which arises from thoracic 10 sympathetic ganglion. T10 spinal segment also receives the sensation of pain from umbilical area. Since somatic pain is better appreciated than visceral pain, pain of early appendicitis is referred to umbilical region. Later on there is pain in right fossa due to inflammation of local parietal peritoneum.

Intestinal obstruction: Intestinal obstruction is caused by tubercular ulcers not typhoid ulcers. In tubercular ulcers, the lymph vessels are affected, these pass circularly around the gut wall. During healing, these cause constriction of the gut wall and subsequent obstruction. Typhoid ulcers lie longitudinally along the antimesenteric border of the gut. These do not cause obstruction during healing.

Intussusception: Rarely a segment of intestine enters into the lumen of proximal segment of intestine, causing obstruction, and strangulation. It may be ileoileal or ileocolic.

Meckel's diverticulum: The apex of midgut loop is connected to secondary yolk sac by vitellointestinal duct. The proximal part of vitellointestinal duct may persist as Meckel's diverticulum. It is 2 inches long present at the antimesenteric border of ileum, 2 feet away from ileocaecal junction. Meckel's diverticulum may be connected to umbilicus by a fibrous band around which intestine may rotate and get obstructed (see Fig. 20.16b).

Internal haemorrhoids: The superior rectal artery divides into right and left branches. Only the right branch divides further into anterior and posterior branches. The veins follow the arteries. The venous radicles are in 3, 7, 11 o'clock positions. The internal piles are accordingly in 3, 7, 11 o'clock positions (see Fig. 33.14).

Cholecystitis: Inflammation of the gallbladder is called cholecystitis. There is pain over right hypochondrium, radiating to the inferior angle of right scapula or to the right shoulder (see Fig. 22.11).

Cholelithiasis: Stone formation in the gallbladder is called cholelithiasis (see Fig. 22.12).

Splenomegaly: Enlargement of spleen is called splenomegaly. It occurs mostly in malaria and blood disorders (see Fig. 23.9).

Splenectomy: Removal of spleen is called splenectomy. One must be careful of the tail of pancreas during splenectomy.

Diabetes mellitus: Deficiency of insulin causes diabetes mellitus.

Carcinoma of head of pancreas: Carcinoma of head of pancreas causes pressure over the underlying bile duct which leads to persistent obstructive jaundice.

Hepatitis: Inflammation of liver is referred to as hepatitis. It may be *infective* or *amoebic* hepatitis.

Cirrhosis: Due to malnutrition or alcohol abuse, the liver tissue undergoes fibrosis and shrinks. This is called cirrhosis of the liver.

Common diseases of kidney: The common diseases of kidney are nephritis, pyelonephritis, tuberculosis of kidney, renal stones and tumours. Common manifestations of a kidney disease are renal oedema and hypertension. Renal transplantation can be tried in selected cases. Lithotripsy is being used for removal of stones.

Ureteric colic: The ureteric colic is referred to T11–T12 segments. The pain radiates from loin to the groin (see Fig. 24.33).

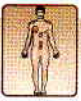Hysterectomy: The procedure of removing uterus for various reasons is called hysterectomy. One has to carefully ligate the uterine artery, which crosses the ureter lying below the base of broad ligament. The integrity of ureter has to be maintained.

Tubectomy: This is a simple operative procedure done in females for family welfare. The peritoneal cavity has to be opened in females. The fallopian tube or uterine tube is ligated at two places and intervening segment is removed. The procedure is done on both sides (see Figs 31.7 and 31.8).

Rupture of male urethra: The membranous part of urethra is likely to be ruptured. The urine fills superficial perineal space, scrotum, penis and lower part of anterior abdominal wall. It cannot go into the thighs because of firm attachment of membranous layer of superficial fascia to their boundaries (see Fig. 28.15).

Tubal pregnancy: Sometimes the fertilized ovum instead of reaching the uterus adheres to the walls of the uterine tube and starts developing there. This is known as *tubal pregnancy*. The enlarging embryo mostly leads to rupture of the fallopian tube.

Prolapse of the uterus: Sometimes the uterus passes downwards into the vagina, invaginating it.



B. For each of the statements or questions below, one or more answers given is/are correct.

- A. If only a, b, c are correct
B. If only a, c are correct
C. If only b, d are correct
D. If a, b, c, d are correct
E. If only d is correct
F. If all are correct
1. Contents of spermatic cord is/are:
a. Ductus deferens
b. Testicular artery
c. Pampiniform plexus of veins
d. Ilioinguinal nerve
2. Epiploic foramen is bounded:
a. Superiorly by the left lobe of the liver
b. Posteriorly by the inferior vena cava
c. Inferiorly by pylorus of stomach
d. Anteriorly by lesser omentum containing hepatic artery, portal vein and bile duct
3. Parasympathetic nerves innervating stomach:
a. Increase the mobility of the stomach
b. Are inhibitory to pyloric sphincter
c. Increase the secretion of pepsin and HCl
d. Are the chief pathway for pain sensation
4. The following statements are true regarding appendix:
a. Appendicular orifice is situated on the posterolateral aspect of caecum.
b. Sympathetic innervation is derived from T10 spinal segment.
c. Pelvic position is the most common position of appendix.
d. Referred pain caused by appendicitis is first felt in the region of umbilicus.
5. Lymphatics of the uterus drain into the following lymph nodes:
a. External iliac
b. Internal iliac
c. Superficial inguinal
d. Deep inguinal.

ANSWERS

- A. 1. a - ii, b - iv, c - i, d - iii, 2. a - iii, b - i, c - ii, d - iv,
3. a - i, b - iv, c - ii, d - iii, 4. a - iv, b - i, c - ii, d - iii
B. 1. D 2. C 3. A 4. C 5. A

Index

A

Abdomen

- autonomic nervous system of 344
- cavity of 229
- osteology of 183
- imaging procedures used for 436
- regions of 229

Acetabulum 6

Aditus to lesser sac 240

Ampulla

- hepatopancreatic 301
- of uterine tube 385
- of Vater 301

Anal canal 413

- musculature of 414
- relations of 413
- sphincters 414

Anastomosis, anastomoses

- around knee joint 80
- on back of thigh 88
- trochanteric 70, 73

Ankle joint 147

Anorectal ring 415

Anserine bursa 110

Anteflexion,

- of uterus 387

Anteversion,

- of uterus 387

Antrum, pyloric 251

Anus 413

Aorta, abdominal 337

Apparatus, extrahepatic

- biliary 287

Arch, arches

- lumbocostal
- lateral 331
- medial 331

of foot

- lateral longitudinal 160
- medial longitudinal 159
- transverse,

anterior 160

posterior 160

plantar 121

venous, dorsal, of foot 125

Artery, arteries

abnormal obturator 48

appendicular 270

arcuate 97

calcanean 104

circumflex femoral

lateral 50

medial 63

circumflex iliac

deep 208

superficial 201

coeliac trunk 275

colic

left 280

middle 278

right 278

common

hepatic 276

iliac 339

cremasteric 208

cystic 276

dorsalis pedis 97, 166

epigastric

inferior 208

superficial 201

superior 208

epiphyseal, of femur 17

femoral 45, 48, 165

gastric

left 276

gastroduodenal 276

gastroepiploic 277

Abdominal aorta 337

gluteal

inferior 70

superior 70

gonadal 339

hepatic common 276

iliac

common 339

deep circumflex 207

external 48

internal 419

iliolumbar 450

jejunal 278

lumbar 339

marginal 281

mesenteric

inferior 280

superior 277, 434

metatarsal 98

1st dorsal 98

musculophrenic 208

obturator 63

of penis

deep 221

dorsal 221

to bulb 221

ovarian 339

pancreatic 301

pancreaticoduodenal

inferior 278

superior 276

perforating 89

peroneal 110

phrenic, inferior 338

plantar

arch 167

lateral 116, 167

medial 116, 166

vessels 128, 165

popliteal 76, 78

profunda femoris 88, 165

pubdental

external

deep 51

superficial 43, 201

internal 70, 364

rectal

inferior 415

middle 410

superior 281

renal 338

sacral

lateral 421

median 339



sciatic 87
sigmoid 280
splenic 277
suprarenal 338
tarsal
 lateral 97
 medial 97
testicular 449
tibial
 anterior 94, 166
 posterior 109, 166
uterine 421
vaginal 421
vesical
 inferior 421
 superior 420
Ascites 232
Axis, uterine 387

B

Ball valve mechanism 213
Barium
 enema 438
 meal 437
Biliary apparatus
 extrahepatic 287
Bones,
 calcaneus 32
 cuboid 35
 cuneiform
 intermediate 35
 lateral 35
 medial 35
 femur 13
 fibula 25
 hip 6
 metatarsal 36
 navicular 33
 patella 19
 phalanges 37
 talus 30
 tibia 22
Bursa, bursae
 anserine 100
 around knee joint 43
 omental 240

C

Caecum 267
 blood supply 268
 relations of 268
Calcar femorale 18
Calf pump 99, 141
Canal
 adductor 55
 Hunter's 55
 inguinal 211
 boundaries of 212
 mechanism of 213
 structures passing
 through 212

Capsules
 of kidney 314
Cervix, of uterus 387
Chain
 sympathetic
 lumbar 344
 sacral 423
Chromaffin system 329
Cisterna chyli 341
Clinical anatomy
 achalasia cardia 249
 Addison's disease 328
 adrenalectomy 328
 adrenogenital syndrome 328
 ankle jerk 108
 annular pancreas 263
 anserina bursitis 101
 anterior tibial compartment
 syndrome 93
 appendicitis 271, 369
 arthroscopy 155
 ascitis 232
 aspiration of hip joint 139
 avascular necrosis of
 femur 63
 talus 31
 Baker's cyst 147
 Barrett's oesophagus 249
 blood pressure in lower limb 79
 bone graft 29
 Buerger's disease 4
 Calot's triangle 291
 caput Medusae 309
 carcinoma oesophagus 265
 carcinoma ovary 398
 carcinoma prostate 407
 carcinoma rectum 412
 catheterization of bladder 380
 cauda equina syndrome 186
 cholecystectomy 291
 cholecystitis 291
 cholelithiasis 291
 cirrhosis of liver, 309
 claw foot 163
 claw toe 155
 clergyman's knee 44
 club foot 163
 colon diverticulitis 267
 comparison of lower and upper
 limbs 132
 congenital dislocation of hip 139
 Courvoisier's law 291
 coxa vara 139
 Cushing's syndrome 329
 cut open procedure 127
 cystocoele 395
 determination of ovulation 384
 diabetes mellitus 304
 diaphragm 331
 diaphragmatic hernia 334
 digital per rectum 412

disc prolapse 186
disease of lumbosacral and
 sacroiliac joint 429
dislocation of ankle 150
duodenal diverticula 263
ectopic testis 225
elephantiasis 129
enlargement of prostate 404
epididymitis 226
episiotomy 369
epispadias 381
extravasation of urine 357, 378
fibroid uterus 392
fistula in ano 354, 417
flat foot 163
floating kidney 318
foot drop 97
fracture of pelvis 369
fracture
 5th metatarsal 37
 neck of femur 19
 Pott's fracture 41
gait lurching 70
gastric carcinoma 255
gastric pain 254
gastric ulcer peptic 254
genu valgum 146
genu varum 146
haemodialysis 318
hallux valgus 156
hammer toe 155
hepatitis 309
hermaphroditism 255
hernia
 external 214
 femoral 48
 inguinal 214
 internal 214, 245
hiatal hernia 335
hiccup 334
high heels 111
housemaid's knee 44
hydrocele 223
hypospadias 381
incisions in abdominal wall 206
injury to common peroneal
 nerve 80
injury to cruciate ligament 147
injury to knee 146
injury to tibial nerve 80
intramuscular injection 55
intrauterine contraceptive
 device 392
kidney stone 318
kyphosis 186
laparotomy 232
liver
 biopsy 309
 resection 309
 transplantation 309
lumbar lordosis 186



mallet toe 155
 march fracture 122
 McBurney's point 271
 Meckel's diverticulum 199, 265
 meningomyelocoele 186
 meralgia parasthetica 48
 Morton's neuroma 119
 Murphy's sign 291
 oesophageal varices 249, 283
 os trigonum 30
 pancreas resection 304
 pancreatic cyst 304
 pancreatitis 304
 partial splenectomy 298
 peripheral heart 106
 peritoneal dialysis 232, 318
 peritonitis 232, 241
 Perthe's disease 139
 pes cavus 163
 thromboangitis obliterans 108
 undescended testis 225
 pes
 calcaneus 122
 equinus
 valgus 122
 varus 122
 phases of gait 155
 pheochromocytoma 329
 piles 416
 polycystic kidney 323
 portal hypertension 283
 portocaval anastomoses 283
 proctoscopy 412
 prolapse of
 disc 186
 ovaries 384
 rectum 354, 412, 416
 uterus 426
 vagina 399
 prostatectomy 404
 pseudohermaphroditism 222
 psoas abscess 342, 348
 pudendal nerve block 364
 rectal incontinence 412
 rectum and anal canal 407
 referred pain 348, 355
 renal angle 317
 rupture of
 urethra 357, 380
 sacralisation of 5th lumbar
 vertebra 186
 sacroiliac strain 429
 sciatica 87
 semimembranous bursitis 87
 Shenton's line 140
 shoulder tip pain 298
 sleeping foot 87
 spina bifida 186
 splenectomy 298
 splenic puncture 298
 splenomegaly 298

spondylolisthesis 186
 sprains of ankle 150
 sterility 386
 strangulated internal hernia 241
 subphrenic abscess 244
 tendocalcaneus reflex 108
 thrombosis of inferior
 vena cava 340
 tracheo-oesophageal fistula 249
 Trendelenburg's test 70, 127
 tubal pregnancy 386
 tubectomy 386
 ureteric colic 323
 ureteric stone 323
 vaginitis 395
 varicocoele 226
 varicose veins and ulcers 127
 vasectomy 400
 vena cava blockage
 inferior 201
 superior 201
 visceral pain 348
 waddling gait 70
 walls of pelvis 429
 Weaver's bottom 13
 talipes equinovarus 163
 Club foot 174
 Coccyx 190
 Coeliac trunk 275
 Colon
 ascending 271
 descending 272
 left flexure of 272
 right flexure of 272
 sigmoid 272
 transverse 272
 Communications
 portosystemic 284
 Compartments
 of leg 93
 of peritoneal cavity
 infracolic 243
 supracolic 243
 Conjoint tendon 206
 Contraceptive devices,
 intrauterine 392
 Cord, spermatic 212
 constituents of 212
 coverings of 212
 Corpus, Corpora
 cavernosa 220
 spongiosum 220
 Coxa vara 139
 Cremaster muscle 206
 Crest
 iliac 6
 Cuboid bone 35
 Cuneiform bones 35
 Curvatures of stomach
 greater 251
 lesser 251
 Chromaffin system 329

D

Dermatomes
 of lower limb 130
 of sole 113
 Descent of testis 226
 Development of organs
 diaphragm 334
 ductus deferens 400
 female reproductive system 395
 gallbladder 308
 gut 233
 kidney and ureter 323
 liver 308
 pancreas 303
 portal vein 284
 prostate 404
 rectum, anal canal 416
 spleen 298
 stomach 255
 suprarenal 329
 testis 226
 urinary bladder and urethra 380
 Diaphragm
 pelvic 424
 thoracoabdominal 331
 Divarication of recti 215
 Duct, ducts
 bile 289
 sphincters related to 289
 cystic 288
 hepatic 287
 main pancreatic 301
 Ductus deferens 399
 blood supply of 400
 course of 402
 Duodenum 268
 relations
 of first part 260
 of fourth part 261
 of second part 260
 of third part 261

E

Elephantiasis 129
 Epididymis 226
 Epiploic foramen 240
 Extrahepatic biliary apparatus 287
 Extravasation of urine 378

F

Falx inguinalis 206
 Fascia
 lata 8
 spermatic 222
 transversalis 211
 Fascia lata 9, 49
 Femoral
 canal 47
 sheath 47, 46
 triangle 45



Femur 13
 Fibula 25
 Fistula
 in ano 417
 Foetogram 440
 Foot
 arches of 159
 dorsum of 106
 Fossa, fossae
 iliac 8
 ischioanal 352
 popliteal 76
 Fundus
 of gallbladder 288
 of uterus 387

G

Gait
 lurching 70
 waddling 70
 Gallbladder 288
 body of 288
 fundus of 288
 neck of 288
 nerve supply of 290
 Ganglion, ganglia
 coeliac 344
 sympathetic, lumbar 344
 Genu valgum 146
 Genu varum 146
 suprarenal 331
 arterial supply 332
 lymphatic drainage 333
 Gluteal region 65
 Guy ropes 101

H

Haemorrhoids 416
 Heart,
 peripheral 106
 Hepatic segments 307
 Hernia
 diaphragmatic 334
 femoral 48
 inguinal 214
 Hip bone 6
 Histology of organs
 anal canal 416
 clitoris 365
 colon 273
 ductus deferens 400
 duodenum 263
 epididymis 226
 gallbladder 292
 ileum 264
 jejunum 264
 kidney 317
 liver 308
 oesophagus 249
 ovary 384
 pancreas 302

penis 365
 prostate 404
 seminiferous tubule 225
 spleen 297
 stomach 255
 suprarenal gland 328
 testis 225
 ureter 317
 urinary bladder 380
 uterine tube 386
 uterus 392
 vagina 395
 vermiform appendix 271
 Hysterosalpingogram 440
 Hysterosalpingography 440

I

Ileum 272
 differences from jejunum 264
 lymphatic drainage of 264
 Ilium 6
 Iliac crest 6
 Iliac tuberosity, 8
 Incisions
 of anterior abdominal wall 206
 Intestine
 differences between large and
 small 266
 large 265
 blood supply 266
 lymphatic drainage 267
 nerve supply of 267
 small 257
 Ischium 11

J

Jejunum 263
 blood supply of 264
 differences from ileum 264
 lymphatic drainage of 264
 Joint
 ankle 147
 ligaments of 148
 movements at 149
 nerve supply of 150
 calcaneocuboid 153
 hip 4, 6, 136
 blood supply of 138
 congenital dislocation of 139
 ligaments of 137
 relations of 138
 intervertebral 193
 knee 140
 blood supply of 144
 ligaments of 143
 movements at 145
 lumbosacral 426
 midtarsal 153
 of lower limb 136
 of pelvis 426
 sacroiliac 427

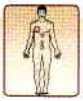symphysis pubis 429
 talocalcanean 152
 talocalcaneonavicular 152
 tibiofibular 158
 inferior 151
 middle 150
 superior 150
 transverse tarsal 153

K

Kidney 312
 blood supply of 316
 capsules of 314
 lymphatic drainage of 316
 relations of 313

L

Labia
 majora 358
 minora 358
 Labrum, acetabular 136
 Layers of abdomen 346
 ligamentum patellae 142
 Leg
 back of 103
 lateral side of 98
 medial side of 100
 Lesser sac of peritoneum 240
 Ligament
 calcaneofibular 29
 cardinal, of uterus 390
 collateral
 fibular 18, 28, 143
 tibial 142
 coronary
 of knee joint 142
 cruciate
 anterior 18, 24, 143
 posterior 18, 24, 143
 deltoid 31, 148
 iliofemoral 16, 137
 iliolumbar 10
 inguinal 11, 197, 205
 ischiofemoral 12, 137
 Mackenrodt's 390
 metatarsal, transverse
 deep 155
 of uterus 390
 popliteal, oblique 143
 sacroiliac, dorsal 10
 sacroteruberous 428
 sacrospinous 428
 talofibular
 anterior 149
 posterior 149
 tibiofibular
 anterior 151
 inferior transverse 29, 151
 interosseous 151
 posterior 151



tibionavicular 30
 Line, lines
 gluteal 8
 Liver 304
 blood supply of 307
 lymphatic drainage of 307
 relations of 306
 segments of 307
 Lobe, lobes
 of liver 305
 Lower limb,
 dermatomes of 130
 joints of 136
 inguinal lymph nodes
 deep 128
 superficial 128
 lymphatic drainage of 127
 myotomes of 131
 of posterior abdominal wall 340
 radiological anatomy 170
 segmental innervation 130
 surface marking of 165
 sympathetic innervation 131
 venous drainage of 124
 Lymphatic drainage of
 kidney 316
 liver 307
 pancreas 302
 spleen 297
 stomach 252
 suprarenal gland 328
 urinary bladder 375
 Lymphatics
 cisterna chyli 341
 of lower limb 129
 deep 129
 superficial 129

M

McBurney's point 270
 Mechanism of
 erection of penis 221
 inguinal 213
 Membrane
 obturator 12
 perineal 357, 361
 structures piercing 357, 361
 Meningocele 186
 Meningomyelocele 186
 Menisci of knee joint
 lateral 24
 medial 24
 Mesentery 235
 Mesoappendix 236
 Mesocolon
 sigmoid 237
 transverse 236
 Murphy's sign 291
 Muscle, muscles
 abductor
 hallucis 37

adductor
 hallucis 37, 120
 of thigh
 brevis 10, 17, 59
 longus 10, 17, 59
 magnus 17, 59, 84
 articularis genu 53
 biceps femoris 28, 84
 cremaster 10
 extensor
 digitorum brevis 33, 95
 digitorum longus 28, 95
 hallucis longus 28, 95
 flexor
 digiti minimi brevis 120
 digitorum accessorius 116, 117
 digitorum brevis 33
 digitorum longus 37, 108,
 116, 117
 hallucis brevis 35, 120
 hallucis longus 29, 108, 116,
 117
 gastrocnemius 17, 106
 gemellus
 inferior 12
 superior 12
 gracilis 10, 59
 hamstrings 83
 iliacus 10, 16, 341
 interossei of foot 115, 121
 obturator
 externus 10, 12, 16, 67
 internus 10, 16, 67
 of abdominal wall
 anterior 202
 oblique,
 external 202
 internal 203
 transversus 8, 204
 posterior 341
 of leg
 anterior compartment 95
 lateral compartment 99
 posterior compartment 106,
 108
 of pelvis 10, 424
 of perineum 364
 of sole 115
 pectineus 59
 peroneus
 brevis 28, 36, 99
 longus 28, 36, 99
 tertius 28, 61, 95
 piriformis 67
 plantaris 17, 32, 106
 popliteus 18, 108
 psoas major 16, 341
 pyramidalis 207
 quadratus
 femoris 12, 67
 lumborum 8, 341
 quadriceps femoris 53
 rectus, abdominis 204
 sartorius 8, 53
 semimembranosus 12, 24, 84
 semitendinosus 12, 84
 soleus 25, 28, 106
 tensor fasciae latae 8
 tibialis
 anterior 25, 35, 36
 posterior 25, 28, 34, 108
 vastus
 intermedius 16
 lateralis 17, 21
 medialis 17, 21
 Myotomes of lower limb 131

N

Navicular bone 33
 Nerve, nerves
 accessory obturator 59
 cutaneous
 of calf, lateral 104
 perforating 70
 femoral 46, 52, 168
 genitofemoral 46, 343
 gluteal
 inferior 184
 superior 70
 lower intercostal 441
 lumbar 343, 441
 obturator 59
 pelvic
 autonomic 423
 splanchnic 423
 peroneal
 common 29, 76, 77, 168
 deep 92, 95, 168
 superficial 168
 plantar
 medial 169
 lateral 169
 pudendal 70, 363, 442
 saphenous 91, 103
 sciatic 168
 sural 104
 communicating 104
 tibial 77, 79, 110
 to obturator internus 73
 to quadratus femoris 73
 Notch
 greater sciatic 11
 lesser sciatic 11
 acetabular 12

O

Oesophagus
 abdominal part 248
 Ometum
 greater 234
 lesser 234



Ovary 382
 blood supply of 384
 relations of 383

P

Pain
 referred 258, 300

Pancreas 298
 external features 299
 body of 300
 ducts of 301
 head of 299
 neck of 300
 tail of 301
 uncinate process of 300

Paraganglia 329

Patella 4

Pelvic
 cavity 370
 inlet 367
 structures crossing 370
 outlet 368

Pelvimetry 191

Pelvis
 cavity of 370
 floor of 369
 mechanism 429

Pelvis, bony 191
 morphological classification 192

Penis
 body of 220
 corpora cavernosa 220
 corpus spongiosum 220
 lymphatic drainage of 221
 mechanism of erection 221
 nerve supply of 221
 prepuce of 220
 root of 219
 veins of 221

Perineal body 352

Perineum 350
 divisions of 350

Peritoneal cavity 231, 238

Peritoneum 229
 folds of 230
 gutters, paracolic 244
 horizontal tracing 239
 lesser sac of 240
 vertical tracing 238

Phalanges of foot 37

Plane
 subcostal 197
 transpyloric 197
 transtubercular 197

Plexus (of nerves)
 abdominal aortic 444
 coeliac 344
 hypogastric
 inferior 445
 superior 445

lumbar 422, 441
 sacral 442

Prostate 401
 age changes 404
 blood supply of 402
 capsules of 402
 senile enlargement of 407

Pubis 11

Pyelography 438
 descending 438
 excretory 438
 retrograde 439

R

Radiological anatomy
 of lower limb 170
 of abdomen and pelvis 436

Rectum 407
 arterial supply of 410
 relations of 408
 supports of 411
 venous drainage of 410

Rectus sheath 209

Reflex
 cremasteric 206

Retinaculum, retinacula
 around ankle
 extensor
 inferior 93
 superior 93
 flexor 105
 peroneal 98

S

Sacrum 187

Scrotum 221
 blood supply of 222
 layers of 222
 nerve supply of 222

Segments
 hepatic 307

Space, spaces
 deep perineal space 360
 perineal 415
 schioanal 415
 subphrenic 243
 superficial perineal space 362

Spine, iliac
 anterior inferior 7
 anterior superior 6

Spleen 294
 arteries of 296
 functions of 297
 lymphatic drainage of 297
 relations of 295

Splenectomy 298

Splenomegaly 298

Stomach 250
 blood supply of 252
 external features of 250

lesser curvature of 251
 lymphatic drainage of 252
 nerve supply of 253
 relations of 251

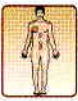Subphrenic spaces 243

Suprarenal gland 326

Surface marking
 of abdomen 431
 viscera
 abdominal aorta 434
 appendix vermiform 432
 ascending colon 432
 bile duct 433
 caecum 432
 coeliac trunk 434
 common iliac artery 434
 descending colon 433
 duodenum 432
 external iliac artery 434
 gallbladder 433
 ileocaecal valve 432
 inferior vena cava 435
 inguinal canal 435
 kidney 433
 liver 433
 mesenteric artery,
 inferior 434
 superior 434
 pancreas 433
 portal vein 435
 rectum and anal canal 433
 root of mesentery 435
 spleen 431
 stomach 431
 transverse colon 433
 ureter 433

of lower limb
 anterior tibial 166
 dorsalis pedis 166
 femoral 165
 femoral ring 169
 flexor retinaculum 169
 inferior extensor
 retinaculum 169
 inferior gluteal 165
 lateral plantar 167
 medial plantar 166
 plantar arch 167
 popliteal artery 165
 posterior tibial 166
 profunda femoris 165
 saphenous opening 169
 superior extensor
 retinaculum 169
 superior gluteal 165

of nerves
 common peroneal 168
 deep peroneal 168
 femoral 168
 lateral plantar 169



medial plantar 168
sciatic 168
superficial peroneal 168
tibial 168
of veins 177
 femoral 167
 great saphenous 167
 small saphenous 167
Sympathetic
 chain
 lumbar 442
 pelvic 442
 innervation of
 lower limb 131
 abdomen 443
 pelvis 444
Symphysis pubis 429
System, chromaffin 329

T

Talus 30
 necrosis 31
Tarsus 29
Terms clinical 177, 448
Testis 223
 arteries of 224
 coverings of 224
 descent of 226
 lymphatic drainage of 225
 nerve supply of 225
 structure of 224
 veins of 225
Thigh
 back of 83
 front of 40
 medial side of 59
Tibia 22
Tract iliotibial 44
Trochanters, of femur
 greater 15
 lesser 15

U

Ulcer
 peptic 254
Umbilicus 197, 198

Ureter 318
 female pelvis 394
Urethra
 female 379
 male 376
Urinary bladder 372
 blood supply of 375
 capacity of 375
 external features 372
 interior of 374
 ligaments of 374
 lymphatic drainage of 375
 nerve supply of 375
 relations of 373
Urine, extravasation of 357
Uterine tube 385
Uterus 387
 anteflexion of 387
 anteversion of 387
 axis of 387
 body of 387
 cervix of 387
 development 395
 fundus of 387
 histology 392
 ligaments of 389
 lymphatic drainage of 390
 nerve supply of 390
 supports of 390

V

Vagina 393
 fornices of 393
 relations of 393
Valve, valves
 ileocaecal 268
Varicocele 226
Varicose veins 127
Vein, veins
 anal 415
 cystic 290
 dorsal venous arch 91
 femoral 45, 51, 167
 gastric 252
 mesenteric
 inferior 281
 superior 279

oesophageal 248
of penis, dorsal
 deep 221
 superficial 221
pampiniform plexus of 225
perforating, perforator 125
 direct 126
 indirect 126
portal 282
 branches of 283
 tributaries of 283
rectal
 deep veins of lower limb 124
 inferior 415
 internal iliac 421
 middle 411
 plantar 116
 seminal vesicle 401
 superficial veins 124
 superior 410
 vertebral system of veins 405
saphenous
 great 167
 long 167
 short 77, 167
 small 77, 167
Vena cava, inferior 339
Venous return, factors helping 124
Vermiform appendix 269
 blood supply 270
 lymphatic drainage 271
 nerve supply 270
 peritoneal relations 270
Vertebra, lumbar 183
 fifth 184

W

Wall
 abdominal
 anterior 196
 posterior 337
 pelvic 419

Z

Zona orbicularis 137
Zone, transitional, of anal canal 414